

Detection and management of a complex canal configuration in mesiobuccal root of maxillary first molar using three dimensional imaging

Velagala L. Deepa, Indira Priyadharsini Bollu¹, Bhargavi Dhamaraju, Padmasri Yadla

Department of Conservative Dentistry and Endodontics, Lenora Institute of Dental Sciences, ¹Department of Conservative Dentistry and Endodontics, St. Joseph Dental College, Andhra Pradesh, India

Corresponding author (email: <drdeeparamesh@yahoo.com>)

Dr. Velagala L. Deepa, Department of Conservative Dentistry and Endodontics, Lenora Institute of Dental Sciences, Rajanagram, Rajahmundry, Andhra Pradesh - 533 401, India.

Received: 24-02-16

Accepted: 07-04-16

Published: 26-04-16

Abstract

This case report discusses the identification and management of complex canal configuration of 3-2-1 in the mesiobuccal (MB) root of the maxillary left first molar. Careful attention to details of the pulpal floor and applying the knowledge of the laws of orifice location along with deepening the subpulpal groove with ultrasonic tips helped in identifying the three MB canals. Manual scouting helped in understanding the anatomic configuration; the use of three-dimensional imaging technique and spiral computed tomography (SCT) confirmed the same. SCT images showed buccolingually wide and bulbous mesiobuccal root with three separate canals at coronal third that merged into two canals in the middle and exited as a single canal at the apex. This article highlights the role of SCT in three-dimensionally analyzing the unseen rarest canal configurations that ultimately enabled the clinician to thoroughly explore, debride, and obturate the entire root canal system.

Key words: Canal configuration, maxillary first molar, mesiobuccal canal, spiral computed tomography

INTRODUCTION

Internal anatomy of the mesiobuccal (MB) root of the maxillary first molar has been studied extensively for the past three decades because this is the root that exhibited the maximum number of variations not only in the presence of extra canals but also in their canal configuration. The literature showed 73.2% to 93% incidence of two canals^[1] and only 1.1% occurrence of three canals.^[2] Three canals in the MB root with a configuration of Vertucci type 8 (3-3), Sert and Bairily type XV, or type XVIII (3-2/3-1) have been reported.^[3,4] However, complex configurations

of 3-2-1 and 2-3-2-1-2 canal types in the MB root have rarely been described in studies either *in vitro* or *in vivo*.^[5] The present case report describes one such atypical configuration of 3-2-1 in the MB root of maxillary first molar. The canal morphology was confirmed using spiral computed tomography (SCT) scan findings.

CASE REPORT

A young Indian male patient reported with the chief complaint of spontaneous pain of moderate intensity in

This is an open access article distributed under the terms of the Creative Commons Attribution-NonCommercial-ShareAlike 3.0 License, which allows others to remix, tweak, and build upon the work non-commercially, as long as the author is credited and the new creations are licensed under the identical terms.

For reprints contact: reprints@medknow.com

How to cite this article: Deepa VL, Bollu IP, Dhamaraju B, Yadla P. Detection and management of a complex canal configuration in mesiobuccal root of maxillary first molar using three dimensional imaging. J Int Soc Prevent Communit Dent 2016;6:S75-8.

Access this article online	
Quick Response Code:	Website: www.jispcd.org
	DOI: 10.4103/2231-0762.181190

the upper left back tooth region for the past two weeks. He gave a history of localized, mild, intermittent pain in the same region one month back that had increased in intensity in the past three days. On intraoral examination of the second quadrant, the first molar had a deep carious lesion and was mildly tender on vertical percussion. The tooth showed no response to thermal and electric pulp testing procedures. There was no history of swelling or any other associated signs and symptoms. On radiographic examination, there was pulpal involvement with widening of periodontal ligament space [Figure 1a]. Based on these findings, the tooth was diagnosed as a nonvital tooth with chronic apical periodontitis, and the patient was planned for endodontic therapy. The maxillary left first molar was first isolated using rubber dam and then access cavity preparation was initiated. After deroofting the pulp chamber, the MB, distobuccal (DB), and palatal canals were located. Following along the dentinal map and slowly removing a shelf of dentin covering the dentinal map, a small groove connecting the MB and the palatal canal orifices was identified. Access cavity was further widened toward the mesial marginal ridge to facilitate easy exploration along this subpulpal groove, and by probing with DG 16 explorer two additional sticky canal entrances were identified. These extra canals were then negotiated using No. 08 K files. Based on their anatomic location on the pulpal groove, the canal orifice nearer to the palatal orifice was named as palatal mesiobuccal (p-MB) whereas the one nearer to the MB canal orifice was named as middle mesiobuccal (m-MB) [Figure 1b] The three canals in the MB root and their working length were confirmed with multiple angled periapical radiographs using Ingle's method as well as electronic apex locator (Root

ZX; Morita, Tokyo, Japan) [Figure 1c]. A careful interpretation of working length radiograph revealed a complex canal configuration of 3-2-1 in the MB roots. A single canal with a single apical foramen was noted in both the distobuccal and palatal roots and the access was closed with a temporary restoration.

The presence of this unusual 3-2-1 canal configuration in the MB root was confirmed using a three-dimensional imaging technique SCT-Dentascan (GE Healthcare, USA) after explaining to the patient. The SCT images showed buccolingually wide and bulbous mesiobuccal root with three separate canals at coronal third that merged into two canals in the middle and exited as a single canal at the apex [Figure 2c].

At the next visit, shaping of the MB, DB, and the palatal canals was done using Ni-Ti Protaper rotary files (Dentsply, Maillefer, Switzerland) in a passive crown-down manner under copious irrigation with 3% sodium hypochlorite solution. m-MB and p-MB canals were cautiously prepared to avoid stripping of the MB root using only hand instrumentation in step back technique. The canals were then obturated with gutta-percha in conventional lateral condensation technique followed by core build up with silver amalgam. After a week, the tooth was prepared for full veneer crown. At six month recall and evaluation, the tooth was functional and completely asymptomatic [Figure 1d].

DISCUSSION

A clinician should always remember that the occurrence of a single canal with single exit is not always a rule because there is every possibility for the anatomic

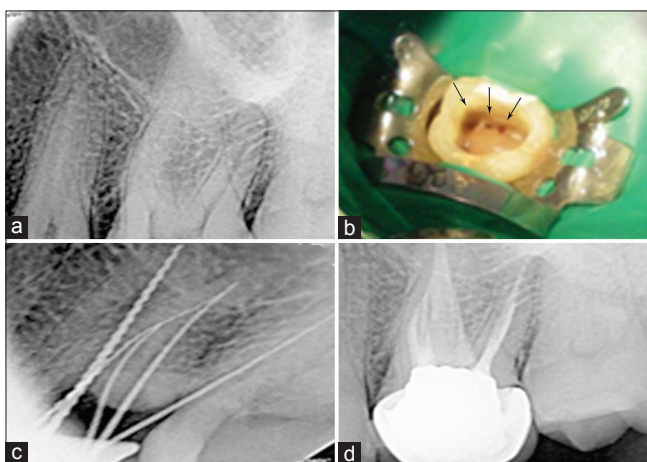


Figure 1: (a) Preoperative radiograph, (b) access opening showing three distinct orifices in the MB root, (c) working length radiograph, (d) postobturation radiograph

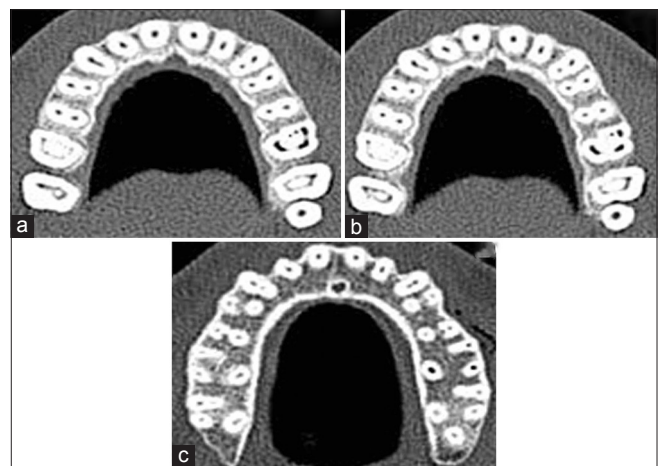

Figure 2: Spiral CT images (a) coronal third, (b) middle third, (c) apical third

complexities to exist in any tooth and in any of the roots. Having the knowledge of anatomic variations and the clinician's skill helps in locating and negotiating these complexities. Endodontic success depends on thorough debridement and complete obturation of the entire root canal system.^[1] The present case is one such example of the presence of three canals in the MB root of maxillary first molar with unusual internal anatomy. The anatomic configuration of three canals as 3-2-1 was identified by scouting the canals with hand files. Among the three canals, the major canal was the MB; the second major canal, m-MB, joined the MB canal in the apical third, whereas p-MB is the smallest canal that joined MB canal in the middle third. Manual scouting also helped in differentiating between a true canal and a fin. This same configuration is also confirmed using multiple medially angulated radiographs taken with files in the MB root and further confirmed using three-dimensional imaging technique, SCT. Although SCT has the disadvantage of more radiation exposure than Cone Beam Computed Tomography (CBCT)^[6], it is used due to the lack of availability of CBCT. The axial scans in apical third showed buccopalatally elongated bean-seed shaped MB root, being wider buccally and with concavity toward the furcation that is on its distal side. Taking this shape into consideration, m-MB and p-MB were conservatively prepared so as to prevent stripping on the distal side.^[2]

A literature search was conducted on PubMed data base to note the reported cases for the presence of three canals in the MB root of maxillary first molar and the results are tabulated in Table 1. The possible canal configurations reported were Vertucci's type VIII (3-3; 3 separate canals with separate foramina), Sert and Bairley's XV-3-2 configuration, XVIII-3-1 configuration, and XXI-4-1 configuration.

Sert,^[5] in his *in vitro* study on Turkish population, first reported the occurrence of 3-2-1 canal configuration in the MB root of maxillary first molar. Later, similar configuration was reported by Arora *et al.* in the MB root of the maxillary second molar.^[7] Based on this literature review, the present article is one of the rarest configurations to be reported in the MB root of the first molar.

CONCLUSION

An increased awareness of incidence of extra canals in the MB root of maxillary first molar with a better understanding of the complex canal configurations and use of advanced diagnostic aids, such as SCT, helps the clinician in proper diagnosis and correct endodontic

Table 1: Case reports of three mesio buccal canals of maxillary first molar

Year	Authors	MB	DB	P
1983	Martinez-Berna ^[9]	3MBs	2DBs/j	1P
1984	Beatty ^[9]	3MBs	1DB	1P
2005	Ferguson DB ^[9]	3MBs/j	1DB	1P
2006	Amauri Favieri <i>et al</i> ^[9]	3MBs/j	1DB	1P
2007	Adanir N ^[9]	3MBs/j	1DB	2P
2009	Sanaa Ibrahim ^[9]	3MBs/j	2DBs/j	1P
2010	Garg ^[9]	XV	1DB	1P
2010	Kottoor ^[6]	XV	2DBj	2Pj
2011	Ma ^[9]	3MB	1DB	1P
2011	Du ^[10]	3MBs	1DB	2P
2011	Kottoor ^[11]	XV	XV	2P/j
2011	Leyla B Ayranci ^[4]	XVIII	1DB	1P
2011	zhang ^[12]	3MB	1DB	1P
2012	Kakkar P ^[13]	XV	1DB	1P
2013	Kaushik M, Mehra N ^[14]	XV	2j	2j
2014	Martins JN ^[15]	XXI	2j	1P
2014	Raghavendra SS ^[16]	XV	2j	2s
2014	Kumar ^[17]	XV	2j	2j
2014	Badole G ^[18]	3-3	2s	2s
2015	Nayak G <i>et al</i> ^[19]	XV	3-2-1DB	1P
2015	Munavalli A <i>et al</i> ^[20]	XVIII	2j	2j

s=Separate canals with separate foramina, j=Canals joining in the apical one third, XV=3-2 configuration, XVIII=3-1 configuration, XXI=4-1 configuration

management of the rarest variations to achieve a successful endodontic outcome.

Financial support and sponsorship

Nil.

Conflicts of interest

There are no conflicts of interest.

REFERENCES

1. Stropko JJ. Canal morphology of maxillary molars: Clinical observations of canal configurations. *J Endod* 1999;25:446-50.
2. Degerness RA, Bowles WR. Dimension, anatomy and morphology of the mesiobuccal root canal system in maxillary molars. *J Endod* 2010;36:985-9.
3. Garg AK, Tewari RK, Kumar A, Agarwal N. Endodontic treatment of a maxillary first molar having three mesio buccal canals with the aid of spiral computed tomography: A case report. *J Oral Sci* 2010;52:495-9.
4. Ayranci LB, Arslan H, Topcuoglu HS. Maxillary first molar with three canal orifices in mesio buccal root. *J Conserv Dent* 2011;14:436-7.
5. Sert S, Bayirli GS. Evaluation of the root canal configurations of the mandibular and maxillary permanent teeth by gender in the Turkish population. *J Endod* 2004;30:391-8.
6. Cotton TP, Geisler TM, HoldenDT, Schwartz SA, Schindler WG. Endodontic Applications of Cone-Beam

- Volumetric Tomography. *J Endod* 2007;33:1121-32.
7. Arora A, Acharya SR, Saraswathi MV, Sharma P, Ather A. Dilemmas pertaining to three canals in the mesiobuccal root of a maxillary second molar: A case report. *Restor Dent Endod* 2013;38:172-7.
 8. Kottor J, Velmurugan N, Sudha R, Hemamalathi S. Maxillary first molar with seven root canals diagnosed with cone-beam computed tomography scanning: A case report. *J Endod* 2010;36:915-21
 9. Ma L, Yu J, Sun JJ. Maxillary first molar with three mesiobuccal root canals: A case report. *Hua Xi Kou Qiang Yi Xue Za Zhi*. 2011;29:102-3
 10. Du Y, Soo I, Zhang CF. A case report of six canals in a maxillary first molar. *Chin J Dent Res*. 2011;14:151-3.
 11. Kottor J, Velmurugan N, Surendran S. Endodontic management of a maxillary first molar with eight root canal systems evaluated using cone-beam computed tomography scanning: A case report. *J Endod* 2011;37:715-9.
 12. Zhang P, Mao LS. Left maxillary first molar with three mesiobuccal canals: A case report. *Beijing Da Xue Xue Bao*. 2011;43:919-20.
 13. Kakkar P, Singh A. Maxillary first molar with three mesiobuccal canals confirmed with spiral computer tomography. *J Clin Exp Dent*. 2012;4:256-9.
 14. Kaushik M, Mehra N. Maxillary first molars with six canals diagnosed with the aid of cone beam computed tomography: A report of two cases. *Case Rep Dent*. 2013; 2013:406923.
 15. Martins JN. Endodontic treatment of a maxillary first molar with seven root canals confirmed with cone beam computer tomography – Case report. *J Clin Diagn Res*. 2014;8:ZD13-5.
 16. Raghavendra SS, Hindlekar AN, Desai NN, Vyavahare NK, Napte BD. Endodontic management of a maxillary first molar with seven root canals diagnosed using cone beam computed tomography scanning. *Indian J Dent*. 2014;5:152-6.
 17. Kumar R. Report of a rare case: A maxillary first molar with seven canals confirmed with cone-beam computed tomography. *Iran Endod J*. 2014;9:153-7.
 18. Badole G, Waebadpande MM, Shenoi PR, Lachure C, Badole SG. A rare root canal Configuration of bilateral maxillary first molar with 7 root canals diagnosed using Cone-beam computed tomographic scanning: A case report. *J Endod*. 2014;40:296–301.
 19. Nayak G, Singh KK, Shekhar R. Endodontic management of a maxillary first molar with three roots and seven root canals with the aid of cone-beam computed tomography. *Restor Dent Endod*. 2015;40:241-8.
 20. Munavalli A, Kambale S, Bandekar S, Aijaonkar N. Maxillary first molar with seven root canals diagnosed with cone-beam computed tomography scanning. *Indian J Dent Res*. 2015; 26:82-5.