



Review Article

Anatomical snuff box approach for percutaneous coronary interventions – Current status

Surender Deora^{a,*}, Dushyant Agrawal^a, Rahul Choudhary^a, Atul Kaushik^a, Tejas M. Patel^b^a All India Institute of Medical Sciences, Jodhpur, India^b NHL Medical College, Ahmedabad, India

ARTICLE INFO

Article history:

Received 7 January 2021

Received in revised form

8 August 2021

Accepted 20 August 2021

Available online 25 August 2021

Keywords:

Anatomical snuff box

Distal radial artery

Coronary interventions

ABSTRACT

Anatomical snuff box or distal radial artery approach for various percutaneous coronary angiograms and interventions has gained increased interest in recent years. The main advantage is the ergonomic comfort to the patient as it allows the patient's arm to be in more natural position. The safety and feasibility of this novel approach has been studied in past few years but still the data is limited and the distal radial artery approach has not been included in the guidelines. The present review focuses on the latest evidence, technique, advantages and disadvantages of this distal radial artery access.

© 2021 Cardiological Society of India. Published by Elsevier B.V. This is an open access article under the CC BY-NC-ND license (<http://creativecommons.org/licenses/by-nc-nd/4.0/>).

1. Introduction

Transradial Approach (TRA) is the default vascular access for coronary angiography (CAG) and percutaneous coronary intervention (PCI) worldwide. It has fewer access site complications as compared to Transfemoral Approach (TFA). But still radial artery occlusion (RAO) and forearm hematomas are observed with conventional TRA and is a clinical concern. The other sites of vascular access distal to wrist crease are the ulnar artery in hypothenar prominence and distal radial artery (dRA) in anatomical snuff box (ASB). Ulnar artery is running deep in hypothenar muscles and therefore its access is difficult and more painful whereas dRA is better palpable in ASB and therefore an alternative to conventional TRA. Moreover, the prone position of the arm during the dRA access is more natural and comfortable. There are many case reports, case series, observational studies, few randomized trials and a meta-analysis of this novel approach and its comparison with conventional TRA has been published.^{1,2} This review of anatomical snuff box is focused on the history, anatomy, clinical and technical considerations.

2. History

The earliest description of the term anatomical snuff box or tabatié' re anatomique is from French text in 1850 where it is mentioned as "Dans ce que Bichat appellee la tabatiere anatomique" or "in what Bichat called the anatomical snuffbox".³ It was also mentioned as anatomic snuff-box of Cloquet in texts of early 1900s referring to French anatomist Jules Germin Cloquet (1790–1883).⁴ This depression on the dorsum of the hand was used to place and snuff the powdered tobacco in 19th century and hence the name was derived.

3. Anatomy

The ASB or fossa radialis is a small depression on dorso-radial aspect of wrist (Fig. 1). This region is seen better when the palm is placed flat on the table and the thumb is extended and lifted off of the table. This little triangular area is often used to perform clinical procedures like cannulation of the cephalic vein, distal radial artery (dRA) and surgical procedures as creating arteriovenous fistula. The base of ASB is formed by the distal margin of the retinaculum of extensor muscles, styloid process of radius and laterally limited by the tendons of abductor pollicis longus and extensor pollicis brevis muscles, and medially limited by the tendon of extensor pollicis longus muscle (Fig. 2). The vertex is confirmed by the attachment of

* Corresponding author. Medical college, AIIMS Jodhpur, Room No. 3131, Rajasthan, 342005, India.

E-mail address: drsdeora@gmail.com (S. Deora).

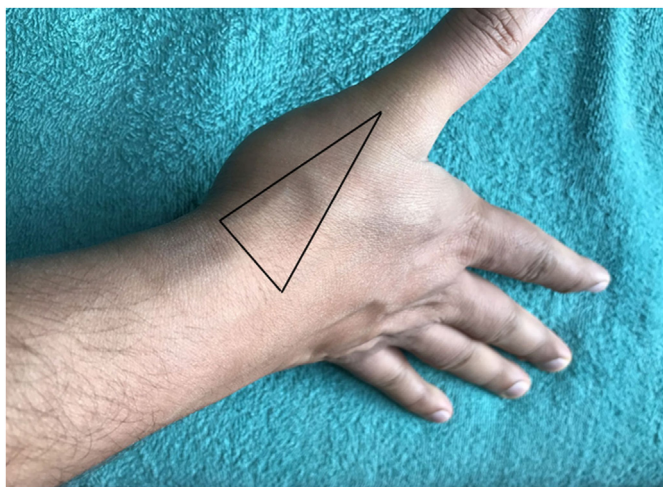


Fig. 1. Right hand in semi prone position showing a triangular depression (anatomical snuff box) on the dorso-radial aspect.

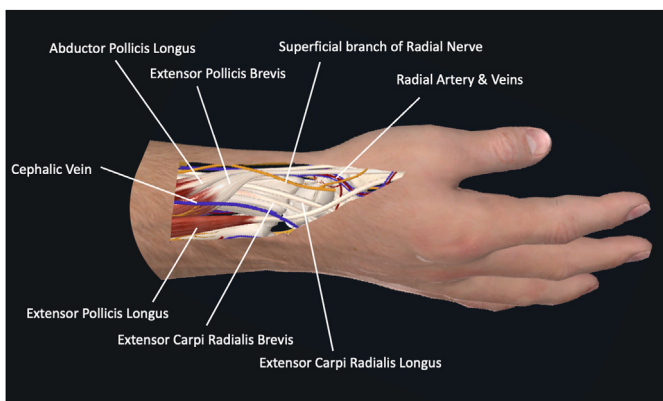


Fig. 2. Right hand in semi prone position showing neurovascular anatomy of anatomical snuff box.

the tendons of extensor pollicis longus and extensor pollicis brevis muscles. The roof is formed by the skin and superficial fascia, in which cephalic vein and superficial branch of the radial nerve lies. The deep structures forming bottom of this region are the scaphoid, trapezium and the base of the first metacarpal bone. The radial artery, covered by fat pad through its passage in the depth of snuff box (onto trapezium bone) penetrates deep to the tendons of the abductor pollicis longus and extensor pollicis brevis muscles and is located very near to the base of the ASB. In this area, superficial branch of the radial nerve & lateral cutaneous nerve of forearm, lies either superimposed on the radial artery or located on radial side of it.

The radial artery and ulnar artery form the Superficial and Deep palmar arch (Fig. 3). The superficial palmar arch (SPA) is formed by superficial palmar branch of radial artery and the end of ulnar artery. After giving superficial palmar branch, the radial artery curves around the wrist to enter the ASB and through first interosseous space crosses the palm and forms deep palmar arch (DPA) along with deep palmar branch of ulnar artery. Therefore, the ulnar artery mainly forms SPA whereas radial artery is the main vessel forming the DPA.

4. Clinical considerations

TRA through right radial artery (RRA) is the default access for percutaneous coronary artery procedures all over the world. Dr

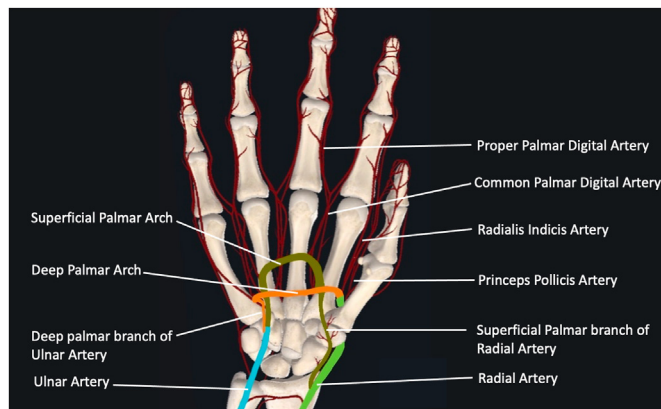


Fig. 3. Right hand supine position showing anatomy of superficial and deep palmar arch.

Lucian Campeau first time introduced TRA for CAG by using 5F catheters and Dr Ferdinand Kiemeneij did PCI for the first time using 6F guiding catheters.^{5,6} The vascular and bleeding related complications are significantly less with TRA resulting in decreased morbidity and mortality as compared to TFA. It is also more comfortable to the patients and allows for their early ambulation and discharge from the hospital. TRA through RRA is preferred because the working position of the operator is towards the right side of the patient. But sometimes access to RRA is not feasible because of occlusion due to previous procedure, spasm, small diameter, extreme tortuosity and presence of right radial arterio-venous fistula for dialysis and thus left radial artery (LRA) access is chosen. Also, CAG in post Coronary Artery Bypass Graft (CABG) patients, LRA is preferred for left internal mammary artery (LIMA) angiography. But LRA approach is cumbersome for operator because of unfavorable position as the operator has to bend forwards for the procedure and it becomes more challenging in obese patients. It also exposes the operator for increased radiation exposure because of direct (proximity to source of radiation) and the scattered radiation (from patient body). Patients for LRA access have to keep the forearm in supine position over the torso which is also uncomfortable if kept for prolonged procedure. But there are many advantages with LRA access as compared to RRA access. Post procedure, the patients are more comfortable with LRA access as majority of them are right-handed with pressure hemostasis of left wrist give them easy and free movement of right hand. The vascular access through left dRA has been proposed to overcome the disadvantages of conventional LRA access and now increasingly been used for CAG and PCI.

The initial description of dRA approach was in 2011 by Babunashvili in Russia, who used this approach to facilitate retrograde radial artery recanalization.⁷ In 2016, Dr Roghani at 4th International Cardiovascular Joint Congress, Isfahan, Iran described merits of more distal accesses in the hand for coronary angiography and intervention in female patients who wear bracelets covering the forearm, limiting hemostasis. Then in 2017, Dr Kaledin shared his experience of this approach for endovascular interventions in over 2500 patients at Cardio Update Europe.⁸ The first feasibility report of left dRA came from The Netherland by Kiemeneij in 70 patients in whom LRA access was preferred over RRA access for CAG and PCI.⁹ Patients with weak or absent pulse in left dRA, left handedness, indwelling venous canula near to ASB and patient's refusal were the main reasons for not performing left dRA access. There were eight patients with failure to gain access of left dRA requiring crossover to conventional LRA or RRA approach. Most commonly 6F sheath was used in 40 patients followed by 5F in 22 and 4F in 8

patients. No major complication was noted with left dRA approach. Follow-up assessment was seen in 50 of 62 patients (81%) and radial artery was patent at conventional forearm site in all except in one patient with occluded distal radial artery. After this feasibility study by Kiemeneij, various single and multicenter studies were published establishing the safety and feasibility of dRA approach for CAG and PCI.¹⁰ The LeDRA trial, a prospective, observational registry enrolled 200 consecutive patients who were planned for CAG and having a palpable left distal radial artery.¹¹ Puncture site complication was seen in 15 patients including minor hematomas in 14 patients and arterial dissection in one patient. At one month follow-up, two patients had left thumb numbness and no distal radial artery occlusion. The dRA approach has also been attempted successfully in patients with ST-segment myocardial infarction (STEMI) undergoing primary PCI, patients with chronic total occlusion (CTO) and PCI for bifurcation and unprotected left main coronary artery disease. In a study of 138 patients with STEMI, the operators attempted the dRA in patients with well-palpable pulse with the success rate was 92.8% and all patients underwent successful primary PCI.¹² The procedure was performed by left dRA in 80.5% of the patients with 6F guiding catheter in most of the cases (97.7%). There was no major bleeding reported but 3.1% of patients had local access-site complications (three local hematoma and one case of local numbness which improved after 3 months). Similarly, the safety and feasibility of this approach was established in patients with CTO. A study by Gasperini et al recruited 41 patients undergoing CTO PCI and left dRA was successfully accessed with 7F Glidesheath Slender in 82.9% of patients.¹³ The procedural success was seen in 78.1% of patients with no immediate access site complications but 4.3% RAO at one month Doppler follow-up. Isolated case report of PCI of unprotected left main coronary artery disease from left dRA have also been reported.^{14,15}

When compared with conventional TRA approach, dRA approach has been shown to have significantly reduced radial artery occlusion (RAO) rate. In a study by Wang et al of 620 patients who underwent PCI with either conventional TRA or dRA approach, there was no significant difference in puncture time, puncture success rate, procedure time, puncture site hemorrhage, hematoma and aneurysm but RAO was significantly lower in dRA access ($p < 0.05$).¹⁶ Similar findings were observed in a meta-analysis of five studies (four observational and one randomized trial), with a total of 4676 patients.¹⁷ The rate of RAO was lower with dRA approach (2.30 versus 4.86%, RR = 0.51; 95%CI 0.32–0.81; $p = 0.004$) as compared to conventional TRA. There was no difference in radial artery spasm, radial artery dissection and local hematoma. Another recent prospective, randomized study by Eid-Lidt et al in 282 patients showed dRA approach prevents RAO in the proximal segment at 24 h and 30 days after the procedure compared with conventional TRA.¹⁸ But a retrospective study by Chugh et al from India on the safety and efficacy of dRA, revealed statistically non-significant difference in RAO between dRA and conventional TRA at 1-day and 30-day follow up.¹⁹ The ongoing multicenter randomized controlled trials TENDERA (NCT04211584) and DISCO Radial (NCT04171570), comparing conventional TRA with dRA approach will enlighten us further with regard to vascular access site complications especially late RAO rate.

There is limited data with regard to procedural time and radiation exposure with dRA approach as compared to conventional TRA approach. An observational study by Bhambhani et al in 200 patients undergoing CAG showed increased procedural time with dRA approach (13.4 ± 4.2 vs 9.2 ± 3.1 min; $p < 0.01$) but insignificant difference in fluoroscopic time between the two groups.²⁰ With increase in experience and after certain learning curve (at least 50 successful puncture), the procedural time could be decreased further specially the time to access the artery in ASB.

5. Technical considerations

The wrist is painted and draped in neutral semi-prone position in sterile environment. Local anesthesia (1–2 ml of lidocaine) is infiltrated in skin and subcutaneous tissues with or without 200–500 µg nitroglycerine for tumescent anesthesia.²¹ The most important challenge with dRA approach is having successful rate of puncture which varies between 70 and 100%. The only randomized study by Koutouzis et al showed increased rate of cannulation failure, prolonged duration of cannulation and increased number of attempts with dRA approach.²² The only benefit of dRA approach in this study was shorter duration of hemostasis. Increased failure of cannulation of dRA may be due to small size and tortuosity of the artery in the ASB. The use of ultrasound may increase the success rate of dRA access and help in avoiding the damage to superficial branch of radial nerve and adjacent tendon. A study by Mori et al compared feasibility and safety between ultrasound-guided and conventional dRA access for CAG or PCI.²³ The authors concluded that ultrasound-guided dRA access was associated with a lower failure rate but with no significant differences in puncture time and complication rate. Also, the utility of ultrasound is in vessels with straight course and diameter more than 2 mm.²⁴ Indian patients have smaller radial artery dimensions with the mean diameter of 1.7 mm in males and 1.6 mm in females and therefore the use of ultrasound for dRA access needs to be evaluated.²⁵

Usually, the access is gained with either 20 or 21G needle as in routine radial artery cannulation but anterior and proximal puncture at the base of the triangle is preferred. “Through and through” puncture technique is usually not preferred because carpal bone is just underneath the artery and hitting the periosteum with needle causes severe pain and may lead to spasm of dRA. Once the access is obtained, the preferred sheath which is usually 6F in diameter in most of the cases is inserted and spasmolytic is given as per the institutional protocol (Fig. 4). In complex cases where larger access is required, 7 Fr Glidesheath Slender (Terumo) or 7 Fr Railway Sheathless (RS) access system (Cordis Corporation) may be helpful.²⁶ After the procedure is completed, the sheath is flushed with saline and vasodilator (diltiazem or verapamil) may be given to reduce local site pain and the chances of RAO.²⁷

There are no standard protocols for hemostasis in patients with dRA approach but lighter compression is safe and effective as compared to conventional TRA approach.²⁸ Hemostasis can be achieved with manual compression, use of gauze ball followed by

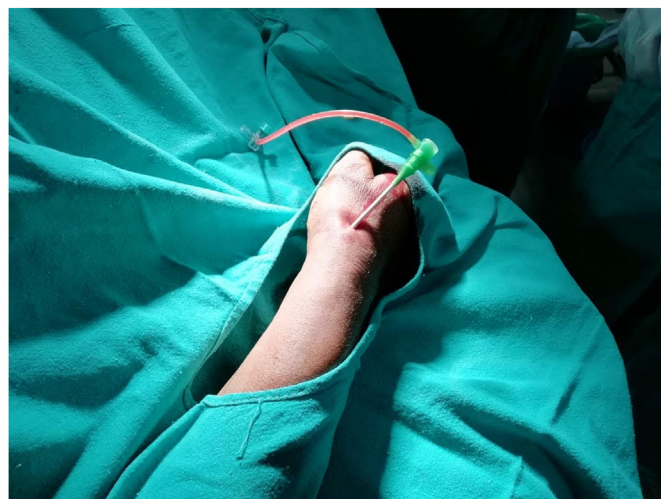


Fig. 4. Semi prone position of right hand showing 6 French sheath in distal radial artery.

application of sterile semi elastic bandage or use of TR band (Terumo Medical). Recently, some dedicated disposable, hemostatic devices (PSD; Merit Medical Systems, Inc., South Jordan, UT) have been developed for compression at the puncture site of dRA with patent hemostasis protocol.²⁹ Hemostasis is achieved after 2–3 h and the blood flow is maintained in the dRA without damage at 1 month after catheterization. Hemostatic patches have also been used for hemostasis after dRA approach.³⁰ There are no randomized studies of safety and efficacy of different hemostasis methods in patients with dRA approach.

The following are the advantages and disadvantages of dRA approach.

Advantages of distal radial artery access.

1. The prone position of hand is a more natural as compared to supine position therefore is more comfortable for patients.
2. There is reduced risk of RAO although debatable as compared to the conventional access of radial artery. This may help in repeat procedures and also preserves radial artery for free graft during CABG.
3. There is reduced risk of hand ischemia as flow is maintained through superficial palmar arch.³¹
4. Hemostasis is achieved relatively early in approx. 2–3 h and there is no edema over the hand as there is no major vein compressed.
5. Left dRA is preferred over conventional LRA because of more comfort for both patient and operator.

Disadvantages of distal radial artery access.

1. The dRA is small in diameter, tortuous and therefore relatively more challenging to gain access.
2. The available catheter lengths may be short specially in taller patients (above 6 feet) as the access is 3–5 cm distal to the conventional radial puncture site.
3. The conventional larger radial introducer sheaths of > 7F are difficult to introduce and therefore may limit the interventions requiring larger access.

6. Conclusion

The choice of vascular access for CAG and PCI has changed from TFA to TRA. In last few years various case series, observational, non-randomized and small randomized studies of the safety and feasibility of dRA access in various clinical settings has been published. The main advantage of dRA access is that it is more patient friendly and claimed to cause less RAO but simultaneously has many challenges. It is to be seen in coming years with large randomized trials the advantage of dRA over conventional TRA in terms safety and efficacy.

Funding

Nil.

Declaration of competing interest

Nil.

Acknowledgements

Nil.

References

1. Aoi S, Htun WW, Freeo S, et al. Distal transradial artery access in the anatomical snuffbox for coronary angiography as an alternative access site for faster hemostasis. *Cathet Cardiovasc Interv.* 2019;94(5):651–657.
2. Schenke K, Viertel A, Joghetaei N, et al. Distal transradial access for coronary angiography and interventions in everyday practice: data from the TRIANGLE registry (Twitter initiated registry for coronary ANgiography in Germany via distal radial access). *Cardiol Ther.* 2021;10(1):241–253.
3. Fabre F. *Bibliothèque du médecin-praticien*. 12. Paris, France: Chez J.-B. Baillière; 1850.
4. Davis GG. *Applied Anatomy*. Philadelphia, Pa: J.B. Lippincott Company; 1910. circa.
5. Campeau L. Percutaneous radial artery approach for coronary angiography. *Cathet Cardiovasc Diagn.* 1989;16(1):3–7.
6. Kiemeneij F, Laarman GJ, de Melker E. Transradial artery coronary angioplasty. *Am Heart J.* 1995;129(1):1–7.
7. Babunashvili A, Dundua D. Recanalization and reuse of early occluded radial artery within 6 days after previous transradial diagnostic procedure. *Cathet Cardiovasc Interv.* 2011;77(4):530–536.
8. Kaledin AKI, Podmetin P, Ardeev VN. *Distal Radial Artery in Endovascular Interventions. Distal Radial Artery in Endovascular Interventions*; 2017. Available online from: <https://www.researchgate.net/publication/319162208>.
9. Kiemeneij F. Left distal transradial access in the anatomical snuffbox for coronary angiography (ldTRA) and interventions (ldTRI). *Euro Intervention.* 2017;13:851–857.
10. Mizuguchi Y, Izumikawa T, Hashimoto S, et al. Efficacy and safety of the distal transradial approach in coronary angiography and percutaneous coronary intervention: a Japanese multicenter experience. *Cardiovasc Interv Ther.* 2019;24:1–6.
11. Lee JW, Park SW, Son JW, Ahn SG, Lee SH. Real-world experience of the left distal transradial approach for coronary angiography and percutaneous coronary intervention: a prospective observational study (LeDRA). *EuroIntervention.* 2018;14:995, 100.
12. Kim Y, Lee JW, Lee SY, et al. Feasibility of primary percutaneous coronary intervention via the distal radial approach in patients with ST-elevation myocardial infarction. *Korean J Intern Med.* 2021;36(Suppl 1):S53–S61.
13. Gasparini GL, Garbo R, Gagnor A, Oreglia J, Mazzarotto P. First prospective multicentre experience with left distal transradial approach for coronary chronic total occlusion interventions using a 7 Fr Glidesheath slender. *Euro-Intervention.* 2019;15(1):126–128.
14. Kim Y, Jeong MH, Kim I, et al. Intravascular ultrasound-guided percutaneous coronary intervention with drug-eluting stent for unprotected left main disease via left snuffbox Approach. *Korean Circ J.* 2018;48(6):532–533.
15. Kim Y, Jeong MH, Kim MC, et al. Successful percutaneous coronary intervention with two-stent technique for unprotected true left main bifurcation lesion via left snuffbox Approach. *J Invasive Cardiol.* 2019;31(3):E55.
16. Wang H, Peng WJ, Liu YH, et al. A comparison of the clinical effects and safety between the distal radial artery and the classic radial artery approaches in percutaneous coronary intervention. *Ann Palliat Med.* 2020;9(5):2568–2574.
17. Hamandi M, Saad M, Hasan R, et al. Distal versus conventional transradial artery access for coronary angiography and intervention: a meta-analysis. *Cardiovasc Revascularization Med.* 2020;S1553–8389(20):30154–30158. <https://doi.org/10.1016/j.carrev.2020.03.020>.
18. Eid-Lidt G, Rivera Rodríguez A, Jimenez Castellanos J, Farjat Pasos JJ, Estrada López KE, Gaspar J. Distal radial artery approach to prevent radial artery occlusion trial. *JACC Cardiovasc Interv.* 2021;14(4):378–385.
19. Chugh Y, Kanaparthi NS, Piplani S, et al. Comparison of distal radial access versus standard transradial access in patients with smaller diameter radial Arteries(The distal radial versus transradial access in small transradial ArteriesStudy: D.A.T.A - S.T.A.R study). *Indian Heart J.* 2021;73(1):26–34.
20. Bhamhani A, Pandey S, Nadamani AN, Tyagi K. An observational comparison of distal radial and traditional radial approaches for coronary angiography. *J Saudi Heart Assoc.* 2020;32(1):17–24.
21. Chen Y, Ke Z, Xiao J, et al. Subcutaneous injection of nitroglycerin at the radial artery puncture site reduces the risk of early radial artery occlusion after transradial coronary catheterization: a randomized, placebo-controlled clinical trial. *Circ Cardiovasc Interv.* 2018;11, e006571.
22. Koutouzis M, Kontopodis E, Tassopoulos A, et al. Distal versus traditional radial approach for coronary angiography. *Cardiovasc Revascularization Med.* 2019;20(8):678–680.
23. Mori S, Hirano K, Yamawak M, et al. A comparative analysis between ultrasound guided and conventional distal transradial access for coronary angiography and intervention. *J Intervent Cardiol.* 2020;2020:7342732.
24. Hull E, Kinsey EN, Bishop WL. Mapping of the snuffbox and cubital vessels for percutaneous arterial venous fistula (pAVF) in dialysis patients. *J Vasc Access.* 2013;14(3):245e251.
25. Chugh SK, Chugh S, Chugh Y, Rao SV. Feasibility and utility of pre-procedure ultrasound imaging of the arm to facilitate transradial coronary diagnostic and interventional procedures (PRIMAFACIE-TRI). *Cathet Cardiovasc Interv.* 2013;82(1):64–73.
26. Colletti G, Auslender J, De Meester A, Aminian A, Kayaert P, Ungureanu C. Feasibility and safety of performing complex coronary interventions by distal

- radial artery using the Railway sheathless vascular system. *J Invasive Cardiol*. 2020;32(12):459–462.
27. Dharma S, Kedev S, Patel T, Kiemeneij F, Gilchrist IC. A novel approach to reduce radial artery occlusion after transradial catheterization: postprocedural/prehemostasis intra-arterial nitroglycerin. *Cathet Cardiovasc Interv*. 2015;85(5):818–825.
 28. Sgueglia Gregory A, Lee Bong-Ki, Cho Byung-Ryul, et al. Distal radial access: consensus report of the first korea-europe transradial intervention meeting, JACC. *Cardiovascular Interventions*. 2021;14(8):892–906.
 29. Kawamura Y, Yoshimachi F, Nakamura N, Yamamoto Y, Kudo T, Ikari Y. Impact of dedicated hemostasis device for distal radial arterial access with an adequate hemostasis protocol on radial arterial observation by ultrasound. *Cardiovasc Interv Ther*. 2021;36:104–110.
 30. Hadjivassiliou A, Cardarelli-Leite L, Jalal S, et al. Safety and efficacy of a truncated deflation algorithm for distal transradial access. *J Vasc Intervent Radiol*. 2020;31:1328–1333.
 31. Nairoukh Z, Jahangir S, Adjepong D, Malik BH. Distal radial artery access: the future of cardiovascular intervention. *Cureus*. 2020;12(3), e7201.