

This article is licensed under the Creative Commons Attribution-NonCommercial 4.0 International License (CC BY-NC) (<http://www.karger.com/Services/OpenAccessLicense>). Usage and distribution for commercial purposes requires written permission.

Single Case

Mind the Gap: Successful Endoscopic Closure of a Large Gastric Sleeve Leak Using an Endoscopic Stent and Over-the-Scope Clips

Jiannis Anastasiou Anas Hussameddin Abdulaziz Al Quorain

King Fahd University Hospital, Imam Abdulrahman bin Faisal University,
Khobar, Saudi Arabia

Keywords

Gastric leak · Endoscopic stent · Over-the-scope clip

Abstract

Laparoscopic sleeve gastrectomy (LSG) is gaining popularity for the treatment of morbid obesity. It is regarded as a simple, low-cost procedure achieving significant weight loss within a short period of time. LSG is considered a safe procedure with a relatively low complication rate. The complications encountered nevertheless can result in significant morbidity and may even be lethal. The most significant complications are staple-line bleeding, stricture, and staple-line leak. The purpose of this paper is to present a case of a 31-year-old patient complicated by a 3.06 cm staple-line leak 10 days after LSG. Review of the current literature regarding this complication as well as outline of a strategy for the management of large post-LSG gastric leaks is suggested.

© 2017 The Author(s)
Published by S. Karger AG, Basel

Introduction

Laparoscopic sleeve gastrectomy has become widely implemented in the surgical management of obesity. Advantages of the method include satisfactory weight loss, no rerouting of the intestinal system, thus eliminating the risk of late bowel obstruction due to internal

herniation, and significantly less nutritional deficiencies [1]. However, staple line leaks represent a serious complication associated with significant morbidity and mortality and an incidence varying from 0.2 to 20% [2]. Since the advent of sleeve gastrectomy, endoscopic stents have been used successfully to treat gastric leaks [3–5]. The treatment of gastric leak is variable and depends on the size of the disruption, the severity of the abdominal infection, and the location of the leak. Combined endoscopic treatment of gastric leaks with endoscopic stenting and over-the-scope clips has been reported [6]. Here we report a case of a 31-year-old woman with a large early leak successfully managed with endoscopic stenting and over-the-scope clips.

Case Presentation

A 31-year-old woman weighing 117 kg with a BMI of 46.1 (52 kg of excess weight) presented to the bariatric surgery department and underwent a laparoscopic sleeve gastrectomy. She had an uneventful recovery and was discharged home. Ten days after the sleeve gastrectomy, she presented with nausea, vomiting, diffuse abdominal pain, and high-grade fever. She did not endorse gastrointestinal bleeding, change in bowel movements, recent travel, or sick contacts. On physical examination, she did not have signs of peritonitis but she was pyrexial (39.1°C). Blood work revealed systemic inflammation (C-reactive protein 46 mg/L and leukocytosis with 13.7×10^9 leukocytes per liter with 84% neutrophils). CT of the abdomen showed a $2.7 \times 3.9 \times 2.7$ cm collection just anterior to the superior splenic pole. Upper GI series showed a 3.06 cm leak right distally to the gastroesophageal junction at the anterior wall of the sleeve. Total parenteral nutrition and intravenous antibiotics were administered. An upper endoscopy was performed to evaluate the location and the extent of the leak. Given the large size of the leak, the decision was made to place a 23×155 mm fully covered Boston Scientific Wallflex stent and two Ovesco over-the-scope clips measuring 10.5 and 8.5 mm, respectively. Gastrografin study following the procedure showed no leak (Fig. 1). The patient was discharged home on liquid diet for 2 weeks, to which protein shakes were later added and subsequently advanced to pureed diet. Significant postprocedure clinical improvement was noted. The patient did not report any nausea, fever, diarrhea, vomiting, or abdominal pain and was able to tolerate oral feeding. An upper endoscopy was repeated 8 weeks later. Abdominal and chest X-rays were performed before the procedure, showing that one of the over-the-scope clips was not found and had passed spontaneously. The proximal part of the fully covered stent had partially folded and was removed successfully without complications. Gastrografin study performed during the procedure did not show any leak (Fig. 2). Three months after the stent removal, the patient is doing well denying any gastrointestinal symptoms. A weight loss of 12 kg was reported representing 23% excess weight loss. The patient endorses a completely functional performance status.

Discussion

Laparoscopic sleeve gastrectomy is an established surgical procedure for the treatment of obesity. It reduces the stomach size and promotes less hunger. Moreover, the hormonal changes it induces indicate its success, which is not only due to restricted food intake. Ghrelin levels decrease and GLP-1 and PYY levels increase, promoting satiety, while insulin resistance improves and promotes glycemic control [7, 8]. Although this procedure is less

complex than the Roux-en-Y gastric bypass, its complications can potentially be more serious and even life-threatening. The most important complications are hemorrhage at the staple line in 2% of the cases, stricture of the mid-gastric sleeve area in nearly 1%, and gastric leaks with varying reported incidence of 0.7–20% [9]. The wide reported range of gastric leaks may be attributed to the expertise and experience of the centers at which the procedure is performed and the applied protocols. Higher gastric leak rates tend to be higher at teaching hospitals and at centers that perform routinely barium contrast studies to every patient on the third postoperative day, thus increasing the possibility of detecting small sub-clinical leaks.

Gastric leaks are classified based on time of appearance after surgery, clinical severity, and location [10]. Early leaks occur from the first and fourth postoperative day, intermediate leaks between the fifth and the ninth day, and late leaks appear after the tenth day. Type I or subclinical leaks are classified as localized leaks without spillage, with mild clinical manifestations, and can be managed conservatively. Type II are those with dissemination into the abdomen or pleural cavity. The majority of the leaks occur in the proximal portion of the stomach, close to the gastroesophageal junction [11].

Ischemia of the gastric wall adjacent to the staple line is considered to be a major risk factor for gastric leak. Ischemic fistulas tend to form between the fifth and sixth postoperative day, during the transition of the healing process from inflammatory to fibrotic. Mechanical fistulas are identified earlier within the first couple postoperative days.

The clinical spectrum of symptoms of gastric leak patients varies from asymptomatic to sepsis, multi-organ failure, and death. The commonest manifestations are fever (81%), epigastric pain (69%), tachycardia (44%), and leukocytosis (75%) [7]. Gastrografin study and CT scan are used to identify gastric leaks. During subsequent endoscopy, carbon dioxide use is preferred given its more rapid absorption.

The management of gastric leaks depends on the hemodynamic status of the patient and the timing of appearance. Patients presenting with severe sepsis and hemodynamic instability prompt surgical re-intervention. Early leaks also usually need surgical management. Intermediate and late leaks in the majority of cases can be treated successfully with medical treatment.

Medical management involves drain placement, parenteral or enteral nutrition, high doses of proton pump inhibitors, broad spectrum antibiotics, use of biological glues, and placement of fully covered stents. The use of endoscopic stents in the management of gastric leaks has gained popularity due to minimal invasiveness, early enteral nutrition initiation, shorter hospital stay, cost effectiveness, and controlling local infection with stent placement. The success rate of gastric leak closure ranges from 50 to 83% [2, 8, 9]. Complications of stent insertion include early removal of the stent due to stent migration, bleeding, and obstruction due to kinking of the proximal portion of the stent [9]. Stent migration is the main drawback of the technique requiring stent removal. Partially covered stents were used initially. Complications of partially covered stent placement include the following: difficulty of stent removal or even impossibility to remove, additional endoscopy required to remove the stent in case of initial failure by placing another stent to facilitate stent removal, the need of dilation in 20% of the cases due to tissue ingrowth. Fully covered metal stents have the advantage of removal with one procedure but at the expense of a higher migration rate [3, 12].

Given the large size of our patient's leak, the decision was made to deploy both over-the-scope clips and a fully covered metal stent aiming at closing the largest reported gastric leak endoscopically. A successful combined endoscopic treatment would significantly lower the hospitalization cost and complete the treatment in a single repeat endoscopy. Therefore, we

report that over-the-scope clips if placed in healthy edges of the gastric leak can achieve partial closure of a 3-cm gastric leak. A fully covered metal stent can subsequently be deployed to ensure complete sealing and prevention of stricture formation. To the best of our knowledge, this the largest gastric leak size reported treated endoscopically by stenting and clipping. This novel approach if applied carefully in selected patients may significantly reduce morbidity, mortality, and hospitalization cost of gastric leak patients.

Statement of Ethics

The authors have no ethical conflicts to disclose.

Disclosure Statement

The authors declare no conflicts of interest in relation to this article.

References

- 1 Sakran N, Goitein D, Raziel A, Keidar A, Beglaibter N, Grinbaum R, et al: Gastric leaks after sleeve gastrectomy: a multicenter experience with 2,834 patients. *Surg Endosc* 2013;27:240–245.
- 2 Nguyen NT, Nguyen X-MT, Dholakia C: The use of endoscopic stent in management of leaks after sleeve gastrectomy. *Obes Surg* 2010;20:1289–1292.
- 3 van Boeckel PGA, Dua KS, Weusten BLAM, Schmits RJH, Surapaneni N, Timmer R, et al: Fully covered self-expandable metal stents (SEMS), partially covered SEMS and self-expandable plastic stents for the treatment of benign esophageal ruptures and anastomotic leaks. *BMC Gastroenterol* 2012;12:19.
- 4 Leenders BJM, Stronkhorst A, Smulders FJ, Nieuwenhuijzen GA, Gilissen LPL: Removable and repositionable covered metal self-expandable stents for leaks after upper gastrointestinal surgery: experiences in a tertiary referral hospital. *Surg Endosc* 2013;27:2751–2759.
- 5 Puli SR, Spofford IS, Thompson CC: Use of self-expandable stents in the treatment of bariatric surgery leaks: a systematic review and meta-analysis. *Gastrointest Endosc* 2012;75:287–293.
- 6 Shehab H, Abdallah E, Gawdat K, Elattar I: Large Bariatric-Specific Stents and Over-the-Scope Clips in the Management of Post-Bariatric Surgery Leaks. *Obes Surg* 2017, DOI: 10.1007/s11695-017-2808-1.
- 7 Karamanakos SN, Vagenas K, Kalfarentzos F, Alexandrides TK: Weight loss, appetite suppression, and changes in fasting and postprandial ghrelin and peptide-YY levels after Roux-en-Y gastric bypass and sleeve gastrectomy: a prospective, double blind study. *Ann Surg* 2008;247:401–407.
- 8 Serra C, Baltasar A, Andreo L, Pérez N, Bou R, Bengochea M, et al: Treatment of gastric leaks with coated self-expanding stents after sleeve gastrectomy. *Obes Surg* 2007;17:866–872.
- 9 Tan JT, Kariyawasam S, Wijeratne T, Chandraratna HS: Diagnosis and management of gastric leaks after laparoscopic sleeve gastrectomy for morbid obesity. *Obes Surg* 2010;20:403–409.
- 10 Csendes A, Burdiles P, Burgos AM, Maluenda F, Diaz JC: Conservative management of anastomotic leaks after 557 open gastric bypasses. *Obes Surg* 2005;15:1252–1256.
- 11 Burgos AM, Braghetto I, Csendes A, Maluenda F, Korn O, Yarmuch J, et al: Gastric leak after laparoscopic-sleeve gastrectomy for obesity. *Obes Surg* 2009;19:1672–1677.
- 12 Swinnen J, Eisendrath P, Rigaux J, Kahegeshe L, Lemmers A, Le Moine O, et al: Self-expandable metal stents for the treatment of benign upper GI leaks and perforations. *Gastrointest Endosc* 2011;73:890–899.

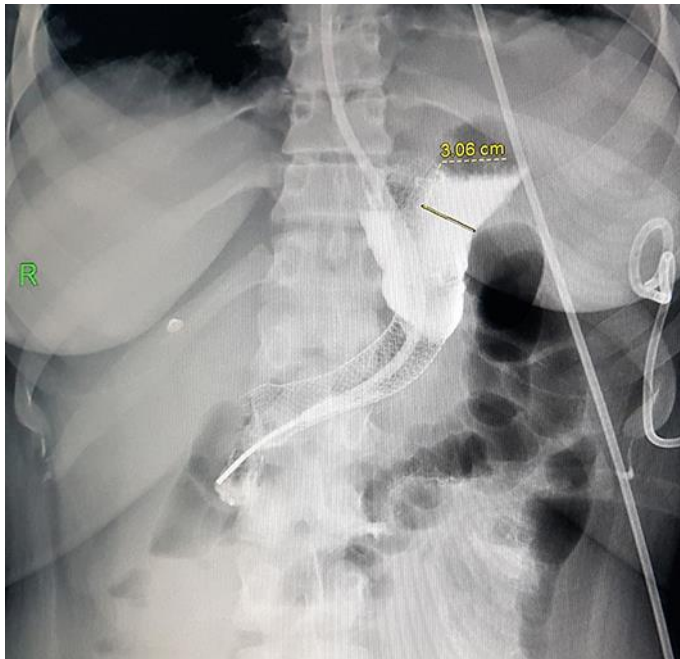


Fig. 1. Upper gastrointestinal series after stent and clips placement showing gastric leak size.

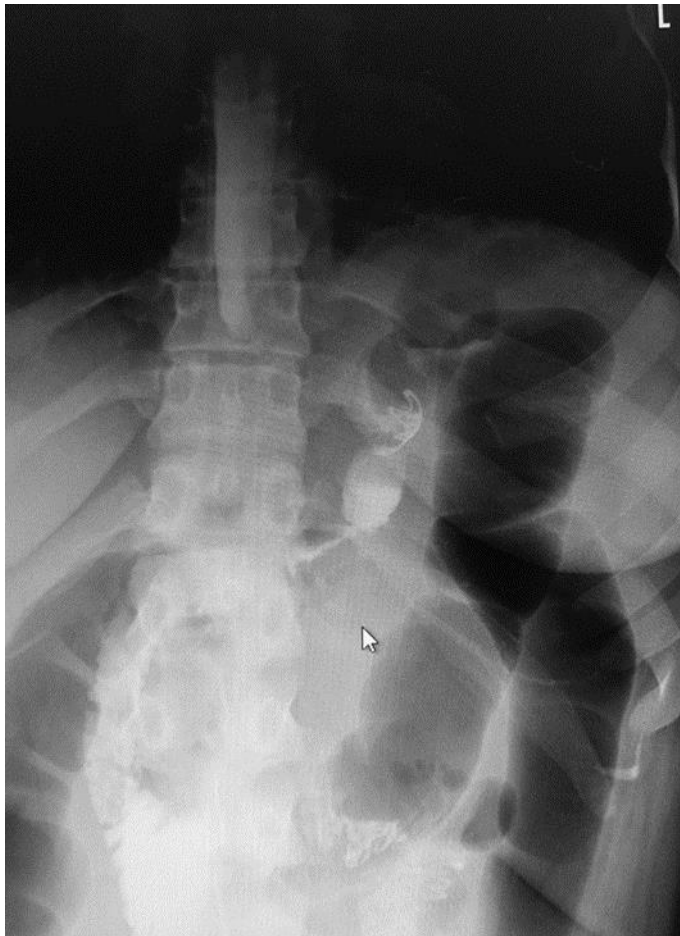


Fig. 2. Upper gastrointestinal series showing closure of leak after stent removal.