

Drug-Eluting Beads Bronchial Arterial Chemoembolization Combined with Immunotherapy Resulted in Pathological Complete Response of Squamous Cell Lung Cancer: A Case Report

Guanghui He¹, Kunning Yang², Zhi Gao¹, Xiaofa Zhang³, Aiqiang Han⁴

¹Interventional Department, Weifang No. 2 People's Hospital, Weifang, People's Republic of China; ²Respiratory Medicine Department, Weifang No. 2 People's Hospital, Weifang, People's Republic of China; ³Interventional Department, Anqiu People's Hospital of Weifang, Weifang, People's Republic of China; ⁴Department of Gerontology, Weifang No. 2 People's Hospital, Weifang, People's Republic of China

Correspondence: Aiqiang Han, Department of Gerontology, Weifang No. 2 People's Hospital, Weifang, Shandong Province, People's Republic of China, Email aiqianghan@139.com

Abstract: The incidence of lung cancer is the highest among all tumors, and treatment has become an urgent problem to be solved. The Drug-eluting bead-based bronchial arterial chemoembolization (DEB-BACE) combination immunotherapy is a rare neoadjuvant therapy for lung cancer surgery, which can significantly reduce the time it takes for lung cancer patients to undergo surgery. We report a male patient, aged 59-year-old, with Stage-III b squamous cell lung cancer accompanied by hemoptysis underwent surgical resection after DEB-BACE combination immunotherapy treatment 21 days later without obvious adverse events. A pathologic complete response (pCR) was observed postoperatively, and the patient has made a successful recovery. The DEB-BACE combined with immunotherapy might be a new neoadjuvant therapy option for locally advanced non-small cell lung.

Keywords: drug-eluting bead-based bronchial arterial chemoembolization, immunotherapy, squamous cell lung cancer, case report

Introduction

In China, lung cancer has the highest morbidity and mortality rates of all malignant tumors, and 80–85% are non-small cell lung cancer (NSCLC), of which squamous cell carcinoma (SCC) accounts for approximately 30%.¹ Surgical resection or combination therapy, including radiotherapy and chemotherapy, is currently the preferred treatment for patients with Stage-I, II, or locally advanced NSCLC. However, even after complete tumor resection, patients still have a low overall long-term survival. Use of neoadjuvant therapy eliminates micro-metastatic lesions present in the patient's body before surgery,² which effectively prolongs patient survival. Forde et al first reported the effectiveness of immunotherapy as a preoperative neoadjuvant therapy for NSCLC.³ Neoadjuvant chemotherapy (NCT) in combination with immunotherapy were proposed, in succession.⁴

Bronchial arterial infusion (BAI) chemotherapy and bronchial arterial chemoembolization (BACE) are key methods for the treatment of advanced lung cancer. Drug-eluting bead-based bronchial arterial chemoembolization (DEB-BACE) is an enhancement of this technique. Compared with BACE, DEB-BACE has more significant advantages in patients with lung cancer with hemoptysis, as it reduces hemoptysis recurrence while enhancing tumor treatment efficacy. The combination of DEB-BACE and immunotherapy neoadjuvant therapy shortens the duration of surgery.⁵ In this paper, we review our recent experience with DEB-BACE in combination with immunotherapy as a preoperative neoadjuvant therapy for lung SCC at our hospital.

Case Report

A 59-year-old male patient was admitted to our hospital on June 14, 2022, due to hemoptysis. Contrast-enhanced computed tomography (CT) imaging of the chest (Figure 1) revealed a space-occupying lesion in the lower lobe of the right lung, with clear borders, with the largest cross-sectional diameter being 69×63 mm. The lesion showed heterogeneous, moderate enhancement. The mediastinal and right hilar lymph nodes were enlarged, and the bronchial and intercostal arteries were significantly enlarged. Pathological findings indicated SCC. The multidisciplinary panel of Oncology (MDT) unanimously agreed on a definitive diagnosis of right lung SCC, with clinical staging of cT3N2M0, staging iiib, and consideration of preoperative neoadjuvant therapy. Considering the clinical manifestations and pathological stages of the patients, DEB-BACE combined immunotherapy was finally used as an important means of preoperative neoadjuvant therapy.

The DEB-BACE was performed on June 22, 2022. No staining was found in the tumor and pleura after embolization, as shown in Figures 2 and 3. Tislelizumab 200 mg was administered intravenously on June 23, 2022. The patient had significantly reduced hemoptysis and was discharged 5 days after surgery. After discharge, the patient developed intermittent fever during which he coughed up a large amount of gray-black necrotic material, but no massive hemoptysis occurred. The patient was re-admitted to the hospital on July 15, 2022, and underwent contrast-enhanced chest CT (Figure 4), which

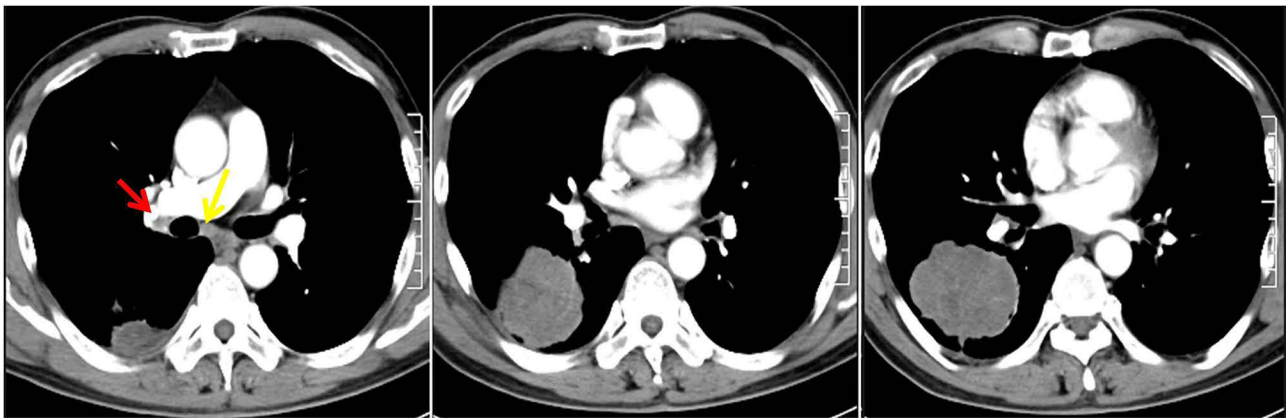


Figure 1 Contrast-enhanced computed tomography of the patient on admission. Red arrow: right hilar lymph node. Yellow arrow: mediastinal lymph nodes.

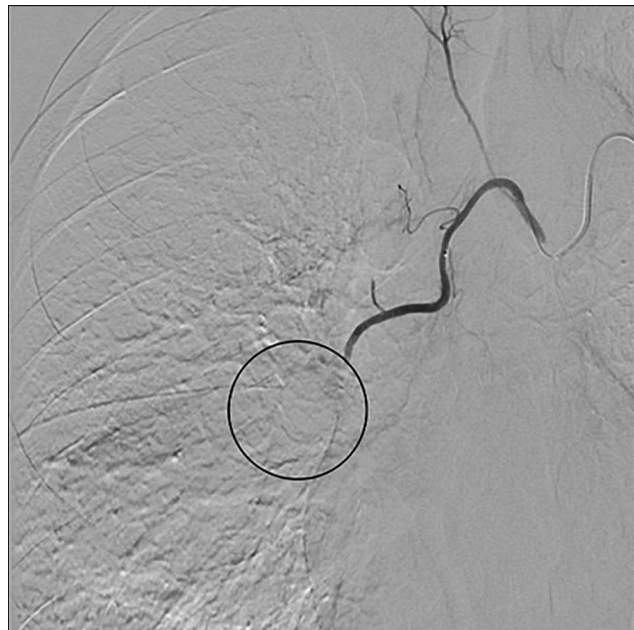

Figure 2 Tumor staining after embolization. Following the embolization procedure, there is a notable absence of staining in the tumor. Circle: Missing tumor staining.

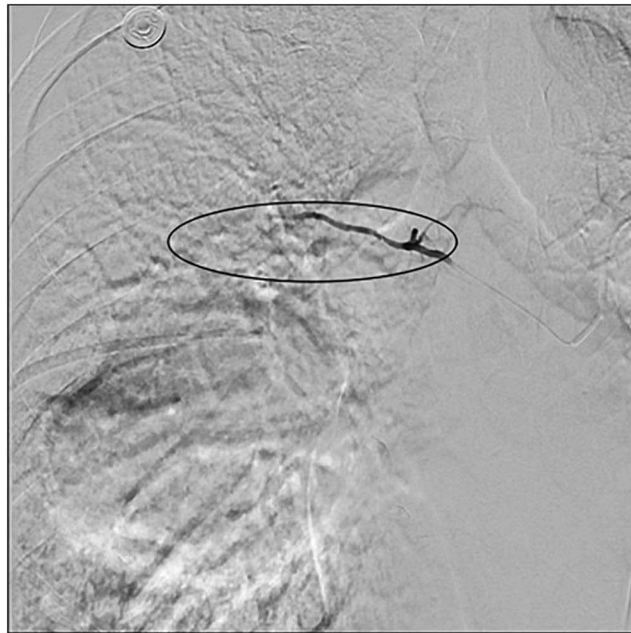

Figure 3 Tumor staining after embolization. Following the embolization procedure, there is a notable absence of staining in the pleural. Circle: Missing tumor staining.

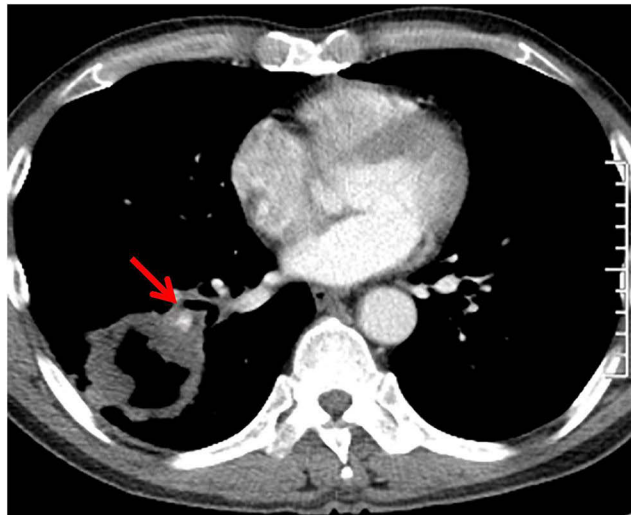


Figure 4 Enhanced chest CT July 15, 2022. Red arrow: pulmonary artery.

showed that a cavity with clear boundaries had formed in the right lower lobe lesion. The maximum cross-sectional diameter of the tumor changed to 63×56 mm and was evaluated as a partial response. After surgical evaluation, thoracoscopic right middle and lower lobectomy and lymph node dissection were performed. The operation was smoothly, with approximately 50 mL of blood loss during the operation. The pathological evaluation revealed a pathological complete response (pCR).⁶ Up to the present, the patient has received 6 rounds of postoperative chemotherapy combined with immunotherapy, and the reexamination results are stable. The latest CT examination is shown in [Figure 5](#).

Discussion

Chemoradiation has been the only standard-of-care neoadjuvant treatment for resectable lung cancer for almost 20 years. With the rapid advancement in immunological therapy, immunotherapy has received increasing attention in the field of neoadjuvant therapy. LCMC3 (NCT02927301)³ is a Phase II clinical trial that is the first to demonstrate the effectiveness

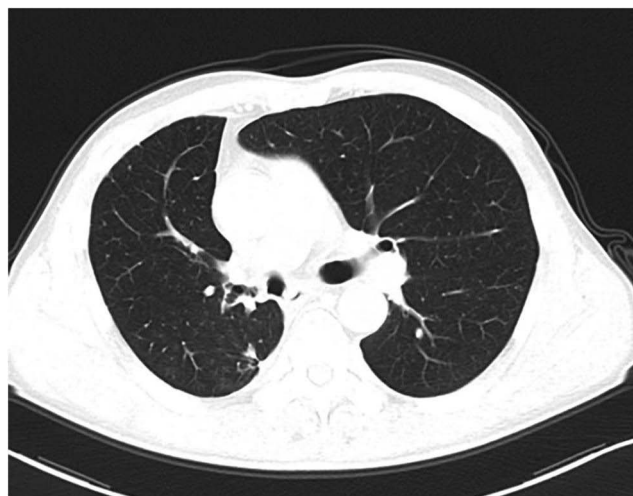

Figure 5 The latest CT examination.

of immunotherapy as a neoadjuvant treatment for NSCLC, which revealed that in patients without epidermal growth factor receptor (EGFR) or anaplastic lymphoma kinase (ALK) mutations, 21% achieved complete response, 7% achieved pCR, and 92% achieved R0 excision. At present, the total response rate (ORR) of different forms of neoadjuvant immunotherapy for lung cancer is very different: the ORR of neoadjuvant immunotherapy,⁷ dual immunotherapy and immunocombined chemotherapy⁸ is 10%, 22% and 78%, respectively. Therefore, the combination therapy can significantly prolong progression-free survival (PFS) and significantly improve the pCR rate.

Given the unique advantages of neoadjuvant immunotherapy combined with chemotherapy, it has been hypothesized that there may be synergism between neoadjuvant immunotherapy and chemotherapy. Current research suggests that chemotherapy induces more gene mutations in tumor cells and generates new epitopes, thereby enhancing the immunogenicity of tumors and improving the efficacy of immunotherapy.⁹ Chemotherapy can directly eliminate tumor cells, increase the ratio of T cells to tumor cells, reduce immunosuppressive molecules, promote dendritic cell maturation and T cell proliferation, as well as enhance the expression of major histocompatibility complex class I proteins and PD-L1 in NSCLC cells.¹⁰ The patient in this report received treatment with a combination of immunotherapy and chemotherapy. Tislelizumab was administered intravenously on the first day after BAI with chemotherapy drugs, ultimately achieving the optimum response of pCR postoperatively.

Systemic NCT reduces tumor staging and allows earlier surgical resection. BAI is an important treatment option for advanced lung cancer as it can accurately deliver chemotherapeutic drugs to tumor cells through the tumor donor artery, increase the local concentration of chemotherapeutic drugs in the tumor, enhance its killing ability, and significantly improve the short-term curative effects. DEB-BACE represents a further improvement on BAI by combining chemotherapy with embolization. The DEB-BACE effectively overcomes the physiological barriers that some intravenous chemotherapies cannot, and it demonstrates a “first-pass effect” of drugs, thereby significantly increasing the localized drug concentration in the tumor. The localized drug concentration can be doubled in BAI, and the lethality to cancer cells can be increased 10-fold.¹¹ Moreover, chemotherapeutic drugs that enter the blood circulation can be reabsorbed by the tumor tissue, exerting a secondary anticancer effect and killing the primary tumor, metastases, as well as hilar and mediastinal lymph nodes. Following DEB-BACE treatment for patients with small cell lung cancer, significant advantages were observed in terms of therapeutic efficacy, quality of life improvement, survival benefit, and safety.¹²

Hemoptysis is a serious complication in patients with advanced NSCLC and is often difficult to control with conservative treatment. BACE is considered as the preferred treatment for patients with lung cancer and massive hemoptysis. With the development of medical materials, drug eluting beads (DEB) have become an important material for embolization. DEB-BACE blocks the blood flow in tumor-supplying arteries rapidly controlling hemoptysis while the loaded chemotherapeutic drugs can kill the tumor cells. Drug-loaded microspheres directly embolize tumor-supplying

arteries to block or reduce main blood supply to tumors causing short-term ischemia and hypoxic necrosis of tumor cells while slowing down erosion of chemotherapy drugs by blood flow. This promotes long-term maintenance of high drug concentrations within tumors while reducing systemic drug concentration levels along with related adverse effects thus further improving therapeutic efficacy. At present, the drug-eluting microspheres used in clinical practice are mainly DC/LC Beads, HepaSphere, CalliSpheres, Tandem, etc. Their particle size and biological characteristics are not exactly the same, and the drug-loading mechanism includes adsorption, ion exchange, ionic bond, etc. More mature drug carriers include doxorubicin, pirarubicin, irinotecan, oxaliplatin, cisplatin, gemcitabine, etc. In clinical use of drug-eluting microspheres, appropriate drug loading should be selected in combination with lung cancer chemotherapy regimen.¹³ Studies have found that DEB-BACE is superior to BACE in ORR, disease control rate (DCR), PFS and overall survival (OS) in the treatment of advanced non-small cell lung cancer, and has good safety and efficacy.¹⁴ Our study demonstrated that DEB-BACE is safe and feasible for patients with advanced NSCLC complicated with hemoptysis and can provide a clinical practice basis for treatment of such patients. Postoperative hemoptysis was significantly relieved in our patient due to embolization of feeding bronchial arteries and control of tumor growth. We administered epirubicin to our patient because it is a broad-spectrum anticancer drug effective against breast cancer, lymphoma, lung cancer among other tumors; it also serves as a candidate drug for treating lung cancer. Importantly, epirubicin achieves higher therapeutic drug concentrations when loaded into microspheres compared to other antitumor drugs. Moreover, epirubicin's red color allows observation of bead loading degree.

In the context of neoadjuvant therapy, immunotherapy for NSCLC has made new progress. In clinical studies, immunotherapy combined with neoadjuvant chemotherapy has been found to have benefits over traditional treatment.¹⁵ In some cases, cancer vaccines are an important part of cancer immunotherapy.¹⁶ Phase III clinical studies in Chinese patients showed that immunotherapy combined with neoadjuvant chemotherapy significantly improved pCR and MPR rates and prolonged EFS and OS benefits compared with neoadjuvant chemotherapy.^{17,18} The current treatment plan typically involves two to four cycles of neoadjuvant immunotherapy, with the majority of patients successfully undergoing surgery. Only a small number of patients experience delays or cancellations in surgery due to immune-related adverse reactions. Adverse reactions to immunotherapy are also a concern, as severe treatment toxicity may lead to postponed or missed surgical opportunities.¹⁹ All patients who received immunotherapy combined with chemotherapy in the NADIM study⁸ underwent timely surgeries without early withdrawal from the study due to disease progression or toxicity. On the other hand, in the NEOSTAR study, treatment-related side effects resulted in surgical delays for 22% of patients by an average of 42 days. Some studies have reported cases where patients had to discontinue immunotherapy due to Grade-IV immune-related pneumonia and others experienced disease progression after treatment or lost their opportunity for surgery.²⁰ Therefore, careful patient selection is crucial when considering neoadjuvant immunotherapy as it may lead to surgical delays or loss of opportunities. In our case, the patient underwent surgery after just one cycle of DEB-BACE combined with immunotherapy because he strongly desired it. Re-examination on contrast-enhanced CT revealed that most of the tumor was necrotic, with minimal peripheral ring enhancement and a large cancerous necrotic cavity showing thicker pulmonary artery passing through its wall, posing a potential risk of fatal pulmonary hemorrhage (FPH). As a result, early surgery was performed.

Although DEB-BACE is a novel form of interventional therapy for lung cancer, it is important to pay attention to the incidence of complications during surgery. The first issue to consider is ectopic embolism, which can lead to complications such as spinal cord infarction²¹ and cerebral infarction.²² With the application of microcatheter super-selective bronchial artery technique, non-target blood vessels such as spinal artery and esophageal terminal branch can be effectively avoided. This also provides greater flexibility in selecting inner diameter of embolization material. In our patient group undergoing BACE using microcatheter super-selection technology at proximal end of tumor with 300–500- μ m diameter microspheres was used. The entire DEB-BACE process was conducted under close fluoroscopic observation strictly following key recommendations for drug-loaded microsphere embolization technology resulting in no occurrence of serious complications such as ectopic embolization. The primary postoperative adverse reactions included chest pain and fever, which may be attributed to tumor swelling and necrosis following embolization. Furthermore, due to the loss of nutrient arteries after DEB-BACE, rapid and severe tumor necrosis occurs, leading to the formation of large cavities

and an increased risk of FPH. Erkan et al²³ also identified tumor cavitation as the sole independent factor associated with a heightened risk of FPH.

Conclusion

Our case highlights the importance of utilizing DEB-BACE as a specialized chemotherapy delivery route in combination with immunotherapy or targeted therapy for the treatment of resectable early-stage NSCLC. This approach offers an effective means of preoperative neoadjuvant therapy. However, due to the limited number of cases treated in this manner, as well as the restricted treatment experience and some academic disagreements, further evaluation and an increase in clinical cases are necessary. Nevertheless, based on the literature review and individual clinical application, it appears that DEB-BACE combined with targeted immunotherapy can effectively downstage tumors at a rapid pace. This allows patients to undergo surgery early, which is particularly crucial for those at risk of FPH. Therefore, there is a strong indication for advocating and applying this approach clinically.

Informed Consent

This case series was approved by the Ethics Committee of Weifang No. 2 People's Hospital. Informed consent has been obtained from the patient. The patient and the hospital have agreed to release details of the case and any accompanying images.

Funding

This work was supported by 2022 Natural Science Foundation of Shandong Province, Project No. ZR2022MH209.

Disclosure

The authors declare no conflict of interest.

References

1. D'Addario G, Früh M, Reck M, et al. Metastatic non-small-cell lung cancer: ESMO clinical practice guidelines for diagnosis, treatment and follow-up. *Ann Oncol.* 2010;21(Suppl 5):v116–9. doi:10.1093/annonc/mdq189
2. Liu J, Blake SJ, Yong MC, et al. Improved efficacy of neoadjuvant compared to adjuvant immunotherapy to eradicate metastatic disease. *Cancer Discov.* 2016;6(12):1382–1399. doi:10.1158/2159-8290.CD-16-0577
3. Forde PM, Chaft JE, Smith KN, et al. Neoadjuvant PD-1 blockade in resectable lung cancer. *N Engl J Med.* 2018;378(21):1976–1986. doi:10.1056/NEJMoa1716078
4. De Scordilli M, Michelotti A, Bertoli E, De Carlo E, Del Conte A, Bearz A. Targeted therapy and immunotherapy in early-stage non-small cell lung cancer: current evidence and ongoing trials. *Int J Mol Sci.* 2022;23(13):7222. doi:10.3390/ijms23137222
5. Fu Z, Wang C, Wei W, et al. Efficacy and safety of drug-eluting beads bronchial arterial chemoembolization versus conventional bronchial arterial chemoembolization in lung cancer patients with hemoptysis. *Future Oncol.* 2022;18(25):2805–2815. doi:10.2217/fon-2021-1515
6. Travis WD, Dacic S, Wistuba I, et al. IASLC multidisciplinary recommendations for pathologic assessment of lung cancer resection specimens after neoadjuvant therapy. *J Thorac Oncol.* 2020;15(5):709–740. doi:10.1016/j.jtho.2020.01.005
7. Xu S. Progress and prospects of neoadjuvant target therapy and immunotherapy for non-small cell lung cancer. *Chin J Clin Oncol.* 2020;47:299–304.
8. Provencio M, Nadal E, Insa A, et al. Neoadjuvant chemotherapy and nivolumab in resectable non-small-cell lung cancer (NADIM): an open-label, multicentre, single-arm, Phase 2 trial. *Lancet Oncol.* 2020;21(11):1413–1422. doi:10.1016/S1470-2045(20)30453-8
9. Brown JS, Sundar R, Lopez J. Combining DNA damaging therapeutics with immunotherapy: more haste, less speed. *Br J Cancer.* 2018;118(3):312–324. doi:10.1038/bjc.2017.376
10. Parra ER, Villalobos P, Behrens C, et al. Effect of neoadjuvant chemotherapy on the immune microenvironment in non-small cell lung carcinomas as determined by multiplex immunofluorescence and image analysis approaches. *J Immunother Cancer.* 2018;6(1):48. doi:10.1186/s40425-018-0368-0
11. Kim ES, Lee JJ, He G, et al. Tissue platinum concentration and tumor response in non-small-cell lung cancer. *J Clin Oncol.* 2012;30(27):3345–3352. doi:10.1200/JCO.2011.40.8120
12. Lin H, Wang Q, Tian F, et al. Drug-eluting beads bronchial arterial chemoembolization in treating relapsed/refractory small cell lung cancer patients: results from a pilot study. *Cancer Manag Res.* 2021;13:6239–6248. doi:10.2147/CMAR.S310115
13. Bie Z, Li Y, Li B, Wang D, Li L, Li X. The efficacy of drug-eluting beads bronchial arterial chemoembolization loaded with gemcitabine for treatment of non-small cell lung cancer. *Thorac Cancer.* 2019;10(9):1770–1778. doi:10.1111/1759-7714.13139
14. Yu G, Shen Y, Chen L, Xu X, Yang J. Drug-eluting beads bronchial arterial chemoembolization vs. conventional bronchial arterial chemoembolization in the treatment of advanced non-small cell lung cancer. *Front Med.* 2023;10:1201468. doi:10.3389/fmed.2023.1201468
15. Grant C, Hagopian G, Nagasaka M. Neoadjuvant therapy in non-small cell lung cancer. *Crit. Rev Oncol Hematol.* 2023;190:104080. doi:10.1016/j.critrevonc.2023.104080

16. Kaur J, Elms J, Munn AL, Good D, Wei MQ. Immunotherapy for non-small cell lung cancer (NSCLC), as a stand-alone and in combination therapy. *Crit. Rev Oncol Hematol.* 2021;164:103417. doi:10.1016/j.critrevonc.2021.103417
17. Yue D, Wang W, Liu H, et al. VP1-2024: RATIONALE-315: event-free survival (EFS) and overall survival (OS) of neoadjuvant tislelizumab (TIS) plus chemotherapy (CT) with adjuvant TIS in resectable non-small cell lung cancer (NSCLC)[J]. *Ann Oncol.* 2024;35(3):332–333. doi:10.1016/j.annonc.2024.01.005
18. Lu S, Zhang W, Wu L, et al. Perioperative toripalimab plus chemotherapy for patients with resectable non-small cell lung cancer: the neotorch randomized clinical trial[J]. *JAMA.* 2024;331(3):201–211. doi:10.1001/jama.2023.24735
19. Yeh J, Marrone KA, Forde PM. Neoadjuvant and consolidation immuno-oncology therapy in stage III non-small cell lung cancer. *J Thorac Dis.* 2018;10(Suppl 3):S451–9. doi:10.21037/jtd.2018.01.109
20. Zhou S, Hao X, Yu D, et al. Preliminary efficacy evaluation of neoadjuvant immunotherapy combined with chemotherapy in resectable non-small cell lung cancer. *Zhongguo Fei Ai Za Zhi.* 2021;24(6):420–425. doi:10.3779/j.issn.1009-3419.2021.102.13
21. Ishikawa H, Ohbe H, Omachi N, Morita K, Yasunaga H. Spinal cord infarction after bronchial artery embolization for hemoptysis: a nationwide observational study in Japan. *Radiology.* 2021;298(3):673–679. doi:10.1148/radiol.2021202500
22. Luo W, Wei MG, Wei HL, Li YL. Cerebral infarction after drug-eluting bead bronchial arterial chemoembolization due to the mechanical force-mediated opening of an errant passage. *Chin Med J.* 2020;134(8):989–990. doi:10.1097/CM9.0000000000001284
23. Topkan E, Selek U, Ozdemir Y, et al. Risk factors for fatal pulmonary hemorrhage following concurrent chemoradiotherapy in stage 3B/C squamous-cell lung carcinoma patients. *J Oncol.* 2018;2018:4518935. doi:10.1155/2018/4518935

International Medical Case Reports Journal

Dovepress

Publish your work in this journal

The International Medical Case Reports Journal is an international, peer-reviewed open-access journal publishing original case reports from all medical specialties. Previously unpublished medical posters are also accepted relating to any area of clinical or preclinical science. Submissions should not normally exceed 2,000 words or 4 published pages including figures, diagrams and references. The manuscript management system is completely online and includes a very quick and fair peer-review system, which is all easy to use. Visit <http://www.dovepress.com/testimonials.php> to read real quotes from published authors.

Submit your manuscript here: <https://www.dovepress.com/international-medical-case-reports-journal-journal>