

Access this article online
Quick Response Code:

Website: www.jehp.net
DOI: 10.4103/jehp.jehp_33_17

Long-lasting chondromyxoid fibroma of the zygoma: A rare case report and review of literature

Mohammad Javad Ashraf¹, Negar Azarpira², Navid Omidifar^{3,4}, Bijan Khademi⁵

Abstract:

Chondromyxoid fibroma (CMF) is a benign tumor which usually occurs in skeletal long bones. Its presence in zygoma is extremely rare. The patient was a 47-year-old female, with chief complaint of painful swelling in the left side of zygoma since 1 month ago after a long-lasting painless swelling for about 15 years. Computed tomography scan showed an osteolytic lesion, in the body of left zygomatic bone with lobulated and well-demarcated margins. During surgery, the mass was completely excised and the histological feature of the tumor was in favor of CMF. CMF is benign tumor and complete resection is the treatment of choice.

Keywords:

Chondromyxoid fibroma, long lasting, treatment, zygoma

Introduction

Chondromyxoid fibroma (CMF) tumor is a benign rare bone tumor. The prevalence of this tumor estimates to be 1% of all primary bone tumors and mostly occurs in the long bones.^[1] It mostly grows in males aged between 10 and 30 years. The most common site is around the knee joint. Head and neck involvement is unusual and skull is extremely rare.^[1-3] It usually manifests as a local swelling that eventually results in pathological fractures. CMF has similarity with other malignant bone tumors such as chondrosarcoma; therefore, accurate diagnosis with careful correlation of clinical, radiological, and pathological findings is very important.^[1,4,5]

Case Report

A 47-year-old female was referred to the Department of Otolaryngology, Oral and Maxillofacial Surgery, with a chief complaint of painful swelling in the left

side of face since 1 month ago. The patient complained about an old 15-year-old mass with slow growth during recent 6 months. She did not mention any former sampling or manipulation of the lesion. In physical examination, a painful, firm, and nonmobile mass in the left zygomatic bone was detected.

On the X-ray, there was a 3 cm × 2 cm mass with destructive picture on the left side of zygomatic bone. Computed tomography (CT) scan showed an osteolytic lesion in the zygomatic bone with lobulated and well-demarcated margins [Figures 1 and 2]. Expansion with partial destruction of cortical bone was also noticed.

During surgery, partial resection of zygomatic bone with safe margins was done. Surgical defect of zygomatic arch was reconstructed with a calvarial bone graft fixed with microplates and screws. The histologic examination of the excised tissue showed lobules of variable sizes with hypercellularity at the periphery and low cellular myxoid stroma at the center of

How to cite this article: Ashraf MJ, Azarpira N, Omidifar N, Khademi B. Long-lasting chondromyxoid fibroma of the zygoma: A rare case report and review of literature. J Edu Health Promot 2017;6:78.

Departments
of ¹Pathology,
⁵Otolaryngology and
³Molecular Clinical
Microbiology Subdivision,
Clinical Pathology Division,
Department of Pathology,
School of Medicine, Shiraz
University of Medical
Sciences, ²Transplant
Research Center, Shiraz
University of Medical
Sciences, ⁴Clinical
Education Research
Centre, Shiraz University
of Medical Sciences,
Shiraz, Iran

Address for correspondence:

Dr. Navid Omidifar,
Molecular Clinical
Microbiology Subdivision,
Clinical Pathology
Division, Department
of Pathology, School
of Medicine, and
Clinical Education
Research Center, Shiraz
University of Medical
Sciences, Shiraz, Iran.
E-mail: omidifar@
gmail.com

Received: 16-03-2017

Accepted: 31-03-2017

This is an open access article distributed under the terms of the Creative Commons Attribution-NonCommercial-ShareAlike 3.0 License, which allows others to remix, tweak, and build upon the work non-commercially, as long as the author is credited and the new creations are licensed under the identical terms.

For reprints contact: reprints@medknow.com

the lobules [Figure 3]. Stellate-shaped cells in a myxoid background as well as osteoclastic giant cells were also seen. Mitosis and necrosis were absent. Chicken wire and granular calcifications were easily identified [Figure 4]. These features were in favor of CMF. The postoperative period was uneventful. There was no recurrence during the 2-year follow-up period in both clinical and radiological examinations. Reconstructed part has worked well.

Discussion

CMF is a rare benign bone tumor arising from cartilage-forming mesenchymal tissue and accounts for <1% of all bone tumors.^[1,5] Jaffe and Lichtenstein described this entity for the first time in 1948.^[6] It generally affects long bones of lower extremity. CMF occurs in all age groups but mostly presents during the second and third decades. It is predominantly found

in the metaphyses of long bones and less frequently in flat bones and ribs.^[7,8] The occurrence of this tumor in the skull is extremely rare. In the jaws, the neoplasm typically occurs in the mandible.^[9]

Radiologic findings of CMF sometimes are characteristic. In plain radiographs, the lesions are radiolucent with well-defined margins.^[10] The CT scan shows osteolytic lesions with a sclerotic margin.^[11]

In magnetic resonance imaging, the tumor is usually hypointense on T1-weighted and hyperintense in T2-weighted images.^[3,7,12] Surgical treatment varied from conservative curettage to complete resection. However, the gold standard treatment is “*en bloc*” resection.^[7,8] The reported recurrence rate is 3%–26% which may be due to incomplete excision.^[1]

In differential diagnosis, enchondroma, chondroblastoma, and chondrosarcoma should be considered.^[7,8] Chondrosarcoma produces islands of malignant hyaline cartilage and mitoses are not difficult to find. In chondroblastoma, the presence of “chondroblasts,” large numbers of osteoclast-like giant cells, and “chicken wire” calcification are easily identified. Histologically, CMF consists of lobulated areas of myxomatous tissue

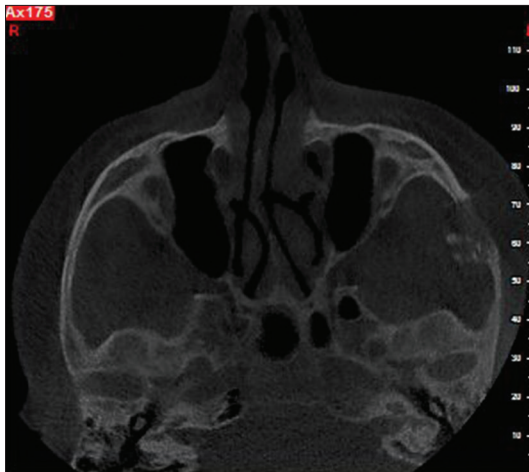

Figure 1: Computed tomography scan revealed a 3 × 2_{Cm} lesion in the zygomatic bone

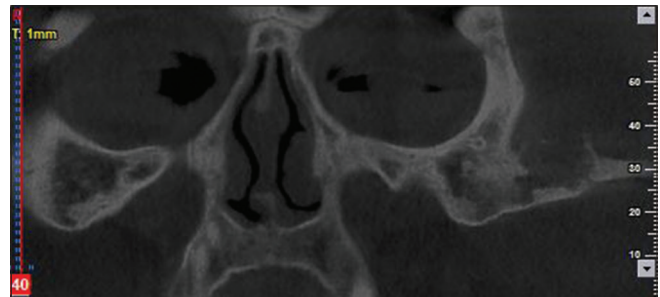


Figure 2: Computed tomography scan revealed osteolytic characteristic of the mass in the zygomatic bone that brought malignant process in the differentials

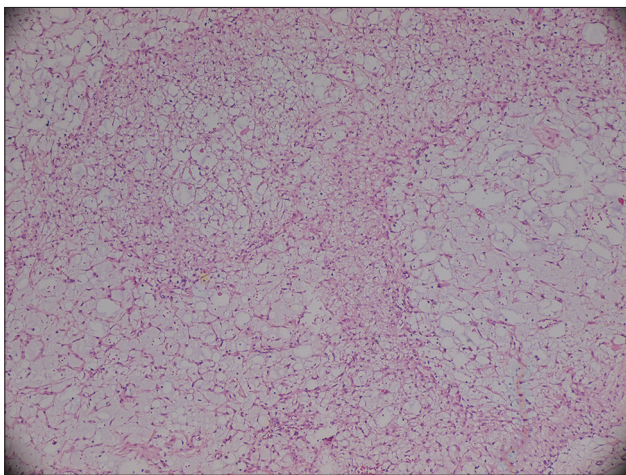


Figure 3: Histopathology of the lesion shows lobular growth pattern with hypercellularity at periphery and low cellular myxoid stroma at center of lobules. (H and E, ×400)

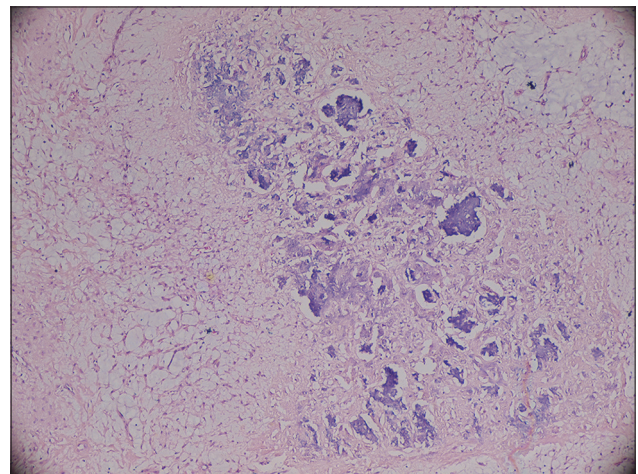


Figure 4: Some microscopic fields of slide show areas of calcification beside low cellular myxoid stroma (H and E, ×400)

separated by fibrocellular bands with little tendency for chondroid formation.^[7,8,10]

Radiotherapy is not routinely recommended because of the potential for sarcomatous transformation.^[10] Radiotherapy is only applicable in tumors that complete resection is impossible like base skull or adjacent to vital organs.^[3,8] In our case, the interesting prolongation of the mass without malignant transformation was noticeable. The mass was completely excised and with no adjuvant radiotherapy.

Conclusion

CMF is a benign tumor and complete resection is the best approach for the treatment. This case showed a benign nature of such tumor despite long duration and absence of any treatment.

Financial support and sponsorship

The study was supported by Shiraz University of Medical Sciences, Shiraz, Iran.

Conflicts of interest

There are no conflicts of interest.

References

1. Pintor F, Bahamondes C, Campos O, Zivov A. Chondromyxoid fibroma of zygoma in an elderly patient: A rare presentation. *Ann Maxillofac Surg* 2015;5:244-8.
2. Baujat B, Attal P, Racy E, Quillard J, Parker F, Evannou A, *et al.* Chondromyxoid fibroma of the nasal bone with extension into the frontal and ethmoidal sinuses: Report of one case and a review of the literature. *Am J Otolaryngol* 2001;22:150-3.
3. Crocker M, Corns R, Bodi I, Zrinzo A, Gleeson M, Thomas N. Chondromyxoid fibroma of the skull base invading the occipitocervical junction: Report of a unique case and discussion. *Skull Base* 2010;20:101-4.
4. Choi YS, Kim BS, Joo JE, Park YK, Lee SH, Song BY. A rare case of epiphyseal chondromyxoid fibroma of the proximal tibia. *Korean J Radiol* 2011;12:761-4.
5. Feuvret L, Noël G, Calugaru V, Terrier P, Habrand JL. Chondromyxoid fibroma of the skull base: Differential diagnosis and radiotherapy: Two case reports and a review of the literature. *Acta Oncol* 2005;44:545-53.
6. Jaffe HL, Lichtenstein L. Chondromyxoid fibroma of bone; a distinctive benign tumor likely to be mistaken especially for chondrosarcoma. *Arch Pathol (Chic)* 1948;45:541-51.
7. Wu CT, Inwards CY, O'Laughlin S, Rock MG, Beabout JW, Unni KK. Chondromyxoid fibroma of bone: A clinicopathologic review of 278 cases. *Hum Pathol* 1998;29:438-46.
8. Zillmer DA, Dorfman HD. Chondromyxoid fibroma of bone: Thirty-six cases with clinicopathologic correlation. *Hum Pathol* 1989;20:952-64.
9. Sudhakara M, Bavle RM, Srinath N, Paremala K. Chondromyxoid fibroma of zygoma: A rare case report. *J Oral Maxillofac Pathol* 2014;18:93-6.
10. Desai SS, Jambhekar NA, Samanthray S, Merchant NH, Puri A, Agarwal M. Chondromyxoid fibromas: A study of 10 cases. *J Surg Oncol* 2005;89:28-31.
11. Karkuzhali P, Chithralekha S, Muthuvel E, Daniel RB. Chondromyxoid fibroma of the parietal bone. *Neuropathology* 2005;25:84-8.
12. Dürr HR, Lienemann A, Nerlich A, Stumpfenhausen B, Refior HJ. Chondromyxoid fibroma of bone. *Arch Orthop Trauma Surg* 2000;120:42-7.