

Submitted: 05/12/2014

Accepted: 21/02/2015

Published: 19/03/2015

Expression of Bcl-2 in canine osteosarcoma

F. Piro and L. Leonardi*

Dipartimento di Medicina Veterinaria – Università degli Studi di Perugia, Via San Costanzo, 4 – 06124 Perugia, Italy

Abstract

Osteosarcoma (OS) is the most common primary malignancy of bone. It is responsible for 80-85% of the primary bone tumors affecting dogs and it is characterized by aggressive and invasive behavior, with a high metastatic potential. Several studies on cancer and related tumorigenesis, show an involvement of the mechanisms of programmed cell death and cell survival. Many signals seem to be involved in the related mechanism of autophagy and in particular, our interest is focused on the expression of a family of Bcl-2 that seems to be involved either in the control of biomolecular mechanisms like autophagy and apoptosis. In this study we investigated the expression of Bcl-2 in different cases of spontaneous canine osteosarcoma and the related preliminary results are described. We found Bcl-2 activity was increased in OS tissue compared to normal bone tissue. These results suggested that Bcl-2 activity may play an important role in the formation of OS and as a diagnostic for neoplastic activity. However, further research is needed to confirm the role of Bcl-2 activity in OS in canines.

Keywords: Autophagy, Bcl-2, Dog, Osteosarcoma.

Introduction

Osteosarcoma (OS) is the most common primary malignancy of the skeleton of dogs and humans. OS arises most commonly in the metaphyseal region of long bones, within the medullary cavity, and penetrates the cortex of the bone to involve the surrounding soft tissues (Broadhead *et al.*, 2011).

In dogs OS represents 80 to 85% of bone tumors, most frequently affecting male dogs of medium to large breeds between 2-years and 12-years of age (Leonardi, 2003 and Leonardi *et al.*, 2014). In dogs 24% of OS typically affects the axial skeleton, while the involvement of the appendicular skeleton is rather high (> 70% of cases) (Liu *et al.*, 1977). Here we investigated immunohistochemically the expression of Bcl-2, an important membrane protein involved in apoptotic/autophagic mechanisms and expressed in several premalignant and malignant lesions and which its role is still not clarified in spontaneous osteosarcoma (Leoncini *et al.*, 1993). Apoptosis is the so-called programmed cell death that occurs when the damaged cell is no longer able to activate the repair systems (Stergiou and Hengartner, 2004). This mechanism can be triggered by external stimuli such as chemical or physical agents, or endogenous stimuli such as cell turnover or remodelling during cellular development.

In tumor formation, apoptosis is usually inhibited and the cells involved undergo uncontrolled proliferation (Robert *et al.*, 2012). Autophagy is an evolutionarily conserved process that involves cellular self-eating (Mizushima *et al.*, 2008). This mechanism of stress

adaptation and degrading acts of cytoplasmic contents, it is in fact physiologically activated under conditions of nutrient deficiency. The process is based on the formation of a vesicles which takes the name of autophagosome, capable of sequestering damaged and degraded cytoplasmic organelles (Brecht *et al.*, 2009).

The tumor suppressor function operated by autophagy is mediated by scavenging of damaged oxidative organelles, thus preventing accumulation of toxic oxygen radicals that would cause the genome instability. However, in some cases autophagy can also promote the survival of cancer cells once tumors have developed. This is attributed to the ability of autophagy to promote cell survival under conditions of poor nutrient supply, as often faced by solid tumors and metastasizing cancer cells (Brecht *et al.*, 2009).

Research works conducted on the study of the mechanism of autophagy in tumors has led to identifying the involvement of a family of proteins that are also involved in apoptosis mechanisms. This family of protein is called Bcl-2 and is localized on the outer mitochondrial membrane, already involved in the apoptotic mechanism (Levine *et al.*, 2008). They are part of a family of more than 15 different proteins that are grouped into two categories according to which play a role in pro-apoptotic or anti-apoptotic cells. The same differentiation was found in the autophagic mechanism. In fact it has been demonstrated that the anti-apoptotic proteins Bcl-2 and Bcl-X₁ also have the ability to inhibit autophagy through binding to a specific domain, which takes the name of BH3, present on a protein known with the

*Corresponding Author: Leonardo Leonardi. Dipartimento di Medicina Veterinaria – Università degli Studi di Perugia, Via San Costanzo, 4 – 06124 Perugia, Italy. Tel.: +39.075.5857663. Email: leonardo.leonardi@unipg.it

name of Beclin1 involved in the regulation of autophagy (Robert *et al.*, 2012).

In humans it was identified that autophagy had an important role in the development of bone cancer (Huang *et al.*, 2012) and might be interesting to investigate whether this mechanism, involved in the process that affects the human being, is equally involved in OS in canines.

The aim of this preliminary study was to evaluate the immunohistochemical expression of Bcl-2 in spontaneous canine osteosarcoma being known its role in cell proliferation and tumorigenesis.

Materials and Methods

Ten cases of spontaneous high grade canine osteoblastic non metastatic osteosarcoma have been used to investigate the immunohistochemical expression of Bcl-2 through the use of specific antibody. The biological samples was represented by tumors resection pieces from patients hospitalized in different Clinics in Italy.

Tumor's samples were fixed in 10% neutral buffered formalin and subsequently were subjected to decalcification for bone tissues composed by an aqueous solution of formic acid, hydrochloric and sulphuric acid in different parts, left at room temperature for a variable time in relation to the degree of daily decalcification. Samples were then processed using common histopathological techniques and stained with Hematoxylin and Eosin (H&E) stains were performed on 3-5 μ sections. The histopathological diagnoses were done in conformity with criterions established in 1994 by WHO classification of bone tumors (Slayter *et al.*, 1994) (Table 1).

Table 1. Clinical data of samples used for IHC investigation.

Samples	Breed	Sex	Age	Site
Sample 1	-	Female		Femur SX
Sample 2	-	Male	13 yy	Hock
Sample 3	Half-breed	Male	10 yy	Humerus DX
Sample 4	Pittbull	Male	12 yy	Vertebrae T3-L3
Sample 5	Miniature Schnauzer	Female	10 yy	Sternum
Sample 6	Golden Retriever	Male	7 yy	Humerus
Sample 7	Half-breed	Male	12 yy	Radius DX
Sample 8	Lagotto	Male	2 yy	Humerus DX
Sample 9	Bull Mastiff	Male	10 yy	Carpus
Sample 10	Terranova	Female	7 yy	Radius

Immunohistochemistry (IHC) was performed using the Avidin Biotin Complex (ABCL-2) method (Abcam kit). Paraffin was removed with xylene and

slides were dehydrated in sequential diluted ethanol and then rinsed in distilled water. To inhibit endogenous peroxidase activity the tissue sections were treated with 3% hydrogen peroxide in tris phosphate-buffered saline (PBS). Non-specific reactivity was blocked with the use of normal goat serum for 30 minutes. Investigations was performed on serial sections of 3-5 μ m using monoclonal antibody mouse antihuman Bcl-2 (clone 124, dilution 1:100, Dako). Samples of normal canine tonsil were used as a positive control for Bcl-2.

Results

Histologically, all tumors were highly cellular with polyhedral cells with large nuclei and hyperchromatic chromatin, frequent mitoses and prominent nucleoli associated with production of different amount of osteoid. Bcl-2 immunostaining showed homogeneous increasing expression in all cases investigated, compared with normal bone in all samples investigated (Fig.1).

The percentage of immunohistochemically positive cells in all cases investigated ranged from 80% to 95%. Fluorescence was always in the cytoplasm, consistent with normal mitochondrial membrane activity.

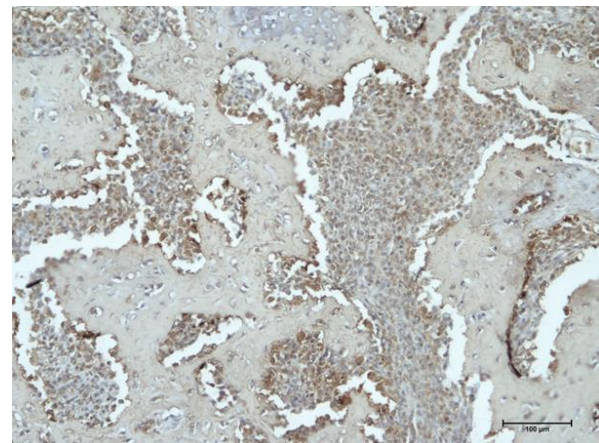


Fig. 1. Bcl-2 expression in spontaneous canine osteoblastic osteosarcoma. Bcl-2 is expressed with prevalent cytoplasmic immunoreactivity by tumoral osteoblastic cells that appears in agglomerated well packed group of cells throughout the lamellar bone structures negative for Bcl-2 IHC as well as the upper isle of cartilage. IHC magnification x20.

Discussion

Bcl-2 is a protein belonging to a family that regulates different mechanisms of cell biology like autophagy and apoptosis (Yip and Reed, 2008). Bcl-2 is an anti-apoptotic protein that may protect cells from a variety of apoptotic stimuli, including cytotoxic drugs, irradiation, heat or growth factor withdrawal (Creagh *et al.*, 2000). The over expression of Bcl-2 has been described in different types of human tumors,

including breast, colon, ovary and prostate cancers (Amundson *et al.*, 2000).

Although Bcl-2 confers resistance to malignant cells, it does not always correlate with poor prognosis (Hassan *et al.*, 2014). Our results showed an over expression of Bcl-2 in all tumoral osteoblastic cells from all primitive canine osteosarcoma investigated.

This positive expression suggest that is possible to speculate the inhibition of the mechanism of programmed cell death in according with the neoplastic event. The results obtained during this preliminary study may suggest that the assessment of the degree of expression of Bcl-2 may play an important role in diagnosing neoplastic event but the role of Bcl-2 as a prognostic marker have to be still investigate.

The over expression of Bcl-2 protein in osteosarcoma samples suggests that also alterations of mechanisms of autophagy/apoptosis may have a role in the bone tumor formation, and suggest too that the Bcl-2 protein during the neoplastic process may loss natural action of anti-apoptotic protein that consequently contribute to stimulate the uncontrolled proliferation of tumor cells.

These results suggest that Bcl-2 protein could work first as anti-apoptotic factor that may prepossess proliferative index activity of osteosarcoma and therefore its aggressiveness. We believe that evaluation of Bcl-2 expression may be used as a diagnostic co-marker but its role as a prognostic marker needs to be further investigate. In conclusion this preliminary study reveals that osteoblastic osteosarcoma provide evidence for Bcl-2 expression that suggesting an involvement of this protein in development of this tumor.

Acknowledgments

The authors gratefully acknowledge support from the “Centro Funzionale di Patologia Veterinaria per il Registro dei Tumori Animali della Regione Umbria” and to Dr. Emilia Del Rossi, from Department of Veterinary Pathology in Perugia – Italy, and to Ms. Jennifer A. Safko and Ms. Chaterine Teresa Malehorn from Athens - Georgia (USA) for their help.

Conflict of interest

The authors declares that there is no conflict of interest.

References

Amundson, S.A., Myers, T.G., Scudiero, D., Kitada, S., Reed, J.C. and Fornace, A.J. 2000. An informatics approach identifying markers of chemosensitivity in human cancer cell lines. *Cancer Res.* 60(21), 6101-6110.
Brech, A., Ahlquist, T., Lothe, R.A. and Stenmark, H. 2009. Autophagy in tumor suppression and promotion. *Mol. Oncol.* 3, 366-375.

Broadhead, M.L., Clark, J.C.M., Myers, D.E., Dass, C.R. and Choong, P.F.M. 2011. The Molecular Pathogenesis of Osteosarcoma: A Review. *Sarcoma*, vol. 2011, Article ID 959248, 12 pages. doi:10.1155/2011/959248
Creagh, E.M., Sheehan, D. and Cotter, T.G. 2000. Heat shock proteins – modulators of apoptosis in tumour cells. *Leukemia* 14, 1161-1173.
Hassan, M., Watari, H., AbuAlmaaty, A., Ohba, Y. and Sakuragi, N. 2014. Apoptosis and Molecular Targeting Therapy in Cancer. *Biomed Res. Int.* 150845. doi: 10.1155/2014/150845.
Huang, J., Liu, K., Yu, Y., Xie, M., Kang, R., Vernon, P., Cao, L., Tang, D. and Ni, J. 2012. Targeting HMGB1-mediated autophagy as a novel therapeutic strategy for osteosarcoma. *Autophagy* 8(2), 275-277.
Leonardi, L. 2003. L'Osteosarcoma nel cane, aspetti anatomo-istopatologici. *Obiettivi & Documenti Veterinari*, XXIV, 4, 45-52.
Leonardi, L., Lepri, L., Nannarone, S., Olivieri, O. and Mechelli, L. 2014. Fibroblastic osteosarcoma in a lion (*Panthera leo*). *Open Vet. J.* 4(1), 1-3.
Leoncini, L., Del Vecchio, M.T., Megha, T., Barbini, P., Galieni, P., Pileri, S., Sabatini, E., Gherlinzoni, F., Tosi, P., Kraft, R. and Cottier, H. 1993. Correlations Between Apoptotic and Proliferative Indices in Malignant Non-Hodgkin's Lymphomas. *Am. J. Pathol.* 142(3), 755-763.
Levine, B., Sinha, S. and Kroemer, G. 2008. Bcl-2 family members: dual regulators of apoptosis and autophagy. *Autophagy* 4, 600-606.
Liu, S.K., Dorfman, H.D., Hurvitz, A.I. and Patnaik, A.K. 1977. Primary and secondary bone tumors in the dog. *J. Small Anim. Pract.* 18(4), 313-326.
Mizushima, N., Levine, B., Cuervo, A.M. and Klionsky, D.J. 2008. Autophagy fights disease through cellular self-digestion. *Nature* 451, 1069-1075.
Robert, G., Gastaldi, C., Puissant, A., Hamouda, A., Jacquet, A., Dufies, M., Belhacene, N., Colosetti, P., Reed, J.C., Auberger, P. and Luciano, F. 2012. The anti-apoptotic Bcl-B protein inhibits BECN1-dependent autophagic cell death. *Autophagy* 8(4), 637-649.
Slyter, M.V., Boosinger, T.R., Pool, R.R., Dämmrich, K., Midsorp, W. and Larsen, S. 1994. *Histological Classification of bone and joint tumors of domestic animals, Second Series, Vol. 1.* AFIP, ARP and WHO Collaborating Center for Comparative Oncology.
Stergiou, L. and Hengartner, M.O. 2004. Death and more: DNA damage response pathways in the nematode *C. elegans*. *Cell Death Differ.* 11, 21-28.
Yip, K.W. and Reed, J.C. 2008. Bcl-2 family proteins and Cancer. *Oncogene* 27, 6398-6406.