

Case Report

Visual Loss from Choroidal Melanoma Mimicking Neurological Syndromes

Karim Hammamji^{a, c} Ehud Reich^a Amit Arora^a Victoria M.L. Cohen^a
Mandeep S. Sagoo^{a, b}

^aOcular Oncology Service, Moorfields Eye Hospital and St. Bartholomew's Hospital, London, UK; ^bUCL Institute of Ophthalmology, London, UK; ^cUniversity of Montreal Health Center, Montreal, QC, Canada

Keywords

Melanoma · Choroid · Masquerade

Abstract

Melanoma of the eye is rare, but can mimic a range of disorders. This report highlights 2 cases of choroidal melanoma with vision loss mimicking neurological diagnoses. The first patient is a 41-year-old white male with a known history of multiple sclerosis and a previous episode of optic neuritis in the right eye, who presented with a 6-month history of decreased vision in the same eye, and occasional photopsiae. He was treated with 2 courses of oral steroids for presumed recurrent optic neuritis. After a temporary improvement in his symptoms, his vision worsened, following which he had a head MRI, which revealed a solid intraocular mass. He was subsequently diagnosed with a choroidal melanoma for which he was treated successfully with ruthenium-106 plaque brachytherapy. The second patient is a 57-year-old female, who presented with a progressive cerebellar syndrome under investigation by the neurology service, as well as decreased vision in the right eye. Her visual acuity gradually deteriorated and her neurological assessment, which included a PET-CT, revealed uptake in the right eye. The diagnosis of a choroidal melanoma was made, and following conservative treatment with proton beam radiotherapy, she had an enucleation of the eye. Intraocular tumours can masquerade as many different entities. Unexplained unilateral visual loss, espe-

cially if it is atypical for a neurological syndrome, should prompt dilated fundoscopy and referral to an ophthalmologist.

© 2017 The Author(s)
Published by S. Karger AG, Basel

Introduction

Melanoma of the eye is rare, but can mimic a range of disorders. This report highlights 2 cases of choroidal melanoma with vision loss mimicking neurological diagnoses.

Case Reports

We report a case series of 2 patients with neurological history and intraocular tumours.

A 41-year-old white male with a known history of multiple sclerosis and right optic neuritis presented with a 6-month history of decreased vision in the same eye, with occasional photopsiae. He was evaluated by a neurologist, who treated him with 2 courses of oral steroids for presumed recurrent optic neuritis. After a slight temporary improvement, his vision worsened, following which a head MRI revealed a solid intraocular mass (Fig. 1a, b), and the patient was referred to our department.

On examination, his visual acuity was 6/24 in the right eye and 6/6 in the left eye. Anterior segment examination, intraocular pressures, and dilated left fundoscopy were normal. The right fundus showed a pigmented, elevated lesion temporal to the fovea (Fig. 1c, d). There was local subretinal fluid and an inferior exudative retinal detachment, as well as lipofuscin on the lesion. B-scan ultrasound showed a dome-shaped lesion with low internal reflectivity, in which the elevation was 5.7 mm and the base 12.5 mm (Fig. 1e). The diagnosis was compatible with a primary choroidal malignant melanoma, which was treated successfully with ruthenium-106 plaque brachytherapy.

The second patient, a 57-year-old Asian female, presented to her neurologist with a progressive cerebellar syndrome and decreased vision in the right eye. Initial examination elsewhere revealed a visual acuity of 6/9 and a fundus appearance thought to be a retinal pigment epithelial detachment. Over the course of a year, her visual acuity gradually deteriorated to counting fingers and her neurological assessment, which included a PET-CT, revealed uptake in the right eye, prompting referral to our service.

The only ophthalmic abnormality was a 14 × 8 mm pigmented choroidal mass, abutting the optic nerve from 6 to 12 o'clock (Fig. 1f) in the right eye. Subretinal fluid was present. Ultrasound scan showed a bilobed lesion of medium-to-low echogenicity, measuring 3.4 mm in elevation (Fig. 1g). Again the diagnosis was primary malignant choroidal melanoma. Conservative treatment with proton beam radiation was attempted, but 6 months later she underwent enucleation of the eye. Histopathology confirmed a primary choroidal melanoma.

Discussion

Although rare, choroidal melanoma is the most common primary intraocular malignant tumour in adults (incidence: 6 cases per million population [1]). Symptoms include blurred vision and photopsiae, depending on the size and location of the tumour, but can be asymptomatic. The Collaborative Ocular Melanoma Study (COMS) showed a 5-year tumour-related mortality rate of 26–28% in large tumours, 9–11% in medium size tumours, and 1% in small

size tumours [2–4]. Common sites of metastases include liver (90%), lung (24%), and bone (16%) [5].

Diagnosis of choroidal melanomas is usually clinical, with fundoscopy and ancillary tests, including B-scan ultrasonography and in some cases fluorescein angiography. Management options include charged particle irradiation, plaque brachytherapy, local resection, enucleation, laser treatment, or, rarely, observation. Choice of treatment depends on multiple factors including tumour size, visual acuity of the affected eye and contralateral eye, age and general health of the patient, and the presence of metastases [6].

Choroidal melanoma can masquerade other entities, such as intraocular haemorrhage, inflammatory granulomas, scleritis, and others [7]. In the 2 cases reported herein, there was an assumption that the visual symptoms were related to previous neurological diagnosis, particularly as undilated fundoscopy can be challenging.

Conclusion

Intraocular tumours can masquerade as many different entities. Unexplained unilateral visual loss, especially if it is atypical for a neurological syndrome, should prompt dilated fundoscopy and referral to an ophthalmologist.

Statement of Ethics

The patients in this report have given their informed consent, and the study has been approved by the ethics review board.

Disclosure Statement

There are no competing interests. This research received no specific grant from any funding agency in the public, commercial, or non-profit sectors.

Author Contributions

K. Hammamji and E. Reich: data acquisition, analysis and interpretation of data, drafting the article, and critical vision. A. Arora, V.M.L. Cohen, and M.S. Sagoo: conception and design, drafting the article, critical revision for intellectual content, and final approval.

References

- 1 Seddon JM, Young TA: Epidemiology of uveal melanoma; in Ryan SJ, Hinton DR, Schachat AP (eds): *Retina*, ed 4. St Louis, Elsevier Mosby, 2006, pp 692–697.
- 2 The Collaborative Ocular Melanoma Study (COMS) randomized trial of pre-enucleation radiation of large choroidal melanoma. II. Initial mortality findings: COMS report No. 10. *Am J Ophthalmol* 1998;125:779–796.
- 3 The Collaborative Ocular Melanoma Study (COMS) randomized trial of pre-enucleation radiation of large choroidal melanoma. III. Local complication and observation following enucleation: COMS report No. 11. *Am J Ophthalmol* 1998;126:362–371.

- 4 Wilson JKV, Albert DM, Diener-West M, et al; Collaborative Ocular Melanoma Study Group: Assessment of metastatic disease status at death in 435 patients with large choroidal melanoma in the Collaborative Ocular Melanoma Study (COMS): COMS report No. 15. *Arch Ophthalmol* 2001;119:670–676.
- 5 Diener-West M, Reynolds SM, Agugliaro DJ, et al; Collaborative Ocular Melanoma Study Group: Screening for metastasis from choroidal melanoma: the Collaborative Ocular Melanoma Study Group Report 23. *J Clin Oncol* 2004;22:2438–2444.
- 6 Shields CL, Shields JA: Recent developments in the management of choroidal melanoma. *Curr Opin Ophthalmol* 2004;15:244–251.
- 7 Yap EY, Robertson DM, Buettner H: Scleritis as an initial manifestation of choroidal malignant melanoma. *Ophthalmology* 1992;99:1693–1697.

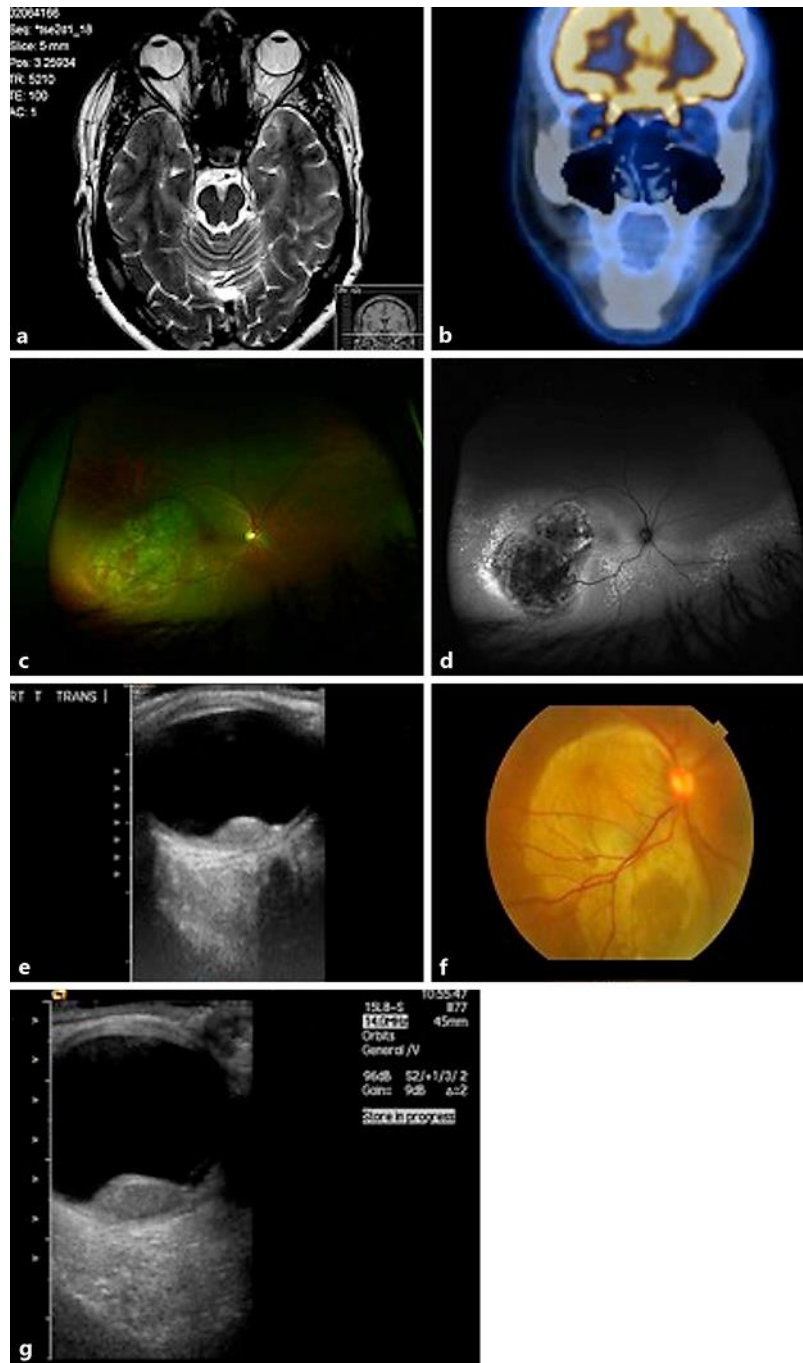


Fig. 1. **a** Head MRI showing a solid, intraocular lesion in the right eye. **b** PET-CT showing uptake of the intraocular lesion in the right eye. **c** Colour fundus photograph of lightly pigmented, elevated choroidal lesion in the right eye. **d** Red-free fundus photograph of choroidal lesion in the right eye. **e** B-scan ultrasonography showing a hypoechoic lesion, measuring 3.4 mm in elevation. **f** Colour fundus photograph of a large, slightly pigmented choroidal lesion in the right eye. **g** B-scan ultrasonography showing a hypoechoic lesion, with an elevation of 5.7 mm.