

Cutaneous metastatic esophageal adenocarcinoma diagnosed via inpatient teledermatology



Hasan Khosravi, MD,^a John Moesch, DO,^b and Joseph C. English III, MD^{a,c}
Pittsburgh and Wexford, Pennsylvania

Key words: carcinoma erysipeloides; cutaneous metastatic esophageal adenocarcinoma; inpatient teledermatology.

INTRODUCTION

The use of inpatient teledermatology has been shown to improve inpatient outcomes and has demonstrated high reliability for the triage of inpatient consultations.¹ Furthermore, by increasing access to inpatient dermatologic care at rural and urban hospitals across Western Pennsylvania, our teledermatology (e-dermatology) service has encountered and consulted on rare dermatoses. One such entity is cutaneous metastatic esophageal adenocarcinoma, accounting for 1% of skin metastases and typically presenting as pink and eroded papulonodules on the head and neck.² Herein, we report a case of cutaneous metastatic esophageal adenocarcinoma presenting as carcinoma erysipeloides with erythematous and edematous plaques. The accompanying consultation was performed via our e-dermatology service.

CASE REPORT

An 89-year-old man with a history of atrial fibrillation, gastroesophageal reflux disease, stroke secondary to malignancy and atrial fibrillation, small bowel obstruction, and T3N2 metastatic esophageal adenocarcinoma (AJCC staging system) presented to the emergency department with weakness, left axillary lymphadenopathy, shortness of breath, and pruritic erythematous and edematous papules coalescing into plaques (Fig 1) on the left side of the chest. On review of systems, the patient denied fever,

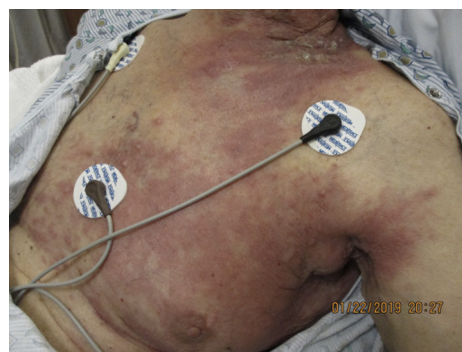

Fig 1. Erythematous and edematous papules coalescing into plaques on the left chest.

dysphagia, chills, or unintentional weight loss. Notably, the patient's esophageal adenocarcinoma was diagnosed in 2016 as HER2-negative with subsequent treatment via minimally invasive esophagectomy. Eighteen months following the procedure, the patient declined adjuvant treatment; however, he developed left supraclavicular and axillary lymphadenopathy with a subsequent left posterolateral side of the neck dissection showing 11/20 positive lymph nodes without extranodal extension. Four months later and 9 months prior to presentation, the patient's computed tomography of the chest with contrast showed enlarged lymph nodes of the left pectoral and axillary regions.

On admission, the primary physical examination showed bilateral axillary lymphadenopathy.

From the Department of Dermatology^a and Dermatopathology Unit, Department of Dermatology, University of Pittsburgh Medical Center,^b and Teledermatology, University of Pittsburgh Medical Center, North Hills Dermatology, Wexford.^c

Funding sources: None.

IRB approval status: Not applicable.

Disclaimer: All procedures followed have been performed in accordance with the ethical standards laid down in the 1964 Declaration of Helsinki and its later amendments.

Correspondence to: Hasan Khosravi, MD, Department of Dermatology, University of Pittsburgh Medical Center, 3601

Fifth Avenue, 5th Floor, Pittsburgh, PA 15213. E-mail: khosravih@upmc.edu.

JAAD Case Reports 2021;12:51-3.
2352-5126

© 2021 by the American Academy of Dermatology, Inc. Published by Elsevier, Inc. This is an open access article under the CC BY-NC-ND license (<http://creativecommons.org/licenses/by-nc-nd/4.0/>).

<https://doi.org/10.1016/j.jdc.2021.03.049>

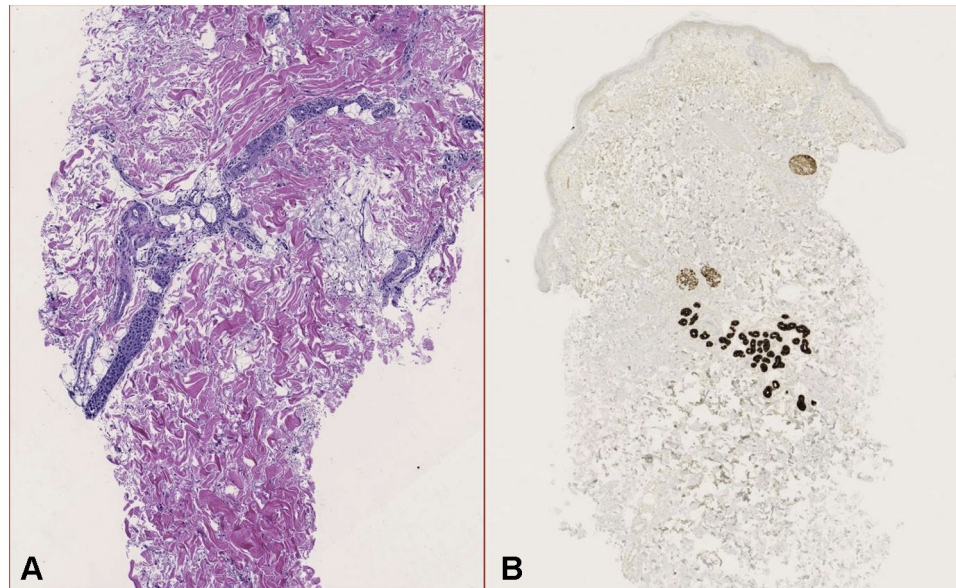


Fig 2. Biopsy of the left side of the chest. **A**, Metastatic deposits within dilated small-caliber dermal blood vessels. **B**, Positive CK7 staining. (**A**, Hematoxylin-eosin stain, and **B**, CK7 stain; original magnification: **A**, $\times 10$.)

Complete blood count and comprehensive metabolic panel were within normal limits. The chest radiograph demonstrated a left lower lobe opacity consistent with atelectasis given recent deconditioning. Computed tomography without contrast of the chest was also obtained 1 day later. It revealed a new small left pleural effusion, progressing bilateral axillary adenopathy, and enlarged subcutaneous metastasis of the posterior left side of the neck. The e-dermatology service was consulted for the rash, and the initial differential diagnosis included a neutrophilic dermatosis, atypical disseminated herpes zoster, dermal hypersensitivity reaction, versus carcinoma erysipeloides. The primary team was instructed to obtain a biopsy from the left side of the chest. The pathologic examination (Fig 2, A) demonstrated metastatic deposits within dilated small-caliber dermal blood vessels that stained positive for CK7 (Fig 2, B) and negative for CK20, p63, Herpes simplex virus-1/2, varicella zoster virus, Periodic acid–Schiff, and Grocott methenamine silver staining. This result was considered consistent with metastatic esophageal adenocarcinoma. The goals of care were reviewed with the patient, and he subsequently passed away 1 week later after deciding to focus on palliative care.

DISCUSSION

To our knowledge, this is the first case of carcinoma erysipeloides due to metastatic esophageal adenocarcinoma diagnosed via inpatient e-dermatology. Notably, esophageal adenocarcinoma is the

eighth most common cause of death with metastases commonly occurring in the liver and lung and less than 1% occurring in the skin.^{2,3} On review of the literature, 1 other case has documented telangiectatic plaques with this metastatic carcinoma.⁴ Most cases demonstrated localized disease: 6 cases of localized nodules and/or plaques on the scalp and face,^{2,5,6} 2 reports of subcutaneous nodules on the back,^{7,8} and 2 reports of subcutaneous nodules on the arm.³ In addition, when considering cutaneous manifestations of metastatic disease, one should also include paraneoplastic manifestations of metastatic esophageal adenocarcinoma, including dermatomyositis and subacute cutaneous lupus.⁹ Treatments for metastatic esophageal adenocarcinoma include, but are not limited to, combination chemotherapy with fluoropyrimidine and oxaliplatin, taxanes, or irinotecan with consideration of trastuzumab for HER2-positive tumors and immunotherapy for PD-L1-overexpressing adenocarcinomas^{2,4,10}; however, given our patient's age and comorbidities, he opted for palliative care.

Lastly, esophageal carcinoma has a 1-year and 5-year survival of 50% and 10%, respectively. The metastatic disease has a median survival of 9 months; cutaneous manifestations of this disease can have significant prognostic implications in both staging and assessing the response to treatment.^{2,3} We believe that this case report not only adds to our knowledge of the clinical manifestations of cutaneous metastatic esophageal adenocarcinoma but also demonstrates the utility of inpatient

dermatology in diagnosing cutaneous manifestations of internal disease.

Conflicts of interest

None disclosed.

REFERENCES

1. Barbieri JS, Nelson CA, James WD, et al. The reliability of teledermatology to triage inpatient dermatology consultations. *JAMA Dermatol.* 2014;150(4):419-424.
2. Tarantino IS, Tennill T, Fraga G, Fischer R. Cutaneous metastases from esophageal adenocarcinoma on the scalp. *Cutis.* 2020;105(3):E3-E4.
3. Chauhan A, Sharma AK, Sunita BS. Cutaneous metastasis as primary presentation in unsuspected carcinoma esophagus: report of two cases. *J Cancer Res Ther.* 2015;11(3):667.
4. Young ED, Wu DJ, Rajpara A, Fraga GR. Cutaneous metastasis of esophageal adenocarcinoma presenting as telangiectatic metastatic carcinoma demonstrating intravascular proliferation of tumor emboli. *JAAD Case Rep.* 2020;6(10):1062-1064.
5. Higgins E, Monaghan L, Mani RR. Cutaneous metastasis of a primary oesophageal adenocarcinoma to the right cheek. *J Surg Case Rep.* 2017;2017(9):rjx181.
6. Roy AD, Sherparpa M, Prasad PR, Lamichanet R. Scalp metastasis of gastro-esophageal junction adenocarcinoma: a rare occurrence. *J Clin Diagn Res.* 2014;8(2):159-160.
7. Adyanthaya R. Multiple cutaneous metastases from esophageal adenocarcinoma. *J Gastrointest Cancer.* 2008;39(1-4):22-25.
8. Hedeshian MH, Wang X, Xu B, Fontaine JP, Podbielski FJ. Subcutaneous metastasis from esophageal cancer. *Asian Cardiovasc Thorac Ann.* 2006;14(6):520-521.
9. Jasim ZF, Walsh MY, Armstrong DK. Subacute lupus erythematosus-like rash associated with oesophageal adenocarcinoma in situ. *Clin Exp Dermatol.* 2007;32(4):443-445.
10. Ter Veer E, Haj Mohammad N, van Valkenhoef G, et al. The efficacy and safety of first-line chemotherapy in advanced esophagogastric cancer: A network meta-analysis. *J Natl Cancer Inst.* 2016;108(10).