

# Pancreaticojejunostomy Sleeve Reconstruction After Pancreaticoduodenectomy in Laparoscopic and Open Surgery

Zhao Lei, MS, Wang Zhifei, MD, Xu Jun, MD, Liu Chang, MD,  
Xu Lishan, MD, Guan Yinghui, MD, Zhai Bo, MS

## ABSTRACT

**Introduction:** Laparoscopic procedures for pancreatic surgery have been significantly improved recently; however, only a limited number of successful laparoscopic or laparoscopy-assisted pancreaticoduodenectomy (PD) have been reported. The limitations could be attributed to the complexity of the reconstruction procedures under laparoscopic observation and the high incidence of complications. Postoperative pancreatic fistula (POPF) has been regarded traditionally as the most frequent major complication and is a potentially serious and life-threatening event. It remains the single most important cause of morbidity after PD and contributes significantly to prolonged mortality. Several modified methods of pancreas anastomosis were introduced to prevent POPF. However, few methods with a satisfactory leakage rate have yet to be seen. Collating principle of theoretical mechanics, we introduce a new method of reconstruction by performing an asymmetric sleeving-joint pancreaticojejunostomy (SJPJ). The aim of this study is to summarize the results of a new technique that is designed to decrease the POPF.

**Methods:** From January 2004 to December 2010, SJPJ was performed on 86 patients undergoing PD by 1 surgeon: a laparoscopic reconstruction was completed in 9 cases, a hand-assisted laparoscopic reconstruction in 2 cases, and an open SJPJ reconstruction in 75 cases.

**Discussion:** We used SJPJ, an asymmetric pancreaticojejunostomy (PJ). The time of operation ranged from 300 minutes to 640 minutes. Postoperatively there were no major morbidities and no deaths. Although POPF was

observed in the laparoscopic SJPJ group with pancreatic adenocarcinoma, 3 patients developed POPF in the open SJPJ group with ampullary adenocarcinoma (n=1) and pancreatic adenocarcinoma (n=2). The POPF rate was 9.30% in the open SJPJ group and 9.10% in the laparoscopic SJPJ group. The SJPJ procedure facilitates PJ, both laparoscopically and in open surgery. It is safe, effective, and feasible in experience hands.

**Key Words:** Laparoscopic, Pancreaticojejunostomy, Pancreaticoduodenectomy, Asymmetry.

## INTRODUCTION

Pancreaticoduodenectomy (PD) is one of the most commonly performed procedures for the management of peri-ampullary adenocarcinoma and cancer of the head of the pancreas. Recently, laparoscopic surgery has evolved to such an extent that even laparoscopic PD has been performed.<sup>1,2</sup> Postoperative pancreatic fistula (POPF) has been regarded traditionally as the most frequent major complication and is a potentially serious life-threatening event. It remains the single most important cause of morbidity after PD and also contributes significantly to prolonged mortality.<sup>3</sup> Previous publications reported that the incidence of pancreatic leakage ranged between 9.9% and 28.5%, and different definitions of PF were applied with high statistical differences between them.<sup>4</sup> To prevent POPF, many methods have been attempted; pancreaticojejunostomy (PJ) is the most common technique used for pancreatic reconstruction<sup>5</sup> and also the most concerning. Many modified methods of PJ were introduced in the literature such as Blumgart's anastomosis for PJ,<sup>6</sup> PJ with application of patch,<sup>7</sup> and Pengl.II-type binding PJ.<sup>8</sup> However, few methods<sup>5</sup> with a satisfactory leakage rate have yet to be seen. The best technique in pancreatic anastomosis, especially under laparoscope, is still debated.<sup>5,8</sup> We introduce a new method of pancreatic reconstruction by performing a sleeving-joint pancreaticojejunostomy (SJPJ) during PD, which was applied both in laparoscopic and open surgery.

Department of General Surgery, Fourth Affiliated Hospital of Harbin Medical University, Harbin City, Heilongjiang Province, China (all authors).

Drs. Lei and Zhifei contributed equally to this work and should be considered co-first authors.

This work was supported by a grant from the Ministry of Education of China [Grant No. W2012RQ06].

Address correspondence to: Jun Xu, Department of General Surgery, Fourth Affiliated Hospital of Harbin Medical University, No. 37, Yiyuan Street, Nan-Gang District, Harbin City, Heilongjiang Prov, 150001, China. Telephone: 008613796001434. E-mail: zhaoleihyd@163.com

DOI: 10.4293/108680812X13517013318238

© 2013 by JSLS, *Journal of the Society of Laparoendoscopic Surgeons*. Published by the Society of Laparoendoscopic Surgeons, Inc.

## MATERIALS AND METHODS

### Materials

From January 2004 to December 2010, data of 158 cases undergoing PD (11 cases of laparoscopic PD, 147 cases of open PD) by the same surgeon were retrospectively studied and were divided into 3 groups according to the different reconstruction patterns for PJ: laparoscopic SJPJ in 11 cases (group A), open SJPJ in 75 cases (group B), and conventional end-to-end PJ in 72 cases (group C). The primary indications for surgery were severe to moderate unremitting abdominal pain, unrelieved or partially relieved with analgesics; severe unremitting icterus; and significant weight loss. In group A, a totally laparoscopic reconstruction was completed in 9 cases and a hand-assisted laparoscopic reconstruction in 2 cases. A stent was placed in the pancreatic duct in some of the patients (**Table 1**). All patients underwent routine hematological and biochemical investigations and abdominal radiograph, ultrasonography computed tomography scan, and magnetic resonance cholangiopancreatography. All patients were predicted to be fully resectable. PD was performed by the surgeon with experience of >80 conventional open PD and >100 complicated hepatobiliary and pancreatic surgery operations.

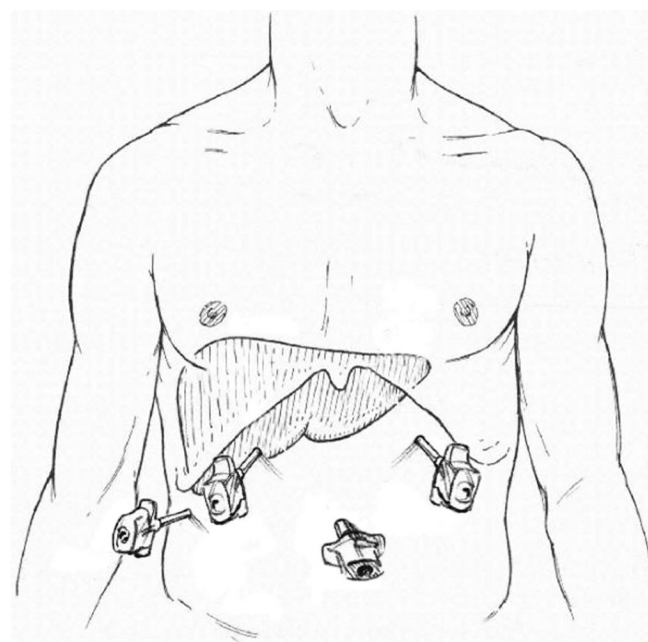
### General Considerations

The operation was performed under general anesthesia with preoperative and intraoperative antibiotic cover. For laparoscopic PD, the patient was placed in a supine position with both lower limbs abducted. The first 10-mm trocar was inserted 1.0 cm under the umbilicus to allow the laparoscope (Olympus, Tokyo, Japan), and a pneumoperitoneum was established with the pressure at 13 mm Hg. A 5-mm trocar and a 15-mm trocar were inserted 1.0 cm under the junction of the left and right medio clavicular line (MCL) and costal margin (CM) for laparoscopic harmonic scalpel (UHS) and LigaSure (Covidien,

Boulder, CO), respectively. An ancillary 5-mm trocar was inserted 1.0 cm under the intersection of the right anterior axillary line (AAL) and CM for laparoscopic grasping forceps. All of the positions of trocars were inserted as illustrated in **Figure 1**. For open PD, the patients were placed in the supine position.

### Resecting Specimen

After a thorough exploration of the abdomen viscera and systematic examination of any suspicious serosal lesion, especially in the liver and stomach, the gastrocolic ligament was dissected and divided. The right half of the great omentum was opened; a Kocher incision was made and extended to 15.0 cm distal to the Treitz ligament for completely mobilizing the duodenum. The superior mesenteric vein (SMV) was identified and dissected following the middle colic vein below the pancreatic inferior margin toward the junction of the SMV and portal vein. The dorsal aspect of the pancreatic neck was then directly dissected from the SMV and portal vein. The hepatoduodenal ligament was dissected, and the eighth and twelfth group lymph nodes together with the surrounding soft tissue were removed for a complete skeletonization. Distal gastrectomy was completed using Endo GIA (Covidien) after dividing the right gastric gastroepiploic arteries and gastroduodenal artery with LigaSure. The common hepatic



**Figure 1.** Trocar placement and site of surgical incision for the specimen delivery.

**Table 1.**

Data of Patients With and Without Stent in the Pancreatic Duct

	Laparoscopic SJPJ (n=11)	Open SJPJ (n=75)	Open PJ (n=72)
With stent (n)	10	47	45
POPF (n) (%)	1 (10.00)	0 (0)	5 (11.11)
Without stent (n)	1	28	27
POPF (n) (%)	0 (0)	3 (10.71)	10 (37.04)

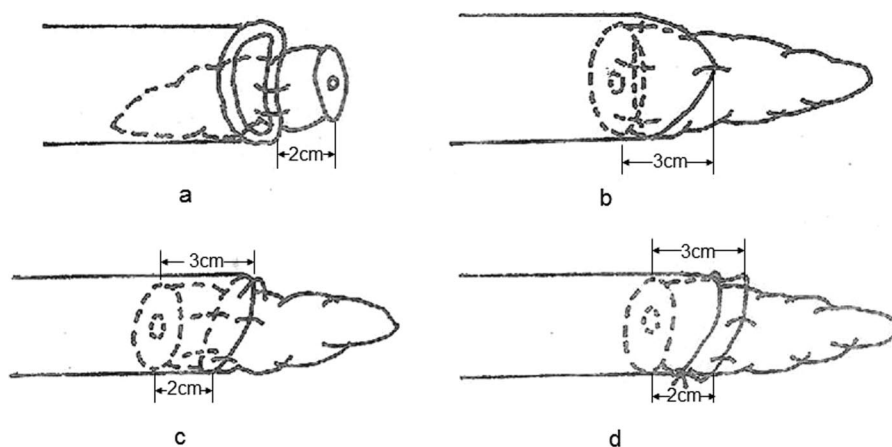
duct was transected after cholecystectomy. The neck of the pancreas was carefully divided using a laparoscopic harmonic scalpel. The uncinate process of the pancreas was separated and dissected along the SMV. The upper portion of the jejunum was transected with Endo GIA. The resection margins were tumor-free in all patients and confirmed by frozen section and histopathology.

### Reconstruction

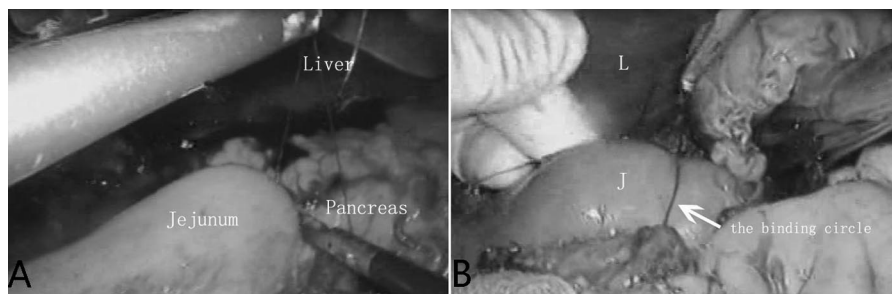
A modified reconstruction procedure was performed with Child's reconstruction. Laparoscopic SJPJ was performed first. The remnant of the pancreas was dissected for a distance of 2.0 cm from the cut edge. First, the anastomosis was constructed in an end-to-end fashion. The posterior wall consisted of interrupted 2 sutures with 5-0 absorbable monofilament incorporating the pancreatic capsule 2.0 cm distant to the pancreatic stump and seromuscular bites of the jejunum. Tension should be maintained on the jejunum specifically between sutures, for a tight connection between the anastomosis part (**Figure 2A**). Second, the anterior jejunum wall was drawn to wrap over the pancreatic stump

with a 3.0-cm distance to the pancreatic stump; then the seromuscular layer of the jejunum was sutured to the pancreatic capsule. Thus, an asymmetry of 1.0 cm between 2 sides at the PJ site was made to form an additional appropriate tension. One or 2 sutures were added to keep a 0.3- to 0.5-cm distance between sutures (**Figure 2B, C**), depending on the size of the pancreatic stump. Finally, a binding technique was routinely added: a 4-0 nonabsorbable ligature was circled around the jejunum loop with the pancreatic stump inside, 1.0 cm distant to the anastomosis, after 2 string sutures were placed, connecting it to the jejunum serosa to prevent sliding. Then the circled ligature was tied to form an appropriate tension until the wall where the jejunum was bound appeared a little wrinkled (**Figure 2D**).

Cholangiojejunostomy (CHJ) and gastrojejunostomy (GJ) were done on the same jejunal loop distal to the PJ. CHJ was completed 10 cm distal to the stoma of pancreaticojejunostomosis with a 1-layer suture with 3.0 absorbable ligatures. GJ was completed 50.0 cm away from the CHJ site with staples. Two drainage tubes were



**Figure 2.** The main steps of laparoscopic sleeve-joint pancreaticojejunostomy (SJPJ); (B) top view of laparoscopic SJPJ; (C) side view of laparoscopic SJPJ.



**Figure 3.** (A) Sleeve-joint pancreaticojejunostomy (SJPJ) in total laparoscopic reconstruction; (B) SJPJ in hand-assisted laparoscopic reconstruction.

placed near the anastomosis site of PJ and CHJ, respectively.

## RESULTS

The volume and the amylase level of the drain fluid were measured daily postoperatively. The draining tube was removed when the drain output was <10 mL/day. POPF was definite according to the definition of the International Study Group of Pancreatic Fistula in 2005<sup>4</sup>: Output via an operatively placed drain (or a subsequently placed percutaneous drain) of any measurable volume of drain fluid on or after postoperative day 3, with an amylase content >3 times the upper normal serum value.

The demographic data and the pathological findings of the 3 groups are shown in **Table 2**. The final pathology of the resected specimens was reviewed by 2 independent pathologists. There were no significant differences in the data between the 3 groups. The intraoperative data and postoperative courses and complications of the 3 groups of patients are presented in **Table 3**. The mean operative time of laparoscopic SJPJ was 473.8 minutes (range: 300–640), which was significantly longer than that of both open SJPJ and open PJ ( $P<.05$ ). For all of the patients in the 3 groups, 35 cases were found to have complications: the total complication rate was 22.15% (35/158). Among

them, POPF was observed in 19 cases, with the rate of 12.03% (19/158), bile leakage was found in 3 cases, delayed gastric emptying occurred in 4 cases, and lung infection occurred in 2 cases.

Among the cases with the complication of POPF, 4 were found in the laparoscopic and open SJPJ groups, with a rate of 4.65% (4/86), whereas 15 were found in the open PJ group, with a rate of 20.83% (15/72). In groups B and C, the incidence rate of pancreatic leakage was significantly higher in the cases without the placement of stent versus with stent placement ( $P<.05$ ). For those with the stent placement, POPF rate in the laparoscopic and open SJPJ groups was both lower than that in the open PJ group ( $P<.05$ ), whereas there was no significant difference between the laparoscopic and open SJPJ groups. For those without stent placement, the POPF rate was the lowest in the open SJPJ group ( $P<.05$ ), whereas in the laparoscopic SJPJ group, the POPF rate was not taken into account because there was only 1 case. All of the cases with POPF were treated and cured with reliable irrigation and drainage. The mean duration of the postoperative hospital stay for laparoscopic SJPJ was 18.14 days, significantly shorter compared with 22.29 days for open SJPJ and 25.11 days for open PJ. The difference between the 2 groups was significant ( $P<.05$ ).

**Table 2.**  
Demographic Data and Pathological Findings<sup>a</sup>

	Laparoscopic SJPJ (n=11)	Open SJPJ <sup>b</sup> (n=75)	Open PJ <sup>b</sup> (n=72)
Age (y)	58.55±13.31	54.81±10.63	54.68±9.96
Body mass index <sup>c</sup>	25.66±2.04	26.03±1.80	26.92±3.23
Gender [n (%)]			
Male	6 (54.55)	33 (44.00)	35 (48.61)
Female	5 (45.45)	42 (56.00)	37 (51.39)
Final pathology [n (%)]			
Pancreatic adenocarcinoma	5 (45.45)	25 (33.33)	22 (30.56)
Duodenal adenocarcinoma	3 (27.27)	23 (30.67)	16 (22.22)
Ampullary adenocarcinoma	1 (9.10)	18 (24.00)	17 (23.61)
Chronic pancreatitis and pancreatic lithiasis	1 (9.10)	—	—
Duodenal ulcer attack on the pancreatic papillae	1 (9.10)	6 (8.00)	2 (2.78)
Distal bile duct adenocarcinoma	—	3 (4.00)	6 (8.33)
Pancreatic pseudocyst	—	—	9 (12.50)

<sup>a</sup>Data are presented as mean ± SD.

<sup>b</sup>SJPJ=sleeving-joint pancreaticojejunostomy; PJ=pancreaticojejunostomy.

<sup>c</sup>Calculated as weight in kilograms divided by height in meters squared.



**Table 3.**  
Intraoperative and Postoperative Course and Complications<sup>a</sup>

	Laparoscopic SJPJ <sup>b</sup> (n=11)	Open SJPJ <sup>b</sup> (n=75)	Open PJ <sup>b</sup> (n=72)
Blood loss (mL)	1106±52.67	1103±56.14	1143±285.61
Operative time (min)	473.75±88.27	250.88±46.75	288.56±53.15
Abdominal complications [n (%)]			
Pancreatic anastomotic leakage	1 (9.10)	3 (4.00)	15 (20.83)
Biliary leakage	0	0	0
Delayed gastric emptying	1 (9.10)	2 (2.67)	1 (1.39)
Lung infection	0	1 (1.33)	1 (1.39)
Intraperitoneal abscess	0	0	0
Postoperative hospital stay (days)	18.14±5.99	22.29±3.10	25.11±4.20
In-hospital mortality [n (%)]	0	0	0

<sup>a</sup>Data are presented as mean ± SD.

<sup>b</sup>SJPJ=sleeving-joint pancreaticojejunostomy; PJ=pancreaticojejunostomy.

The follow-up ranged from 1 to 6 months. Icterus relief was complete in 158 patients. Pain relief was complete in 155 patients (98.10%). In 3 patients (1.90%) with initial pain relief, pain recurred after approximately 3 to 6 months but was milder in intensity, was occasional, and could be relieved with oral analgesics. Exocrine function of the pancreas was normal in all patients. No deaths were reported in all cases within 6 months.

## DISCUSSION

POPF is one of the most common and serious complications of PD, and various attempts at PJ have been attempted to reduce its incidence.<sup>9</sup> Our study showed a lower rate of POPF with the novel SJPJ pattern than with conventional PJ, taking the stent placement in the pancreatic duct as an independent factor.

The incidence of POPF is generally considered to be related to several factors: placement of the stent inside the pancreatic duct, the texture of the pancreatic stump, and the pattern for anastomosis. PJ is a commonly used pattern. Still, various modified attempts have been tried,<sup>5-7,9</sup> and some were reported to be effective and have been applied. However, the length for connecting the pancreas and jejunum is no doubt an important factor, and an appropriate longer length for the pancreatic stump plugged into the jejunum should be an effective modification. Yet, little attention is paid to its modification. This is understandable given the fact that a longer freeing of the dorsal side for pancreatic stump is somehow hard to achieve. However, the anterior side of the pancreatic

stump can be easily and safely for dissection to a longer distance, which will result in the longer connection for PJ anteriorly. In addition, the different length of jejunum connecting the pancreatic stump will produce an asymmetry for the anastomosis part; as a result, the anterior jejunum wall connecting the pancreatic stump will retract slightly to form a tension that makes the connection between the posterior wall of the jejunum and the pancreatic stump tighter.

In addition, we also applied a binding around the jejunum loop with the pancreatic stump inside similar to binding PJ by Peng's procedure without destroying the mucosa of the segment of jejunum contacting with the pancreatic stump. The advantages of this binding procedure have already been introduced.<sup>5</sup> We merely combined the binding with our asymmetry anastomosis as SJPJ. The binding technique may also have contributed to the lower POPF rate of laparoscopic and open SJPJ, so there should have been a comparative study taking the binding technique as a single factor to rule out its influences.

Before laparoscopic PD, we completed 58 cases of open PD from January 2004 to November 2005. During that time, 40 PJs and 18 SJPJs were performed. After the initial experience, we performed more SJPJs than PJs. Specifically, since December 2005, SJPJs have been the only procedure for laparoscopic PD at our center. In this retrospective study, we take the placement of the pancreatic stent as a single factor to rule out the influence of pancreatic duct drainage. In all of the cases in the 3 groups, we abandoned the placement of the pancreatic

duct stent only in the cases whose pancreatic ducts could not be found and also with nearly normal pancreatic texture. For those with a stent in open PD, the POPF rate of open SJPJ was lower than that in open PJ ( $P<.05$ ), whereas for those without stent placement, the POPF rate of open SJPJ was lower than that in open PJ ( $P<.05$ ) too, which shows that SJPJ reduces the POPF rate in open PD.

## CONCLUSION

Laparoscopic PJ after PD was rarely reported because it is technically demanding and there is a high risk of PF complication. The rates of POPF in laparoscopy were still unsatisfactory.<sup>10–12</sup> On the basis of the data in our study, laparoscopic SJPJ reduces the POPF rate. In addition, to our experience, it does not add much to the technique's difficulties. Our study suggests that SJPJ is a safe and feasible new technique for PJ, but more cases are needed to verify this validity.

## References:

1. Tania O, Jindal MK, Khanna S, Sen B. Laparoscopic lateral pancreaticojejunostomy: our experience of 17 cases. *Surg Endosc.* 2004;18:1054–1057.
2. Zureikat AH, Breaux JA, Steel JL, Hughes SJ. Can laparoscopic pancreaticoduodenectomy be safely implemented? *J Gastrointest Surg.* 2011;15:1151–1157.
3. Poon RT, Lo SH, Fong D, Fan ST, Wong J. Prevention of pancreatic anastomotic leakage after pancreaticoduodenectomy. *Am J Surg.* 2002;183:42–52.
4. Bassi C, Dervenis C, Butturini G, et al. Postoperative pancreatic fistula: an international study group (ISGPF) definition. *Surgery.* 2005;138:8–13.
5. Peng SY, Wang JW, Lau WY, et al. Conventional versus binding pancreaticojejunostomy after pancreaticoduodenectomy: a prospective randomized trial. *Ann Surg.* 2007;245:692–698.
6. Kleespies A, Rentsch M, Seeliger H, Albertsmeier M, Jauch KW, Bruns CJ. Blumgart anastomosis for pancreaticojejunostomy minimizes severe complications after pancreatic head resection. *Br J Surg.* 2009;96:741–750.
7. Chirletti P, Caronna R, Fanello G, et al. Pancreaticojejunostomy with application of fibrinogen/thrombin-coated collagen patch (TachoSil) in Roux-en-Y reconstruction after pancreaticoduodenectomy. *J Gastrointest Surg.* 2009;13:1396–1398; author reply 1399–1400.
8. Peng S, Mou Y, Cai X, Peng C. Binding pancreaticojejunostomy is a new technique to minimize leakage. *Am J Surg.* 2002;183:283–285.
9. Chen XP, Qiu FZ, Zhang ZW, Chen YF, Huang ZY, Zhang WG. A new simple and safe technique of end-to-end invaginated pancreaticojejunostomy with transpancreatic U-sutures—early postoperative outcomes in consecutive 88 cases. *Langenbecks Arch Surg.* 2009;394:739–744.
10. Palanivelu C, Jani K, Senthilnathan P, Parthasarathi R, Rajapandian S, Madhankumar MV. Laparoscopic pancreaticoduodenectomy: technique and outcomes. *J Am Coll Surg.* 2007;205:222–230.
11. Dulucq JL, Wintringer P, Mahajna A. Laparoscopic pancreaticoduodenectomy for benign and malignant diseases. *Surg Endosc.* 2006;20:1045–1050.
12. Kendrick ML, Cusati D. Total laparoscopic pancreaticoduodenectomy: feasibility and outcome in an early experience. *Arch Surg.* 2010;145:19–23.