

Received: 2013.02.28  
Accepted: 2013.05.17  
Published: 2013.11.21

ISSN 1507-6164  
© Am J Case Rep, 2013; 14: 494-497  
DOI: 10.12659/AJCR.889102

## Postoperative left ventricular apical ballooning: Transient Takotsubo cardiomyopathy following orthotopic liver transplantation

Authors' Contribution:  
Study Design A  
Data Collection B  
Statistical Analysis C  
Data Interpretation D  
Manuscript Preparation E  
Literature Search F  
Funds Collection G

ABDF **Helena Bedanova**  
D **Marek Orban**  
E **Petr Nemec**

Center of Cardiovascular and Transplant Surgery, Brno, Czech Republic

**Source of support:** The authors were supported by the European Regional Development Fund – Project FNUSA-ICRC No. CZ.1.05/1.1.00/02.0123

**Corresponding Author:** Helena Bedanova, e-mail: [hbedanova@seznam.cz](mailto:hbedanova@seznam.cz)

**Patient:** Female, 51  
**Final Diagnosis:** Takotsubo cardiomyopathy  
**Symptoms:** —  
**Medication:** —  
**Clinical Procedure:** —  
**Specialty:** Cardiology • Transplantology

**Objective:** Rare disease

**Background:** Left ventricular apical ballooning syndrome (LVAB), also known as Takotsubo cardiomyopathy, is a cardiac syndrome characterized by transient left ventricular dysfunction in the absence of obstructive atherosclerotic coronary artery disease. An episode of emotional stress, typically in female patients, is believed to precede and trigger the development of this syndrome.

**Case Report:** We report a case of Takotsubo cardiomyopathy that developed after orthotopic liver transplantation in a 51-year-old woman. On D2 (day 2) the patient had severe hemodynamic compromise. Echocardiography showed systolic dysfunction of the left ventricle (LV), with ejection fraction (EF) of 20% and anteroapical akinesis and ballooning of the apical 2/3 of the LV. Troponin T was elevated but other markers of myocardial necrosis were negative, as was coronary angiography. From D7 onward, there was an improvement in the hemodynamics in conjunction with a gradual increase of LV EF. The patient was dismissed from the hospital on D30 with signs of normal cardiac function and LV motion and EF of 50%. Liver function was also excellent.

**Conclusions:** Every major operation, including liver transplantation, is associated with emotional stress for the patient. Therefore, it is necessary to consider Takotsubo cardiomyopathy in the differential diagnosis of heart failure developing early after LT, and clinicians should subsequently use adequate diagnostic and therapeutic measures.

**Key words:** takotsubo cardiomyopathy • cardiogenic shock • liver transplantation

**Full-text PDF:** <http://www.amjcaserep.com/download/index/idArt/889102>



1036



—



6



11

## Background

Left ventricular apical ballooning syndrome (LVAB), also known as Takotsubo cardiomyopathy, is a cardiac syndrome characterized by transient left ventricular dysfunction in the absence of obstructive atherosclerotic coronary artery disease. An episode of emotional stress, typically in female patients, is believed to precede and trigger the development of this syndrome. Excessive physical stress, including major surgery, is another suspected cause. Liver transplant has been associated with LVAB in a limited number of case reports. Takotsubo cardiomyopathy usually represents an acute coronary syndrome characterized by chest pain, pulmonary edema, electrocardiographic changes, elevated cardiac enzymes, and, in some cases, cardiogenic shock. These symptoms can be modified shortly after major surgery. Early detection is crucial for further treatment and can be rather challenging.

## Case Report

We report a case of transient left ventricular apical ballooning syndrome (Takotsubo cardiomyopathy) that occurred after orthotopic liver transplantation. A 51-year-old woman with end-stage liver cirrhosis with ascites and fluidothorax secondary to autoimmune hepatitis underwent successful orthotopic liver transplantation in September 2011. The patient's medical history included systemic lupus erythematosus syndrome (presenting with liver and kidney dysfunction, hemolytic anemia, and joint involvement), hepatitis type A, and gastrointestinal bleeding, without a prior history of coronary artery or valvular diseases, systemic hypertension, diabetes, smoking, or hyperlipidemia. Transthoracic echocardiography prior to transplantation demonstrated normal left ventricular size and function (60% ejection fraction). There were no stress-induced wall motion abnormalities and the cardiac valves were normal. There was a chronic pleural effusion in the right thorax. The intraoperative course was uneventful. The patient had an estimated blood loss of 500 mL and received 1 unit of platelets. The patient did not require inotropic support

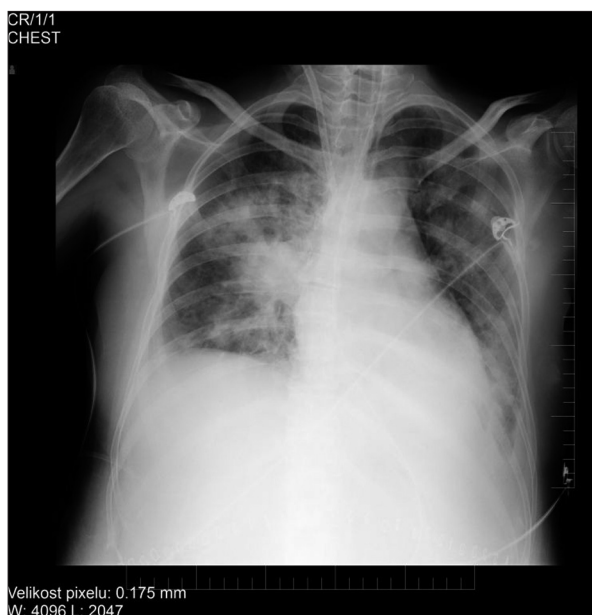


Figure 1. Chest x-ray: pulmonary edema.

during the procedure and had no hemodynamic instability. Thromboelastogram during the procedure did not reveal any evidence of a hypercoagulation state and the patient was extubated 6 hours after surgery.

Anuria developed on D1 (day 1) after surgery, with the need for continuous venovenous hemofiltration and reintubation. On D2, severe hemodynamic compromise manifested, with the need for significant inotropic support (norepinephrine and dobutamine). Because symptoms of low cardiac output with systolic blood pressure below 80 mmHg persisted, an intra-aortic balloon pump was placed. Echocardiography was performed, showing severe systolic dysfunction of the left ventricle (LV), with an estimated ejection fraction (EF) of approximately 20% and anteroapical akinesia and ballooning of the distal and apical walls. Chest x-rays revealed pulmonary edema consistent with severe cardiac failure (Figure 1). A 12-lead electrocardiogram demonstrated anterior and lateral T-wave inversion (Figure 2). Troponin T was elevated at 1.21 ug/l (normal range

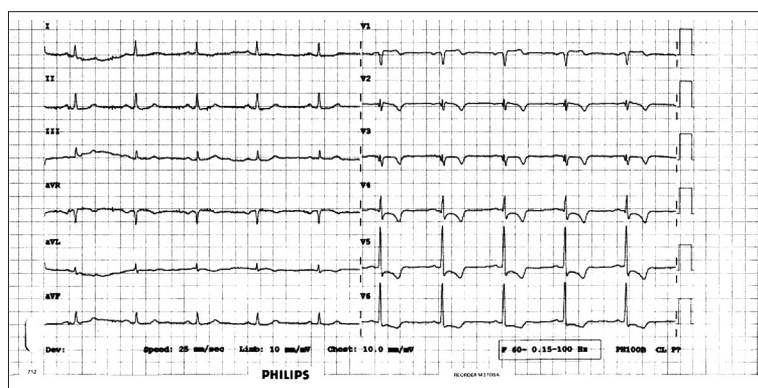
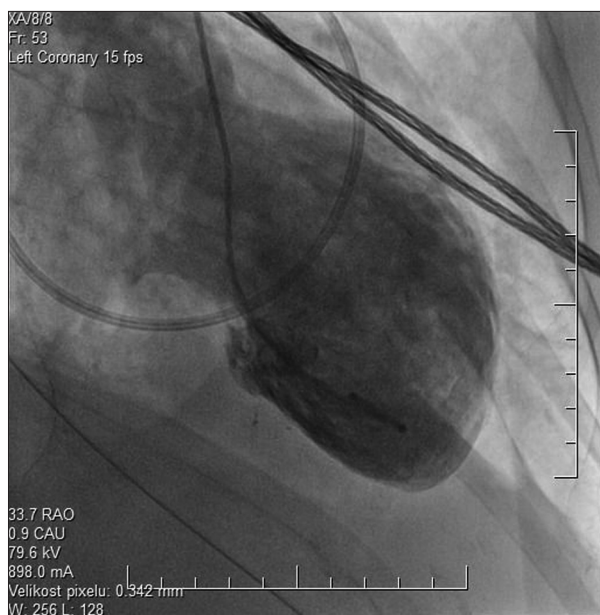
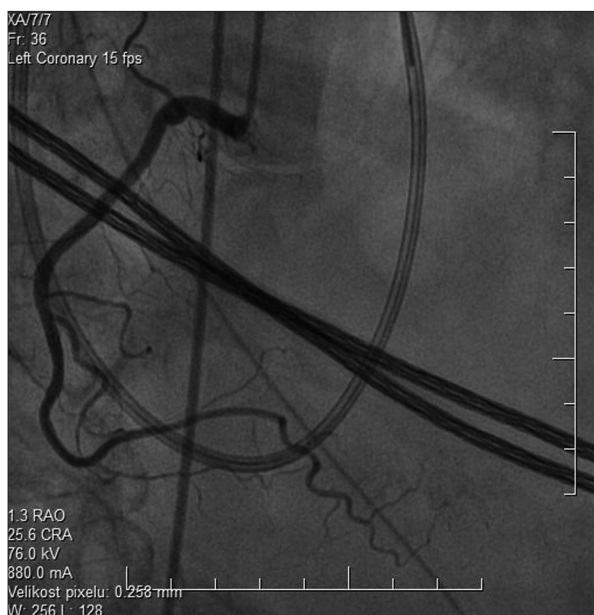


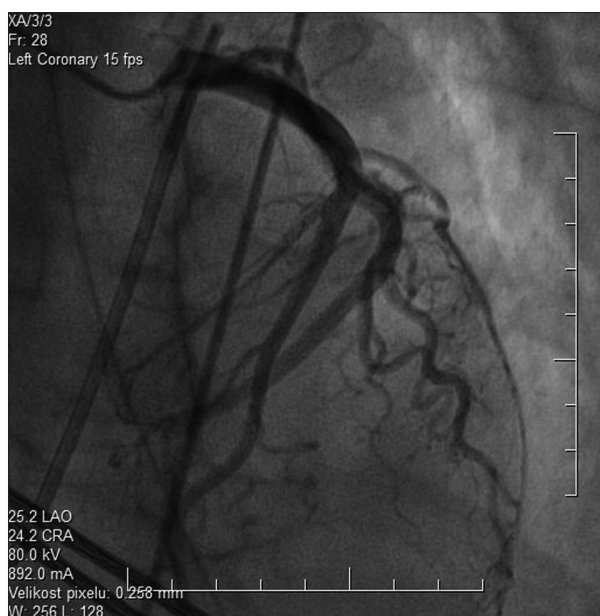
Figure 2. EKG: flipped T waves in anterior and lateral wall.



**Figure 3.** Left ventriculography during systole showing apical ballooning.



**Figure 5.** Angiography RCA.



**Figure 4.** Angiography LCA.

0–0.014), but other markers of myocardial necrosis were negative. The suspicion of Takotsubo cardiomyopathy was confirmed by left ventriculography, with apical wall motion abnormalities (Figure 3) and a negative coronary angiography (Figures 4 and 5). The next day, an endomyocardial biopsy from the right ventricle was performed, with no evidence of acute myocarditis. From D7 onward, an improvement in the hemodynamics, in conjunction with a gradual increase of LV EF, was recorded on echocardiography, and the intra-aortic balloon pump was removed on D9. The patient was dismissed from the hospital



**Figure 6.** The Japanese octopus trap – takotsubo.

on D30 with signs of normal cardiac function and LV motion and EF of 50%. Liver function was also excellent.

One year after LT, the patient has good liver and heart function and is living a full life.

## Discussion

Today, liver transplantation candidates are increasingly older; thus, it is not surprising that they have more cardiovascular comorbidities. Apart from the fact that they are older and have more comorbidity, there are specific cardiovascular responses to cirrhosis that can have a harmful effect on the postoperative course after LT. As presented by Raval [1], patients

with cirrhosis usually demonstrate increased cardiac output and a compromised ventricular response to stress, a condition termed cirrhotic cardiomyopathy. Low systemic vascular resistance and bradycardia are also commonly seen in cirrhosis and can be aggravated by beta-blocker use. These pathophysiologic changes all increase the potential for cardiovascular complications, particularly when exposed to the hemodynamic stress that LT patients face in the immediate post-operative period.

For these reasons, prior to placement on the waiting list, older liver transplant candidates in particular are very carefully examined (echocardiography, angiography, right-sided heart catheterization) to minimize the risk of adverse posttransplant cardiovascular events. In spite of these preventive measures, unpredicted life-threatening complications may occur and require heightened recognition and adequate treatment.

Takotsubo cardiomyopathy is one of the rare but very dangerous adverse cardiac events that have been reported after various major surgeries, including liver transplantation. The disease takes its name from the typical left apical ballooning observed on the end of the systolic left ventriculogram, which has the appearance of a *Tako-Tsubo*, a term for an ancient device used in Japan to trap octopuses in the sea (Figure 6). Other names – stress cardiomyopathy, left ventricular apical ballooning syndrome, and broken heart syndrome – are used interchangeably. Although initially reported only in Japan [2–4], it has been reported in patients with diverse ethnic backgrounds from all over the world [5].

## References:

1. Raval Z, Harinstein M, Skaro AI et al: Cardiovascular risk assessment of the liver transplant candidate. *J Am Coll Cardiol*, 2011; 58: 223–31
2. Sato H, Taiteishi H, Uchida T: Takotsubo-type cardiomyopathy due to multivessel spasm. In: *Clinical aspect of myocardial injury: From ischemia to heart failure*, Kodama K, Haze K, Hon M (Eds), Kagakuhyouronsha, Tokyo, 1990; 56
3. Dote K, Sato H, Tateishi H et al: Myocardial stunning due to simultaneous multivessel coronary spasms: a review of 5 cases. *J Cardiol*, 1991; 21: 203–14
4. Kawai S, Suzuki H, Yamaguchi H et al: Ampulla cardiomyopathy ('Takotsubo' cardiomyopathy)—reversible left ventricular dysfunction: with ST segment elevation. *Jpn Circ J*, 2000; 64: 156–59
5. Donohu D, Movahed MR: Clinical characteristics, demographics and prognosis of transient left ventricular apical ballooning syndrome. *Heart Fail Rev*, 2005; 10(4): 311–16
6. Lee HR, Hurst RT, Vargas HE: Transient left ventricular apical ballooning syndrome (Takotsubo cardiomyopathy) following orthotopic liver transplantation. *Liver Transpl*, 2007; 13: 1343–45
7. Tiwari AK, D'Attellis N: Intraoperative left ventricular apical ballooning: Transient Takotsubo cardiomyopathy during orthotopic liver transplantation. *J Cardiothorac Vasc Anesth*, 2008; 22(3): 442–45
8. Pires LJT, Curiati MNC, Reiche FW et al: Stress-induced cardiomyopathy (Takotsubo cardiomyopathy) after liver transplantation – report of two cases. *Transplant Proc*, 2012; 44: 2497–500
9. Dorman TA, Iskandrian AE: Takotsubo cardiomyopathy: State-of-the-art review. *J Nucl Cardiology*, 2009; 16: 122–34
10. Kurisu S, Sato H, Kawagoe T et al: Tako-tsubo-like left ventricular dysfunction with ST-segment elevation: a novel cardiac syndrome mimicking acute myocardial infarction. *Am Heart J*, 2002; 143(3): 448–55
11. Abe Y, Kondo M, Matsuoka R et al: Assessment of clinical features in transient left ventricular apical ballooning. *J Am Coll Cardiol*, 2003; 41(5): 737–42

## Conclusions

Every major operation causes emotional stress for the patient and it is understandable that organ transplantation, when the patient is aware of the fact that their life depends on the death of another person, is associated with an even greater emotional storm. Therefore, it is necessary to consider the possibility of Takotsubo cardiomyopathy developing early after a LT and to use adequate diagnostic and therapeutic measures.