

# Topical Dimethyl Sulfoxide for Congested Nipple–areolar Complexes in Breast Surgery: A Pilot Study

Max L. Silverstein, MD\*  
Paige McLean, MD†  
Jiwon S. Crowley, MD†  
Amanda A. Gosman, MD†

**Background:** Necrosis of the nipple–areolar complex (NAC) is a major complication of breast surgery that most commonly results from venous congestion. Several conservative rescue therapies have been proposed for relieving NAC congestion, but each carries certain drawbacks, including cost and side effect profile. In this study, we evaluated the effectiveness of topical dimethyl sulfoxide (DMSO), an inexpensive compound with vasodilatory, free radical scavenging, and antiinflammatory properties in rescuing congested NACs.

**Methods:** We conducted a review of all 15 patients treated with DMSO for NAC congestion at our institution between May 2019 and October 2020. DMSO was applied in liquid form on a soaked gauze pad in the hospital; patients were instructed to apply a DMSO cream to the NAC twice a day following discharge. Patient characteristics and data related to DMSO treatment and NAC healing were compared via univariate analysis.

**Results:** Eighteen congested NACs from 15 patients who underwent mastectomy, breast reduction, mastopexy, or breast reconstruction were treated with DMSO. Of the 18 treated NACs, 15 healed with DMSO treatment alone. The average length of DMSO treatment was  $9.4 \pm 8.5$  days (mean  $\pm$  standard deviation); NAC healing took place over  $9.9 \pm 9.6$  days. There were no complications related to DMSO treatment.

**Conclusions:** This pilot study shows that DMSO may be an effective topical treatment for NAC congestion following breast surgery. Given its low cost, ease of application, and lack of side effects, future studies should prospectively compare DMSO against other topical treatments, like nitroglycerin ointment. (*Plast Reconstr Surg Glob Open* 2022;10:e4595; doi: [10.1097/GOX.0000000000004595](https://doi.org/10.1097/GOX.0000000000004595); Published online 28 October 2022.)

## INTRODUCTION

Preservation of the nipple–areolar complex (NAC) is fundamental to achieving optimal cosmesis in reduction mammoplasty, mastopexy, and breast reconstruction after nipple-sparing mastectomy. Necrosis and loss of the NAC is an uncommon complication that has major cosmetic and functional consequences that are difficult to correct despite the reconstructive options available.

NAC necrosis most commonly occurs due to venous congestion.<sup>1</sup> The arterial system supplying the NAC courses deeper within the breast and is less likely to be disrupted during surgery than the more superficial venous

network.<sup>2</sup> Outflow obstruction can also be caused by kinking of the pedicle, overly tight skin closure, or hematoma. Congestion of the NAC can be identified clinically by its dark or dusky appearance, excessively brisk capillary refill, and edema of the nipple.<sup>3</sup>

Several conservative rescue therapies have been proposed for relieving nipple congestion in the early post-operative period. In addition to release of the sutures securing the areola to the surrounding breast, nitroglycerin ointment (NTG), steroids, vasodilators, leeches, and hyperbaric oxygen therapy (HBOT) have all been used to improve venous outflow with varying rates of success. Topical NTG is one of the most commonly used therapies for skin flap congestion, with a recent meta-analysis demonstrating its efficacy when applied to threatened mastectomy skin flaps,<sup>4</sup> though other studies refute its ability to rescue cutaneous flaps and grafts.<sup>5–8</sup>

In general, there is a paucity of published research on the use of any of the aforementioned conservative

From the \*Division of Plastic and Reconstructive Surgery, Stanford Hospital and Clinics, Palo Alto, Calif.; and †Department of Surgery, Division of Plastic Surgery, UC San Diego School of Medicine, San Diego, Calif.

Received for publication May 19, 2022; accepted August 23, 2022.

Copyright © 2022 The Authors. Published by Wolters Kluwer Health, Inc. on behalf of The American Society of Plastic Surgeons. This is an open-access article distributed under the terms of the [Creative Commons Attribution-Non Commercial-No Derivatives License 4.0 \(CCBY-NC-ND\)](https://creativecommons.org/licenses/by-nc-nd/4.0/), where it is permissible to download and share the work provided it is properly cited. The work cannot be changed in any way or used commercially without permission from the journal.

DOI: [10.1097/GOX.0000000000004595](https://doi.org/10.1097/GOX.0000000000004595)

**Disclosure:** The authors have no financial interest to declare in relation to the content of this article.

Related Digital Media are available in the full-text version of the article on [www.PRSGlobalOpen.com](https://www.PRSGlobalOpen.com).

measures for the treatment of NAC congestion. Each carries a risk for certain adverse effects (such as hypotension in patients treated with topical NTG) and several are inconvenient or impossible for a patient to self-administer in the case of prolonged treatment. Here, we present our experience using topical dimethyl sulfoxide (DMSO)—an inexpensive, safe,<sup>9</sup> over-the-counter compound commonly used as a vehicle for delivering other drugs through the skin—to rescue congested-appearing tissue following breast surgery, a concept that has been discussed multiple times in the plastic surgery literature since the late 1960s.<sup>10–12</sup> DMSO is thought to have vasodilatory, free radical scavenging, anesthetic, and antiinflammatory properties and has been used by urologists since the 1970s to treat interstitial cystitis. Here, we also compare DMSO with other topical therapies for NAC congestion and discuss its proposed mechanisms of action.

## METHODS

A retrospective chart review was conducted using the Epic (Epic Systems Corporation, Verona, WI) Slicer Dicer feature to isolate patients that had been treated with DMSO by a plastic surgery faculty member at our institution. Patients were further narrowed to those who received DMSO for NAC congestion, leaving 15 subjects, all treated between May 2019 and October 2020. This study was performed with institutional internal review board approval.

The following data elements were collected from the electronic medical record: age, body mass index (BMI), smoking status, comorbidities, ongoing cancer therapy, surgeon, breast surgery type, and laterality. In each instance, the earliest point at which signs of NAC congestion were observed and a description of the nipple appearance were recorded. Information related to the use of DMSO was collected throughout the treatment period: volume, dose, and frequency of application, length of use, complications, and any adjunctive topical treatments. Finally, the outcome of the congested NAC and the length of time between onset of congestion and either healing or debridement were noted.

NAC congestion was recognized by the operating surgeon either intraoperatively or in the immediate postoperative period. Congestion was identified by observable signs of reversible circulatory compromise, including edema, cyanosis, excessive ecchymosis, markedly brisk capillary refill, or dark rapid bleeding on pinprick. In two cases, NAC congestion was identified intraoperatively, and the periareolar sutures were released to decrease tension on the nipple. The NAC was determined to have healed when clinical signs of congestion had resolved and the area had returned to a color consistent with the patient's preoperative appearance. Conversely, necrosis was defined as irreversible, full-thickness compromise of the NAC, resulting in tissue loss with exposure of underlying layers. Once demarcation had set in, necrotic portions were debrided by the respective operating surgeon.

DMSO was applied to the NAC topically as soon as congestion was identified, often intraoperatively. The solution applied in the postoperative period prior to discharge was

## Takeaways

**Question:** Are there any alternatives to topical nitroglycerin for improving nipple-areolar complex (NAC) congestion following breast surgery?

**Findings:** In a series of 18 threatened NACs treated with topical dimethyl sulfoxide (DMSO), 15 healed completely and there were no complications observed.

**Meaning:** This pilot study shows that DMSO may be an effective topical treatment for NAC congestion following breast surgery.

a 50% DMSO liquid; approximately 50 mL of this liquid was used to soak a 4 cm × 4 cm gauze pad, which was then left in place over the NAC under a surgical bra for 12 hours until the next application. After discharge, patients were given directions to purchase a 70% DMSO cream (available online without a prescription) and instructed to apply the cream to the entire NAC twice per day. No exact dose or volume was specified. Patients were instructed to stop applying DMSO only if it was determined that the NAC had healed or required debridement during follow-up. Adjunctive treatments were used at the discretion of the operating surgeon, as noted in Supplemental Digital Content 1. Only HBO was used as an alternative, salvage treatment if the NAC remained viable but did not show signs of improvement after 48 hours of DMSO treatment. (See table, Supplemental Digital Content 1, which shows a detailed description for each study patient. <http://links.lww.com/PRSGO/C226>.)

Patient characteristics and data related to DMSO treatment and NAC healing were compiled and tabulated. Patient characteristics were analyzed on a per-patient basis; statistics related to DMSO and NAC healing were calculated per NAC treated. Univariate analysis was performed to compare the healed versus non-healed NACs across a number of factors known to influence wound healing. Continuous variables (age, BMI, length of DMSO treatment) were compared using the Mann-Whitney U test; categorical or binary variables (smoking, history of hypertension, immunocompromised state, laterality) were compared using the Pearson chi-square test. Significance was set at a *P* value of 0.05. All statistical analysis was performed using R Statistical Software (R Foundation for Statistical Computing, Vienna, Austria).

## RESULTS

A total of 15 patients were treated with DMSO for NAC congestion during the study period. Three of those patients were treated for bilateral congestion, for a total of 18 NACs. Patient characteristics are reported in Table 1. Only one patient was a current smoker at the time of surgery, and one patient had a history of hypertension. Two patients were immunocompromised secondary to ongoing chemotherapy.

Of the 18 congested NACs, 15 (83.3%) healed with DMSO as the primary intervention (Table 2). None of the NACs were converted to a free nipple graft, but two were

**Table 1. Patient Characteristics**

	Overall (N = 15)
Age, mean (SD)	53.1 (9.3)
BMI, mean (SD)	26.8 (6.0)
Smoking	1 (6.7%)
Diabetes	0 (0.0%)
Hypertension	1 (6.7%)
Chronic kidney disease	0 (0.0%)
Coronary artery disease	0 (0.0%)
Immunocompromised	2 (13.3%)
Unilateral versus bilateral	
Unilateral	3 (20.0%)
Bilateral	12 (80.0%)

**Table 2. DMSO Treatment and NAC Healing**

	Overall (N = 18)
Healed	15 (83.3%)
Converted to graft	0 (0.0%)
Sutures released	2 (11.1%)
Length of DMSO use (d)	
Mean (SD)	9.4 (8.5)
Range	1.0–22.0
Time to heal (d)	
Mean (SD)	9.9 (9.6)
Range	1.0–28.0
Complications from DMSO	0 (0.0%)

addressed with intraoperative suture release. The average length of DMSO treatment was  $9.4 \pm 8.5$  days (mean  $\pm$  SD); NAC healing took place over  $9.9 \pm 9.6$  days (Table 2). There were no complications related to DMSO treatment.

The 15 healed NACs were compared with the three that did not heal with DMSO across a number of factors known to influence wound healing (Table 3). BMI was significantly greater in patients with nonhealing NACs ( $25.7 \pm 4.8$  versus  $32.5 \pm 6.8$  kg/m<sup>2</sup>,  $P = 0.049$ ). None of the other variables—age, smoking status, history of hypertension, immunocompromised state, laterality, length of DMSO use, or suture release—were significantly different between the two groups.

A more detailed description of each of the 15 patients treated with DMSO is reported in Supplemental Digital Content 1 (<http://links.lww.com/PRSGO/C226>). The surgeries preceding NAC congestion included nipple-sparing mastectomies, reduction mammoplasties, mastopexies, exchange or removal of tissue expanders or implants, and an autologous breast reconstruction. Of the three cases in which NAC congestion did not resolve with

**Table 3. Univariate Analysis of Factors Related to NAC Healing**

Healed (N = 15)	Not Healed (N = 3)		P
Age, mean (SD)	53.1 (9.1)	52.0 (5.3)	0.850
BMI, mean (SD)	25.7 (4.8)	32.5 (6.8)	0.049
Smoking	1 (6.7%)	0 (0.0%)	0.645
Hypertension	1 (6.7%)	0 (0.0%)	0.645
Immunocompromised	2 (13.3%)	1 (33.3%)	0.396
Unilateral versus bilateral			0.180
Unilateral	9 (60.0%)	3 (100.0%)	
Bilateral	6 (40.0%)	0 (0.0%)	
Length of DMSO use (d)			0.703
Mean (SD)	9.8 (8.5)	7.7 (9.9)	
Sutures released	1 (6.7%)	1 (33.3%)	0.180

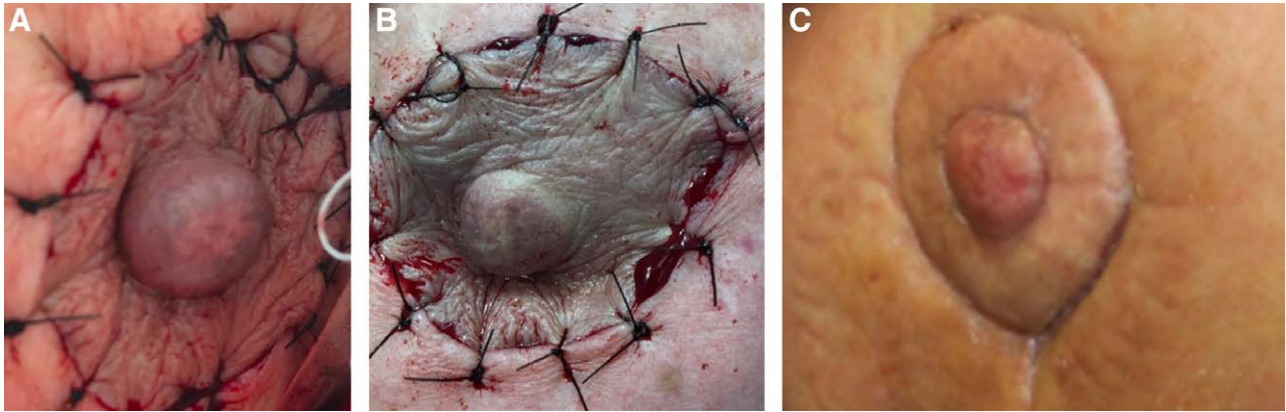
DMSO treatment alone, two (patients 7 and 11) required NAC debridement; patient 9 healed but only after receiving 16 days of HBOT following three days of DMSO application. Patient 7 underwent primary debridement for a periareolar infection; DMSO was attempted for only 1 day prior to definitive debridement of the entire NAC. Patient 11's congested NAC was treated with DMSO for 19 days following unilateral deep inferior epigastric perforator flap breast reconstruction but failed to heal despite adjunctive application of Silvadene (Pfizer, New York, N.Y.) and Aquaphor ointment (Beiersdorf, Hamburg, Germany).

Patients 9 and 14 were treated with suture release intraoperatively. Patient 9 healed with HBOT; patient 14 healed with DMSO alone. Patient 3 was treated with nitroglycerin ointment (Nitro-Bid 2%, Savage Laboratories, Melville, N.Y.) and DMSO concurrently. She was unable to follow-up regularly and is only known to have healed at some point during a 77-day period. The only other adjunct used was Medihoney (Integra LifeSciences, Plainsboro, N.J.), an antimicrobial wound dressing containing 80% Leptospermum honey and 20% gelling agents (patient 15). Photographs of patient 2 (Fig. 1) and patient 15 (Fig. 2) are included to visually convey the improvements in NAC congestion/necrosis we observed with DMSO treatment.

## DISCUSSION

The series of cases presented here support a potential role for topical DMSO in the treatment of NAC congestion following breast surgery. Of the 18 congested NACs in our study, 15 (83.3%) healed completely with DMSO as the primary treatment; two NACs became necrotic and required debridement and one healed following treatment with HBOT. Of the two NACs injuries that failed to heal, one originated from a periareolar wound infection and was treated with DMSO for a single day before being debrided. In the other case, the patient underwent nipple-sparing mastectomy performed by a separate surgical oncology team, followed by a deep inferior epigastric artery perforator flap breast reconstruction. NAC and mastectomy skin flap necrosis was noted in the immediate postoperative period and failed to heal despite DMSO therapy. Importantly, among all 18 treated patients, we observed no complications or side effects that could be plausibly attributed to the use of DMSO.

Failure to preserve the NAC during breast surgery results in loss of a functional and aesthetically distinctive structure that can be approximated but never perfectly matched by reconstructive methods. The NAC is primarily supplied by perforators of the internal mammary artery with lesser contributions from the lateral mammary branches of the lateral thoracic artery and inferior mammary branches of the anterior intercostal arteries.<sup>1,13</sup> The nipple is most reliably drained by the superomedial/medial and inferior pedicles via superficial veins that course directly underneath the dermis.<sup>2</sup> As a result of its superficiality, the NAC's venous network is more likely to be disrupted during breast surgery, resulting in problems with outflow more often than inflow.<sup>1</sup> Venous obstruction can also be caused by kinking or compression of the pedicle, excessively tight closure, or hematoma.<sup>3</sup> Factors



**Fig. 1.** Right NAC of patient 2 after bilateral breast implant removal and mastopexy, appearing congested on postoperative day 0 (A and B) and fully salvaged 19 days later, following 12 days of DMSO treatment (C).

that have been associated with NAC necrosis include age, higher BMI (as seen in our study), greater breast volume, smoking, and diabetes.<sup>3,14,15</sup> When NAC congestion is detected early, every effort should be made to prevent irreversible, full-thickness injury. Release of periareolar sutures may help relieve pressure compressing venous outflow; intraoperative detection of NAC compromise can also be addressed with conversion to a free nipple graft, though this decision must weigh the consequent loss of nipple sensation and potentially poor aesthetic results. Additionally, a number of topical and systemic treatments have been proposed to induce vasodilation and improve drainage of blood from the NAC.

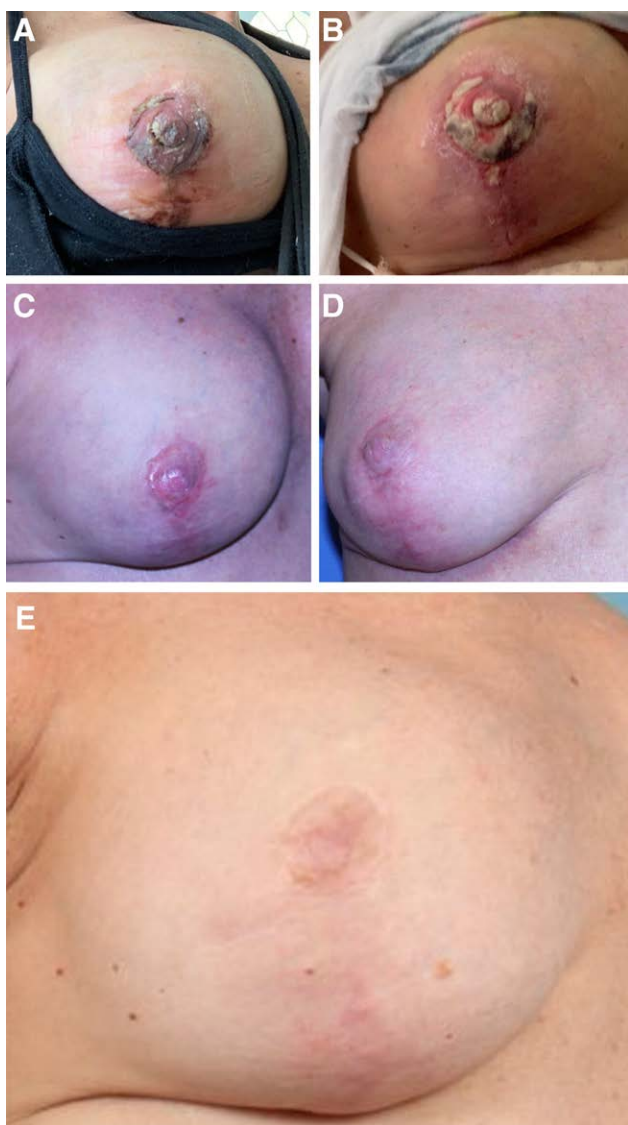
DMSO is a colorless liquid most commonly used for its polar, aprotic property, which allows it to dissolve a wide range of polar and nonpolar small molecules. DMSO has long been used as a vehicle for other compounds in basic science research and, in the 1960s, was found to readily penetrate the skin.<sup>16–18</sup> Subsequent clinical experiments showed that DMSO had local anti-inflammatory properties that were effective in treating cutaneous scleroderma, fingertip ischemia, and ulceration, keloids and hypertrophic scars.<sup>18–20</sup> Animal studies revealed that DMSO possessed membrane penetrating, anti-inflammatory, analgesic, and vasodilatory properties, and a number of rat studies demonstrated circulatory improvement in pedicle flaps treated with DMSO solution.<sup>10,21–23</sup> In veterinary medicine, DMSO has long been used in topical and intravenous forms to treat a variety of ailments, including joint swelling,<sup>24</sup> spinal cord injury,<sup>25</sup> laminitis (hoof inflammation),<sup>26</sup> muscle trauma,<sup>27</sup> and hypoxic damage to various tissues following infarction.<sup>28</sup> In 1996, a randomized controlled trial by Rand-Luby et al showed that application of topical 60% DMSO to human mastectomy skin flaps reduced the average area of flap ischemia by approximately 63%.<sup>29</sup> Celen et al performed a similar study and found that topical DMSO reduced the weight of necrotic tissue in mastectomy flap edges, without any major side effects.<sup>30</sup> Despite these findings, DMSO is currently only FDA-approved to treat interstitial cystitis via intravesicular administration of a 50% liquid solution.<sup>18</sup>

The mechanism by which DMSO improves circulation and wound healing is not fully understood. It is known to cause histamine release by mast cells and also increase prostaglandin E1 production, both ways in which it may induce vasodilation.<sup>23,30,31</sup> DMSO is also a hydroxyl-inactivating compound, giving it the ability to reduce ischemia-reperfusion injury by scavenging free radical species.<sup>32</sup> Its local anesthetic effects may also reduce oxidative stress by tempering cellular excitation.<sup>30</sup> It is possible that a number of these effects work in concert to yield the results seen in the studies mentioned above and our experience presented here. Indeed, even a single dose of DMSO, either intra- or immediately postoperatively seems to be effective in our experience, perhaps alleviating vasospasm and oxidative stress during this critical time period. The half-life of DMSO is 16 hours in the blood and it is estimated to be completely cleared within 72 hours of ending treatment.<sup>33,34</sup>

While localized erythema, edema, and pruritis have been associated with topical DMSO—likely due to histamine release—these side effects are rare and transient.<sup>23,30</sup> More common is a garlic-like odor from the breath, though this side effect persists only during treatment and was not reported by any patients in our study.<sup>18,30</sup> It appears, then, that topical DMSO is safe and well-tolerated, with several beneficial effects for congested flaps and healing wounds.

A number of other therapies exist for the treatment of pedicle flap congestion that should be discussed alongside DMSO. Medicinal leech therapy has been used for decades to relieve acute venous congestion in various types of flaps, including the NAC. The research on leech therapy for congested flaps consists mainly of small case series that have reported results similar to ours.<sup>35–39</sup> Leeches, however, are not a benign treatment. The most recent systematic review showed that nearly 50% of patients treated with leeches required blood transfusion and 14% developed infections.<sup>39</sup> Due to the risk of *Aeromonas* infection, patients are typically treated prophylactically with fluoroquinolones, which carry their own risks of complications.

HBOT is another treatment modality used in the management of congested flaps. HBOT is thought to increase oxygen tension in tissues, promoting neovascularization



**Fig. 2.** Right NAC of patient 15 following bilateral implant exchange and right-sided mastopexy on postoperative day 1 (A), 5 (B), and 14 (C). The NAC appears well-healed at 3 months postoperative (D) and after 2.5 years (E).

and postischemic tissue survival.<sup>40</sup> Support for HBOT in plastic surgery is based largely on animal studies and small trials that have demonstrated flap and graft salvage rates up to 89%.<sup>41–47</sup> A case series by Shuck et al showed successful salvage of eight NACs treated with HBOT over an average of 35.9 days.<sup>46</sup> However, HBOT is both expensive and inconvenient for patients. Treatment times are typically 90 minutes to 4 hours with per-session costs of \$100 to \$1000.<sup>48,49</sup> Still, it appears that DMSO and HBOT may play complementary roles: DMSO's vasodilatory and free radical scavenging properties are likely more effective in the immediate postoperative period, while the angiogenesis and fibroblast formation promoted by HBOT may facilitate more long-term wound healing. Indeed, patient 9 in our study healed with 3 days of DMSO treatment followed by 16 days of HBOT.

The most commonly used topical treatment for breast skin necrosis is NTG ointment. NTG is a vasodilator that preferentially affects veins, relieving congestion in threatened skin flaps. Topical NTG has been well studied in the prevention of mastectomy flap necrosis, with a recent meta-analysis showing that NTG significantly improved rates of full-thickness flap necrosis over placebo, but did not prevent superficial flap necrosis (ie, congestion).<sup>4</sup> The studies included in that meta-analysis tested NTG as a preventative measure administered to all patients following mastectomy, not as an intervention for threatened flaps. Dent et al studied the use of NTG in the treatment of 65 cases of NAC ischemia following nipple-sparing mastectomy, reporting a 100% or 71% salvage rate for partial-thickness or full-thickness ischemia, respectively.<sup>14</sup> NTG, even in its topical form, does carry a risk for adverse effects, including severe headache and hypotension, especially in older patients and patients taking antihypertensive medications.<sup>15</sup> Otherwise, however, NTG shares many of DMSO's favorable attributes: rapid onset, effective penetration into the skin, ease of application, and low cost. Given the findings in this pilot study, future research should evaluate whether DMSO's vasodilatory and free radical scavenging properties give it an advantage over NTG in relieving NAC congestion and preventing necrosis.

The primary limitations of our study are small sample size and lack of a comparison group. Small sample size is characteristic of nearly all studies on this topic due to the relatively low rate of NAC ischemia overall. Because any comparison group would be very small and, therefore, have minimal statistical value, the authors chose to use every case of NAC congestion to test the efficacy of DMSO. Another limitation of the study is its heterogeneity in terms of surgery types and DMSO application frequency and length of use. This heterogeneity can be partly attributed to the study's retrospective nature, and the impetus by the authors to include as much data as possible on this therapy for an uncommon problem.

## CONCLUSIONS

Necrosis of the NAC is an uncommon but functionally and aesthetically devastating complication of breast surgery. Due to the superficial nature of the nipple's venous drainage network, circulatory compromise of the NAC is typically a result of venous insufficiency, causing NAC congestion. In this pilot study, 15 of the 18 congested NACs treated primarily with topical DMSO healed without any other postoperative intervention. DMSO, which has vasodilatory and free radical scavenging properties, offers a convenient and inexpensive alternative to therapies like medicinal leeches and HBOT, without major side effects. Future studies should prospectively compare DMSO against NTG ointment to determine whether DMSO should be favored over the current standard for preventing NAC necrosis.

*Amanda A. Gosman, MD*

Department of Plastic Surgery, UC San Diego Health  
200 West Arbor Drive MC 8890  
San Diego, CA 92103-8890

## REFERENCES

- van Deventer PV, Page BJ, Graewe FR. The safety of pedicles in breast reduction and mastopexy procedures. *Aesthetic Plast Surg.* 2008;32:307–312.
- le Roux CM, Pan WR, Matousek SA, et al. Preventing venous congestion of the nipple-areola complex: an anatomical guide to preserving essential venous drainage networks. *Plast Reconstr Surg.* 2011;127:1073–1079.
- Handel N, Yegiyants S. Managing necrosis of the nipple areolar complex following reduction mammoplasty and mastopexy. *Clin Plast Surg.* 2016;43:415–423.
- Wang P, Gu L, Qin Z, et al. Efficacy and safety of topical nitroglycerin in the prevention of mastectomy flap necrosis: a systematic review and meta-analysis. *Sci Rep.* 2020;10:6753.
- Dunn CL, Brodland DG, Griego RD, et al. A single post-operative application of nitroglycerin ointment does not increase survival of cutaneous flaps and grafts. *Dermatol Surg.* 2000;26:425–427.
- Nichter LS, Sobieski MW, Edgerton MT. Efficacy of topical nitroglycerin for random-pattern skin-flap salvage. *Plast Reconstr Surg.* 1985;75:847–852.
- Price MA, Pearl RM. Multiagent pharmacotherapy to enhance skin flap survival: lack of additive effect of nitroglycerin and allopurinol. *Ann Plast Surg.* 1994;33:52–56.
- Aral M, Tuncer S, Şencan A, et al. The effect of thrombolytic, anticoagulant, and vasodilator agents on the survival of random pattern skin flap. *J Reconstr Microsurg.* 2015;31:487–492.
- Kollerup Madsen B, Hilscher M, Zetner D, et al. Adverse reactions of dimethyl sulfoxide in humans: a systematic review. *F1000Res.* 2018;7:1746.
- McFarlane RM, Laird JJ, Lamon R, et al. Evaluation of dextran and DMSO to prevent necrosis in experimental pedicle flaps. *Plast Reconstr Surg.* 1968;41:64–70.
- Young VL, Boswell CB, Centeno RF, et al. DMSO: applications in plastic surgery. *Aesthet Surg J.* 2005;25:201–209.
- Wall H. What's the Deal (Wo)Man? XXcuting Plastic Surgery Myths Panel. Paper presented at: American Society for Aesthetic Plastic Surgery Meeting; May 18, 2019; New Orleans, LA.
- Vazquez OA, Becker H. Healing of bilateral nipple areolar complex necrosis by secondary intention. *Cureus.* 2020;12:e9025.
- Dent BL, Small K, Swistel A, et al. Nipple-areolar complex ischemia after nipple-sparing mastectomy with immediate implant-based reconstruction: risk factors and the success of conservative treatment. *Aesthet Surg J.* 2014;34:560–570.
- Gdalevitch P, Van Laeken N, Bahng S, et al. Effects of nitroglycerin ointment on mastectomy flap necrosis in immediate breast reconstruction: a randomized controlled trial. *Plast Reconstr Surg.* 2015;135:1530–1539.
- Jacob SW, Bischel M, Herschler RJ. Dimethyl sulfoxide (DMSO): a new concept in pharmacotherapy. *Curr Ther Res Clin Exp.* 1964;6:134–135.
- Horita A, Weber LJ. Skin penetrating property of drugs dissolved in DIMETHYLSULFOXIDE (DMSO) and other vehicles. *Life Sci (1962).* 1964;3:1389–1395.
- Capriotti K, Capriotti JA. Dimethyl sulfoxide: history, chemistry, and clinical utility in dermatology. *J Clin Aesthet Dermatol.* 2012;5:24–26.
- Scherbel AL, McCormack LJ, Poppo MJ. Alteration of collagen in generalized scleroderma (progressive systemic sclerosis) after treatment with dimethyl sulfoxide: preliminary report. *Cleve Clin Q.* 1965;32:47–56.
- Engel MF. Dimethyl sulfoxide (DMSO) in clinical dermatology. *South Med J.* 1966;59:1318–1319.
- Adamson JE, Horton CE, Crawford HH, et al. The effects of dimethyl sulfoxide on the experimental pedicle flap: a preliminary report. *Plast Reconstr Surg.* 1966;37:105–110.
- Haller J, Trachy R, Cummings CW. Effect of dimethyl sulfoxide on island flap perfusion and survival in rats. *Arch Otolaryngol Head Neck Surg.* 1987;113:859–863.
- Brayton CF. Dimethyl sulfoxide (DMSO): a review. *Cornell Vet.* 1986;76:61–90.
- Smith G, Bertone AL, Kaeding C, et al. Anti-inflammatory effects of topically applied dimethyl sulfoxide gel on endotoxin-induced synovitis in horses. *Am J Vet Res.* 1998;59:1149–1152.
- Levine JM, Cohen ND, Heller M, et al. Efficacy of a metalloproteinase inhibitor in spinal cord injured dogs. *PLoS One.* 2014;9:e96408.
- Mitchell CF, Fugler LA, Eades SC. The management of equine acute laminitis. *Vet Med (Auckl).* 2015;6:39–47.
- Douwes RA, van der Kolk JH. [Dimethylsulfoxide (DMSO) in horses: a literature review]. *Tijdschr Diergeneesk.* 1998;123:74–80.
- Hillidge CJ. The case for dimethyl sulphoxide (DMSO) in equine practice. *Equine Vet J.* 1985;17:259–261.
- Rand-Luby L, Pommier RF, Williams ST, et al. Improved outcome of surgical flaps treated with topical dimethylsulfoxide. *Ann Surg.* 1996;224:583–9; discussion 589.
- Celen O, Yildirim E, Berberoğlu U. Prevention of wound edge necrosis by local application of dimethylsulfoxide. *Acta Chir Belg.* 2005;105:287–290.
- Carpenter RJ, Angel MF, Morgan RF. Dimethyl sulfoxide increases the survival of primarily ischemic island skin flaps. *Otolaryngol Head Neck Surg.* 1994;110:228–231.
- Houwing R, Peeters IG, Cp T, et al. A systematic review of the efficacy of topical skin application of dimethyl sulfoxide on wound healing and as an anti-inflammatory drug. *Wounds UK.* 2003;15:361–370.
- Gad SE, Sullivan DW. Dimethyl Sulfoxide (DMSO). In: Wexler P, ed. *Encyclopedia of Toxicology.* 3rd ed. Oxford: Academic Press; 2014:166–168.
- Layman DL, Jacob SW. The absorption, metabolism and excretion of dimethyl sulfoxide by rhesus monkeys. *Life Sci.* 1985;37:2431–2437.
- Butt AM, Ismail A, Lawson-Smith M, et al. Leech therapy for the treatment of venous congestion in flaps, digital re-plants and revascularizations – A two-year review from a regional centre. *J Ayub Med Coll Abbottabad.* 2016;28:219–223.
- Freeman M, Carney M, Matatov T, et al. Leech (*Hirudo medicinalis*) therapy for the treatment of nipple-areolar complex congestion following breast reduction. *Eplasty.* 2015;15:ic45.
- Gross MP, Apesos J. The use of leeches for treatment of venous congestion of the nipple following breast surgery. *Aesthetic Plast Surg.* 1992;16:343–348.
- Riede F, Koenen W, Goerdt S, et al. Medicinal leeches for the treatment of venous congestion and hematoma after plastic reconstructive surgery. *J Dtsch Dermatol Ges.* 2010;8:881–888.
- Whitaker IS, Oboumarzouk O, Rozen WM, et al. The efficacy of medicinal leeches in plastic and reconstructive surgery: a systematic review of 277 reported clinical cases. *Microsurgery.* 2012;32:240–250.
- Thom SR. Hyperbaric oxygen: its mechanisms and efficacy. *Plast Reconstr Surg.* 2011;127 Suppl 1:131S–141S.
- Shulman AG, Krohn HL. Influence of hyperbaric oxygen and multiple skin allografts on the healing of skin wounds. *Surgery.* 1967;62:1051–1058.
- Zamboni WA, Roth AC, Russell RC, et al. The effect of hyperbaric oxygen on reperfusion of ischemic axial skin flaps: a laser Doppler analysis. *Ann Plast Surg.* 1992;28:339–341.
- Liu X, Yang J, Li Z, et al. Hyperbaric oxygen preconditioning promotes neovascularization of transplanted skin flaps in rats. *Int J Clin Exp Pathol.* 2014;7:4734–4744.
- Perrins DJ. Influence of hyperbaric oxygen on the survival of split skin grafts. *Lancet.* 1967;1:868–871.

45. Bowersox J, Strauss M, Hart G. Clinical experience with hyperbaric oxygen therapy in the salvage of ischemic skin flaps and grafts. 1986.
46. Shuck J, O’Kelly N, Endara M, et al. A critical look at the effect of hyperbaric oxygen on the ischemic nipple following nipple sparing mastectomy and implant based reconstruction: a case series. *Gland Surg.* 2017;6:659–665.
47. Chang C, White C, Katz A, et al. Management of ischemic tissues and skin flaps in Re-Operative and complex hypospadias repair using vasodilators and hyperbaric oxygen. *J Pediatr Urol.* 2020;16:672.e1–672.e8.
48. Guo S, Counte MA, Gillespie KN, et al. Cost-effectiveness of adjunctive hyperbaric oxygen in the treatment of diabetic ulcers. *Int J Technol Assess Health Care.* 2003;19:731–737.
49. Chuck AW, Hailey D, Jacobs P, et al. Cost-effectiveness and budget impact of adjunctive hyperbaric oxygen therapy for diabetic foot ulcers. *Int J Technol Assess Health Care.* 2008;24:178–183.