

## Horseshoe Lung Associated With Holt-Oram Syndrome

Xu Qin<sup>1</sup>; Wang Wei<sup>1</sup>; Gong Fangqi<sup>1,\*</sup>

<sup>1</sup>Department of Cardiology, Children's Hospital, Zhejiang University School of Medicine, Hangzhou, China

\*Corresponding author: Gong Fangqi, Department of Cardiology, Children's Hospital, Zhejiang University School of Medicine, Hangzhou, China. E-mail: gongfangqi@zju.edu.cn

**Received:** September 11, 2014; **Revised:** December 22, 2014; **Accepted:** January 10, 2015

**Keywords:** Horseshoe Lung; Lung Hypoplasia; Holt-Oram syndrome

### Dear Editor,

Horseshoe lung is an uncommon congenital malformation in which the bases of the right and the left lungs are fused to each other by a narrow isthmus posterior to the cardiac apex (1). There have been 52 case reports in the English literature. Holt-Oram syndrome is characterized by cardiac septation defects and pre-axial radial ray abnormalities (2). To our knowledge, it is the first report of horseshoe lung combined with Holt-Oram syndrome.

An 18-month-old boy was admitted to our hospital because of discovered heart murmur at local hospital. He was born to a G1P1, 25-year-old mother at 39 weeks' gestation at a local hospital. The pregnancy and prenatal history were uneventful. He was naturally delivered with a birth weight of 3400 g, and at admission he had a weight of 10 kg and height of 83 cm. He has mild respiratory distress since he was born but without cyanosis. There was no family history of congenital anomalies.

Physical examination revealed a sloping left shoulder, compressed left thorax, malformed left upper-extremity and asymmetric face when crying. Tachypnea, intercostal retractions, decreased breathing sounds over the left side of the chest, and a systolic murmur grade 3/6 over lower left sternal border were noted. Malformations of the left upper arm included inward twisting of left wrist and absence of left thumb.

Radiology of extremity showed absence of left radius (Figure 1). Chest X ray showed a poorly aerated right lung, ten left ribs, left side deviation of the cardiothymic shadow. Hemivertebra or H-shaped vertebra was formed from the sixth cervical vertebra to the sixth thoracic vertebra. Thorax CT scan showed horseshoe lung: a hypoplastic left lung and hyperinflation of the right lung with an image of continuity between the lower lobes (Figure 2). Slightly tracheostenosis was

found under glottis level. Cardiac ultrasound showed ventricular septal defect (VSD), patent ductus arteriosus (PDA) and pulmonary hypertension. In addition, karyotype test was undertaken with a result of 46XY 15P+. Unfortunately no genetic tests are available for further investigation. He received patch repair of VSD and PDA ligation surgery. In operation the absence of left pulmonary artery was noted. The patient was uneventfully discharged after the operation with a long term follow up.

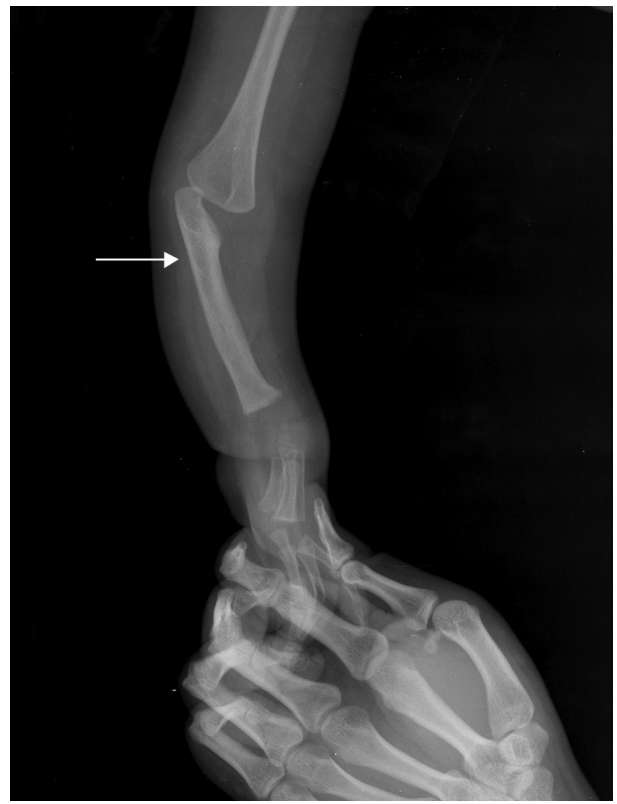Horseshoe lung, first described in 1962, remains a rare clinical finding, consisting of lung hypoplasia and/or vascular anomalies. Pulmonary arteriography and chest computed tomography can be applied to confirm this diagnosis (1). Most of cases reported were associated with scimitar syndrome and a few were associated with other cardiovascular anomalies including atrial septal defect, ventricular septal defect, tetralogy of Fallot, and hypoplastic left ventricle (3). Right lung hypoplasia is more common and left lung hypoplasia is seldom reported (4). In our case, there was no cardiac dextrorotation or dextroversion and no apparent right lung hypoplasia. Instead, Holt-Oram syndrome featured with heart and hand abnormalities was found in association.

Holt-Oram syndrome is an autosomal dominant disorder characterized by upper arm skeletal abnormalities with congenital cardiac defects. The causative gene has been shown to be TBX5, located on 12q24.1, which encodes a transcription factor. More than 70% of individuals who meet strict diagnostic criteria have an identifiable mutation in the TBX5 gene (5). Besides, genetic heterogeneity has been confirmed by cases having nothing to do with TBX5. Several patients, which have been reported with presentations compatible to Holt-Oram syndrome, have been found to be carrying

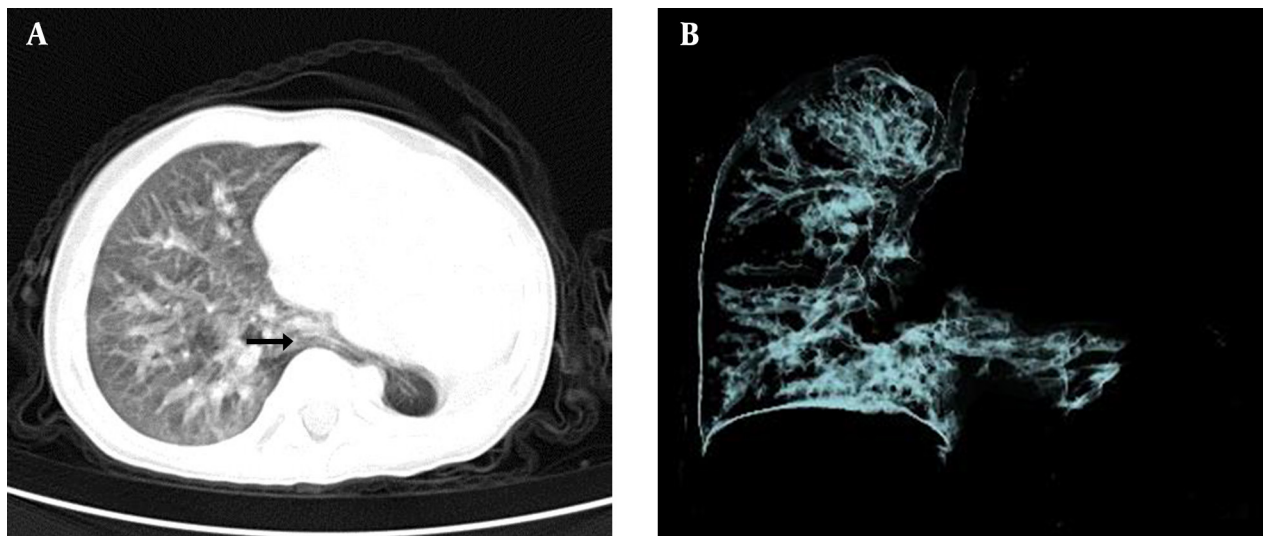
chromosome structure changes other than TBX5 mutation (6-8). As in our patient, hand-heart anomalies were typical manifestations of Holt-Oram syndrome, including absent radius, absent partial carpal bones and congenital cardiac defects. We found karyotype of 46XY 15P+ in our patient though without gene test for TBX5. We speculated that overproduction of materials encoded by 15P may effect heart-hand embryogenesis and finally cause Holt-Oram syndrome.

On the other hand, pulmonary anomalies are rare in Holt-Oram syndrome. Right lung agenesis associated with Holt-Oram syndrome caused by a de novo mutation in the TBX5 gene has been reported (9). However, horseshoe lung in association is the first case in literature. The association between Holt-Oram syndrome and pulmonary abnormality requires further investigation. Studies of the TBX5 gene in a variety of species showed that this transcriptional factor may be important in the development of forelimb, heart, eye, trachea, and pulmonary vasculatures (10, 11). It is probable that some kind of gene located on 15P may directly or indirectly be involved in embryogenesis of the lung.

In conclusion, we report on the first case of horseshoe lung associated with Holt-Oram syndrome. Our findings further expand the phenotypic spectrum of horseshoe lung and Holt-Oram syndrome and suggest that chromosome duplication of 15P may cause this phenotype.



**Figure 1.** Radiograph of the Upper Extremity Revealed Absence of Left Radial Bones (Arrow)



**Figure 2.** CT Axial: CT Image (A) and 3-D Reconstruction Image (B) Demonstrate Fusion of the Posterobasal Portions of the Right and the Left Lungs via a Parenchymal Isthmus (Arrow) Behind the Heart to Form the Horseshoe Lung. The Heart is Displaced to the Left Because of the Left Lung Hypoplasia

## References

1. Horseshoe lung associated with rare bilateral variant of scimitar syndrome: demonstration by 64-slice MDCT angiography. Akay HO, Kervancioglu M, Nazaroğlu H, Katar S, Ozmen CA, Kilinc I, et al. *Pediatr Radiol*. 2008;38(5):563.
2. Genetic heterogeneity of heart-hand syndromes. Basson CT, Solomon SD, Weissman B, MacRae CA, Poznanski AK, Prieto F, et al. *Circulation*. 1995;91(5):1326.
3. Horseshoe lung associated with unique left pulmonary vein: an unreported association. Salerno T, Guccione P, Malena S, Cutrera R. *Pediatr Cardiol*. 2010;31(6):905.
4. Horseshoe lung associated with left-lung hypoplasia, left pulmonary artery sling and bilateral agenesis of upper lobe bronchi. Oguz B, Alan S, Ozcelik U, Haliloglu M. *Pediatr Radiol*. 2009;39(9):1002.
5. TBX5 genetic testing validates strict clinical criteria for Holt-Oram syndrome. McDermott DA, Bressan MC, He J, Lee JS, Aftimos S, Brueckner M, et al. *Pediatr Res*. 2005;58(5):981.
6. Holt-Oram syndrome in two generations with translocation t(9;15)(p12;q11.2). Caglayan AO, Koklu E, Saatci C, Gunes T, Ozkul Y, Narin N, et al. *Ann Saudi Med*. 2008;28(3):209.
7. [Holt-Oram syndrome with chromosomopathy (author's transl)]. Gonzalez Espinosa C, Artiles Perez L, Garcia Baez M, Otero Gomez A, Garcia Miranda JL. *An Esp Pediatr*. 1982;16(1):77.
8. Molecular characterization of a 14q deletion in a boy with features of Holt-Oram syndrome. Le Meur N, Goldenberg A, Michel-Adde C, Drouin-Garraud V, Blaysat G, Marret S, et al. *Am J Med Genet A*. 2005;134(4):439.
9. Holt-Oram syndrome with right lung agenesis caused by a de novo mutation in the TBX5 gene. Tseng YR, Su YN, Lu FL, Jeng SF, Hsieh WS, Chen CY, et al. *Am J Med Genet A*. 2007;143A(9):1012.
10. Developmental regulation of Tbx5 in zebrafish embryogenesis. Begemann G, Ingham PW. *Mech Dev*. 2000;90(2):299.
11. Fibroblast growth factor 10 plays a causative role in the tracheal cartilage defects in a mouse model of Apert syndrome. Tiozzo C, De Langhe S, Carraro G, Alam DA, Nagy A, Wigfall C, et al. *Pediatr Res*. 2009;66(4):386.