

Feasibility and reliability of point-of-care pocket-sized echocardiography

Garrett Newton Andersen^{1,2*}, Bjørn Olav Haugen^{2,3}, Torbjørn Graven¹, Øyvind Salvesen⁴, Ole Christian Mjølstad^{2,3}, and Håvard Dalen^{1,2}

¹Levanger Hospital, Nord-Trøndelag Health Trust, Levanger, Norway; ²MI Laboratory, Department of Circulation and Medical Imaging, Norwegian University of Science and Technology, Box 8905, 7491 Trondheim, Norway; ³Department of Cardiology, St Olavs Hospital/Trondheim University Hospital, Trondheim, Norway; and ⁴Department of Cancer Research and Molecular Medicine, Norwegian University of Science and Technology, Trondheim, Norway

Received 3 May 2011; accepted after revision 22 June 2011; online publish-ahead-of-print 2 August 2011

Aims

To study the reliability and feasibility of point-of-care pocket-sized echocardiography (POCKET) at the bedside in patients admitted to a medical department at a non-university hospital.

Methods and results

One hundred and eight patients were randomized to bedside POCKET examination shortly after admission and later high-end echocardiography (HIGH) in the echo-lab. The POCKET examinations were done by cardiologists on their ward rounds. Assessments of global and regional left ventricular (LV) function, right ventricular (RV) function, valvular function, left atrial (LA) size, the pericardium and pleura were done with respect to effusion and measurements of inferior vena cava (IVC) and abdominal aorta (AA) were performed. Correlations between POCKET and HIGH/appropriate radiological technique for LV function, AA size and presence of pericardial effusion were almost perfect, with $r \geq 0.92$. Strong correlation ($r \geq 0.81$) was shown for RV and valvular function, except for grading of aortic stenosis ($r = 0.62$). The correlations were substantial for IVC and LA dimensions. Median time used for bedside screening with POCKET was 4.2 min (range: 2.3–13.0). There was excellent feasibility for cardiac structures and pleura, which was assessed to satisfaction in $\geq 94\%$ of patients. Lower feasibility (71–79%) was seen for the abdominal great vessels.

Conclusion

Point-of-care semi-quantitative evaluation of cardiac anatomy and function showed high feasibility and correlation with the reference method for most indices. Pocket-sized echocardiographic examinations of ~ 4 min length, performed at the bedside by experts, offers reliable assessment of cardiac structures, the pleural space and the large abdominal vessels.

Clinical trial registration: <http://www.clinicaltrials.gov>; unique ID: NCT01081210.

Keywords

Echocardiography • Pocket-size • Hand-held • Screening • Point-of-care ultrasound • Bedside

Introduction

With limited resources and an increasing need for speed in the health-care system, the advent of cheaper and more user friendly miniaturized ultrasound scanners is appealing. Pocket-sized scanners can now easily be brought to the patient, so-called point-of-care ultrasonography.¹ The recently published recommendations for the use of pocket-sized echocardiography

(POCKET) by the European Association of Echocardiography states that POCKET may serve as a tool for fast initial screening and as complement to the physical examination.² Further, POCKET may be used for the triage of the patient in need of a complete echocardiographic examination and has the potential to rearrange inpatient workflow and diagnostics.^{2–5}

Recent studies have shown good correlation between POCKET and high-end echocardiography (HIGH) in both outpatient cardiac

*Corresponding author. Tel: +47 48 22 25 66; fax: +47 72 82 83 72. Email: garrett.andersen@gmail.com

Published on behalf of the European Society of Cardiology. All rights reserved. © The Author 2011. For permissions please email: journals.permissions@oup.com.

The online version of this article has been published under an open access model. Users are entitled to use, reproduce, disseminate, or display the open access version of this article for non-commercial purposes provided that the original authorship is properly and fully attributed; the Journal, Learned Society and Oxford University Press are attributed as the original place of publication with correct citation details given; if an article is subsequently reproduced or disseminated not in its entirety but only in part or as a derivative work this must be clearly indicated. For commercial re-use, please contact journals.permissions@oup.com

clinics and echo-labs,^{4,6–8} which offer optimal conditions for echocardiography. Even though the pocket-sized ultrasound devices are designed for point-of-care ultrasonography, it is not known whether bedside examinations with inferior conditions for echocardiography are feasible and reliable. Thus, we aimed to study the feasibility and reliability of POKET as a bedside cardiovascular screening tool and adjunct to the physical examination in routine clinical ward rounds in patients admitted to a medical department.

Methods

Study population

One hundred and ninety-six patients admitted to the medical department at Levanger Hospital, Norway between March and September 2010 were scanned with POKET (Vscan; GE Vingmed, Horten, Norway) by one of the three experienced cardiologists on their regular on-call ward rounds. Selection was random, based solely on admission dates.

The specialist on call for general medicine at this hospital is either 1 of 3 cardiologists experienced in echocardiography or one of the 10 other specialists in internal medicine. Patients were only available for inclusion if one of the three cardiologists were on call the day the patients were admitted to hospital.

Patients admitted to the departments' cardiac unit (119 patients) were automatically referred to a subsequent HIGH examination. In addition, all patients from the non-cardiac units with standard indications for echocardiography were also referred and included in the analyses. Exclusion criteria included death or discharge before completed study protocol or withdrawal of consent. Patients were specifically not excluded due to poor image quality, previous illness or any other unspecified attribute. In total, 90 patients from the cardiac unit and 18 patients from the non-cardiac units underwent both POKET and HIGH and these 108 patients are included in the analyses.

Written informed consent was obtained. The study was approved by the Regional Committee for Medical and Health Research Ethics and conducted according to the Declaration of Helsinki.

Pocket-sized echocardiographic screening

The ultrasound screening was performed at the bedside with a pocket-sized ultrasound device, Vscan (GE Vingmed Ultrasound, Horten, Norway). The device weighs 390 g, including the phased-arrayed probe, which measures 135 × 73 × 28 mm. The device offers two-dimensional grey scale and live colour Doppler imaging. The image sector for echocardiographic imaging is 75°. The bandwidth ranges from 1.7 to 3.8 MHz and is automatically adjusted. An algorithm enables automatic storage and looping of a cardiac cycle without ECG signal.⁹ The length of recordings of other structures is predefined and limited to 2 s. Patient identification was performed by voice recording and the automatically assigned examination number. All images and recordings were saved on the device's micro-SD card and later transferred to a computer by commercial software (Gateway; GE Vingmed Ultrasound).

A standardized screening protocol was used. The cardiovascular screening by POKET was performed at the bedside with patients in a left-lateral decubitus and supine position. Assessment of left ventricular (LV) global and regional function, right ventricular (RV) size and function, valvular anatomy and function, and the pericardium were done from parasternal long- and short-axis and apical four-chamber, two-chamber and long-axis views. Global LV and RV functions were

classified online by visual assessment as: normal/near normal, moderate dysfunctional or severe dysfunctional, while regional LV function was classified as regional dysfunction present or not. Valvular pathology and dysfunction were classified as mild, moderate or severe by visual assessment from grey-scale and colour Doppler imaging. The area and intensity of the regurgitation jets assessed by colour Doppler were the most important for grading valvular regurgitations, while the grading of aortic stenosis was based on the degree of calcification and the movement of the cusps. Pericardial effusion was classified as present or not. The size of the left atrium was measured online on grey-scale parasternal long-axis images. An attempt was made in order to do the measurement at end systole. From the subxiphoid position, the abdominal aorta (AA) and inferior vena cava were assessed by grey-scale imaging. The AA was assessed distally to the bifurcation and classified as: no abdominal aortic aneurysm present or abdominal aortic aneurysm present, depending on whether the diameter exceeded 35 mm or not. In case of doubt by visual assessment, measurement was done by the device's calliper mode. The inferior vena cava diameter was measured end-expiratory within 2 cm from the right atrium orifice. All measurements of size were done on the POKET. With patients in a supine position, the pleura was assessed by grey-scale imaging from left and right lateral views, and the amount of pleural effusion was classified as: no pleural effusion, small-to-moderate amounts of pleural effusion or significant pleural effusion.¹⁰ All recordings were saved on the POKET and the time used for the screening was calculated as the time from start to end of the examination.

Validation of point-of-care pocket-sized echocardiography

HIGH was performed in the hospital's echo-lab, under optimal conditions, with a Vivid 7 scanner (GE Vingmed Ultrasound, Horten, Norway) using a 2.0-MHz phased-array transducer (M3S) with bandwidth 1.5–3.6 MHz. The scanner weighs 190 kg. Second harmonic imaging was used and the sector angle set to 90° as default, but was adjusted when appropriate. Storage and looping of cardiac cycles were ECG triggered. HIGH examinations were performed independently by one of four experienced cardiologists blinded to the results of POKET with a median time delay of 17.3 h. The same cardiovascular structures as described above were measured and classified according to the guidelines of the European Association of Echocardiography (EAE).^{11–15} Ejection fraction was measured by Simpson's rule from apical four-chamber and two-chamber views. Dimensions were measured by M-mode from parasternal recordings.¹⁴ Valvular pathology was graded according to the recommendations from the EAE.^{11–13} Additionally, imaging techniques such as computer tomography, magnetic resonance imaging or ultrasound were ordered according to standard care and performed at the Department of Radiology. For the analyses in the patients who underwent both echocardiographic and radiologic examinations, the radiologists' grading of pleural effusion and size of the AA was preferred compared with the echocardiography.

In a randomized subset of 20 study participants, the high-end echocardiographic recordings were reanalysed by a second cardiologist blinded to the original measurements in order to test inter-analyser variability.

Statistics

The basic characteristics are presented as mean ± standard deviation (SD) and range. The Spearman's rho (*r*) was used for comparison of the grading of pathology between the POKET and the HIGH or

radiologic examinations. Data are presented as r [95% confidence interval (CI)] with CI computed using bootstrapping. For comparison of continuous variables between the POCKET and the HIGH examinations, Pearson's ρ (r) was used. The reliability of HIGH is expressed by the coefficient of variation and was calculated as the within subjects SD of the two sets of observations, divided by the mean of the observations. A two-tailed $P < 0.05$ was considered significant. All statistical analyses were performed using SPSS for Windows (version 18.0, SPSS Inc., Chicago, IL, USA).

Results

Study population

Basic characteristics of the study population are shown in Table 1. Age was mean \pm SD (range) 69.1 ± 13.7 (20–92) years and 36% were female. Mean BMI was 27 ± 5 (17–44) kg/m^2 and LV ejection fraction was 60 ± 15 (19–86)%, respectively.

Pocket-sized echocardiography

Median time used for POCKET was 4.2 min (range: 2.3–13.0). Image quality and interpretation were generally good (Table 2). Specifically a high feasibility ($\geq 98\%$) for cardiac structures was seen, whilst it was somewhat lower for non-cardiac structures such as the intra-abdominal vessels ($\geq 71\%$).

The correlations of semi-quantitative assessment of cardiovascular structures and function indices between POCKET and HIGH are shown in Tables 3 and 4. LV regional and global function and RV size and function showed almost perfect correlation with r (95% CI): 0.92 (0.83–0.99), 0.95 (0.90–0.99) and 0.85 (0.65–1.0), respectively. Classification of valvular function indices between POCKET and HIGH correlated well for aortic, mitral and tricuspid regurgitations ($r \geq 0.81$). Grading of aortic valve calcification or stenosis showed substantial correlation with r (95% CI): 0.62 (0.42–0.79). Table 4

Table 1 Basic characteristics of the 108 study participants

Variable	Mean \pm SD (range) ^a
Age, years	69.1 \pm 13.7 (20–92)
Women, n (%)	39 (36%)
Height (cm)	172 \pm 9 (146–189)
Body mass index (kg/m^2)	27 \pm 5 (17–44)
Systolic blood pressure (mm Hg)	146 \pm 32 (58–250)
Diastolic blood pressure (mm Hg)	81.5 \pm 20 (32–161)
Heart rate (bpm)	78.7 \pm 24 (29–145)
Atrial fibrillation, n (%)	22 (20%)
Prior hypertension, n (%)	39 (36%)
Prior diabetes, n (%)	18 (17%)
Prior myocardial infarction, n (%)	33 (31%)
Prior angina, n (%)	27 (25%)
Prior heart failure, n (%)	12 (11%)
Prior peripheral vessel disease, n (%)	13 (12%)
Prior stroke, n (%)	12 (11%)

^aData are presented as mean \pm SD (range) unless otherwise specified.

Table 2 Feasibility of point-of-care pocket-sized echocardiography

Structure	Assessed to satisfaction, n (%)
Left ventricle	108 (100)
Right ventricle	106 (98)
Pericardial space	108 (100)
Left atrium	105 (97)
Heart valves ^a	≥ 106 (98)
Pleural space	102 (94)
AA	77 (71)
Inferior vena cava	85 (79)

^aAortic, mitral, tricuspid and the pulmonary valves.

Table 3 Correlations of semi-quantitative echocardiographic indices between pocket-sized echocardiography and reference method

Grading of:	n_{total}	$n_{\text{pathology}}$	r (95% CI)
Global LV function	108	35	0.95 (0.90–0.99)
Apparent LV regional dysfunction	108	35	0.92 (0.83–0.98)
RV function	106	10	0.85 (0.65–1.0)
Size of the left atrium ^a	107	69	0.65 (0.51–0.76)
AA ^a	67	7	1.0 (1.0)
Pleural effusion ^a	85	14	0.89 (0.74–1.0)
Inferior vena cava ^b	76	—	0.68 (0.53–0.80)
Pericardial effusion	108	9	0.94 (0.78–1.0)
Aortic calcification and stenosis	106	24	0.62 (0.42–0.79)
Aortic regurgitation	106	31	0.92 (0.83–0.98)
Mitral regurgitation	107	54	0.89 (0.82–0.95)
Tricuspid regurgitation	108	34	0.81 (0.69–0.91)

n_{total} , total number in the analyses; $n_{\text{pathology}}$, total number with the described pathology. ^aReference method was radiologic examinations and high-end echocardiography. In case of doubt, radiologic examination was used.

^bPearson's correlation, all other analysed by Spearman's rank correlation.

and Figure 1 illustrate the agreement of POCKET with HIGH regarding the assessments of valvular function. Severe pulmonary regurgitation and mitral stenosis was only present in one patient each and no pulmonary stenosis was detected (data not tabulated).

Visual estimation of the size of the AA had perfect correlation (1.0) with respect to detecting aneurysms ≥ 35 mm. Seven (10%) patients had abdominal aortic aneurysms. The degree of LA dilatation and end-expiratory IVC diameter showed a less robust correlation, both $r = 0.65$ (IVC, $r^2 = 0.42$). Pericardial effusion was detected in nine (8%) patients and in one patient with insignificant pericardial effusion this was missed by POCKET. Detection of pleural effusions had an overall correlation of $r = 0.82$ (0.79–1.0). In total 14 patients had pleural effusion detected by HIGH. No

Table 4 Agreement between point-of-care pocket-sized echocardiography and reference echocardiography of different cardiac indices

Indices (n = total/ pathology)	All examinations, POCKET – 2/– 1/ 0/+ 1/+ 2 grades misclassification	Examinations in diseased, POCKET – 2/– 1/0/+ 1/+ 2 grades misclassification
Global LV function (n = 107/35)	—/4/98/5/—	—/4/27/4/—
Regional LV function ^a (n = 106/35)	—/1/103/2/—	—/1/34/—/—
Global RV function (n = 107/10)	—/1/104/2/—	—/1/9/—/—
LA size (n = 106/69)	—/20/73/12/1	—/20/46/3/—
Aortic stenosis (n = 106/24)	1/10/89/6/—	1/10/13/—/—
Aortic regurgitation (n = 106/31)	—/4/100/2/—	—/4/26/1/—
Mitral regurgitation (n = 107/54)	—/3/97/7/—	—/3/50/1/—
Tricuspid regurgitation (n = 108/34)	—/10/94/3/1	—/10/22/1/1

LV, left ventricle; RV, right ventricle; LA, left atrium.
POCKET – 2/– 1/0/+ 1/+ 2 refer to underestimation (–) and overestimation (+) by POCKET of the described indices compared with reference echocardiography.
^aLV regional dysfunction was classified as present or not, i.e. only two categories.

significant amount of pleural effusion was missed. Table 5 shows the high sensitivity, specificity, positive, and negative predictive values of POCKET with respect to detecting at least moderate pathology of the cardiovascular indices.

The coefficients of variation for all presented echocardiographic indices were $\leq 6.0\%$, indicating low interanalysers variability of the reference method. Mean \pm SD (range) time used for reference echocardiography, excluding post-processing beyond calculation of ejection fraction was 17.2 ± 3.8 (12–32) min.

Discussion

This study of 108 patients admitted to a medical department shows that bedside, limited, semi-quantitative point-of-care ultrasound examination with a pocket-sized device can offer high-quality assessment of cardiac structures, cardiac function indices, abdominal great vessels and the pleural space. The pocket-sized ultrasound examinations were highly feasible and the agreement with reference methods was excellent for most indices.

The presented findings are in line with recent publications from echo lab's and outpatient clinics with respect to feasibility and reliability.^{4,6–8} However, direct comparisons between studies are

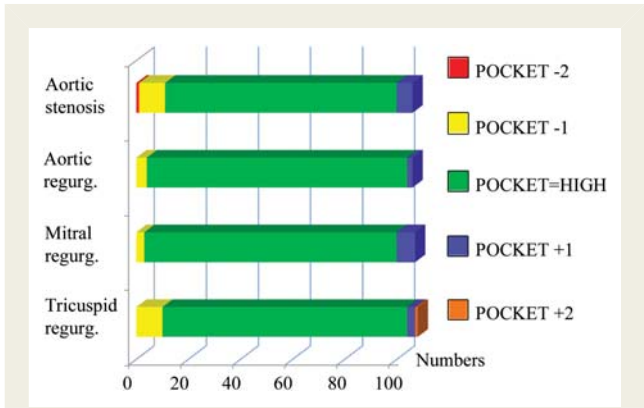


Figure 1 Agreement of grading valvular function with pocket-sized echocardiography compared with reference. All indices of valvular function graded as normal, or mild, moderate, and severe pathology. The number of patients with any; aortic valve calcification/stenosis, aortic regurgitation, mitral regurgitation, or tricuspid regurgitation by high-end echocardiography was 24, 31, 54, and 34, respectively. POCKET – 2, – 1, + 1 and + 2 refer to grades of underestimation (–) and overestimation (+) of the described pathology compared with reference echocardiography. Abbreviations: regurg, regurgitation.

difficult due to different populations and exclusion criteria. We excluded only patients who did not consent to participate or remain long enough in-hospital to have a reference echocardiography for comparison.

Furthermore, our study was conducted at the bedside by cardiologists, in sub-optimal examination conditions, on call during busy working hours, in a department where most admissions are on an emergency basis.

As shown by Supplementary material online, Figures S1 and S2 there was a modest underestimation of valvular pathology by POCKET compared with HIGH. This was most pronounced for classification of aortic stenosis. Visual detection of aortic stenosis by POCKET was inferior to high-end reference. This may be explained by the lack of spectral Doppler and the lower resolution (240 × 320 pixels) on the Vscan with inferior visualization of the valvular cusps. However, there was no misclassification of valvular dysfunction in those with severe aortic stenosis. Colour-coded images are limited by a low frame rate, but this is compensated for by the vendor by a high sensitivity. Very small or insignificant leakages may be bloomed and this may account for some of the overestimated pathology presented in Supplementary material online, Figures S1 and S2. There were no misclassifications of severe aortic, mitral and tricuspid regurgitations. Thus, it does not seem to be any limitation for the clinical use of the colour mode.

The size of the left atrium and the inferior vena cava showed only substantial agreement between POCKET and HIGH. This may primarily be related to timing of the measurements in the cardiac or respiratory cycles and the time delay of median 17 h between POCKET and HIGH. As the POCKET device is not able to show the cyclicity of the cardiac or respiratory phases, timing of measurements is done by visual assessment only. As

Table 5 Sensitivity, specificity, positive, and negative predictive value of point-of-care pocket-sized echocardiography to detect pathology compared with reference method

To detect:	n _{pathology} (n _{total})	Sensitivity (%)	Specificity (%)	PPV (%)	NPV (%)
At least moderate LV dysfunction	35 (108)	97	99	97	99
Any LV regional dysfunction	35 (108)	97	99	92	96
Any RV dysfunction	10 (106)	90	99	82	98
Any dilatation of the left atrium	69 (107)	81	68	85	73
Any abdominal aortic aneurysms	7 (67)	100	100	100	100
Any pleural effusion ¹	14 (85)	93	98	87	97
Any pericardial effusion	9 (108)	89	99	100	100
At least moderate aortic stenosis	8 (106)	63	100	100	97
At least moderate aortic regurgitation	6 (106)	83	99	83	99
At least moderate mitral regurgitation	14 (107)	93	99	93	99
At least moderate tricuspid regurgitation	8 (108)	88	98	78	98

Abbreviations and explanations as in Table 3.

the dimension of the inferior vena cava is an indirect measure of right atrial filling pressure, the delay from POCKET to HIGH may bias the analyses of reliability, related both to physiologic conditions and any given treatment.¹⁶ The lack of M-mode and ECG timing on the POCKET device may lead to inaccurate measurements.

The clinical implication of our study is that pocket-sized device can safely be implemented as a bedside screening device during ward rounds when operated by experienced users. Further work should address whether point-of-care POCKET influences workflow in hospitals and if our findings are reproducible by less-experienced users.

Limitations

The applicability of this study may be limited in that all POCKET examinations were performed by experienced cardiologists with a special interest in echocardiography. How feasible and reliable the use of POCKET by non-experts is in similar situations remains uncertain.

The POCKET examinations were performed under non-optimal conditions at the bedside. Thus, the POCKET and the HIGH examinations were performed under different conditions and this may influence both feasibility and reliability. However, the aim of this study was to assess the feasibility and reliability of POCKET used as a bedside screening device and therefore this was necessary.

The time delay (median 17.3 h) between POCKET and HIGH examinations may bias the analyses of reliability, related both to physiologic conditions, disease progression or regression and any given treatment.

Lack of spectral Doppler capability makes assessment of valvular pathology according to recommended guidelines difficult.^{11–13} Instead the quantification of pathology was assessed based on colour Doppler, grey-scale images of leaflet thickening, calcification and mobility.

However, the high sensitivity, specificity, and positive and negative predictive values of POCKET with respect to detecting at least

moderate pathology shows that POCKET may serve as an efficient tool for triage of the patient in need of a complete echocardiographic examination. Although POCKET quickly performs a limited semi-quantitative assessment well, it is not as accurate or reliable as the gold standard techniques. Pocket-sized echocardiography is as an adjunct to physical examination and a general screening tool. In settings where referral to formal imaging techniques is warranted POCKET is no substitute.

Conclusion

Focused point-of-care ultrasound examinations of 4 min duration with a pocket-sized device can offer high-quality semi-quantitative assessment of cardiac structures and function, as well as abdominal great vessels and the pleural space. The pocket-sized device can safely be implemented as a bedside screening device in the routine clinical practice of experienced operators.

Supplementary data

Supplementary data are available at *European Journal of Echocardiography* online.

Acknowledgements

G.N.A., B.O.H. and H.D. hold positions at MI Lab, a Centre of Research-based Innovation that is funded by the Research Council of Norway and industry. One of the industry partners is GE Vingmed Ultrasound. The Centre has a total budget of ~24 million NOK for the 8 years period from 2007 to 2014, and the contribution from GE Vingmed Ultrasound to this budget is ~7 million NOK (~6%).

Conflict of interest: none declared.

Funding

This study is funded by the Nord-Trøndelag Health Trust, Norway and the Norwegian University of Science and Technology, Norway.

References

1. Moore CL, Copel JA. Point-of-care ultrasonography. *N Engl J Med* 2011;**364**:749–57.
2. Sicari R, Galderisi M, Voigt J-U, Habib G, Zamorano JL, Lancellotti P et al. The use of pocket-size imaging devices: a position statement of the European Association of Echocardiography. *Eur J Echocardiogr* 2011;**12**:85–7.
3. Badano LP, Nucifora G, Stacul S, Gianfagna P, Pericoli M, Del Mestre L et al. Improved workflow, sonographer productivity, and cost-effectiveness of echocardiographic service for inpatients by using miniaturized systems. *Eur J Echocardiogr* 2009;**10**:537–42.
4. Cardim N, Fernandez Golfin C, Ferreira D, Aubele A, Toste J, Cobos MA et al. Usefulness of a new miniaturized echocardiographic system in outpatient cardiology consultations as an extension of physical examination. *J Am Soc Echocardiogr* 2011;**24**:117–24.
5. Kaul S, Miller JG, Grayburn PA, Hashimoto S, Hibberd M, Holland MR et al. A suggested roadmap for cardiovascular ultrasound research for the future. *J Am Soc Echocardiogr* 2011;**24**:455–64.
6. Culp BC, Mock JD, Chiles CD, Culp WC. The pocket echocardiograph: validation and feasibility. *Echocardiography* 2010;**27**:759–64.
7. Galderisi MSA, Versiero M, Lomoriello VS, Esposito R, Raia R, Farina F et al. Improved cardiovascular diagnostic accuracy by pocket size imaging device in non-cardiologic outpatients: the NaUSiCa (Naples Ultrasound Stethoscope in Cardiology) study. *Cardiovasc Ultrasound* 2010;**8**:51.
8. Prinz C, Voigt J-U. Diagnostic accuracy of a hand-held ultrasound scanner in routine patients referred for echocardiography. *J Am Soc Echocardiogr* 2011;**24**:111–6.
9. Aase SA, Snare SR, Dalen H, Støylen A, Orderud F, Torp H. Echocardiography without electrocardiogram. *Eur J Echocardiogr* 2011;**12**:3–10.
10. Vignon P, Chastagner C, Berkane V, Chardac E, François B, Normand S et al. Quantitative assessment of pleural effusion in critically ill patients by means of ultrasonography. *Crit Care Med* 2005;**33**:1757–63.
11. Baumgartner H, Hung J, Bermejo J, Chambers J, Evangelista A, Griffin B et al. EAE/ASE. Echocardiographic assessment of valve stenosis: EAE/ASE recommendations for clinical practice. *Eur J Echocardiogr* 2009;**10**:1–25.
12. Lancellotti P, Moura L, Pierard LA, Agricola E, Popescu BA, Tribouilloy C et al. European Association of Echocardiography recommendations for the assessment of valvular regurgitation. Part 2: mitral and tricuspid regurgitation (native valve disease). *Eur J Echocardiogr* 2010;**11**:307–32.
13. Lancellotti P, Tribouilloy C, Hagendorff A, Moura L, Popescu BA, Agricola E et al. European Association of Echocardiography recommendations for the assessment of valvular regurgitation. Part 1: aortic and pulmonary regurgitation (native valve disease). *Eur J Echocardiogr* 2010;**11**:223–44.
14. Lang RM, Bierig M, Devereux RB, Flachskampf FA, Foster E, Pellikka PA et al. Recommendations for chamber quantification. *Eur J Echocardiogr* 2006;**7**:79–108.
15. Nagueh SF, Appleton CP, Gillebert TC, Marino PN, Oh JK, Smiseth OA et al. Recommendations for the evaluation of left ventricular diastolic function by echocardiography. *Eur J Echocardiogr* 2009;**10**:165–93.
16. Kircher BJ, Himelman HR, Schiller NB. Non-invasive estimation of right atrial pressure from the inspiratory collapse of the inferior vena cava. *Am J Cardiol* 1990;**66**:493–496.