

# De Novo Pediatric Ulcerative Colitis Triggered by SARS-CoV-2 Infection: a Tale of 2 Sisters

Nicholas A. Preziosi, MD,\* Areeba H. Rizvi, MD,<sup>†</sup> John D. Feerick, MD,<sup>‡</sup> and Chetan Mandelia, MD<sup>‡</sup> 

From the \*Department of Pediatrics, East Carolina University Brody School of Medicine, Greenville, NC, 27834, USA

<sup>†</sup>Department of Pathology and Laboratory Medicine, East Carolina University Brody School of Medicine, Greenville, NC, 27834, USA

<sup>‡</sup>Division of Pediatric Gastroenterology, East Carolina University Brody School of Medicine, Greenville, NC, 27834, USA

Address correspondence to: Chetan Mandelia, MD, 600 Moye Blvd, Mail Stop 632, Greenville, NC, 27834, USA ([chetanmandelia@gmail.com](mailto:chetanmandelia@gmail.com)).

## Lay Summary

We present a report of 2 sisters who developed acute onset hematochezia concurrently with SARS-CoV-2 infection. One patient recovered completely, whereas the sibling developed chronic symptoms leading to a diagnosis of ulcerative colitis requiring biologic therapy.

## Introduction

Coronavirus disease 2019 (COVID-19) has been associated with a wide variety of gastrointestinal symptoms including abdominal pain, vomiting, and diarrhea, which are usually self-limited.<sup>1</sup> There are infrequent reports of SARS-CoV-2 triggering new-onset inflammatory bowel disease (IBD) in adults, but none have been reported in children.<sup>2–5</sup>

## Case Report

Two sisters aged 10 (patient A) and 9 years (patient B) who were previously healthy presented together to the emergency department (ED) in August 2021 with acute-onset diarrhea and hematochezia that started 5 days earlier (day 0). They both had low-grade fever and cough for 2 days at onset of symptoms and developed 2 to 3 loose bowel movements daily mixed with bright red blood. Both patients were unimmunized and positive for SARS-CoV-2 infection by polymerase chain reaction testing. The siblings had unremarkable stool studies including bacterial culture, ova and parasite, and *Clostridioides difficile* antigen and toxin.

Patient A had resolution of hematochezia and diarrhea within 2 weeks. Labs at presentation were remarkable for microcytic anemia with hemoglobin (Hgb) nadir of 7.4 g/dL and mild elevation in C-reactive protein (CRP) to 3.4 mg/L. She was started on oral iron supplements and repeat Hgb at 2 weeks and 2 months was 9.0 and 12.0 g/dL respectively. At follow up, there were no gastrointestinal symptoms and CRP had normalized.

Patient B had a very similar presentation with initial improvement in symptoms within 2 weeks. At week 4, she presented with worsening of abdominal pain, diarrhea, and hematochezia; and labs were significant for elevated

inflammatory markers, anemia, and hypoalbuminemia, which continued to worsen (Table 1, weeks 4 and 8). Fecal calprotectin was found to be significantly elevated at 1401 ug/g (reference range, 0–120). She underwent endoscopic evaluation at week 8, which showed pancolitis (Mayo subscore 2) extending circumferentially and continuously from rectum to ascending colon with normal cecum, terminal ileum, and unremarkable upper endoscopy. Biopsies showed moderately active pancolitis with features of chronicity (Figure 1).

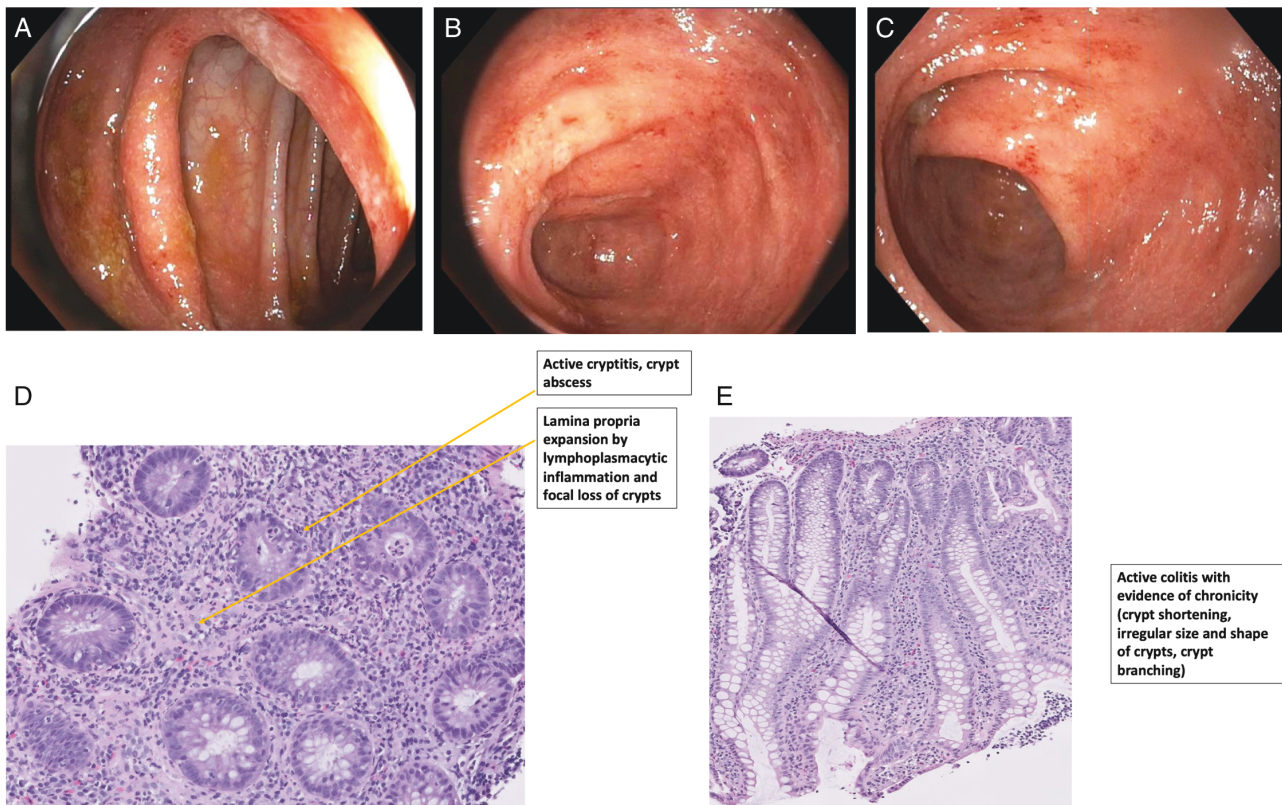
Patient B was started on prednisone (40 mg daily, weight 35.5 kg) for induction, which led to rapid improvement in symptoms within 2 weeks. Oral mesalamine (2.4 g daily) was started at week 10 with plan to gradually taper off prednisone. The patient had repeated relapses as the dose of prednisone was decreased to less than 20 mg daily (Table 1, weeks 16 and 24). Infliximab (8 mg/kg every 6 weeks) was started at week 27. By the end of induction, patient was off prednisone and in clinical and biochemical remission with normalization of fecal calprotectin (Table 1, week 39).

## Discussion

COVID-19 has been associated with the development of over 10 distinct autoimmune conditions in both children and adults.<sup>6</sup> SARS-CoV-2 virus can enter the gastrointestinal tract by binding to angiotensin-converting enzyme 2 (ACE-2) receptor located on enterocytes. There is emerging evidence that this leads to immune hyperstimulation, redistribution of immune cells, and dysbiosis, similar to that seen in IBD.<sup>7</sup> It is not yet fully understood why this occurs in certain patients and not in others, but it is hypothesized to be secondary to genetic susceptibility, defects in immune regulation, and/or presence of other environmental factors.

**Table 1.** Laboratory parameters of patient B in relation to clinical events.

	Week 1	Week 4	Week 8	Week 10	Week 16	Week 24	Week 39
Clinical Event	Initial ED visit	Recurrence of symptoms	Endoscopic evaluation	2 weeks after starting steroid	Relapse with steroid taper	Relapse with steroid taper	Infliximab 4th Dose
Hemoglobin (g/dL)	11.8	10.3	8.2	9.1	7.2	10.9	12.8
C-reactive protein (mg/L)	1.0	1.6	1.2	0.33	48.41	0.89	0.3
Erythrocyte Sedimentation Rate (mm/h)	28	38	50	19	43	68	16
Albumin (g/dL)	4.0	3.9	3.5	4.0	3.2	4.5	4.1
Fecal Calprotectin (ug/g) (Ref: <120)			1401		2359	1756	79



**Figure 1.** Endoscopic and histological images from colonoscopy of Patient B. A, Ascending colon: transition zone between inflamed and normal mucosa. B, Transverse colon: mucosa with loss of vascularity, erythema and erosions. C, Descending colon: mucosa with loss of vascularity, erythema, erosions and contact friability. D, Ascending colon biopsy (H&E- 20x): active cryptitis, crypt abscess, lamina propria expansion by lymphoplasmacytic inflammation and focal loss of crypts. E, Descending colon biopsy at H&E 10x: active colitis with evidence of chronicity (crypt shortening, irregular size and shape of crypts, crypt branching).

Our patients did not have any prior gastrointestinal symptoms, and the simultaneous occurrence of hematochezia in the siblings argues against the possibility of pre-existing IBD. The findings from these 2 cases suggest that SARS-CoV-2 infection can trigger an acute intestinal inflammation, which can either self-resolve or evolve into a chronic inflammatory disorder such as ulcerative colitis under unidentified circumstances.

## Funding

None to disclose

## Conflicts of Interest

None to disclose

## References

1. Pegoraro F, Trapani S, Indolfi G. Gastrointestinal, hepatic and pancreatic manifestations of COVID-19 in children. *Clin Res Hepatol Gastroenterol.* 2022;46:101818.
2. Calabrese E, Zorzi F, Monteleone G, et al. Onset of ulcerative colitis during SARS-CoV-2 infection. *Dig Liver Dis.* 2020;52: 1228-1229.

3. Imperatore N, Bennato R, D'Avino A, et al. SARS-CoV-2 as a trigger for de novo ulcerative colitis. *Inflamm Bowel Dis*. 2021;27: E87-E88.
4. Taxonera C, Fisac J, Alba C. Can COVID-19 Trigger De Novo inflammatory bowel disease? *Gastroenterology*. 2021;160: 1029-1030.
5. Senthamizhselvan K, Ramalingam R, Mohan P, et al. De Novo Crohn's disease triggered after COVID-19: is COVID-19 more than an infectious disease? *ACG Case Rep J*. 2021;8: e00652.
6. Dotan A, Muller S, Kanduc D, et al. The SARS-CoV-2 as an instrumental trigger of autoimmunity. *Autoimmun Rev*. 2021;20: 102792.
7. Dvornikova KA, Bystrova EY, Churilov LP, et al. Pathogenesis of the inflammatory bowel disease in context of SARS-COV-2 infection. *Mol Biol Rep*. 2021;48:5745-5758.