



Case Report

A moderate form of osteogenesis imperfecta caused by compound heterozygous *LEPRE1* mutationsAdolfredo Santana^a, Jeanne M. Franzone^a, Cristina M. McGreal^b, Richard W. Kruse^a, Michael B. Bober^{b,*}^a Department of Orthopaedic Surgery, Alfred I. duPont Hospital for Children, Wilmington, DE, United States^b Division of Genetics, Department of Pediatrics, Alfred I. duPont Hospital for Children, Wilmington, DE, United States

ARTICLE INFO

Keywords:

Osteogenesis imperfecta
 Non-collagen I osteogenesis imperfecta
 LEPRE1
 Recessive osteogenesis imperfecta

ABSTRACT

Osteogenesis imperfecta (OI) is a genetic disorder causing skeletal fragility, multiple fractures, and other extra-skeletal manifestations. Most cases are caused by mutations in *COL1A1* or *COL1A2*. Recent investigations have discovered several other autosomal recessive genes responsible for OI. Among these genes is *LEPRE1*, which is involved in post-translational modifications of collagen. To date, more than 40 *LEPRE1* mutations have been described. One of these mutations is carried by 1.5% of West Africans and 0.4% of African Americans, and is associated with OI Type VIII. We describe the case of a five year old male with a moderate form of OI and compound heterozygous *LEPRE1* mutations (c.1080 + 1G > T; c.1646 T > G, p.Met549Arg). He was diagnosed shortly after birth following a skeletal survey demonstrating multiple healing fractures as well as lower extremity deformity suggestive of remote fractures. He was then without a fracture until a calvarial fracture at 18 months of age, a femur fracture at 4 years and seven months and a second femur fracture at 5 years and 4 months. He walked at age 14 months and has been an active boy. Pamidronate infusions began at seven weeks of age and were discontinued at three years of age due to increased bone mineral density and absence of fractures. Type VIII OI typically causes a severe to lethal phenotype presenting at birth with severe osteopenia, congenital fractures and other clinical manifestations. Only a few individuals have survived to childhood. This case description serves to expand the clinical phenotyping of this recessive form of OI into the more moderate spectrum.

1. Introduction

Osteogenesis imperfecta (OI) is a heterogeneous group of genetic disorders of the connective tissue that cause skeletal fragility, multiple fractures, and other extra-skeletal manifestations. Most cases of OI are caused by heterozygous mutations in *COL1A1* or *COL1A2*, the genes encoding the two type I procollagen alpha chains, pro- α 1 and pro- α 2. Mutations in these genes result in quantitative and/or qualitative defects in type I collagen production by osteoblasts (Forlino and Marini, 2016; Takagi et al., 2012; Van Van Dijk and Silence, 2014).

More recently, studies have discovered several genes responsible for OI inherited as an autosomal recessive trait (Barnes et al., 2006; Byers and Pyott, 2012; Morello et al., 2006; van Dijk et al., 2009). Among these genes, *LEPRE1* encodes prolyl 3-hydroxylase 1 (P3H1), which forms a molecular complex with cartilage associated protein (CRTAP) and cyclophilin B (CypB) encoded by *PPIB*, in the endoplasmic reticulum (ER) that is responsible for one step in collagen post-

translational modification, the prolyl 3-hydroxylation of specific proline residues, specifically α 1(I) Pro986. P3H1 provides the enzymatic activity of the complex and is the only component of the complex with a Lys-Asp-Glu-Leu (KDEL) ER-retrieval sequence at the carboxyl terminus (Takagi et al., 2012). One *LEPRE1* mutation (c.1080 + 1G > T) has a carrier frequency of about 1/240 in the African American population, most commonly resulting in a lethal form of OI when present in a homozygous state (Cabral et al., 2012).

To date, more than 40 *LEPRE1* mutations have been described and the natural history of patients with a *LEPRE1* mutation is a severe or lethal presentation of the disease (Pepin et al., 2013). Here we report the case of a five year old male with a moderate form of OI and compound heterozygous *LEPRE1* mutations (c.1080 + 1G > T (paternal); c.1646 T > G, p.Met549Arg (maternal)). Usually the c.1080 + 1G > T mutation is severe or lethal when homozygous (Pepin, 2013). The mutation c.1646 T > G is a novel missense mutation. The resulting substitution of methionine by arginine at position 549 occurs in the

* Corresponding author at: Alfred I. duPont Hospital for Children, 1600 Rockland Road, Wilmington, DE 19803, United States.

E-mail address: Michael.Bober@nemours.org (M.B. Bober).<https://doi.org/10.1016/j.bonr.2018.09.002>

Received 25 April 2018; Received in revised form 4 July 2018; Accepted 14 September 2018

Available online 15 September 2018

2352-1872/ © 2018 The Authors. Published by Elsevier Inc. This is an open access article under the CC BY-NC-ND license

<http://creativecommons.org/licenses/by-nc-nd/4.0/>.

prolyl-hydroxylase domain of the protein. This case description serves to expand the clinical phenotyping of this recessive form of OI into the more moderate spectrum.

2. Case report

The patient is a now 5 year old male with a moderate form of OI. He was the fourth pregnancy for his then 30 year old mother and the sixth pregnancy for his then 39 year old father.

There is no known family history of OI or any other bone dysplasia. There is no consanguinity. The patient's mother is of Scottish/Irish/British ancestry. Her height is 5'2". She has no fracture history. The patient's father is of West African/Irish/Canadian/Indian ancestry. He has a history of nephritis, asthma, chronic obstructive pulmonary disease (COPD), and two transient ischemic attacks of the brain. His height is 5'8". He has no fracture history.

The pregnancy was recognized at four to five weeks and prenatal care began at eight weeks of gestation. There were no maternal medical problems affecting the pregnancy. Prenatal vitamins were taken daily as well as ondansetron as needed for nausea. There was cigarette smoking during pregnancy (6–7 cigarettes daily). A single 12 week ultrasound did not detect any abnormalities. The amniotic fluid level was normal. Fetal movements were described as decreased. There were premature contractions beginning at 35 weeks of gestation. A decision was made to induce labor at 39 weeks gestation. Rupture of membranes was artificial. Labor was difficult and presentation was occiput anterior. Delivery was vaginal with vacuum assistance. The birth weight was 7 lb, 4 oz and the birth length was 18.5 in. He was discharged on day of life one and seen by his pediatrician on day of life two. He was noted to have a swollen right upper arm and decreased leg movements with frog legged posture. Referral to orthopedics was made and he was evaluated by a pediatric orthopedist on day of life 12. His parents reported that during this interval he was fussy and crying and likely in pain. A skeletal survey at that time demonstrated both sub-acute and chronic changes. Fractures with associated periosteal reactions and callus could be identified in the right humeral diaphysis, right clavicle, right distal femur, right proximal tibia, right distal fibula and left distal tibia. All of these appeared to be in the same stage of healing and are highly suggestive of perinatal fractures (See Fig. 1). In addition a skull fracture was noted and likely related to vacuum extraction. No vertebral body fractures were noted. Chronic changes of symmetric, bowed and undermodeled femurs were noted and suggestive of *in utero* fractures. Symmetric bulbous changes were also seen at the distal ends of the ribs bilaterally. Initial genetic testing from blood failed to demonstrate mutations in *COL1A1* and *COL1A2*. Subsequent testing identified compound heterozygous changes in the *LEPRE1* gene (c.1080 + 1G > T, c.1646T > G). No changes were identified in *CRTAP*, *PP1B*, *FKBP10*, *SERPINF1*, *PLOD2*, *SERPINH1*, *SP7* or *ALPL* (Collagen Diagnostic Lab, University of Washington). The c.1080 + 1G > T mutation is the common West African allele and is known to cause severe or lethal OI when homozygous (Pepin et al., 2013). The c.1646T > G mutation is a novel missense mutation. The resulting substitution of methionine by arginine at position 549 occurs in the prolyl-hydroxylase domain of the protein. Follow-up testing from a skin biopsy and parental blood samples demonstrated paternal inheritance of the c.1080 + 1G > T variant and maternal inheritance of the c.1646T > G variant. No differences were identified in the secretion or electrophoretic mobility of types I and III procollagens. The efficiency and conversion of procollagens to collagen were similar to control cells.

The patient was started on a pamidronate therapy at seven weeks of age at a dose of 9.0 mg/kg/year (Glorieux et al., 2008). An initial L1-L4 bone mineral density (BMD) was measured at 0.092 g/cm² (Hologic Delphi). A Z-score could not be calculated due to the patient's age. Following two years and 17 cycles of treatment, the pamidronate dosing was reduced to 4.5 mg/kg/year due to improved BMD, a lack of

fractures and pain. L1-L4 BMD at that point measured 0.383 g/cm² (Hologic Discovery A). Again a Z-score could not be calculated, however this represented an interval increase of 316%. At three years of age, pamidronate therapy was discontinued due to distal femoral BMD Z-scores above the normal range (+2.7 on the left and +2.8 of the right). L1-L4 BMD was 0.436 g/cm² (Z-score-0.4) (Hologic Discovery A). At age 4.5 years, a DEXA scan continued to demonstrate elevated bone densities. At diagnosis and throughout his treatment his calcium, phosphorus and alkaline phosphatase levels have been normal. 25-hydroxy Vitamin D levels were supplemented into the normal range.

The patient's height has increased steadily with Z-scores consistently between -2 and -3. His weight is tracking at approximately the 25th percentile on the CDC grid for boys. Developmentally, he rolled at seven months, sat at nine months and walked at 14 months. The patient has appropriate hearing and vision. There is no evidence for dentinogenesis imperfecta or blue sclera.

On physical examination, there is anterolateral bowing of both femurs which improved with observation from the neonatal period until the age of 4.5 years (Fig. 1). Bilateral hip internal rotation is 30°, external rotation on the left 40°, and on the right 45°, bilateral hip flexion 110°, knee ROM 0–130°, popliteal angles 10° bilaterally. Bilateral foot dorsiflexion with the knees in full extension is 10° and bilateral foot dorsiflexion with knees in 90° of flexion is 20°. The left thigh foot angle is -10° and the right thigh foot angle is -5°. The patient has bilateral mild pes flexibile planovalgus.

The post-neonatal fracture history includes three fractures. At 18 months of age the patient was identified as having a right parietal calvarial fracture following an episode of altered consciousness. The fracture was an incidental imaging finding and remote from the acute episode. At four years and seven months of age, the patient fell at preschool and sustained a right femur fracture. The right femur fracture has been treated with an osteotomy and intramedullary Fassier-Duval rodding as demonstrated in Fig. 1. At 5 years 4 months, while playing outside, he fell and transversely fracture his left subtrochanteric femur. This was treated with an osteotomy and intramedullary Fassier-Duval rodding. No vertebral fractures have been noted.

3. Discussion

We report, to our knowledge, the most moderate case of a patient with a OI due to compound heterozygous mutations in *LEPRE1*. Typically biallelic *LEPRE1* mutations are associated with a lethal to severe form of OI characterized by rhizomelic limb shortening, white sclerae, severe skeletal undermineralization, extreme growth deficiency and bulbous metaphyses (Cabral et al., 2012; Cabral et al., 2007; Baldridge et al., 2008). Our patient has white sclera, but is without rhizomelic limb shortening, severe undermineralization or extreme growth deficiency. His presentation in the perinatal period suggested multiple fractures associated with birth trauma, but also more chronic disease and *in utero* fractures with bilateral femoral bowing. Symmetric bulbous changes were also seen at the distal ends of the ribs bilaterally. No vertebral fractures have been noted. His is currently an ambulatory active child who has only two long bones fractures (right and left femurs) since the perinatal period. These fractures however, were significant and required bilateral rodding procedures.

He began pamidronate therapy using standard dosing (Glorieux et al., 2008) and has had a robust response with a more than 300% improvement although the measurements were made on different machines in different centers. There is little published on pamidronate therapy in OI, Type VIII. Willaert et al. described a patient whose BMD improved from a Z-score of -11.0 at 6 years old to -6.8 after treatment, but the treatment details were not documented. That individual had a severe thoracic kyphoscoliosis and had shortened, bowed and twisted limbs (Willaert et al., 2009). Takagi also reported a child with Type VIII OI who began pamidronate therapy at 2 months of age and at 5, that child did not have severe deformity of the long bones and was

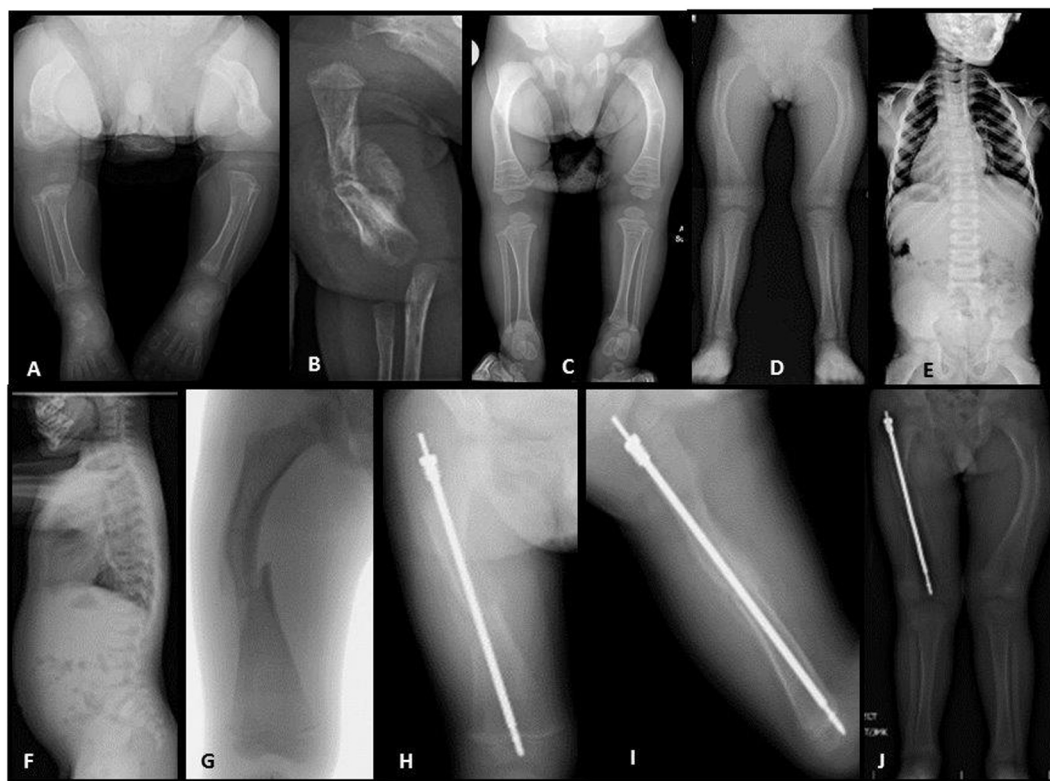


Fig. 1. Radiographic images. Lower extremities (panel A) and right humerus (panel B) at 12 days of age. Lower extremities at 1 year of age (panel C) and 4 years 6 months (panel D). Anterior posterior (AP) (panel E) and lateral (panel F) thoracolumbar spine. AP of right femur fracture at 4 years 7 months (panel G). AP (panel H) and lateral (panel I) images obtained 8 weeks postoperatively demonstrating Fassier-Duval rod placement and healing of the fracture and osteotomy. Lower extremities at 5 months postoperatively.

able to walk with support (Takagi et al., 2012). This robust response to pamidronate, may in part explain the few number of post-natal fractures.

The c.1080 + 1G > T *LEPRE1* mutation is a well described pathogenic variant associated with OI type VIII. It has been termed the “West African allele,” because it is seen in about half of the cases found in Ghana, Nigeria and among African-Americans patients (Cabral et al., 2012). Our patient's father is of West African ancestry and is known to carry this allele. When this mutation is present in homozygosity or in conjunction with another nonsense mutation, and it almost uniformly leads to a very severe or lethal form of OI (Cabral et al., 2007; Pepin et al., 2013). Our patient's second allele, inherited from his mother, is a novel c.1646 T > G mutation. The resulting substitution of methionine by arginine at position 549 occurs in the prolyl-hydroxylase domain of the protein and is expected to lead to a modified protein rather than an absence of protein. This amino acid appears to be highly conserved across primate and vertebrate species for which data is available in the UCSC Genome Browser (<http://genome.ucsc.edu/>) (Kent et al., 2002). This precise variant has not been identified in ClinVar (<https://www.ncbi.nlm.nih.gov/clinvar/>) nor the Exome Variant Server (<http://evs.gs.washington.edu/evs/>) (Landrum et al., 2018). This type of missense mutation is not a common as a cause for patients with Type VIII OI. Pepin et al. analyzed *LEPRE1* alleles in 42 individuals with OI (Pepin et al., 2013). Of the 46 distinct disease causing alleles identified 42 were either splice site, nonsense or frameshift mutations and predicted to lead to lack of P3H1 protein. Two of the remaining mutations likely did not affect mRNA stability but resulted in a protein that lacked the carboxyl-terminal rough ER (RER) localization signal (KDEL sequence). The consequence is functional haploinsufficiency through either rapid protein (P3H1) degradation or lack of P3H1 retention in the RER, or both (Pepin et al., 2013). The remaining two mutations were missense, and each changed the last nucleotide of exon 8, a position that normally

contributes to the function of the splice donor site. *In vitro* studies identified abnormal splice products, again leading to the absence of P3H1 (Pepin et al., 2013). Other reports appear to document only a single additional patient with a missense mutation. That individual was a compound heterozygote with a splice site mutation and a missense mutation (c.1466 T > C) (Zhang et al., 2012). While severely affected, that individual is the oldest known surviving patient (See Table 1).

The Type I procollagen molecules synthesized by cells from most individuals with mutations that significantly reduce the amount of CRTAP, P3H1, or CYPB are overmodified (Byers and Pyott, 2012). This overmodification can be measured by reduced electrophoretic mobility of collagen polypeptides due to increased posttranslational hydroxylation and glycosylation of lysyl residues (Byers and Pyott, 2012). Our patient's procollagen electrophoretic mobility studies failed to demonstrate this classic pattern. It is believed that in the absence of P3H1 or CRTAP, there is a delay in triple helix formation with secondary prolonged exposure of the procollagen chains to other hydroxylation steps (Byers and Pyott, 2012; Barnes et al., 2010). In an individual with mutations that resulted no P3H1 activity on one allele and the loss of the KDEL ER-retrieval sequence on the other, P3H1 activity is retained and *in vitro* functional studies demonstrated a higher level of appropriate prolyl 3-hydroxylation in the $\alpha 1(I)$ Pro986 position and a milder clinical phenotype that is somewhat similar to our patient. Despite this, protein overmodification is present and can be measured as reduced electrophoretic mobility (Takagi et al., 2012). This patient suggests that the ability to have more normal prolyl 3-hydroxylation in the $\alpha 1(I)$ Pro986 position may be independent of overmodification of the procollagen chains. Although P3H1 protein arising from the KDEL allele is likely normal, it may only have a transient presence in ER (Takagi et al., 2012).

Our patient's missense mutation does not clearly affect the KDEL sequence, but more likely affects 3-hydroxylation given its location in

Table 1
Clinical characteristics of long-term surviving patients with *LEPRE1* mutations.

	Patient 1 (Zhang et al., 2012)	Patient 2 (Zhang et al., 2012)	Patient 3 (Willaert et al., 2009)	Patient 4 (Willaert et al., 2009)	Our case
Published age (years + months)	24	17	17 + 7	8	5 + 6
Clinical classification	Severe	Severe	Severe to lethal	Severe to lethal	Moderate
Blue sclera	No	No	Slight	Yes	No
Hearing loss	No	No	No	NA	No
Dentinogenesis imperfecta	No	No	NA	No	No
Limb deformity	Severe	Severe	Severe	Severe	Moderate
Popcorn epiphyses	No	No	Yes	Yes	No
Short stature	Yes, 110 cm	Yes, 130 cm	NA	NA	Yes, 97 cm (−2.92 Z-score)
Mutation types					
Allele one	Splice site	Splice site	Splice site	Splice site	Splice site
Allele two	Missense	Nonsense	Nonsense	Splice site	Missense

the prolyl-hydroxylase domain of the protein. One could therefore, hypothesize that prolonged ER exposure and overmodification of procollagen chains is not purely a result of diminished P3H1 activity, but time the procollagen spend in the ER. If this is true, the combination of mutations present in our patient, could diminish the ER times but just lower levels of prolyl 3-hydroxylation in the $\alpha 1(I)$ Pro986 position without resulting in protein overmodification. As is pointed out by Pepin et al., the milder end of the clinical spectrum could be due to as yet unidentified missense mutations in *LEPRE1* (Pepin et al., 2013). Protein studies were not available from the 24 year old patient with a similar type of compound heterozygous mutations as our patient, but this long term survivor is also milder than the classic phenotype (Zhang et al., 2012). Clinical characteristics of this individual and other published long term survivors are described in Table 1. Given our patient's overall good health and milder skeletal phenotype, this case description serves to expand the clinical phenotyping of this recessive form of OI into the more moderate spectrum.

Funding

This research did not receive any specific grant from funding agencies in the public, commercial, or not-for-profit sectors.

Transparency document

The Transparency document associated this article can be found, in online version.

References

- Baldrige, D., Schwarze, U., Morello, R., Lenington, J., Bertin, T.K., Pace, J.M., Pepin, M.G., Weis, M., Eyre, D.R., Walsh, J., Lambert, D., Green, A., Robinson, H., Michelson, M., Houge, G., Lindman, C., Martin, J., Ward, J., Lemyre, E., Mitchell, J.J., Krakow, D., Rimoin, D.L., Cohn, D.H., Byers, P.H., Lee, B., 2008. CRTAP and *LEPRE1* mutations in recessive osteogenesis imperfecta. *Hum. Mutat.* 29 (12), 1435–1442.
- Barnes, A.M., Chang, W., Morello, R., Cabral, W.A., Weis, M., Eyre, D.R., ... Marini, J.C., 2006. Deficiency of cartilage-associated protein in recessive lethal osteogenesis imperfecta. *N. Engl. J. Med.* 355 (26), 2757–2764.
- Barnes, A.M., Carter, E.M., Cabral, W.A., Weis, M., Chang, W., Makareeva, E., Leikin, S., Rotimi, C.N., Eyre, D.R., Raggio, C.L., Marini, J.C., 2010. Lack of cyclophilin B in osteogenesis imperfecta with normal collagen folding. *N. Engl. J. Med.* 362 (6), 521–528.
- Byers, P.H., Pyott, S.M., 2012. Recessively inherited forms of osteogenesis imperfecta. *Annu. Rev. Genet.* 46, 475–497. <https://doi.org/10.1146/annurev-genet-110711-155608>.
- Cabral, W.A., Barnes, A.M., Adeyemo, A., Cushing, K., Chitayat, D., Porter, F.D., ... Marini, J.C., 2012. A founder mutation in *LEPRE1* carried by 1.5% of West Africans and 0.4% of African Americans causes lethal recessive osteogenesis imperfecta. *Genetics in Medicine* 14 (5), 543–551.
- Cabral, W.A., Chang, W., Barnes, A.M., Weis, M., Scott, M.A., Leikin, S., ... Marini, J.C., 2007. Prolyl 3-hydroxylase 1 deficiency causes a recessive metabolic bone disorder resembling lethal/severe osteogenesis imperfecta. *Nat. Genet.* 39 (3), 359–365.
- van Dijk, F.S., Nesbitt, I.M., Zwikstra, E.H., Nikkels, P.G., Piersma, S.R., Fratantoni, S.A., ... Pals, G., 2009. PPIB mutations cause severe osteogenesis imperfecta. *Am. J. Hum. Genet.* 85 (4), 521–527.
- Forlino, A., Marini, J.C., 2016. Osteogenesis imperfecta. *Lancet* 387 (10028), 1657–1671.
- Glorieux, F.H., Bishop, N.J., Plotkin, H., Chabot, G., Lanoue, G., Travers, R., 2008. Cyclic administration of pamidronate in children with severe osteogenesis imperfecta. *New. Eng. J. Med.* 339 (14), 947–952.
- Kent, W.J., Sugnet, C.W., Furey, T.S., Roskin, K.M., Pringle, T.H., Zahler, A.M., Haussler, D., 2002 Jun. The human genome browser at UCSC. *Genome Res.* 12 (6), 996–1006.
- Landrum, M.J., Lee, J.M., Benson, M., Brown, G.R., Chao, C., Chitipiralla, S., ... Maglott, D.R., 2018. ClinVar: improving access to variant interpretations and supporting evidence. *Nucleic Acids Res.* 46 (D1), 1062–1067.
- Morello, R., Bertin, T.K., Chen, Y., Hicks, J., Tonachini, L., Monticone, M., ... Lee, B., 2006. CRTAP is required for prolyl 3-hydroxylation and mutations cause recessive osteogenesis imperfecta. *Cell* 127 (2), 291–304.
- Pepin, M.G., Schwarze, U., Singh, V., Romana, M., Jones-Lecointe, A., Byers, P.H., 2013. Allelic background of *LEPRE1* mutations that cause recessive forms of osteogenesis imperfecta in different populations. *Mol. Genet. Genomic Med.* 1 (4), 194–205.
- Takagi, M., Ishii, T., Barnes, A.M., Weis, M., Amano, N., Tanaka, M., ... Hasegawa, T., 2012. A novel mutation in *LEPRE1* that eliminates only the KDEL ER-retrieval sequence causes non-lethal osteogenesis imperfecta. *PLoS One* 7 (5), e36809.
- Van Dijk, F.S., Sillence, D.O., 2014. Osteogenesis imperfecta: clinical diagnosis, nomenclature and severity assessment. *Am. J. Med. Genet. A* 164A (6), 1470–1481.
- Willaert, A., Malfait, F., Symoens, S., Gevaert, K., Kayserili, H., Megarbane, A., ... De Paepe, A., 2009. Recessive osteogenesis imperfecta caused by *LEPRE1* mutations: clinical documentation and identification of the splice form responsible for prolyl 3-hydroxylation. *J. Med. Genet.* 46 (4), 233–241.
- Zhang, Z.L., Zhang, H., Ke, Y.H., Yue, H., Xiao, W.J., Yu, J.B., ... Fu, W.Z., 2012. The identification of novel mutations in *COL1A1*, *COL1A2*, and *LEPRE1* genes in Chinese patients with osteogenesis imperfecta. *J. Bone Miner. Metab.* 30 (1), 69–77.