

Intravitreal Bevacizumab versus Combined Bevacizumab and Triamcinolone Acetonide for Neovascular Age-Related Macular Degeneration

Mohammad Riazi-Esfahani,¹ MD; Hamid Ahmadi,² MD; Hooshang Faghihi,¹ MD; Niloofar Piri,¹ MD; Ramin Taei,² MD; Reza Karkhaneh,¹ MD; Zahra Alami-Harandi,¹ MD; Alireza Lashay,¹ MD; Ahmad Mirshahi,¹ MD; Mehdi Nili-Ahmadabadi,¹ MD; Masoud Soheilian,² MD; Masoumeh Sanagou,² MSc

¹Eye Research Center, Farabi Hospital, Tehran Medical University, Tehran, Iran

²Ophthalmic Research Center, Labbafinejad Medical Center, Shahid Beheshti University MC, Tehran, Iran

Purpose: To compare the short-term outcomes of intravitreal bevacizumab (IVB) with the combination of IVB and intravitreal triamcinolone acetonide (IVB/IVT) for treatment of neovascular age-related macular degeneration (AMD).

Methods: This randomized clinical trial was performed on 92 eyes of 90 patients with subfoveal and juxtafoveal choroidal neovascularization (CNV) secondary to AMD. The eyes were randomly assigned to receive IVB 1.25 mg alone (53 eyes) or in combination with IVT 2 mg (39 eyes). Best-corrected visual acuity (BCVA) and fundus autofluorescence were assessed, and fluorescein angiography (FA) and optical coherence tomography (OCT) were performed at baseline and repeated 6 weeks after treatment.

Results: Mean age was 70.6±8.7 (range 50-89) years and 57.7% of the patients were male. BCVA improved from 1.03±0.40 to 0.93±0.38 logMAR (P=0.001) in the IVB group and from 1.08±0.33 to 0.91±0.38 logMAR (P=0.008) in the IVB/IVT group. There was a trend toward greater visual improvement with combined therapy (P=0.06). BCVA improvement was greater in eyes with +1 versus those with +2 (P=0.049) and +3 (P<0.001) fundus autofluorescence at baseline. Mean decrease in central macular thickness was 113±115 µm (P<0.001) in the IVB group versus 53.96±125 µm (P=0.008) in the IVB/IVT group with no intergroup difference (P=0.38). FA showed decreased leakage in 57.4%, increased leakage in 12.8% and no change in 29.8% of patients in the IVB group. Corresponding figures were 60.0%, 5.7% and 34.3% in the IVB/IVT group (P=0.556).

Conclusion: Addition of triamcinolone acetonide to bevacizumab for treatment of neovascular AMD does not seem to significantly increase its short-term efficacy. More severe fundus autofluorescence appears to be predictive of poorer response to treatment.

J Ophthalmic Vis Res 2008; 3 (2): 95-101.

Correspondence to: Niloofar Piri, MD. Eye Research Center, Farabi Hospital, Department of Ophthalmology, School of Medicine/Medical Sciences, University of Tehran; Qazvin Sq, Kargar Street, Tehran, Iran; Tel: +98 21 55410006-9, Fax: +98 21 55421002; e-mail: niloufarpiri@yahoo.com, pirin@sina.tums.ac.ir

Received: January 28, 2008 **Accepted:** April 19, 2008

INTRODUCTION

Age-related macular degeneration (AMD) is the leading cause of irreversible and severe visual

loss in subjects aged 50 years and above in developed countries.¹ Although the neovascular form of AMD represents only 10% of the disease, it is responsible for 90% of severe visual

loss due to AMD.² Attempts made to prevent visual loss by targeting the neovascular lesion, include thermal laser photocoagulation^{3,4} and photodynamic therapy (PDT).^{5,6} Laser photocoagulation results in immediate destruction of the central macula and loss of vision in subfoveal and juxtafoveal choroidal neovascularization (CNV) lesions. PDT selectively occludes neovascular tissue but has not been shown to improve vision in patients with CNV.⁷⁻⁹

The vascular endothelial growth factor (VEGF) has been implicated as the major angiogenic stimulus for neovascularization in AMD, accordingly, anti-VEGF agents have recently been used to treat CNV secondary to AMD.¹⁰⁻¹⁵ Bevacizumab, a full-length, humanized monoclonal anti-VEGF antibody has been successfully used for off-label treatment of neovascular AMD and CNV due to high myopia.¹⁶⁻³²

Other agents such as triamcinolone acetonide have been tried with short-term success. Besides its anti-inflammatory effects, triamcinolone acetonide causes down-regulation of VEGF.³³ The combination of PDT and triamcinolone, has also been reported to be effective.³⁴⁻³⁶ One case series has demonstrated successful triple therapy with PDT, bevacizumab and dexamethasone for exudative AMD.³⁷

To our knowledge, no clinical trial has been performed to assess whether triamcinolone acetonide has an additive effect with bevacizumab. In the current study we compared the effect of intravitreal bevacizumab (IVB) with that of the combination of bevacizumab and triamcinolone (IVB/IVT) on subfoveal and juxtafoveal neovascular AMD.

METHODS

This prospective, randomized, double-masked, two-center clinical trial was conducted from Dec. 2005 to April 2006. Subjects aged 50 years or older who had subfoveal or juxtafoveal CNV secondary to AMD with best-corrected visual acuity (BCVA) of 20/40 or less in the better eye and BCVA of 20/800-20/40 in the fellow eye were enrolled. All angiographic subtypes of AMD were included. To be eligible for inclu-

sion, total lesion size (including hemorrhage, scar, atrophy and neovascularization) was limited to 12 disc areas (DA) with at least 50% of the lesion consisting of active CNV and less than 50% being occupied by subretinal hemorrhage. Using balanced block randomization, subjects were randomly assigned to receive either 1.25 mg intravitreal bevacizumab (IVB group) or a combination of 1.25 mg bevacizumab and 2mg intravitreal triamcinolone acetonide (IVB/IVT group). Eligible patients provided written informed consent. The study protocol was approved by the institutional review boards and ethics committees of the participating centers.

Intravitreal injections were performed using a standard protocol as follows: following topical anesthesia and scrubbing the lids and eyelashes using povidone-iodine 10%; the eyelids were retracted using a sterile speculum and povidone-iodine 5% drops were applied over the ocular surface. Using a #30-gauge needle on an insulin syringe, 0.05 ml (1.25 mg) bevacizumab (Avastin, Genentech Inc., San Francisco, USA), was then injected through the pars plana into the vitreous cavity 3 to 4 mm posterior to the limbus, superotemporally. Triamcinolone acetonide (Triamhexal, Hexal AG, Holzkirchen, Germany), 0.05 ml (2 mg) was injected in the same manner using another syringe inferotemporally. The eye was then patched for 4 hours, topical chloramphenicol 0.5% was used every 6 hours thereafter for 3 days. All patients were examined 24 hours and 1 week after injection.

The primary outcome measures for efficacy were changes in BCVA and central macular thickness (CMT) by optical coherence tomography (OCT), 6 weeks after treatment. BCVA was measured at baseline and 6 weeks later using Snellen and ETDRS charts by a masked optometrist. CMT (central 1 mm) and central macular volume (central 3 mm) were measured using OCT (Stratus OCT, version 4.0.2; Stratus, Carl Zeiss Meditec, Dublin, CA, USA) at the same time intervals. Color fundus photography, assessment of autofluorescence and fluorescein angiography (FA) were performed in all patients at baseline and 6 weeks after intervention

using the Heidelberg Retinal Angiograph II (HRA-II). Fundus autofluorescence was graded as follows: +1 for minimal changes (Fig. 1), +2 for moderate changes (Fig. 2) and +3 for severe

changes (Fig. 3). The CNV lesions were divided by size into small (<4 DA) and large (≥ 4 DA). Fluorescein angiograms were reviewed by two masked authors (MRE and HA).

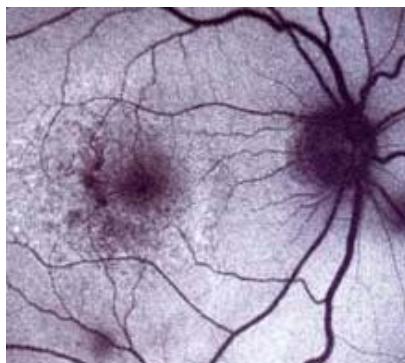


Figure 1 Standard photograph 1: minimal fundus autofluorescence.

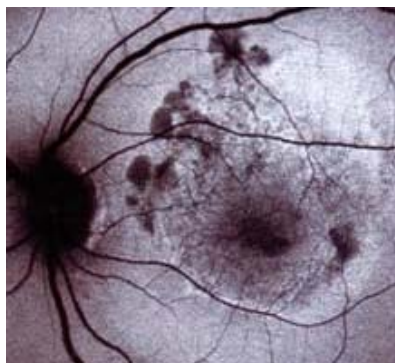


Figure 2 Standard photograph 2: moderate fundus autofluorescence.

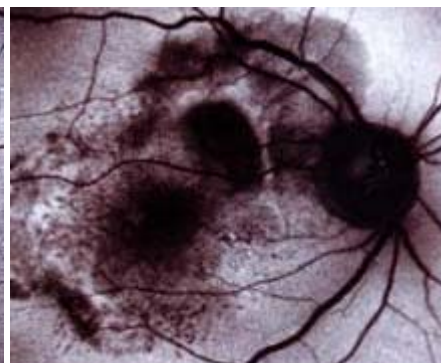


Figure 3 Standard photograph 3: severe fundus autofluorescence.

A minimum sample of 80 eyes (40 eyes in each study arm) was calculated to detect a 30% intergroup difference in CMT with study power of 0.8. Efficacy in the IVB and IVB/IVT groups was assumed to be 60% and 90% respectively. Data analysis was performed using *t*-test for comparing mean values between the two groups, and Chi-square or Fisher exact tests for comparing frequency values with significance level set at 0.05.

RESULTS

A total of 106 eyes of 104 consecutive patients met the study criteria and were enrolled. Fourteen patients did not complete the 6-week follow-up. Eventually, data from 92 eyes of 90 patients with mean age of 70.6 ± 8.7 (range 50-89) years, including 52 (57.7%) male and 38 (42.2%) female subjects were analyzed. Fifty-three and 39 eyes were allocated to the IVB and IVB/IVT groups respectively. Patients' demographics and ocular features at baseline were comparable between the study groups (table 1).

Mean BCVA significantly improved from 1.03 ± 0.40 to 0.93 ± 0.38 logMAR ($P=0.001$) in the IVB group and from 1.08 ± 0.33 to 0.91 ± 0.38 logMAR ($P=0.008$) in the IVB/IVT group. Visu-

al improvement was slightly greater in the IVB/IVT group ($P=0.06$). Overall, visual acuity improved 10 letters in 31 eyes (34%), 5-9 letters in 17 eyes (19%), remained unchanged in 32 eyes (35%) and decreased in 11 eyes (12%). The mean amount of decrease in visual acuity was 0.295 logMAR (approximately equivalent to 15 letters).

Mean CMT decreased from 361 ± 115 to 248 ± 115 μm ($P<0.001$) in the IVB group and from 352 ± 112 to 298 ± 138 μm ($P=0.008$) in the IVB/IVT group. The difference between the two groups was not significant in this regard ($P=0.38$). Mean CMV decreased from 3.61 mm^3 to 2.55 mm^3 ($P=0.001$) in the IVB group and from 4.18 mm^3 to 2.81 mm^3 ($P<0.001$) in the IVB/IVT group. The difference between the two groups was not significant ($P=0.493$).

Leakage on FA decreased in 27 (57.9%) eyes (Fig. 4), increased in 6 (12.8%) eyes and did not change in 14 (29.8%) eyes in the IVB group; corresponding figures in the IVB/IVT group were 21 (60%) eyes (Fig. 5), 2 (5.7%) eyes and 12 (34.3%) eyes, respectively. The difference between the two groups was not significant ($P=0.556$).

There was no difference between patients with lesions <4 DA and ≥ 4 DA in terms of BCVA, 6 weeks after treatment ($P=0.78$). Im-

provement in visual acuity was more profound in eyes with minimal (+1) fundus autofluorescence at baseline as compared to eyes with +2 (P=0.049) and +3 (P<0.001) changes.

Table 1 Baseline and demographic characteristics of the study groups

	IVB group	IVB/IVT group	*P value
Age (years): M±SD	70.7±8.9	70.4±8.5	0.87
Smoking: No (%)			
Yes	12 (26.7)	13 (46.4)	0.09
No	33 (73.3)	15 (53.6)	
Size of lesion: No (%)			
<4 DA	27 (58.7)	23 (71.9)	0.23
≥4 DA	19 (41.3)	9 (28.1)	
FA type: No (%)			
Dominantly classic	22 (42.3)	17 (47.2)	0.69
Minimally classic	14 (26.9)	7 (19.4)	
Purely occult	12 (23.1)	9 (25.0)	
Autofluorescence: No (%)			
+1	11 (28.2)	12 (35.3)	0.27
+2	16 (41.0)	17 (50.0)	
+3	12 (30.8)	5 (14.7)	
BCVA (logMAR): M±SD	1.03±0.40	1.08±0.33	0.72
CMT (µm): M±SD	361±115	352±112	0.66
CMV (mm ³): M±SD	3.61±1.57	4.18±2.09	0.22
BP (mmHg): M±SD			
Systolic	129±24	120±28	0.23
Diastolic	76±12	75±11	0.79

IVB, intravitreal bevacizumab; IVT, intravitreal triamcinolone; M, mean; SD, standard deviation; DA, disc area; FA, fluorescein angiography; BCVA, best-corrected visual acuity; CMT, central macular thickness; CMV, central macular volume; BP, blood pressure.

*Chi-square for frequency values and *t*-test for mean values.

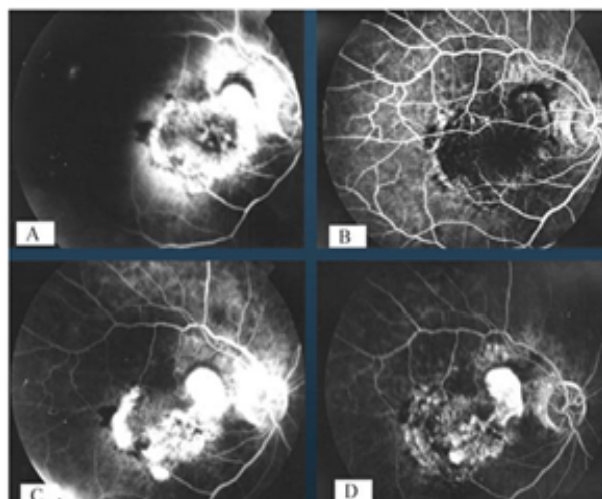


Figure 4 Fluorescein angiography of the right eye of a patient in the intravitreal bevacizumab group; (A) early phase at baseline, (B) early phase 6 weeks after injection, (C) late phase at baseline and (D) late phase 6 weeks after injection.

No significant change occurred in systolic (P=0.395) and diastolic (P=0.134) blood pressure after 6 weeks of follow-up. No patient developed uveitis, endophthalmitis, retinal toxicity or arterial thromboembolic events.

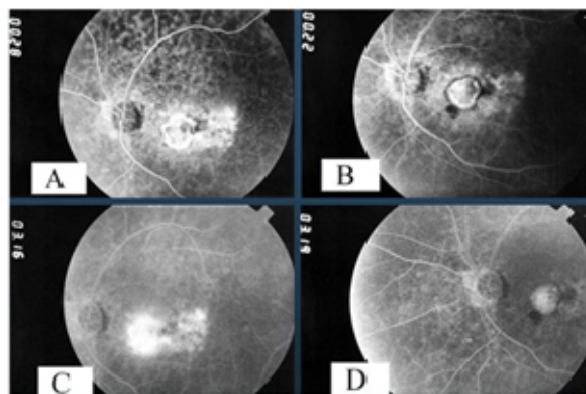


Figure 5 Fluorescein angiography of the right eye of a patient in the intravitreal bevacizumab plus triamcinolone group; (A) early phase at baseline, (B) early phase 6 weeks after injection, (C) late phase at baseline, and (D) late phase 6 weeks after injection.

DISCUSSION

The current study demonstrated that both IVB and IVB/IVT are well tolerated for treatment of neovascular AMD. There was no significant difference between the two modalities 6 weeks after treatment in terms of visual improvement, reduction of macular thickness and improved leakage on fluorescein angiography. Our results are consistent with previous studies reporting off-label IVB in patients with neovascular AMD.¹⁶⁻³² This study indicates that the addition of 2 mg triamcinolone acetonide does not significantly enhance the efficacy of bevacizumab in patients with neovascular AMD at least in the short-term; however, there was a trend toward greater visual improvement in the IVB/IVT treated group. This lack of additive effect may reflect inadequate triamcinolone acetonide dosage, inadequate sample size, or short follow-up. Another explanation for lack of synergistic effect may be that bevacizumab and triamcinolone affect similar pathways in angiogenesis; therefore the additive effect may

not be as significant as in the case of triamcinolone after PDT for neovascular AMD.³⁴⁻³⁶

Pegaptanib (Macugen) was the first anti-VEGF agent successfully used in the human eye. Although it was effective in preventing visual loss, visual improvement occurred in only 6% of patients one year after treatment.^{6,38} In our study, visual gain of ≥ 10 letters and ≥ 5 letters was observed in 33% and 52.7% of the patients after 6 weeks.

Ranibizumab is an anti-VEGF antibody fragment recently developed for intraocular use. It is a small molecule that would theoretically penetrate the retina better than a full-length antibody such as bevacizumab.³⁹ Using ranibizumab in patients with minimally classic and occult CNV, 25% of eyes treated with the 0.3 mg dosage and 33% of eyes treated with the 0.5 mg dosage had a 3-line improvement in visual acuity.⁴⁰ The short-term results of the mentioned studies are comparable to those of the current report. One drawback is that ranibizumab is more expensive and has a shorter half-life in the vitreous cavity necessitating repeat injections.⁴¹

Bevacizumab and ranibizumab have demonstrated similar efficacy in terms of visual improvement and stability; both agents provided stability of vision in 90 and 95% of eyes respectively.⁴¹ In addition, both prevent severe visual loss (greater than 3 lines) in almost all patients. The rate of visual improvement of up to 2 lines, or from 3 to 5 lines, is also comparable. Three to five lines of visual improvement was observed in 38% of bevacizumab treated eyes and 30% of ranibizumab treated eyes.²⁷ It is noteworthy that bevacizumab outcomes are based on short-term data (3 months) whereas the visual improvement seen with ranibizumab has been shown to last for up to 2 years. Overall it seems quite possible that bevacizumab may be as effective as ranibizumab. The National Institute of Health is conducting a controlled study to compare bevacizumab and ranibizumab.⁴¹

We did not observe any instance of intraocular inflammation with bevacizumab in either study group which is in accordance with pre-

vious studies.¹⁷⁻²⁰ However, inflammation has been reported with ranibizumab¹⁸ suggesting greater immunogenicity by the latter agent or existence of a proinflammatory component in the drug preparation. Ranibizumab is produced by bacteria but bevacizumab is produced using mammalian tissue culture¹⁸, this may explain the lack of inflammatory reaction following bevacizumab injection.

We observed that patients with minimal (+1) fundus autofluorescence at baseline show better response to treatment. Under such circumstances, only minimal retinal pigment epithelial (RPE) cells are damaged and the prognosis for visual improvement is good. This non-invasive method may be used for prognostic purposes.

Follow-up period in this study was inadequate to make definite recommendations for treatment guidelines in neovascular AMD. Despite a trend toward better visual outcomes in the combined IVB/IVT group, triamcinolone acetonide did not have a clearly additive effect to bevacizumab in the treatment of neovascular AMD in terms of anatomical or functional outcomes. The study is being continued and long-term results will be published in near future.

Acknowledgements

The authors would like to thank Sinadarou pharmaceutical company for their invaluable contribution in drug preparation and also express their gratitude to Roxana Namdar, Pharm.D. and Nazila Koupal for their assistance in the study.

REFERENCES

1. Pauleikhoff D. Neovascular age-related macular degeneration: natural history and treatment outcomes. *Retina* 2005;25:1065-1084.
2. Ferris FL III, Fine SL, Hyman L. Age-related macular degeneration and blindness due to neovascular maculopathy. *Arch Ophthalmol* 1984;102:1640-1642.
3. Macular Photocoagulation Study Group. Argon laser photocoagulation for senile macular degeneration. Results of a randomized clinical trial. *Arch Ophthalmol* 1982;100:912-918.

4. Macular Photocoagulation Study Group. Persistent and recurrent neovascularization after krypton laser photocoagulation for neovascular lesions of age-related macular degeneration. *Arch Ophthalmol* 1990;108:825-831.
5. Verteporfin in Photodynamic Therapy Study Group. Verteporfin therapy of subfoveal choroidal neovascularization in age-related macular degeneration: two-year results of a randomized clinical trial including lesions with occult and no classic choroidal neovascularization-Verteporfin in PDT report 2. *Am J Ophthalmol* 2001;131:541-560.
6. Gragoudas ES, Adamis AP, Cunningham ET Jr, Feinsod M, Guyer DR. Pegaptanib for neovascular age-related macular degeneration. *N Engl J Med* 2004;351:2805-2816.
7. Blinder KJ, Bradley S, Bressler NM, Bressler SB, Donati G, Hao Y, et al. Effect of lesion size, visual acuity, and lesion composition on visual acuity change with and without verteporfin therapy for choroidal neovascularization secondary to age-related macular degeneration: TAP and VIP report no. 1. *Am J Ophthalmol* 2003;136:407-418.
8. Bressler NM, Arnold J, Benchaboune M, Blumenkranz MS, Fish GE, Gragoudas ES, et al. Verteporfin therapy of subfoveal choroidal neovascularization in patients with age-related macular degeneration: additional information regarding baseline lesion composition's impact on vision outcomes: TAP report no. 3. *Arch Ophthalmol* 2002;120:1443-1454.
9. Bressler NM, Bressler SB, Haynes LA, Hao Y, Kaiser PK, Miller JW, et al. Verteporfin therapy for subfoveal choroidal neovascularization in age-related macular degeneration: four-year results of an open-label extension of 2 randomized clinical trials: TAP report no. 7. *Arch Ophthalmol* 2005;123:1283-1285.
10. Lopez PF, Sippy BD, Lambert HM, Thach AB, Hinton DR. Transdifferentiated retinal pigment epithelial cells are immunoreactive for vascular endothelial growth factor in surgically excised age-related macular degeneration-related choroidal neovascular membranes. *Invest Ophthalmol Vis Sci* 1996;37:855-868.
11. Frank RN, Amin RH, Elliott D, Puklin JE, Abrams GW. Basic fibroblast growth factor and vascular endothelial growth factor are present in epiretinal and choroidal neovascular membranes. *Am J Ophthalmol* 1996;122:393-403.
12. Kvant A, Algvere PV, Berglin L, Sergard S. Subfoveal fibrovascular membranes in age-related macular degeneration express vascular endothelial growth factor. *Invest Ophthalmol Vis Sci* 1996;37:1929-1934.
13. Kliffen M, Sharma HS, Mooy CM, Kerkuliet S, de Jong PT. Increased expression of angiogenic growth factors in age-related maculopathy. *Br J Ophthalmol* 1997;81:154-162.
14. Otani A, Takagi H, Oh H, Koyama S, Sugita G, Ogura Y. Vascular endothelial growth factor family and receptor expression in human choroidal neovascular membranes. *Microvasc Res* 2002;64:162-169.
15. Rakic JM, Lambert V, Devy L, Luttan A, Carmeliet P, Claes C, et al. Placental growth factor, a member of the VEGF family, contributes to the development of choroidal neovascularization. *Invest Ophthalmol Vis Sci* 2003;44:3186-3193.
16. Bartz-Schmidt KU, Holz FG. Introduction to the topic: off-label use of bevacizumab in the treatment of neovascular age-related macular degeneration. *Ophthalmologe* 2006;103:461-462.
17. Rosenfeld PJ, Moshfeghi AA, Puliafito CA. Optical coherence tomography findings after an intravitreal injection of bevacizumab (Avastin) for neovascular age-related macular degeneration. *Ophthalmic Surg Lasers Imaging* 2005;36:331-335.
18. Rich RM, Rosenfeld PJ, Puliafito CA, Dubovy SR, Davis JL, Flynn HW, et al. Short-term safety and efficacy of intravitreal bevacizumab (Avastin) for neovascular age-related macular degeneration. *Retina* 2006;26:495-511.
19. Ladewig MS, Ziemssen F, Jaissle G, Helb HM, Scholl HP, Eter N, et al. Intravitreal bevacizumab for neovascular age-related macular degeneration. *Ophthalmologe* 2006;103:463-470.
20. Niemeyer M, Hefner L, Jochmann C, Wiedemann P. Intravitreal Bevacizumab for recurring choroidal neovascularisation. *Ophthalmologe* 2007;104:158-160.
21. Avery RL, Pieramici DJ, Rabena MD, Castellarin AA, Nasir MA, Giust MJ. Intravitreal bevacizumab (Avastin) for neovascular age-related macular degeneration. *Ophthalmology* 2006;113:363-372.
22. Michels S, Rosenfeld PJ, Puliafito CA, Marcus EN, Venkatraman AS. Systemic bevacizumab (Avastin) therapy for neovascular age-related macular degeneration: twelve-week results of an uncontrolled open-label clinical study. *Ophthalmology* 2005;112:1035-1047.
23. Nguyen QD, Shah S, Tatlipinar S, Do DV, Anden EV, Campochiaro PA. Bevacizumab suppresses choroidal neovascularisation caused by pathological myopia. *Br J Ophthalmol* 2005;89:1368-1370.
24. Spaide RF, Laud K, Fine HF, Klancnik JM Jr, Meyerle CB, Yannuzzi LA, et al. Intravitreal bevacizumab treatment of choroidal neovascularization secondary to age-related macular degeneration. *Retina* 2006;26:383-390.
25. Ratimir L, Nikica G. Intravitreally administered bevacizumab (Avastin) in minimally classic and

- occult choroidal neovascularization secondary to age-related macular degeneration. *Graefes Arch Clin Exp Ophthalmol* 2007;245:68-73.
26. Yoganathan P, Deramo VA, Lai JC, Tibrewala RK, Fastenberg DM. Visual improvement following intravitreal bevacizumab (Avastin) in exudative age-related macular degeneration. *Retina* 2006;26:994-998.
 27. Bashshur ZF, Bazarbachi A, Schakal A, Haddad ZA, El Habibi CP, Noureddin BN. Intravitreal bevacizumab for the management of choroidal neovascularization in age-related macular degeneration. *Am J Ophthalmol* 2006;142:1-9.
 28. Chen CY, Wong TY, Heriot W. Intravitreal bevacizumab (Avastin) for neovascular age-related macular degeneration: A short-term study. *Am J Ophthalmol* 2007;143:510-512.
 29. Mackiewicz J, Mankowska A, Dolar-Szczasny J, Zubilewicz A, Oleszczuk A, Nowomiejska K, et al. Intravitreal bevacizumab (Avastin) for neovascular age-related macular degeneration (AMD): preliminary results. *Klin Oczena* 2007;109:146-149.
 30. Emerson MV, Lauer AK, Flaxel CJ, Wilson DJ, Francis PJ, Stout JT, et al. Intravitreal bevacizumab (Avastin) treatment of neovascular age-related macular degeneration. *Retina* 2007;27:439-444.
 31. Aisenbrey S, Ziemssen F, Volker M, Gelissen F, Szurman p, Jaissle G, et al. Intravitreal bevacizumab (Avastin) for occult choroidal neovascularization in age-related macular degeneration. *Graefes Arch Clin Exp Ophthalmol* 2007;245:941-948.
 32. Lazic R, Gabric N. Intravitreally administered bevacizumab (Avastin) in minimally classic and occult choroidal neovascularization secondary to age-related macular degeneration. *Graefes Arch Clin Exp Ophthalmol* 2007;245:68-73.
 33. Nauck M, Roth M, Tamm M, Eickelberg O, Wieland H, Stulz P, et al. Induction of vascular endothelial growth factor by platelet-activating factor and platelet-derived growth factor is downregulated by corticosteroids. *Am J Resp Cell Mol Biol* 1997;16:398-406.
 34. Arias L, Garcia-Arumi J, Ramon JM, Badia M, Rubio M, Pujol O. Photodynamic therapy with intravitreal triamcinolone in predominantly classic choroidal neovascularization. One-year results of a randomized study. *Ophthalmology* 2006;113:2243-2250.
 35. Augustin AJ, Schimdt-Erfurth U. Verteporfin therapy with intravitreal triamcinolone in all types of choroidal neovascularization due to age-related macular degeneration. *Ophthalmology* 2006;113:14-22.
 36. Spaide RF, Sorenson J, Maranan L. Combined photodynamic therapy with verteporfin and intravitreal triamcinolone acetate for choroidal neovascularization. *Ophthalmology* 2003;110:1517-1525.
 37. Augustin AJ, Puls S, Offermann I. Triple therapy for choroidal neovascularization due to age-related macular degeneration: verteporfin PDT, bevacizumab and dexamethasone. *Retina* 2007;27:133-140.
 38. Spaide R. New treatments for age-related macular degeneration. *Ophthalmology* 2006;113:160-161.
 39. Modenti, Cuthbertson Ra, Ferrara N, Thomsen K, Berleau L, Licko V, et al. Comparisons of intraocular tissue distribution, pharmacokinetics, and safety of ¹²⁵I-labeled-full-length and Fab antibodies in rhesus monkeys following intravitreal administration. *Toxicol Pathol* 1999;27:536-544.
 40. Miller J, Chung CY, Kim RY, MARINA study group. Randomized controlled phase III study of ranibizumab (Lucentis) for minimally classic and occult neovascular age-related macular degeneration. Program and abstracts of American society of retina Specialists 23rd Annual Meeting 2005; July 16-20, Montreal, Canada.
 41. Freeman WR, Falkenstein I. Avastin and new treatments for AMD: Where are we? *Retina* 2006;26:853-858.