

## Review Article

# Nonsaccular aneurysms: A wide comparison between the four main types

Enrico Affonso Barletta, Ranieri Henrique Moraes Lopes Gaspar, João Flávio Mattos Araújo<sup>1</sup>, Maick Willen Fernandes Neves<sup>2</sup>, José Luis Braga de Aquino<sup>3</sup>, Telmo Augusto Barba Belsuzarri<sup>1,2,4</sup>

Medicine Student from Pontifical Catholic University of Campinas, <sup>1</sup>Neurosurgery Department from Pontifical Catholic University of Campinas, <sup>2</sup>Post-Graduation at the State Server Hospital (IAMSPE), <sup>3</sup>Post-Graduation Department at Pontifical Catholic University of Campinas, <sup>4</sup>Post-Graduation Program, Masters in Health Sciences, Pontifical Catholic University of Campinas, Campinas, SP, Brazil

E-mail: \*Enrico Affonso Barletta - [enrico.barletta333@gmail.com](mailto:enrico.barletta333@gmail.com); Ranieri Henrique Moraes Lopes Gaspar - [ranieri.h.moraes@gmail.com](mailto:ranieri.h.moraes@gmail.com); João Flávio Mattos Araújo - [jflavioaraujo@terra.com.br](mailto:jflavioaraujo@terra.com.br); Maick Willen Fernandes Neves - [maickfernandes@gmail.com](mailto:maickfernandes@gmail.com); José Luis Braga de Aquino - [jlaquino@sigmanet.com.br](mailto:jlaquino@sigmanet.com.br); Telmo Augusto Barba Belsuzarri - [telmobelsuzarri@hotmail.com](mailto:telmobelsuzarri@hotmail.com)  
\*Corresponding author

Received: 12 May 18 Accepted: 20 August 18 Published: 11 March 19

## Abstract

**Background:** The present study aims to present the most important considerations when it comes to patients features, clinical presentation, localization, morphology, pathogenesis, and the best treatment for each type of the nonsaccular aneurysms.

**Methods:** We performed a literature review using PubMed. The search was limited to the studies published in English, from 2010 to 2017.

**Results:** Data about the clinical presentation; the aneurysm pathogenesis, morphology, and localization; the patient features; and about the surgical or endovascular approach were analyzed for the four types of nonsaccular aneurysms presented.

**Conclusion:** All types of nonsaccular aneurysms have a higher prevalence in young adults. Men are more affected by fusiform and mycotic aneurysms while women suffer more with blister-like aneurysms (BLAs). The mycotic and the BLAs affect more the anterior circulation while the fusiform affects more the posterior circulation. Mycotic and blister-like has as its major complication and clinical presentation the hemorrhage; however, the fusiform aneurysms usually present ischemia and/or mass effect. The reconstructive endovascular techniques for all types of nonsaccular aneurysms presented as the treatment with the best outcomes. Among this technique, the flow diversion presented good results in all types of aneurysms and it seems to promote the best outcomes.

**Key Words:** Aneurysm, blister-like, fusiform, intracranial, mycotic, nonsaccular

### Access this article online

**Website:**

[www.surgicalneurologyint.com](http://www.surgicalneurologyint.com)

**DOI:**

10.4103/sni.sni\_138\_18

**Quick Response Code:**

## INTRODUCTION

Intracranial aneurysms can be classified according to pathogenesis, shape, or its cause. The classification according to its shape is the most used and it can be divided into saccular and nonsaccular types.<sup>[24]</sup> There are four major types of nonsaccular aneurysms with

This is an open access journal, and articles are distributed under the terms of the Creative Commons Attribution-NonCommercial-ShareAlike 4.0 License, which allows others to remix, tweak, and build upon the work non-commercially, as long as appropriate credit is given and the new creations are licensed under the identical terms.

**For reprints contact:** [reprints@medknow.com](mailto:reprints@medknow.com)

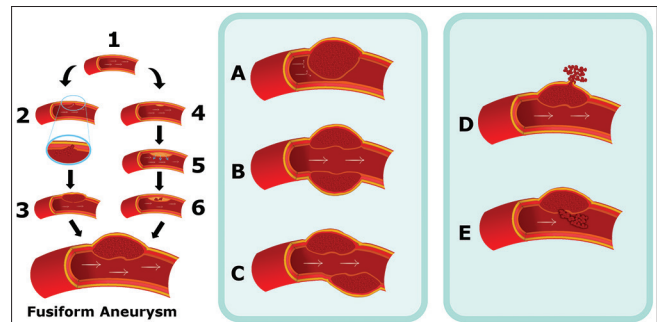
**How to cite this article:** Barletta EA, Gaspar RH, Araújo JF, Neves MW, Aquino JL, Belsuzarri TA. Nonsaccular aneurysms: A wide comparison between the four main types. *Surg Neurol Int* 2019;10:30.

<http://surgicalneurologyint.com/Nonsaccular-aneurysms-A-wide-comparison-between-the-four-main-types/>

different formation process, fusiform aneurysms due to dissection, fusiform aneurysms due to atherosclerosis, blister-like aneurysms (BLAs), and mycotic aneurysms (MAs).

An important feature of the intracranial fusiform aneurysms is the communication between both lumens (the true lumen and the pseudolumen) through a disrupted portion of the internal elastic lamina in most of the cases. A possibility for its evolution is the disruption advance to the adventitia, rupturing the aneurysm and causing a subarachnoid hemorrhage (SAH), or it can be contained by the media layer, which will result in ischemia or stenosis of the artery caused by the enlargement of the aneurysm toward the artery lumen.<sup>[21]</sup> A propose for atherosclerotic fusiform aneurysms pathogenesis and evolution is that the initial event in the formation of the aneurysm is a lipid deposition in and beneath the intima. This disrupts the internal elastic membrane (IEM) and infiltrates the muscular wall. Intramural hemorrhage and rupture of the atheroma leads to transmural extension of the thrombus and thickens the intima to create the fusiform shape of the aneurysm. The rupture of the vasa vasorum by shear stress or by forces on the parent vessel lumen then causes intimal impairment, mainly of the IEM. This process leads to the formation of an intramural hematoma due to the bleeding into the arterial wall. If the dissection occurs between the internal elastic lamina and the media, the vessel lumen becomes narrow or occluded with an intramural hematoma and the patients present with ischemic symptoms. If dissection is located between the media and the adventitia, the rupture of the aneurysm will lead to a SAH or intracranial hemorrhage (ICH) and the patient will present hemorrhage symptoms. The rupture into the vessel lumen of an intramural thrombus can cause a distal embolization. However, the further expansion of the intramural clot will lead to vessel occlusion. After occluding vessel by intramural hematoma, it can be recanalized and enlarged the dissection both laterally and longitudinally. Serpentine channel forms as disease extends longitudinally, combined with varying degrees of intraluminal thrombosis.<sup>[24]</sup> So it's possible to classify six stages for fusiform aneurysms evolution (atherosclerotic or nonatherosclerotic fusiform aneurysms) and they are: Arterial dissection with intramural hemorrhage between the intima and media producing focal narrowing of vessel; Rupture producing bleeding into the brain or subarachnoid space after the arterial dissection. Rupture of a dissection into the arterial lumen producing a distal embolization. Further expansion of an intramural clot leading to vessel occlusion. Progress enlargement of dissection both laterally and longitudinally and serpentine channel within dissected thrombotic aneurysm.<sup>[24]</sup> All this process is exemplified in Figure 1.

Intracranial fusiform aneurysms are rare, although the number of cases has increased in recent years, mainly in



**Figure 1: Fusiform aneurysm pathogenesis: (1) normal intracranial vessel; (2) dissection in the IEM; (3) hematoma is formation; (4) lipid deposition in and beneath the intima; (5) disruption of the IEM; and (6) intramural hemorrhage and rupture of the atheroma. The formation of an intramural hematoma leads to 5 main evolution patterns: (A) further expansion of the intramural hematoma; (B) progress enlargement of dissection both laterally and longitudinally; (C) serpentine channel; (D) rupture producing off vessel bleeding; and (E) rupture into the arterial lumen**

young patients.<sup>[4,13,16,20,29]</sup> They represent about 3–13% of all intracranial aneurysms and they are often presented at the vertebrobasilar system.<sup>[20,24]</sup> Fusiform aneurysms in the anterior circulation are less frequent when compared with the posterior circulation and most of the times, the middle cerebral artery (MCA) is the most affected, followed by the internal carotid artery (ICA) and the anterior cerebral artery (ACA).<sup>[20,24]</sup> The supraclinoid segment is the site for the majority of cases of fusiform aneurysm of the intracranial ICA.<sup>[20]</sup>

The patient can present symptoms and signs of occlusion, arterial rupture, or mass effect.<sup>[4,20,24]</sup> Fusiform aneurysms present more often with ischemic stroke or mass effect.<sup>[27]</sup>

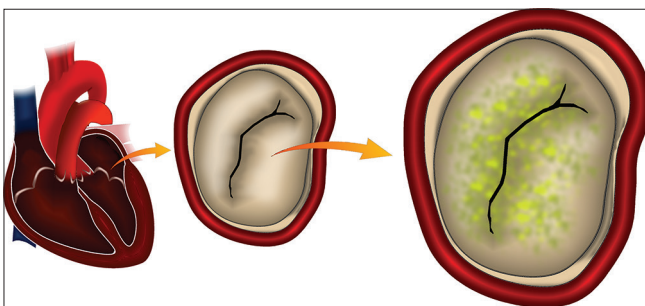
The best therapeutic choice for treatment of dissecting aneurysms, mainly the ones at the vertebrobasilar system, is controversial.<sup>[1]</sup> Fusiform aneurysms are a real challenge for any traditional microsurgical or endovascular treatment (EVT) because of their morphology and the involvement of the parent vessel.<sup>[1,16]</sup> Ruptured vertebral-basilar dissecting aneurysms (VBDA) are associated with a poor natural history with high rates of rebleed, stroke, and death when left untreated. Unruptured VBDA when not associated with stroke or mass effect usually present a good clinical course; however, they have a tendency to rupture and stroke when symptomatic. Both surgical and EVT have proved to be success when it comes to treat fusiform aneurysms. On account of its lower rates of treatment-related morbidity as well as their efficacy, EVTs have emerged as the treatment of choice.<sup>[4,10,31]</sup> However, a number of endovascular approaches to the treatment of VBDA exist. The EVT can be reconstructive, like stent placement, flow diversion (FD), and stent-assisted coiling or deconstructive techniques such as parent artery occlusion and trapping of the aneurysm.<sup>[28]</sup> A deconstructive treatment sacrifices the parent artery; a

proximal occlusion of the parent artery is performed by using balloons or coils at the segment proximal to the VBDA, and internal coil trapping is coil embolization of the parent artery at the dissected segment. In contrast, reconstructive treatments preserve the parent artery and use 1–3 overlapping stents, alone or with coiling.<sup>[4]</sup> The FD is an endovascular technique developed for treatment of intracranial aneurysms and it can be a good option for the treatment of large, giant, and wide-necked aneurysms; so, fusiform intracranial aneurysms has an anatomical predisposition for this technique.

Intracranial MA or infectious aneurysm is also a rare type of intracranial aneurysm, representing only 0.7–6% of all intracranial aneurysms.<sup>[9,19,30,32]</sup> The infection sources can be divided into systemic or local infections, such as infective endocarditis (IE) representing the first and meningitis, cavernous sinusitis, or orbital cellulitis representing the second type. The documentation of the intracranial aneurysm by angiography and a series of predisposing conditions are the two main pillars for the diagnosis of an MA. IE is the main cause and the formation of the aneurysm happens in only 2–10% of patients with IE;<sup>[19,32]</sup> this is represented in Figure 2.

The treatment of these aneurysms has to consider the cardiac condition of the patient.<sup>[32]</sup> An infectious emboli, originated on the heart, may occlude vessels, cause cerebral infarction, or promote infection. Intracranial MAs can manifest initially as headache with fever in different grades. Focal deficit or SAH may be developed at a later stage in the MA course. In patients with IE, septic emboli from cardiac valves may lodge at intracranial vessels both at branching points or at distal segments.<sup>[19,32]</sup> These emboli may cause focal infection and corrupt the vessel wall, which subsequently gives rise to the MA. This process can be seen on Figure 3.

Therefore, considering the treatment of IE-related intracranial MAs, the targeting of the cardiac disorders is mandatory.<sup>[30]</sup> Generally, in the presence of MAs with cerebral infarction, the risk of rupture or hemorrhagic transformation justifies a 2–3-week postponement of the realization of a cardiac surgery.<sup>[19]</sup>

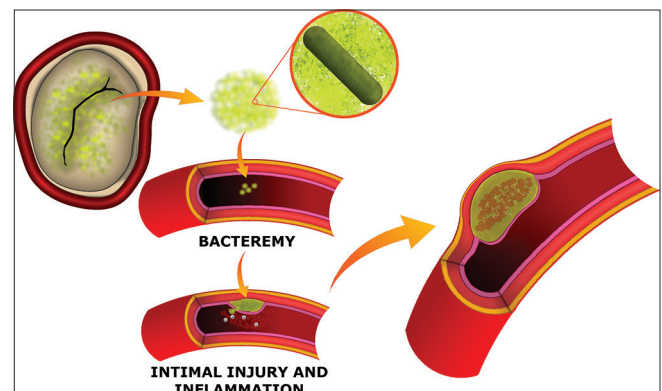


**Figure 2: Representation of the infective endocarditis – the illustration shows the most common place for the vegetations formation: the mitral valve**

Digital subtraction angiography (DSA) is a gold standard tool for intracranial aneurysm diagnosis. Nevertheless, the multidetector CT imaging increased the resolution of CT angiograms, allowing the visualization of the entire intracranial vascular tree, which contributes to find the MAs.

The treatment can be divided into medical, surgical, and endovascular therapy.<sup>[30]</sup> When a diagnosis of MA is established, a 6-week intravenous antibiotic therapy regimen associated with the culture results, when available, should be followed. The rupture of an MA is the main point to determine the therapeutic conduct; the ruptured needs to be immediately treated by surgical or endovascular procedures and the unruptured may be managed empirically with antibiotics. The evolution of MAs with antibiotic therapy is unpredictable: they may regress, disappear, persist, enlarge, or rupture. If the aneurysm presents a good outcome (decrease in size or be completely resolved), surgical or endovascular intervention is usually unnecessary and antimicrobial therapy should be continued. However, if the aneurysm presents a bad response (increase in size or remains unchanged), a surgical/endovascular intervention has a high probability to be required. Although the risk of rupture is <2%, the rates of morbidity and mortality are high, reaching 80%; hence, it is prudent the follow of an aggressive therapeutic approach.<sup>[19]</sup> Its obliteration must be undertaken when the aneurysm is ruptured or fails to respond to antibiotic therapy.<sup>[9]</sup> EVT is considered to be more effective and less invasive than surgical procedures. The localization of the aneurysm is also an important point to the procedure's choice. An MA in an important proximal parent artery that may require preservation of the artery flux.<sup>[32]</sup> The prognosis is extremely poor after the rupture occurrence, with a mortality of 60–90%<sup>[30,32]</sup> and 30% when unruptured.<sup>[30]</sup>

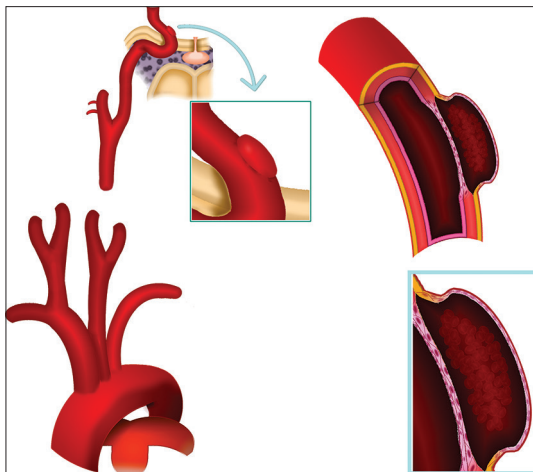
In young patients presenting with fever, focal neurological deficits and IE, the presence of MA's must be considered.<sup>[19]</sup>



**Figure 3: The mycotic aneurysm pathogenesis – the infectious emboli passes to the blood and reaches the intracranial vessels. There, the emboli can cause occlusion or it can promote a focal infection and corrupt the vessel wall, which subsequently gives rise to the MA**

BLAs are intracranial arterial injuries originating at non-branching sites of the dorsal supraclinoid internal carotid and basilar artery. They represent approximately 0.9–6.5% of all ICA aneurysms, accounting for 0.3–1% of all intracranial aneurysms and for 0.9–6.5% of ruptured aneurysms.<sup>[12,15,23]</sup> They are attributed to subadventitial dissections which lead to a focal wall defect with absence of internal elastic lamina and media, usually resulting in acute SAH. The arterial wall consists only in adventitia and thin fibrinous tissue.<sup>[23]</sup> Due to the focal wall defect covered with thin fibrous tissues, an aneurysm arising from the dorsal wall of the ICA is hard to manage either endovascular or surgically and is associated with high morbidity and mortality.<sup>[5]</sup> BLAs are unique owing to their high risk of recurrent bleeding, what is related to their fragile neck. The ruptured BLAs consist in a platelet plug, covering a thin adventitia layer, where is overlaid a defect in the intima and media, once these layers lack the usual collagen.<sup>[15]</sup> Their histological characteristics and their off-vessel morphology are presented in Figure 4.

Patients often present with acute SAH, and the affected population is younger than patients that present with saccular aneurysms. Some authors have reported a female and a right-sided ICA predominance and an association with systemic arterial hypertension. The classical BLAs morphology is small, hemispherically shaped and bulging from non-branching sites on the ICA. They are typically diagnosed after a bleeding episode because their small size allows them to be frequently missed on the first imaging exam, like the computed tomography angiogram or even in the digital subtraction angiogram (DSA). The radiological evolution of BLAs after rupture must be well analyzed because its progression to a saccular shape can be seen up to



**Figure 4: Blister-like aneurysms localization and morphology** – the figure shows the origin of the both carotid arteries and the supraclinoid segment, the main location of the blister-like aneurysms. In the histological representation, a subadventitial dissection leading to the creation of an intramural hematoma and the arterial wall consisting only in adventitia and thin fibrinous tissue can be seen. The figure elucidates the reason why blister-like aneurysms present high rates of rupture

several days after the bleed.<sup>[12]</sup> The angiographic follow-up on the short term is mandatory for the BLAs because it shows two important features of it: the instability and the morphological changes.<sup>[15]</sup> Ruptured BLAs present a high rate of mortality. Besides that, treatment of these lesions is technically difficult due to the lack of a defined neck and because the aneurysm sac has a very thin wall.<sup>[5,23]</sup> Therefore, ruptured BLAs are associated with high rates of spontaneous or treatment-induced rebleed leading to death, regardless the treatment type. The best treatment for blood blister-like aneurysms (BBAs) is controversial.<sup>[11,12]</sup> Many surgical techniques such as wrapping or trapping with bypass have been described for the treatment of these lesions.<sup>[23]</sup> Fragile thin-walled aneurysms have wide and poorly defined necks, which makes it difficult to clip them primarily.<sup>[5]</sup> So, these techniques are associated with high perioperative morbidity and mortality rates. The Sundt clip graft is a vessel-encircling clip, used to repair a significant dehiscence or tear in an intracerebral vessel wall, usually during urgent situations. The Sundt clip graft may be used in emergent situations in which a vascular tear or blister is encountered and the vessel cannot be treated with other surgical/endovascular techniques, including standard encircling aneurysm clips,<sup>[22]</sup> and has been showing good results. Endovascular techniques, both reconstructive and deconstructive, have emerged as the treatment of choice owing to the perceived lower rates of treatment-related morbidity and higher efficacy.<sup>[23]</sup> Many reconstructive techniques have been used to treat the BLAs, such as the endovascular procedures that use a traditional approach of coil embolization (with or without adjunctive stent placement), but it is difficult because of the very reduced size of BLAs without a defined saccular component to allow the introduction of coils safely. The placement of coils into the saccular component of BLAs is a dangerous technique and may cause perforation and re-hemorrhage. Beside that, the effectiveness of coil embolization for the management of dorsal wall ICA aneurysms is controversial. A huge disadvantage of flow diverters is the need for dual antiplatelet therapy in the acute phase of ruptured aneurysms. When the correct clinical setting is considered, flow diverters may present better results compared to other reconstructive procedures in the treatment of BLAs.<sup>[23]</sup> The extremely fragile wall of BLAs complicates and increases the risk of the management of those patients.<sup>[12]</sup>

The nonsaccular aneurysms can manifest with many different symptoms such as patients with incidental findings on routine imaging which are asymptomatic, posterior circulation ischemic strokes, brainstem compression, cranial nerve palsies (most commonly V–VIII), obstructive hydrocephalus, and hemorrhage.

The natural history of these lesions is untoward and mortality is higher than 30%, a recent review suggests that mortality could be even higher than 43%.<sup>[3]</sup>

## METHODS

The authors have prepared a meta-analysis on non-saccular aneurysms and compared a wide comparison between the four main types. A literature review using PubMed was done and the search was limited to the studies published in English, from 2010 to 2017. Data about the clinical presentation; the aneurysm pathogenesis, morphology, and localization; the patient features; and about the surgical or endovascular approach were analyzed for the four types of nonsaccular aneurysms presented.

## RESULTS

### Fusiform aneurysms

Park *et al.*,<sup>[24]</sup> after analyzing 22 patients that presented a fusiform aneurysm, found that 59% are man and 41% are woman; 60% of them were younger than 50 years. Park *et al.*<sup>[24]</sup> found that 36% of the patients analyzed presented SAH, 9% intracerebral hemorrhage, 18% neurological deficits due to ischemia, 23% dizziness, and 4.5% suffers cranial nerve deficit from mass effect.<sup>[24]</sup> About 77% of the aneurysms were located in the anterior circulation; 23% were at the posterior circulation. Fifty-four percent were at the MCA (17% M1, 25% MCA bifurcation, 33% M2, 25% M3), 14% were at the ICA, 9% at the ACA, 4.5% at the posterior cerebral artery (PCA), 9% at the vertebral artery (VA), and 9% at the posterior inferior cerebellar artery (PICA).<sup>[24]</sup> It could be demonstrated that 73% of the fusiform aneurysms were caused by vessel dissection, 18% were caused by atherosclerosis, and 9% by a collagen disease or unknown factor. Arterial dissection with intramural hemorrhage between the intima and media producing focal narrowing of vessel was noted in 18% of the cases. Arterial dissection with rupture producing bleeding into the brain or subarachnoid space was noted in 27%. Rupture of a dissection into the arterial lumen producing a distal embolization was noted in 9%, the vessel occlusion due to the further expansion of an intramural clot was noted in 4.5%, progress enlargement of dissection both laterally and longitudinally was noted in 9%, and serpentine channel within dissected thrombotic aneurysm was noted in 4.5%.<sup>[24]</sup> Fourteen percent of the patients were treated with wrapping of the aneurysm followed by clipping of the wrapping materials, 9% with clipping of the aneurysm followed by wrapping of the remaining portion, 9% with clipping alone, 27% with resection, 23% by proximal occlusion with a coil after extracranial-intracranial (EC-IC) bypass or not, and 4.5% with EC-IC bypass only and 14% of the aneurysms were treated conservatively.<sup>[24]</sup> About 77% of the patients recovered completely after treatment. Some neurological deficits developed in 14% of the patients, but they returned to full normal activities ultimately. Severe neurological deficit occurred in 4.5% of the patients caused by vasospasm during treatment of a ruptured aneurysm and the other 4.5% died because of rebleeding from a

rupture of the clipped aneurysm, causing an intracerebral hemorrhage.<sup>[24]</sup>

In the study by Kim *et al.*,<sup>[4]</sup> 111 patients underwent EVT for 119 VBDA. About 63% are man and 37% woman. The average age was 45 years.<sup>[5]</sup> About 61.3% of VBDA presented with SAH (ruptured aneurysms).<sup>[4]</sup> The group analyzed 62 VBDA that were treated by a reconstructive method, 35 by using 1–3 overlapping stents alone, 12 using a single stent with coiling, and 15 using 2 or 3 overlapping stents with coiling. The remaining 57 VBDA were treated by a deconstructive method, 40 by using internal coil trapping, and 17 using proximal occlusion. Clinical outcomes were favorable in all unruptured VBDA patients and in 77% (56 of 73) ruptured VBDA patients. About 23% (17) of the ruptured VBDA patients had unfavorable outcomes. Twelve percent (9) of the ruptured VBDA patients died, and 55% (5) of the deaths were due to rebleeding. Showing that the most important point to predict a good procedure outcome is to determine if the aneurysm is ruptured, this group represents the worse outcome. Posttreatment recurrence was diagnosed when rebleeding occurred or when angiographic recurrence was confirmed. Angiographic recurrence after deconstructive treatment was defined as the presence of an enlarged dissecting aneurysm, with or without recanalization of the parent artery. After reconstructive treatment, angiographic recurrence was defined as a substantial increase in the contrast medium-filled portion of the dissecting aneurysm compared with a control angiogram taken immediately after treatment.<sup>[4]</sup>

Day *et al.*<sup>[6]</sup> group analyzed 102 fusiform aneurysms on the MCA. The mean age at symptom onset was 38 years. About 71% of the patients were men. The study showed that 80% of the patients presented nonhemorrhagic symptoms or no symptoms at all. Clinical presentation was most often prompted by mass effect or thromboembolic stroke. Most of the aneurysms analyzed were originated from the M1 or M2 segments. Twelve percent of the patients had the MCA lumen stenosed or occluded; focal dilatation in 56% and 32% had a serpentine aspect.<sup>[6]</sup>

Devulapalli *et al.*<sup>[8]</sup> group analyzed 18 patients who underwent an EVT of intracranial fusiform aneurysms. About 72.2% (13) of them presented with SAH. Technical success was achieved in 94.4% (17), with 55.6% (10) undergoing reconstructive EVT and 44.4% (8) undergoing deconstructive EVT. For patients with SAH, favorable clinical outcomes were achieved in 69.2% (9), with 50.0% (3) undergoing reconstructive EVT and 85.7% (6) undergoing deconstructive EVT. Among patients with ruptured aneurysms, only Hunt–Hess grade  $\geq 3$  was associated with an unfavorable clinical outcome. Demonstrating that the size of the hemorrhage is a predictor for bad prognosis and the reconstructive EVT showed worse results, 75% of the patients with

an unfavorable clinical outcome underwent the reconstructive method.<sup>[8]</sup>

This review made by Sönmez *et al.*<sup>[28]</sup> included 476 patients. About 66.8% of them presented with ruptured VBDA, and 33.2% presented with unruptured VBDA. About 43.1% were treated with reconstructive techniques, and 56.9% were treated with deconstructive techniques. Considering all patients, immediate occlusion rates were 75% and long-term occlusion rates were 87%. Angiographic recurrence rates were 7% with a retreatment rate of 3%. Perioperative morbidity was 12%. Patients with ruptured VBDA made up a majority of patients with VBDA with perioperative mortality of 11%. The overall rebleed rate for patients with ruptured VBDA was 9%.<sup>[28]</sup> Patients with ruptured VBDA treated with deconstructive techniques had higher rates of complete occlusion on immediate posttreatment angiography than those treated with reconstructive techniques (94% vs. 43%), equal for long-term posttreatment angiography (95% vs. 83%). Perioperative morbidity rates were similar comparing the reconstructive group with the deconstructive group (7% vs. 14%). Perioperative mortality was 13.0% in the deconstructive group versus 7.0% in the reconstructive group. Long-term good clinical outcome rates were similar between the reconstructive and deconstructive groups (88% vs. 83.0%). Rebleeding rates were similar between the deconstructive and reconstructive (9% vs. 7%) techniques.<sup>[28]</sup> Patients with unruptured VBDA treated with deconstructive techniques had higher rates of complete occlusion on immediate posttreatment angiography than those treated with reconstructive techniques (94% vs. 57%); the same was seen on the long-term posttreatment angiography (97% vs. 68%). Perioperative morbidity rates were similar in the reconstructive group compared with the deconstructive group (7% vs. 7%). Perioperative mortality in the deconstructive group and in the reconstructive group was 4% versus 5%. Long-term good clinical outcome rates were similar between the reconstructive and deconstructive groups (94% vs. 93.0%).<sup>[18]</sup> These findings demonstrate that when it comes to the treatment of ruptured and unruptured VBDA, both deconstructive and reconstructive techniques are efficient. Deconstructive treatments showed higher rates of complete angiographic occlusion compared with reconstructive ones. However, periprocedural rates of morbidity were lower for the reconstructive techniques. Both techniques demonstrated high rates of good neurologic outcome in the long term and also low rates of recurrence and retreatment. Overall, these data suggest that reconstructive techniques are as effective and safer as deconstructive ones, especially in patients who lack sufficient collateral circulation. The present study found similar rates of good neurologic outcome in long term among patients treated with reconstructive and deconstructive techniques but

higher perioperative rates of morbidity between patients treated with deconstructive techniques. Patients treated with deconstructive techniques present higher risk of neurologic complications due to ischemia because of the sacrifice of the parent vessel. Most ischemic complications result from the occlusion and ischemia of the perforating arteries and anterior spinal artery.<sup>[28]</sup>

Zhang *et al.*<sup>[32]</sup> analyzed a total of 309 patients that presented with an intracranial dissecting aneurysm. The average age was 50.43. About 75.4% of the patients were male and 24.6% female. For the 67 patients with ruptured fusiform aneurysms reported, the severity of clinical manifestations was rated using the Hunt and Hess scale. Fifty-two of them were a Hunt and Hess grade I, nine grade II, four grade III, and one was grade IV. Among the 323 aneurysms studied by Zhang *et al.*,<sup>[32]</sup> 8.3% of them were at the anterior circulation and 91.7% at the posterior circulation. Among the aneurysms studied, 47 were treated by a deconstructive technique (the internal trapping) and 275 were treated by reconstructive methods (215 by stent-assisted coiling and 60 by sole stenting). In the deconstructive group, 2.1% of cases suffered an intraoperative complication (one case of aneurysm rupture), 19.1% suffered any postoperative complications (5 ischemic related, 3 compression related, and 1 complication by other causes). In the reconstructive group, 2.5% presented any intraoperative complication (stent thrombosis in 3, aneurysm rupture in 1, stent forward migration in 1, blood flow retardation in a branch artery in 1, and iatrogenic dissection in 1), and 11% suffered a postoperative complication (7 hemorrhagic related, 12 ischemic related, 7 compression related, and 4 complications by other causes). Twenty eight of the patients treated by a deconstructive method realized a radiographic follow-up and none of them presented recurrence of the aneurysm. Around 246 of the patients treated by a reconstructive technique realized the radiographic follow-up and 9.7% presented recurrence of the aneurysm.<sup>[32]</sup>

Table 1 presents the data about the fusiform aneurysms topography and Table 2 shows the data about the treatment outcome and the rates of rupture of the fusiform aneurysms.

### Mycotic aneurysms

Three case reports of four micotic intracranial aneurysm (MIA) treated with either stent monotherapy or stent-assisted coil embolization were identified. Ding *et al.*<sup>[9]</sup> reported a case of a 35-year old with bacterial endocarditis from *Streptococcus mitis* was diagnosed with a ruptured 3 mm MIA of the pericallosal ACA after episodic diplopia. The MIA was successfully treated with stent-assisted coil embolization. Follow-up magnetic resonance (MR) angiography 3 months before the procedure demonstrated complete aneurysm obliteration

and the patient was neurologically intact. The literature showed that a M1 segment MCA, a bilateral cavernous carotid, and a unilateral cavernous carotid MIA were also successfully treated with stent-assisted coil embolization and stent monotherapy, respectively.<sup>[9]</sup>

Wang *et al.*<sup>[30]</sup> reported a case of a 22-year-old male patient suddenly presented with vomiting and progressively deteriorated consciousness. On admission, his Glasgow Coma Scale (GCS) score was 5 with a fixed dilated right pupil and constricted left pupil. The head computerized tomography (CT) scan showed intracerebral hemorrhage which led to the realization of an emergent surgery of hematoma evacuation plus decompressive craniectomy. The GCS score rose to 13 and both pupils regained light reaction. A CT scan showed rebleeding at the surgical site, and DSA uncovered a ruptured aneurysm at the distal branch of the right PCA. Embolization of the ruptured aneurysm and the parent artery using a liquid embolic agent (Onyx) was performed uneventfully. During hospitalization, he also suffered from meningitis.

**Table 1: The fusiform aneurysms topography divided in two groups: the anterior and the posterior circulation**

Fusiform aneurysms topography		
Study (number of aneurysms analyzed)	Anterior circulation	Posterior circulation
Park <i>et al.</i> (22)	17	5
Schnell <i>et al.</i> (19)	–	19
Bhagal <i>et al.</i> (58)	–	58
Sacho <i>et al.</i> (136)	63	73
Zhang <i>et al.</i> (323)	27	296
Average (%)	19.20	80.80

After treatment, he was discharged without neurological deficit. After 3 months, he was presented with high fever and the blood culture disclosed the hemolytic streptococci presence. A regurgitated aortic valve with mobile vegetation on its leaflet was uncovered by an echocardiogram. He underwent cardiac surgery to replace the aortic valve and recovered well. About 3 months after that, he was admitted for cranioplasty. He became sluggish after the surgery. The head CT showed SAH disclosing a ruptured aneurysm at the distal branch of the left MCA. The group embolized the aneurysm and the parent artery using Onyx. After the measures, the consciousness status of the patient gradually improved and he underwent a treatment during 4 weeks of intravenous antibiotic before discharge. Now, the patient has a normal life, after developing two ruptured intracranial MAs within 7 months.<sup>[30]</sup>

Watanabe *et al.*<sup>[32]</sup> presented a case of a 56-year-old male who was admitted with a history of loss of appetite and fever of unknown origin for a month. Multiple blood cultures identified *S. mitis*. Echocardiography demonstrated vegetation of the mitral valve. The diagnosis was IE. The patient was treated with high doses of antibiotics. However, he required open-heart surgery because the mitral valve vegetation was not reduced in size. After 4 weeks of antibiotic therapy, he developed transient dysarthric speech and weakness of the left hand. The next morning, he had sudden onset of headache following nausea and disturbance of consciousness. Computed tomography scan showed SAH in the right sylvian fissure and MR imaging revealed a nodular signal void in the same region. At presentation, he was Hunt and Hess grade III. Four-vessel angiography demonstrated

**Table 2: The treatment outcome and the rates of rupture of the fusiform aneurysms**

Fusiform aneurysms			
Publication year – study – number of patients	Treatment presented	Good outcome (%)	Ruptured aneurysms (%)
2008 – Park <i>et al.</i> – 22	Surgical procedures	77	27
2011 – Kim <i>et al.</i> – 111	Deconstructive versus reconstructive EVT	100 – Unruptured VBDA patients 77 – Ruptured VBDA patients	61
2013 – Kashiwazaki <i>et al.</i> – 73	Deconstructive EVT	77	62
2013 – Devulapalli <i>et al.</i> – 18	Deconstructive versus reconstructive EVT	94.4 – Overall	72.2
2014 – Dabus <i>et al.</i> – 9	Reconstructive EVT	100	22
2015 – Sönmez <i>et al.</i> – 476	Deconstructive versus reconstructive EVT	88 – Reconstructive group 83 – Deconstructive group	66.8
2016 – Zhang <i>et al.</i> – 322	Deconstructive versus reconstructive EVT	86.5 – Reconstructive group 78.8 – Deconstructive group	21.70
Average	77% of surgical procedures presented good outcomes 55.2% of the EVT were reconstructive – 91.5% presented a good outcome 44.8% – of the EVT were deconstructive – 79.6% presented a good outcome 52.5% of the patients presented symptoms due to mass effect or ischemia		

EVT: Endovascular treatment; VBDA: Vertebral-basilar dissecting aneurysm

two aneurysms on the right MCA: a ruptured aneurysm of the M2 segment and an unruptured aneurysm of the distal portion of the posterior parietal artery. Antibiotic therapy was continued for 3 weeks, when repeat angiography showed an enlargement of the ruptured aneurysm suggesting that the risk of rebleeding had increased. However, the size of the unruptured distal aneurysm had diminished. Therefore, endovascular surgery was selected to prevent rebleeding of the ruptured M2 aneurysm before open-heart surgery. Five weeks after the onset of SAH, endovascular surgery was performed. The parent artery was preserved. Angiography 2 weeks later disclosed that both the aneurysms treated with the coil and the unruptured distal aneurysm were completely obliterated. Open-heart surgery was performed to replace the mitral valve 26 days after the endovascular procedure. The patient remained well and did not present any signs of meningitis or inflammatory symptoms.<sup>[32]</sup> Most cases of MA treated by endovascular procedures were associated with IE. The mortality for ruptured MAs before Watanabe *et al.*<sup>[8]</sup> treated eight patients by endovascular approach is 12.5%.<sup>[32]</sup>

Lotan *et al.*<sup>[18]</sup> presented a case of a 23-year-old woman who was admitted with a 1-month history of progressive behavioral changes, apathy, low grade fever, headache, and fatigue. Physical examination revealed mild left facial paralysis, mild left hemiparesis, left upper quadrantopsia, and fever of 39°C. Computed tomography and subsequent MR imaging of the head showed subacute stroke and a focus of SAH was noted. CT angiography showed a branch occlusion of the right MCA at the site of the hemorrhage, but no evidence of MAs. Trans-esophageal echocardiogram revealed moderate regurgitation associated with large mobile vegetation on the aortic and mitral valves. *Enterococcus faecalis* blood cultures were positive and a diagnosis of IE was thus established. Urgent cardiac operation was realized due to complications and a biological prosthesis for the aortic valve was implanted. Cultures of the valve leaflets vegetation yielded *E. faecalis*. Cerebral digital subtraction angiograph not only showed the established occlusion in the right MCA but also revealed a 3-mm aneurysm of the right MCA (M2 Sylvian segment) suspected to be the hemorrhagic source. Multiple small aneurysms of the distal MCA were also found bilaterally. Endovascular embolization was considered appropriate mainly because of the narrow neck of the aneurysm. Embolization was performed using platinum coils, and the aneurysm was completely obliterated. It was decided to continue with a 6-week antibiotic regimen while monitoring the size of the aneurysms.<sup>[19]</sup>

Hamisch *et al.*<sup>[14]</sup> series consisted of six patients with a median age of 57 years. All patients presented with ruptured MAs located on the MCA in 83.3% of the patients, and in 16.6%, the aneurysm was located at the

ACA. About 83.3% of the patients were treated by clipping and resecting the aneurysm and 16.6% underwent coiling. All patients received antibiotic therapy and 16.6% of the patients died. Hamisch *et al.*<sup>[14]</sup> group also identified 814 patients in the literature with a median age of 35. The most frequent locations of the aneurysms were MCA in 63.5% of the cases, PCA in 14%, ACA in 9.0%, and others in 13.5% of them. Treatment for IMAs was described in 62 studies: antibiotic treatment in 56.1%, a combination of antibiotics and surgery in 20.9%, or antibiotics and EVT 23.0%. The mortality rate was of 16.8%.<sup>[14]</sup>

The topography, the treatments and its outcome, and the rupture rates of the MAs are presented in Table 3.

### Blister-like aneurysm

Rouchaud *et al.*<sup>[23]</sup> identified that reconstructive techniques with parent artery preservation are related with similar rates of angiographic occlusion and improved clinical outcomes compared with deconstructive techniques that results in parent artery sacrifice. Patients treated with deconstructive techniques had higher rates of complete occlusion on immediate posttreatment angiography than those treated with reconstructive techniques (77.3% vs. 33.0%) but had a higher risk for perioperative stroke (29.1% vs. 5.0%). Patients treated with flow-diverter stents had higher rates of mid-to-long-term complete occlusion than those treated with other reconstructive techniques (90.8% vs. 69.7%) and a lower rate of retreatment (6.6% vs. 27.1%). Comparing the flow-diverter group with the non-flow-diverter reconstructive group, their perioperative rates of morbidity were similar (12.6% vs. 13.2%). Perioperative mortality was 8.7% versus 7.2%. Mid-to-long-term good clinical outcome rates were statistically similar between the flow-diverter group and non-flow-diverter reconstructive group, 86% versus 75%. Perioperative ICH rates were similar between both groups, 7.6% versus 6.3%.<sup>[23]</sup> Rouchaud *et al.*<sup>[23]</sup> also demonstrated that deconstructive (that consists in endovascular parent artery occlusion) and reconstructive (that is based on the stenting/stent-assisted or coiling/flow-diversion) techniques are both effective in the treatment of ruptured BLAs. Deconstructive treatment resulted in higher initial complete angiographic occlusion rates compared with the reconstructive techniques, although the periprocedural stroke rates were higher. However, statistically there were no significant differences between the occlusion retreatment, rebleeding, or clinical outcomes rates of the deconstructive and reconstructive techniques on mid-term to long term. These data show that reconstructive techniques are as effective and safer as endovascular parent artery occlusion (deconstructive procedures), considering the ischemic risk. These findings are important, especially in deciding treatment options for patients who cannot tolerate parent artery occlusion.<sup>[23]</sup>



**Table 3: The topography, the treatments and its outcome, and the rupture rates of the mycotic aneurysms**

Mycotic aneurysms				
Publication year – study – number of aneurysms	Localization	Treatment presented	Good outcome (%)	Patient presented a ruptured mycotic aneurysm
2014 – Ding <i>et al.</i> – 4	Pericallosal artery (ACA) Segment M1 (MCA) Cavernous segment of bilateral carotid Cavernous segment of unilateral carotid	Reconstructive treatment	100	No
2014 – Wang <i>et al.</i> – 2	Right posterior cerebral artery Left middle cerebral artery	Deconstructive treatment	100	Yes
1998 – Watanabe <i>et al.</i> – 2	Right segment M2 (MCA) Right posterior parietal artery (MCA)	Reconstructive treatment	100	Yes
2014 – Lotan <i>et al.</i> – 1	Right segment M2 (MCA)	Reconstructive treatment	100	Yes
Average	88.8% are at the anterior circulation 11.2% are at the posterior circulation 55.5% are at the MCA	All the aneurysms treated presented a good outcome. However, 77.7% were treated by reconstructive techniques		55.5% of the cases reported presented symptoms due to hemorrhage

MCA: Middle cerebral artery

Twelve patients with BBAs are presented by Gonzalez *et al.*;<sup>[12]</sup> 100% of the patients presented with an SAH. They underwent a CT scan and CT angiogram in the emergency room, both of which did not detect any aneurysm in 50% of them. The mean age of the patients was 56.1 years, and 66.6% were women. Fifty percent of the patients suffered from high blood pressure, 16.6% had a body mass index higher than 30, 8.3% had hypercholesterolemia, and 8.3% smoked. About 58.3% of the patients presented with headache, 33.3% presented with seizures, and 8.3% presented with coma as the initial symptom. According to the DSA, 66.6% of the aneurysms were located in the right supraclinoid ICAs and 33.4% at the left. The lesions measured 2 mm or less in 25% of the patients, between 2 and 4 mm in 58.3% patients, and between 4 and 6 mm in 16.6% of them. Comorbidities associated with the SAH were present in all patients. About 58.3% of the patients presented with hydrocephalus, 8.3% died from cardiovascular and pulmonary complications after admission, 16.6% developed clinically significant vasospasm, and 16.6% developed radiographic evidence of vasospasm without clinical repercussions. The proposed EVT was successful in 66.6% of patients: 45.4% were treated with stent-assisted coiling and 27.3% were treated with double FDSs. The treatment failed in 9% of the patient. In another 9%, the microcatheters were unstable because the lesion was circumscribing the artery. About 18.2% of these patients had to be treated surgically due to complications. The clinical outcome of the patients that underwent the proposed EVT, at 3 and 6 months, was good with a modified Rankin Scale (mRS) less than

or equal to 2 in 91% of the patients and moderate with a mRS of 3 in 9%.<sup>[12]</sup>

A total of 322 patients were evaluated at a systematic review also made by Gonzalez *et al.*<sup>[12]</sup> The mean age of the patients was 50.6 years. In addition, 72% were women. The main initial presentation was SAH in 99% of the cases analyzed. A total of 303 patients were offered treatment, either surgical or endovascular. The initial therapeutic modality offered failed to manage the BBA in 28% of the patients. Among this group of patients, 86% presented with a second SAH or had documented aneurysm regrowth in 56% of the cases. Among the patients who were not initially offered any treatment (6%), 21% died (15.8% due to rebleeding and 5.2% due to the first bleed itself), 68.4% were later offered treatment due to regrowth or rebleeding, and 10.5% were followed without any treatment. All of the treatments included 268 surgical treatments, 147 endovascular procedures, and 19 conservative treatments. About 67% of the patients received one treatment to reach aneurysm occlusion or stability. About 24.5% of the cases had a perioperative event (rupture or ischemic complications). The overall mortality of all the treatment modalities was 19% and the estimated morbidity (mRS outcome >2) was 17%. Eight different surgical techniques were found. Surgical clipping was the most common technique used in the 215 patients who underwent surgery. It was offered as the first approach in 80% of the surgical patients and in 30% of the cases that involved perioperative complications. A second treatment modality was necessary to secure or exclude the BBA in 21%. Surgical

trapping was the second most common technique and was used either as the primary or rescue treatment in 61 patients. Regrowth was observed in 5% of the cases and rebleeding in 30% of them. The rescue treatments after rebleeding or regrowth included a second clipping attempt, arterial suturing, coiling, coiling + stent, endovascular or surgical trapping with or without bypass, or just bypass. The most used rescue surgical techniques were trapping without bypass and arterial suturing. The morbi-mortality per technique was 57 patients among the patients who underwent clipping (75% of the overall morbi-mortality in the surgical group), 4 patients who underwent wrapping (5%), 7 patients who underwent trapping without bypass (9%), 5 patients who underwent surgical trapping and bypass (7%), 1 patient who underwent endovascular trapping and bypass (1%), no patients who underwent bypass (0%), and 2 patients who underwent suturing (3%). Among the endovascular procedures, there were 7 different techniques described offered to 87 patients. The most common technique used was stent-assisted coiling in 34.5% of the patients. Regrowth occurred in 38%, and rebleeding occurred in 12.5%. In 46%, a second treatment modality was required. The most common rescue technique for the endovascular procedures was surgical trapping. The overall morbidity of the EVTs was 3.4% and the mortality was 11.5%. The morbi-mortality was 34.7% in the patients treated with coiling; none in the parent artery occlusion/patients treated with coils or balloons; 10% in the patients treated with stents and coiling; 33.3% in the patients treated with covered stents; 8% in the patients treated with regular stents; and none in the patients treated with 1 or 2-layer flow diverters.<sup>[12]</sup>

Fang *et al.*<sup>[11]</sup> evaluated the safety and efficacy of stent-assisted coiling and subsequent overlapping stents (SAC + OS) in the treatment of BBAs. SAC + OS were successfully performed in all 15 cases presented. The immediate angiographic results were total occlusion in 40% of the cases, residual neck in 46.6%, and residual aneurysm in 13.3% of them. Angiographic follow-ups revealed total occlusion in 100% of the cases treated by triple or quadruple stents, and in 66.6% of the cases treated by double stents. Major recanalization was detected in 33.4% of the patients treated by double stents. The mRS score at 4–52 months follow-up was zero in 40% of the cases, 1 in 53.3%, and 3 in 6.6% of them.<sup>[11]</sup>

Cho *et al.*<sup>[5]</sup> described a case with several attempts of endovascular procedures, such as stent-assisted coil embolization, repeated coil embolization for recanalized aneurysm failed to prevent aneurysmal enlargement, or reduce the risk of rebleeding of the fragile aneurysm. As the next best solution, they decided surgical approach including EC–IC bypass and trapping of the ICA or direct clipping with the Sundt clip graft. In the final stage of the surgery, the Sundt clip graft was applied to the ICA,

for which two endovascular stents and coils had already been placed. In this case, clipping-induced stenosis could be minimized by the previously inserted self-expandable stents, which resulted in good preservation of the luminal flow by having the stent as a vascular frame.<sup>[5]</sup>

Table 4 shows and compares the data about surgical, reconstructive, and deconstructive treatment of BLAs. The table shows the treatment and its most common complications and their outcome.

## Overall

Bhogal *et al.*<sup>[5]</sup> analyzed 56 patients with 58 unruptured intradural fusiform aneurysms of the posterior circulation, which underwent an EVT, reconstruction with flow-diverting stents. All the patients received dual antiplatelet therapy (aspirin 75 mg daily and clopidogrel 75 mg) before to the treatment. The post-procedural antiplatelet regime consisted of clopidogrel continued for 12 months or longer following treatment and aspirin continued for life. Just over 80% of the patients were men and the mean age at first treatment was 63.5 years. Patients who were symptomatic from the aneurysm accounted for 37.9% of patients, with the rest presenting incidentally or for reasons thought not to be related directly to the aneurysm. At presentation, 89% of patients had a mRS score of  $\leq 2$  with the remaining 11% presenting with a mRS score of  $\leq 5$ . The most common anatomic location of aneurysms in this cohort was vertebrobasilar representing 44.8% with vertebral location, the second most common accounting for 29.3% of the cases and basilar for 18.9%. About 12.5% of patients had ischemic symptoms. About 3.5% of the patients presented with hemorrhage. The overall complication rate was 15.5%. Around 15.5% of the cohort died.<sup>[5]</sup>

The mean age, most affected sex, artery most affected, and the most common cause for the symptoms onset are presented in Table 5 to establish the features of the patients presenting each type of nonsaccular aneurysm.

## DISCUSSION

Looking for the patient that has a intracranial fusiform aneurysm features, most of them are men,<sup>[4,21,24]</sup> most of them are younger than 50 years old,<sup>[19,20,23,24]</sup> and the most affected population is the pediatric patients.<sup>[4,13,16,20,29]</sup> Dividing the clinical presentation as ischemic/mass effect and hemorrhage symptoms, it can be seen that the majority of symptoms are caused by ischemic/mass effect.<sup>[2,7,24,26,27]</sup> The fusiform aneurysms is often presented in the posterior circulation, mainly in the VA followed by the basilar, PICA, and PCA.<sup>[2,20,24-26]</sup> The atherosclerosis seems to influence the rate of distribution from this aneurysm pattern. Patients with atherosclerotic aneurysms are more likely to have posterior circulation aneurysms and patients with

**Table 4: Compares the data about surgical, reconstructive, and deconstructive treatment of blister-like aneurysms**

Blister-like aneurysms				
Publication year – study – number of patients	Treatment presented	Performed procedure	Complications	Good outcome
2015 – Rouchaud <i>et al.</i> – 265	Reconstructive versus deconstructive treatment	Flow diversion reconstructive EVT	9.2% did not present mid-to-long-term complete occlusion 6.6% retreatment 12.6% perioperative morbidity 8.7% perioperative mortality	86%
		Nonflow diverter reconstructive EVT	30.3% did not present mid-to-long-term complete occlusion 27.1% retreatment 13.2% perioperative morbidity 7.2% perioperative mortality	75%
		Deconstructive EVT	29.1% perioperative stroke	79.90%
2014 – Gonzalez <i>et al.</i> – 12	Reconstructive treatment	Stent-assisted coiling or flow diversion	The treatment failed in 9% of the patient The microcatheters were unstable in 9% 18.2% surgical retreatment	91%
2014 – Gonzalez <i>et al.</i> – 303	Surgical versus deconstructive versus reconstructive treatment	Surgical clipping	30% perioperative complications 21% retreatment 26.5% morbi-mortality	73.50%
		Surgical trapping	5% regrowth 30% rebleeding 6.5% morbi-mortality	93.50%
		Stent-assisted coiling	38% regrowth 12.5% rebleeding 46% retreatment 10% morbi-mortality	90%
		Overall reconstructive EVT	17.2% morbi-mortality	82.80%
		Overall deconstructive EVT	0% morbi-mortality	100%
2014 – Fang <i>et al.</i> – 15	Reconstructive treatment	Stent-assisted coiling with triple or quadruple stents	0% complicated	93.30%
		Stent-assisted coiling with double stents	33.4% major recanalization	
Average	The overall reconstructive treatments morbi-mortality were 15% The surgical morbi-mortality techniques were 29.75% The overall deconstructive treatments morbi-mortality were 10% The flow diversion showed good rates of morbi-mortality with an average rate of 10.65% Reconstructive EVT presented a good outcome rate of 85.62% Deconstructive EVT presented a good outcome rate of 89.95% Surgical treatment presented a good outcome rate of 83.5%			

The treatment and its most common complications and their outcome. EVT: Endovascular treatment

nonatherosclerotics aneurysms are more likely to present anterior circulation aneurysms according to Sacho *et al.*<sup>[25]</sup> Reconstructive and deconstructive techniques are both effective.<sup>[8,17,28]</sup> Reconstructive is safer than deconstructive techniques, particularly in cases in

which patients lack sufficient collateral circulation. The most important feature of an aneurysm to predict a bad prognosis is to determine if the aneurysm is ruptured.<sup>[4,8,17,28]</sup> The atherosclerosis is a risk factor for an aneurysm rupture.<sup>[25]</sup>

**Table 5: The main types of nonsaccular aneurysms are compared**

	<b>Fusiform</b>	<b>Mycotic</b>	<b>Blister-like</b>
Mean age	Pediatric population, young adults <50 years	38.6 years	53.35 years
Most affected sex	Male	Male	Female
Artery most affected	Vertebral artery	Middle cerebral artery	Supraclinoid segment of the internal carotid
Most common clinical presentation	Symptoms due to ischemic or mass effect	Symptoms due to hemorrhage	Symptoms due to hemorrhage
Treatment of choice		Reconstructive endovascular treatment	

The mean age, most affected sex, artery most affected, and the most common cause for the symptoms onset presented are analyzed to characterize and mark the differences between them

A total of 15 patients presenting with MAs were analyzed. The mean age of the analyzed patients was 38.6 years. The man represented 66% of the patients. The pathogens that caused the MAs were as follows: 75% were due to *Streptococcus* sp. (66% *S. mitis*), 25% due to *E. faecalis*. All patients analyzed presented with ruptured MA, showing the importance of the hemorrhage in this vasculopathy. All of the MAs analyzed in the presented study were at the anterior circulation: 66.6% at the MCA, 20% at the cavernous carotid, and 13.3% at the ACA. All the patients analyzed for this feature (5 of 15) presented with endocarditis.<sup>[9,30,32]</sup> In patients with IE, septic emboli from cardiac valves may lodge at intracranial vessels at branching points or distal segments. These emboli may also cause focal infection and corrupt the vessel wall, which subsequently gives rise to aneurysm formation. Therefore, targeting the underlying cardiac disorders is mandatory in the treatment of IE-related intracranial MAs. However, case presented by Wang *et al.*<sup>[30]</sup> indicates that even successful treatment of cardiac disorders may not guarantee the absence of MAS formation. According his group, the delayed formation of the second intracranial MA seen in the case is probably due to the spread of septic emboli preceding the cardiac surgery with an incubation period after the emboli lodgment and before the aneurysm formation. Long-term intravenous antibiotics for 4–6 weeks have been recommended for the treatment of intracranial MAs. Sometimes, mere antibiotic treatment leads to complete resolution of the aneurysm. As it can be seen in the second intracranial MA formed and ruptured despite long-term antibiotic treatment between the two attacks,<sup>[30]</sup> the therapeutic effect of antibiotic treatment appears to vary in individuals, and hence, close angiographic follow-up is necessary in patients with intracranial MAs. In summary, intracranial MAs may develop in a delayed form even after successful management of the underlying cardiac disorder. Therefore, close angiographic follow-up may be warranted following the cardiac surgery.<sup>[30]</sup> Endovascular surgery for ruptured MAs has definitely reduced the previously high mortality of 60–90%. Surgery has to be considered as soon as possible, if an MA does not resolve after appropriate antibiotic therapy or enlarges

during treatment. If the aneurysm has ruptured, a more aggressive approach should be considered because of the high mortality associated with ruptured MAs. The affected vessel and the aneurysm may be extremely fragile, so EVT is associated with greater risks than usual but is considered less invasive and more effective than craniotomy under general anesthesia for patients with poor cardiac condition due to IE. Introduction of a foreign substance into an infective field such as a mycotic aneurysm may be hazardous, but the endovascular procedure is effective because inflammation does not reoccur.<sup>[32]</sup> The use of reconstructive endovascular procedures (stent-assisted coil embolization, only coiling of the aneurysm) to treat MIA showed good results.<sup>[9,19,32]</sup> Deconstructive techniques also presented good outcomes in arteries without numerous branches (such as the distal branch of the left MCA).<sup>[30]</sup> The most important point of the treatment is the use of antibiotic therapy.<sup>[14,19,30,32]</sup> Proper treatment of the pathogens with antibiotic therapy reduces the risk of stent infectious. Intracranial stenting is proving to be safer and more effective to treat select cases of MIA.<sup>[9]</sup> The complications seen were meningitis, recurrence, rebleeding, enlargement, and dead.

Around 334 patients that presented BLAs were analyzed. Fifty percent of them after undergoing a CT scan and CT angiogram in the emergency room did not detect any aneurysm. The mean age of the patients was 53.35 years and 72% were women. High blood pressure is an already detected risk factor. All the aneurysms with data about its localization (12 of 334) were at the supraclinoid ICA: 66.6% in the right supraclinoid ICA segment and 33.4% in the left. Most of the BLAs are smaller than 4 mm. BBAs are frequently associated with hemorrhage and can have rapid growth and high rebleeding rates if not quickly and completely occluded. About 99% of the patients presented with SAH. Regrowth and Rebleeding were the most recurrent complications. The BBA should be treated at the earliest time after its diagnosis,<sup>[12]</sup> and early angiographic follow-up within 2 weeks is recommended.<sup>[11]</sup> The number of additional procedures was higher for patients allocated to EVT compared with those allocated to surgery. However,

EVT has a lower morbi-mortality compared to surgical approaches.<sup>[12]</sup> Reconstructive techniques with parent artery preservation are associated with similar rates of angiographic occlusion and improved clinical outcomes compared with deconstructive parent artery sacrifice. The main problem with parent vessel occlusion with balloons and/or coils is the presence of important side branches, like the ophthalmic artery, anterior choroid, and fetal presentation of the posterior communicating artery in the intracranial segment of the ICA. Coiling of BBAs has been associated with a high intraprocedural rupture rate. The possibility of performing a parent vessel reconstruction appears to be a more physiological method to avoid intra-saccular treatments.<sup>[12]</sup> Patients treated with deconstructive techniques not only had higher rates of complete occlusion on immediate posttreatment angiography than those treated with reconstructive techniques but also had a higher risk for perioperative stroke. Patients treated with flow-diverter stents had higher rates of mid-to-long-term complete occlusion than those treated with other reconstructive techniques and a lower rate of retreatment. Perioperative morbidity rates in the flow-diverter group compared with the non-flow-diverter reconstructive group were similar. Mid-to-long-term good clinical outcome rates were statistically similar between the flow-diverter group and non-flow-diverter reconstructive and perioperative ICH rates were similar between both groups. These findings suggest that reconstructive techniques are as effective and potentially safer than endovascular parent artery occlusion, considering the ischemic risk.<sup>[12,23]</sup> These findings are important, especially in deciding treatment options for patients who cannot tolerate parent artery occlusion.<sup>[23]</sup> When considering differences between different reconstructive techniques, meta-analysis of Rouchaud *et al.*<sup>[23]</sup> and Gonzalez *et al.*<sup>[12]</sup> demonstrated that flow-diverter stents result in better occlusion rates and lower retreatment rates than non-flow-diverter reconstructive techniques (simple coiling, stent-assisted coiling, or overlapped stents). They found a trend toward better clinical outcomes with flow-diverter techniques, such as the higher rate of the overall mid-to-long-term occlusion compared with initial occlusion. Rouchaud *et al.*<sup>[23]</sup> theorize that this improvement is mostly due to the remodeling after FD because the patients that underwent this procedure experienced an occlusion rate increase from 35.9% to 90.8%, while patients treated with non-flow-diverter endovascular reconstructive techniques experienced an increase from 32.8% initial occlusion to 67.9% at mid-to-long-term follow-up, and occlusion rates were quite stable for deconstructive techniques, varying only from 77.3% to 81% between initial and mid-to-long-term evaluations. This increase in occlusion rates is potentially also driven by the interruption of antiplatelet treatment for flow-diversion and non-flow-diversion reconstructive techniques. The

higher morbidity and mortality rates among surgically treated aneurysms are probably partially due to those aneurysms that lack a definitive saccular component and their parent vessel wall is often friable and involves a long vessel segment. These features tend to result in high intraoperative rupture rates.<sup>[23]</sup> When reconstructive EVTs are not feasible, a direct clipping approach with a Sundt clip graft may prove to be a rather useful treatment modality for fragile aneurysm.<sup>[5]</sup>

Nonsaccular aneurysms are characterized by a vessel elongation, dilation, and/or tortuosity. The final appearance is probably due to a variety of different processes, which may account for the difference seen in the natural history and prognosis. FD represents a promising treatment option for nonsaccular aneurysms. Early treatment is proposed prior to the development of symptoms and when the maximum diameter and length of the diseased segment is minimized.<sup>[3]</sup>

## CONCLUSION

All types of nonsaccular aneurysms have a higher prevalence in young adults. Men are more affected by fusiform and MAs while women suffer more with BLAs. The mycotic and the BLAs affect more the anterior circulation while the fusiform affect more the posterior circulation. Mycotic and blister-like have as its major complication and clinical presentation the hemorrhage. However, the fusiform aneurysms usually present ischemia and/or mass effect. The reconstructive endovascular techniques for all types of nonsaccular aneurysms presented as the treatment with the best outcomes. Among this technique, the FD presented good results in all types of aneurysms and it seems to promote the best outcomes.

## Financial support and sponsorship

Nil.

## Conflicts of interest

There are no conflicts of interest.

## REFERENCES

1. Al-Mufti F, Amuluru K, Gandhi CD, Prestigiacomo CJ. Flow diversion for intracranial aneurysm management: A new standard of care. *Neurotherapeutics* 2016;13:582-9.
2. Bhogal P, Pérez MA, Ganslandt O, Bätzner H, Henkes H, Fischer S, *et al.* Treatment of posterior circulation non-saccular aneurysms with flow diverters: A single-center experience and review of 56 patients. *J Neurointerv Surg* 2017;9:471-81.
3. Kim BM, Shin YS, Kim SH, Suh SH, Ihn YK, Kim DI, *et al.* Incidence and risk factors of recurrence after endovascular treatment of intracranial vertebrobasilar dissecting aneurysms. *Stroke* 2011;42:2425-30.
4. Cho JI, Cho JH. Use of the sundt clip graft in a previously coiled internal carotid artery blister-like aneurysm. *J Korean Neurosurg Soc* 2014;56:496-9.
5. Dabus G, Lin E, Linfante I. Endovascular treatment of fusiform intracranial vertebral artery aneurysms using reconstructive techniques. *J Neurointerv Surg* 2014;6:589-94.

6. Day AL, Gaposchkin CG, Yu CJ, Rivet DJ, Dacey RG Jr. Spontaneous fusiform middle cerebral artery aneurysms: Characteristics and a proposed mechanism of formation. *J Neurosurg* 2003;99:228-40.
7. Devulapalli KK, Chowdhry SA, Bambakidis NC, Selman W, Hsu DP. Endovascular treatment of fusiform intracranial aneurysms. *J Neurointerv Surg* 2013;5:110-6.
8. Ding D, Raper DM, Carswell AJ, Liu KC. Endovascular stenting for treatment of mycotic intracranial aneurysms. *J Clin Neurosci* 2014;21:1163-8.
9. Eller JL, Dumont TM, Sorkin GC, Mokin M, Levy EI, Snyder KV, et al. The pipeline embolization device for treatment of intracranial aneurysms. *Expert Rev Med Devices* 2014;11:137-50.
10. Fang YB, Li Q, Wu YN, Zhang Q, Yang PF, Zhao WY, et al. Overlapping stents for blood blister-like aneurysms of the internal carotid artery. *Clin Neurol Neurosurg* 2014;123:34-9.
11. Gonzalez AM, Narata AP, Yilmaz H, Bijlenga P, Radovanovic I, Schaller K, et al. Blood blister-like aneurysms: Single center experience and systematic literature review. *Eur J Radiol* 2014;83:197-205.
12. Gross BA, Smith ER, Scott RM, Orbach DB. Intracranial aneurysms in the youngest patients: Characteristics and treatment challenges. *Pediatr Neurosurg* 2015;50:18-25.
13. Hamisch CA, Mpotsaris A, Timmer M, Reiner M, Stavrinou P, Brinker G, et al. Interdisciplinary treatment of intracranial infectious aneurysms. *Cerebrovasc Dis* 2016;42:493-505.
14. Ji T, Guo Y, Huang X, Xu B, Xu K, Yu J, et al. Current status of the treatment of blood blister-like aneurysms of the supraclinoid internal carotid artery: A review. *Int J Med Sci* 2017;14:390-402.
15. Kan P, Mokin M, Puri AS, Wakhloo AK. Successful treatment of a giant pediatric fusiform basilar trunk aneurysm with surpass flow diverter. *BMJ Case Rep* 2015;2015. pii: bcr2015011718.
16. Kashiwazaki D, Ushikoshi S, Asano T, Kuroda S, Houkin K. Long-term clinical and radiological results of endovascular internal trapping in vertebral artery dissection. *Neuroradiology* 2013;55:201-6.
17. Kizilkilic O, Kayadibi Y, Sanus GZ, Koçer N, Islak C. Combined endovascular and surgical treatment of fusiform aneurysms of the basilar artery: Technical note. *Acta Neurochir (Wien)* 2014;156:53-61.
18. Lotan E, Orion D, Bakon M, Kuperstein R, Greenberg G. Ruptured intracranial mycotic aneurysm in infective endocarditis: Radiological and clinical findings. *Isr Med Assoc J* 2014;16:317-9.
19. Onofrij V, Cortes M, Tampieri D. The insidious appearance of the dissecting aneurysm: Imaging findings and related pathophysiology. A report of two cases. *Interv Neuroradiol* 2016;22:638-42.
20. Ota N, Tanikawa R, Kamiyama H, Miyazaki T, Noda K, Katsuno M, et al. Discrepancy between preoperative imaging and postoperative pathological finding of ruptured intracranial dissecting aneurysm, and its surgical treatment: Case report. *Neurol Med Chir (Tokyo)* 2014;54:219-26.
21. Park PJ, Meyer FB. The sunndt clip graft. *Neurosurgery* 2010;66:300-5.
22. Park SH, Yim MB, Lee CY, Kim E, Son EI. Intracranial fusiform aneurysms: It's pathogenesis, clinical characteristics and managements. *J Korean Neurosurg Soc* 2008;44:116-23.
23. Rouchaud A, Brinjikji W, Cloft HJ, Kallmes DF. Endovascular treatment of ruptured blister-like aneurysms: A systematic review and meta-analysis with focus on deconstructive versus reconstructive and flow-diverter treatments. *AJNR Am J Neuroradiol* 2015;36:2331-9.
24. Sacho RH, Saliou G, Kostynsky A, Menezes R, Tymianski M, Krings T, et al. Natural history and outcome after treatment of unruptured intradural fusiform aneurysms. *Stroke* 2014;45:3251-6.
25. Schnell S, Ansari SA, Vakil P, Wasielewski M, Carr ML, Hurley MC, et al. Three-dimensional hemodynamics in intracranial aneurysms: Influence of size and morphology. *J Magn Reson Imaging* 2014;39:120-31.
26. Serrone JC, Gozal YM, Grossman AW, Andaluz N, Abruzzo T, Zuccarello M, et al. Vertebrobasilar fusiform aneurysms. *Neurosurg Clin N Am* 2014;25:471-84.
27. Sönmez Ö, Brinjikji W, Murad MH, Lanzino G. Deconstructive and reconstructive techniques in treatment of vertebrobasilar dissecting aneurysms: A systematic review and meta-analysis. *AJNR Am J Neuroradiol* 2015;36:1293-8.
28. Takemoto K, Tateshima S, Golshan A, Gonzalez N, Jahan R, Duckwiler G, et al. Endovascular treatment of pediatric intracranial aneurysms: A retrospective study of 35 aneurysms. *J Neurointerv Surg* 2014;6:432-8.
29. Wang K, Sun J, Zhang X, Zhang Q, Chen Z. Management of consecutive development of ruptured intracranial mycotic aneurysms: Case report. *Turk Neurosurg* 2015;25:310-2.
30. Wang Y, Yang X, Youxiang L, Shiqing M, Chuhan J, Zhongxue W, et al. Treatment of symptomatic fusiform aneurysm in basilar artery by stenting following coiling technique. *Turk Neurosurg* 2014;24:44-7.
31. Watanabe A, Hirano K, Ishii R. Cerebral mycotic aneurysm treated with endovascular occlusion. *Neurol Med Chir (Tokyo)* 1998;38:657-60.
32. Zhang Y, Tian Z, Sui B, Wang Y, Liu J, Li M, et al. Endovascular treatment of spontaneous intracranial fusiform and dissecting aneurysms: Outcomes related to imaging classification of 309 cases. *World Neurosurg* 2017;98:444-55.