

A Scoring System to Demonstrate the Risk for Bone Injury in Patients with Clinically Suspected or Occult Scaphoid Fracture

Abstract

Background: It is important to diagnose a scaphoid fracture accurately and start the correct treatment in the shortest time possible. However, the fracture of bone may not be visible on x-ray. In such cases, patients are clinically diagnosed with suspected or occult scaphoid fractures. The aim of this study was to define a scoring system based on physical examination to demonstrate the risk for bone injury in patients with clinically suspected and occult scaphoid fractures with negative radiographs and anatomical snuff box tenderness and to decrease the costs and workforce loss due to unnecessary treatment and magnetic resonance imaging (MRI). **Materials and Methods:** Patients were initially evaluated by the attendant orthopedic physician in the emergency service with X-ray of the wrist, and ten wrist physical examination techniques were used. The X-rays of patients were evaluated by three orthopedic surgeons. Finally sixty patients, who were diagnosed as having no fracture by all three orthopedic surgeon, were included in the study. The wrists of these patients were evaluated with MRI. **Results:** There were 46 male (77%) and 14 female (23%) patients with a mean age of 21.5 years (range 7–61 years). About 3.3% had triquetrum fracture, 15% had bone edema in the scaphoid and radius, 18.3% had distal radius fracture, 31.6% had scaphoid fracture, and 31.8% had no bone injury. A scoring system was also proposed. It can be predicted that in the physical examination of the wrist if the total score is higher than 6.5, the probability of fracture is 2.87 (positive likelihood ratio) fold compared to scores below 6.5. **Conclusions:** Proposal of this new scoring system was thought to be useful for predicting the risk for bone injury in patients with clinically suspected scaphoid fractures and making decision regarding therapeutic options.

Keywords: Bone injury, occult, scaphoid fracture, scoring system

MeSH terms: Scaphoid bone, carpal bones, bone fractures, radiography

H Bahadır Gokcen,
 Mehmet Akif Akcal¹,
 Koray Unay²,
 Selahattin Ozyurek³,
 Oguz Poyanli⁴,
 Irfan Esenkaya⁵

Department of Orthopedics and Traumatology, Istinye University,
²Department of Orthopedics and Traumatology, Medivia Hospital,
³Department of Orthopedics and Traumatology, LIV Hospital,
⁴Department of Orthopedics and Traumatology, Goztepe Training and Research Hospital,
⁵Department of Orthopedics and Traumatology, Istanbul Medeniyet University Goztepe Training and Research Hospital, Istanbul, ¹Department of Orthopedics and Traumatology, Antalya Atatürk State Hospital, Antalya, Turkey

Introduction

Scaphoid fracture is more common in young and active individuals.^{1,2} These patients have a high demand to return to work and sport activities as soon as possible. Therefore, it is important to diagnose a scaphoid fracture accurately and start the correct treatment in the shortest time possible. However, the fracture of bone may not be visible on X-ray. In such cases, patients are clinically diagnosed with suspected or occult scaphoid fractures. It is generally accepted that delay in diagnosis and treatment of scaphoid fractures can lead to nonunion or malunion and can eventually result in symptomatic osteonecrosis, carpal instability, or secondary osteoarthritis.² For these reasons, suspected scaphoid fracture patients should be followed up closely with scaphoid plaster or splint.^{2,3} The use of magnetic resonance imaging (MRI) for detecting occult scaphoid fracture is

highly definitive.^{4,5} On the other hand, the use of conventional plaster, splint, and close followup methods can cause extra treatments, workforce shortage, and high costs. Despite advantages of advanced imaging techniques, there is still conflict about the usage and cost of MRI in the early phase of the fracture^{6,7} as most suspected scaphoid fractures are not real scaphoid fractures.²

In the differential diagnosis of some patients, occult radius fracture, occult carpal bone fracture, or bone contusion should be considered. To make differentiation among these diagnoses, physical examination findings can be helpful. We believe that in clinically suspected scaphoid fracture patients, some physical examination findings are very powerful to demonstrate the bone injury. The target group of this study was patients who had fallen on their wrists, with tenderness in the anatomical snuffbox and

Address for correspondence:

Dr. H Bahadır Gokcen,
 Department of Orthopedics and Traumatology, Istinye University, 34010 Zeytinburnu, Istanbul, Turkey.
 E-mail: bahadrgokcen@gmail.com

Access this article online

Website: www.ijoonline.com

DOI:
 10.4103/ortho.IJOrtho_262_16

Quick Response Code:



How to cite this article: Gokcen HB, Akcal MA, Unay K, Ozyurek S, Poyanli O, Esenkaya I. A scoring system to demonstrate the risk for bone injury in patients with clinically suspected or occult scaphoid fracture. Indian J Orthop 2018;52:184-9.

This is an open access article distributed under the terms of the Creative Commons Attribution-NonCommercial-ShareAlike 3.0 License, which allows others to remix, tweak, and build upon the work non-commercially, as long as the author is credited and the new creations are licensed under the identical terms.

For reprints contact: reprints@medknow.com

without a visible fracture in the X-rays. In patients suspected of scaphoid fracture clinically but with no fracture line seen in the X-rays, we suggest that just like the scaphoid bone, the other wrist bones may be injured too.

The aim of this study was to define a new scoring system based on physical examination methods to demonstrate the risk for bone injury in suspected clinically scaphoid fracture patients. For this, ten physical examination methods were used in this study. In addition to physical examination, the patients' wrist MRI was taken. In clinically suspected scaphoid fracture patients, we suggest that with the use of most appropriate physical examination methods to demonstrate the wrist injury, the costs and workforce loss due to unnecessary treatment and MRI can be decreased.

Materials and Methods

This study target group was chosen from 352 patients, who presented at emergency service between 2013 and 2015 with the history of having fall on the wrist. Patients were initially evaluated by the orthopedic resident in the emergency service with radiography of the wrist in four views (anteroposterior/lateral/oblique and scaphoid). Fracture was detected in the scaphoid or other wrist bones in 158 patients and no fracture in the remaining 194 patients. Of the total, 194 patients without fracture at scaphoid or other wrist bones included in the study. A total of 10 wrist physical examination techniques (E1–E10) were used [Table 1]. Physical examination tests were performed in consecutive order. Pain is evaluated with the maneuvers applied to the anatomical snuffbox, scaphoid tubercle, and radio-scaphoid region. The results of the examination tests were recorded as positive or negative. The results and the examination findings of all the 194 patients were recorded.

The data collection of 194 patients was completed, and X-rays were evaluated by three orthopedic surgeons with at least 10 years clinical experience. They were briefed about the patient's trauma mechanism and physical examination results. According to this, the patients that were diagnosed as having no fracture by all three orthopedic surgeons were included in the study [Figure 1]. The other patients

were excluded from the study. A total of sixty patients met the above criteria. The wrists of the patients were evaluated with MRI using the same machine with 1.5 T superconductivity [Figure 2]. These patients were 46 male (77%) and 14 female (23%) with a mean age of 21.5 years (range 7–61 years).

Statistical analysis

Statistical analyses were performed using NCSS 2007 program. To evaluate the data besides the descriptive statistical methods (mean, standard deviation) “independent *t*-test” to compare the dual groups, “Chi-square test” to compare qualitative data and “odds ratio (OR)” for disease risk were used. For the total score, the approximation point was designated with receiver operating characteristic (ROC) analysis. The results were evaluated as significance $P < 0.05$ and 95% confidential interval.

According to physical examination findings, for the E1–E10 points used, univariate analysis was performed and OR was calculated. Points able to discriminate normal and pathological states and high-risk examination significance and the calculated results were emphasized. Then, to determine the significance of these points, sensitivity, specificity, positive predictive value (PV), negative PV, and maximum likelihood ratios (LR+) were calculated. Significant examination points were also determined here. Then, including all of these examination points, multivariate analysis was performed and OR was calculated. Ultimately, all the OR, adjusted OR and LR + values were observed

Table 1: The wrist physical examination tests used in the study

Examination Number	Examination Name
E1	Abduction of the thumb
E2	Radial deviation of the wrist
E3	Axial loading of the thumb
E4	Flexion of the wrist (volar flexion)
E5	Extension of the wrist (dorsal flexion)
E6	Power grip of the hand
E7	Ulnar deviation of the wrist
E8	Pronation of the forearm
E9	Supination of the forearm
E10	Thumb-index finger pinch

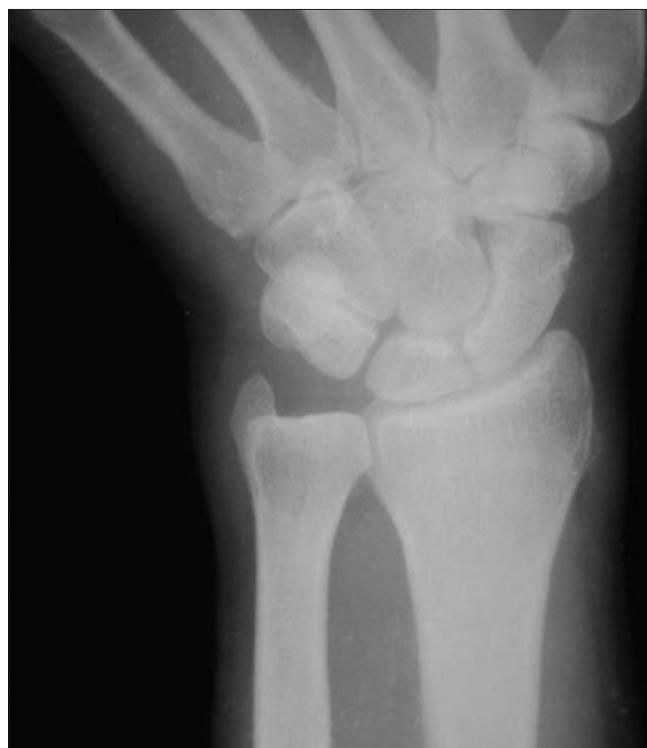

Figure 1: Scaphoid view of the wrist in patient with anatomical snuff box tenderness

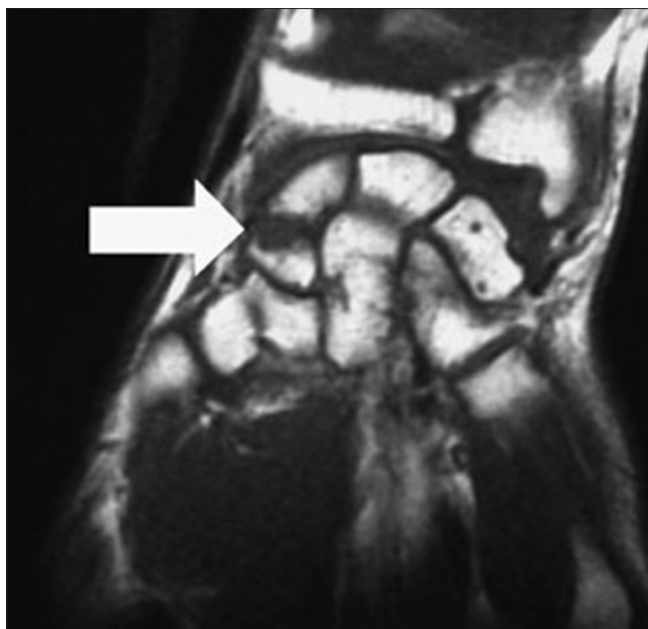


Figure 2: Magnetic resonance imaging of patient with clinically suspected and occult scaphoid fracture with anatomical snuff box tenderness and negative radiographs showing Scaphoid fracture line (white arrow)

together, the OR and other risks were observed as compatible and in some points higher.

Results

60 clinically suspected scaphoid fracture patients were included in this study. On examination of the MRI results, 3.3% (n=2) had triquetrum fracture, 15% (n=9) had bone edema in the scaphoid and radius, 18.3% (n=11) had distal radius fracture 31.6% (n=19) had scaphoid fracture and remaining 31.6% (n=19) had no bone injury.

A scoring range between 1 and 10 was formed depending on the value of adjusted OR [Table 2]. In the forced pronation of the forearm, the constitution of pain in the scaphoid tubercle and radio-scaphoid region has the highest PV to detect the scaphoid or other wrist bone fractures in suspected occult scaphoid fracture patients. This was followed by the pain around the wrist joint with thumb–index finger pinch and supination of the forearm. The other seven examination methods also had value within their scope. Thus, a total score was obtained by grading all the examination points according to importance [Table 3].

The mean values of the total score for normal and pathological groups were compared. The mean total score of the pathological group was found to be statistically significantly higher than that of the normal group ($P = 0.0001$).

The purpose of the mean total score is to find the predictor point and indicate the start point of the disease. The area under ROC trajectory was found. More than 6.5 value at total score had the most sensitive, specific value and was determined as a predictor point [Table 4]. According to

Table 2: E1-E10 multivariate analysis and odds ratio

Tests	Score	Adjusted OR (95% CI)	OR (95% CI)	LR positive
E1	1	1.01 (0.18-5.62)	1.47 (0.41-5.30)	1.09
E2	1	1.35 (0.21-8.86)	1.73 (0.34-8.7)	1.07
E3	0.25	0.47 (0.09-2.42)	0.95 (0.31-2.8)	0.97
E4	1	1.02 (0.12-8.60)	1.73 (0.34-8.7)	1.07
E5	0.25	0.57 (0.10-3.30)	2.47 (0.54-11.2)	1.14
E6	0.25	0.36 (0.05-2.78)	0.68 (0.12-3.76)	0.95
E7	0.25	0.61 (0.11-3.25)	1.26 (0.38-4.13)	1.07
E8	3	3.84 (0.53-12.68)	5.14 (1.59-16.67)	2.05
E9	1.5	1.78 (0.29-11.09)	4.26 (1.34-13.6)	1.80
E10	1.5	1.72 (0.36-8.29)	4.37 (1.3-14.7)	1.31

E=Examination test, LR=Likelihood ratio, OR=Odds ratio, CI=Confidence interval

Table 3: Scoring range of examination tests depending on the value of corrected odds ratio

Examination tests	OR score
E1*	1
E2*	1
E3*	0.25
E4*	1
E5*	0.25
E6*	0.25
E7*	0.25
E8*	3
E9*	1.5
E10*	1.5
Total score of E1-E10	10

*Examination test is positive and adds the score of the examination test in the total score. OR=Odds ratio, E=Examination tests

this scoring system, it can be predicted that in the physical examination of the wrist if the total score of examination tests is higher than 6.5, the probability of fracture is 2.87-fold compared to scores below 6.5.

Discussion

In many clinically suspected scaphoid fracture patients, radial and carpal bone injuries may also exist. According to the previous studies conducted on patients with clinically suspected scaphoid fracture, 13.3%–34.1% had real scaphoid fracture, 0%–25% had distal radius fracture, 0%–0.5% had hamate fracture, 0%–10% had capitate fracture, 0%–2% had triquetrum fracture, 0%–1% had trapezium fracture, 0%–1% had trapezoid fracture, 0.5% had metacarpal fracture, and 10.3% had bone injury.^{4,6,8,9} In this study, of the sixty clinically suspected scaphoid fracture patients, 3.3% had triquetrum fracture, 15% had bone edema in the scaphoid and radius, 18.3% had distal radius fracture, 31.6% had scaphoid fracture, and 31.6% had no bone injury. These results are similar to the results of the aforementioned studies. Rates of triquetrum fracture and bone injury in the current study were found to be higher

Table 4: Receiver operating characteristic trajectory

Total score	Sensitivity	Specificity	LR positive
≥1.5	100.0	0.0	1.00
>1.5	100.0	5.3	1.06
>2.25	100.0	10.5	1.12
>2.5	100.0	15.8	1.19
>2.75	97.6	21.1	1.24
>3	97.6	26.3	1.32
>3.5	95.1	26.3	1.29
>3.75	92.7	36.8	1.47
>4.25	87.8	36.8	1.39
>4.5	87.8	47.4	1.67
>5	82.9	47.4	1.58
>5.25	80.5	57.9	1.91
>5.5	80.5	63.2	2.18
>5.75	75.6	68.4	2.39
>6.5	75.6	73.7	2.87
>7	70.7	73.7	2.69
>7.25	68.3	73.7	2.60
>7.5	65.9	73.7	2.50
>7.75	65.9	78.9	3.13
>8	63.4	78.9	3.01
>8.25	61.0	78.9	2.90
>8.5	51.2	78.9	2.40
>8.75	51.2	84.2	3.24
>9.25	48.8	84.2	3.09
>9.5	41.5	84.2	2.63
>9.75	34.1	84.2	2.16
>10	0.0	100.0	0

More than 6.5 value at total score is predictor point of the scoring system. LR=Likelihood ratio, PV=Predictive value

than in the previous studies. However, among the carpal bones, apart from the scaphoid only triquetrum fracture was detected. The reason for this may be because of differences in the patient group in this study as only patients with tenderness in the anatomical snuffbox were included in this study. Anatomic snuffbox tenderness has been considered an indicator of a possible fracture of scaphoid bone for many years.¹⁰ In one study, examining only the tenderness in the anatomical snuffbox resulted in extra treatment in 85% of the patients with an acute wrist injury.¹¹ Using it alone to diagnose, a scaphoid fracture can be problematic due to its high sensitivity, and during physical examination, there can be tenderness in the anatomical snuffbox together with fracture of radial styloid and distal radius, trapezium fracture and first and second metacarpal fractures.¹²

Many authors have defined clinical findings and tests for scaphoid fractures.^{10,13-18} In a study by Waizenegger *et al.*, which tested 12 examination methods in 52 patients with clinically suspected scaphoid fracture, it was reported that none of the examination methods alone was able to distinguish scaphoid fractures.¹⁹ In this study, 10 physical examination methods were used: abduction of thumb, radial deviation of the wrist, thumb axial loading, flexion of the

wrist, extension of the wrist, power grip of the hand, ulnar deviation of the wrist, pronation of the forearm, supination of the forearm, and thumb–index finger pinch. According to the results, in suspected occult scaphoid fracture patients, pain around the wrist during the pronation of forearm has the highest PV to determine scaphoid or other wrist bone fractures, followed by pain thumb–index finger pinch and pain around the wrist with forced supination of the forearm. As in the aforementioned studies, we too believe that none of the examination methods alone is diagnostic. Therefore, 10 examination methods were used together to conduct the study. However, these examinations were not performed by the same orthopedic surgeon on all patients. The patients were first evaluated by the attendant orthopedic surgeon in the emergency clinic. The initial examination by different clinicians may be a limitation of the current study. However, to the best of our knowledge, there are no reports in the literature on limitations related to examinations performed by different clinicians. Nevertheless, as the signs were based on the patient’s subjective interpretation of pain, it can be presumed that the difference between the evaluators is minimal.¹⁸ Multi-dimensional treatment should be considered for the patient group clinically suspected of scaphoid fracture with no fracture line evident on X-rays. As previously mentioned, an alternative to the conventional treatment approach is the use of advanced imaging methods. Many methods can be used secondarily, one of which is MRI.^{8,20} After clinical examination, the patients in this study were evaluated by MRI which is a method that has proved to be beneficial and has very high accuracy in the diagnosis of scaphoid fractures, avascular necrosis, ligament injury, and carpal instability.^{4,5,8,21} Early MRI can prevent productivity loss in patients who are unnecessarily immobilized in a splint.^{22,23} The perfect consensus has been observed even among the variable reviewers of MRI.²⁴ Examination of an experienced hand surgeon has been reported to be highly valuable in diagnosis of scaphoid fracture.²⁵ However, it may be more difficult to find an experienced hand surgeon in every hospital than to find an MRI machine. Bone scintigraphy,^{19,26,27} high-resolution sonography,^{20,28} and multidetector computed tomography²⁹ are other imaging methods used to determine scaphoid fractures in literature.

One of the questions that our study tries to answer is that of for which patient group is advanced imaging required. The second question is, which examination methods demonstrate the bone injury risk in patients with a wrist injury and tenderness in the anatomic snuffbox? As previously mentioned, many examination methods have been described.³⁰ Each of the ten examination methods used in this study is known to have its value. According to the results of examination methods used in this study, pain development during forced pronation of the forearm has the highest Predictive Value (PV) when compared with the other nine examination methods. This was followed by pain arising around the wrist joint with thumb–index finger pinch

and supination of the forearm. Ten wrist physical examination methods used in this study were statistically analyzed. A scoring range of 1 to 10 was established depending on the statistical results. The mean values of the total score for normal and pathological groups were compared and a score was performed by grading all the examination points according to importance. To find the predictor point and indicate the start point of the disease was important to create a mean total score for a useful formula to demonstrate the risk for bone injury in patients with clinically suspected and occult scaphoid fracture. More than 6.5 value at total score (the area under ROC trajectory) had the most sensitive, specific value and was determined as a predictor point. This indicates that if the sum of the scores shown in Table 3 for each examination method used in this study is more than 6.5, there will be a risk of bone injury. According to this, in patients with tenderness in the anatomic snuffbox, instead of deciding the bone injury by one or two examination methods, it would seem to be more accurate to decide by ten examination methods. From the total score obtained here (>6.5), it can be predicted whether or not the patient needs an advanced imaging method. If a hospital has no advanced imaging methods available, bone injury risk can be evaluated according to this score. Accordingly, a plaster or splint will be applied to the patient and called for follow-up appointments. This will avoid unnecessarily immobilization of the wrist and loss of work force.

Conclusion

It may not be correct to evaluate a patient with wrist trauma with only one examination method. Tenderness in the anatomic snuffbox does not always predict scaphoid fracture. With the use of a scoring system, fracture risk can be predicted beforehand if the total score is >6.5. In this way, the loss of workforce and costs of extra treatments and imaging methods can be prevented.

Declaration of patient consent

The authors certify that they have obtained all appropriate patient consent forms. In the form the patient(s) has/have given his/her/their consent for his/her/their images and other clinical information to be reported in the journal. The patients understand that their names and initials will not be published and due efforts will be made to conceal their identity, but anonymity cannot be guaranteed.

Financial support and sponsorship

Nil.

Conflicts of interest

There are no conflicts of interest.

References

1. Wolfe SW. Fractures of the carpus: Scaphoid fractures. In: Berger AR, Weiss AP, editors. *Hand Surgery*. 1st ed., Vol. II, Ch. 21. Philadelphia Lippincott Williams & Wilkins; 2004.
2. Toh S. Fractures of the scaphoid: In: Ring DC, Cohen MS, editors. *Fractures of the Hand and Wrist*. New York: Informa Health Care; 2007. p. 115-36.
3. N'Dow J, N'Dow K, Maffulli N, Page G. The suspected scaphoid fracture. How useful is a unit policy? *Bull Hosp Jt Dis* 1998;57:93-5.
4. Breitenseher MJ, Metz VM, Gilula LA, Gaebler C, Kukla C, Fleischmann D, *et al.* Radiographically occult scaphoid fractures: Value of MR imaging in detection. *Radiology* 1997;203:245-50.
5. Hunter JC, Escobedo EM, Wilson AJ, Hanel DP, Zink-Brody GC, Mann FA. MR imaging of clinically suspected scaphoid fractures. *AJR Am J Roentgenol* 1997;168:1287-93.
6. Brydie A, Raby N. Early MRI in the management of clinical scaphoid fracture. *Br J Radiol* 2003;76:296-300.
7. Brooks S, Cicuttini FM, Lim S, Taylor D, Stuckey SL, Wluka AE. Cost effectiveness of adding magnetic resonance imaging to the usual management of suspected scaphoid fractures. *Br J Sports Med* 2005;39:75-9.
8. Gaebler C, Kukla C, Breitenseher M, Trattinig S, Mittlboeck M, Vécsei V. Magnetic resonance imaging of occult scaphoid fractures. *J Trauma* 1996;41:73-6.
9. Bretlau T, Christensen OM, Edström P, Thomsen HS, Lausten GS. Diagnosis of scaphoid fracture and dedicated extremity MRI. *Acta Orthop Scand* 1999;70:504-8.
10. Freeland P. Scaphoid tubercle tenderness: A better indicator of scaphoid fractures? *Arch Emerg Med* 1989;6:46-50.
11. Parvizi J, Wayman J, Kelly P, Moran CG. Combining the clinical signs improves diagnosis of scaphoid fractures. A prospective study with follow-up. *J Hand Surg Br* 1998;23:324-7.
12. Nishirara R. The dilemmas of a scaphoid fracture: A difficult diagnosis for primary care physicians. *Hosp Physician* 2003;36:24-40.
13. Chen SC. The scaphoid compression test. *J Hand Surg Br* 1989;14:323-5.
14. Esberger DA. What value the scaphoid compression test? *J Hand Surg Br* 1994;19:748-9.
15. Powell JM, Lloyd GJ, Rintoul RF. New clinical test for fracture of the scaphoid. *Can J Surg* 1988;31:237-8.
16. Barton NJ. Twenty questions about scaphoid fractures. *J Hand Surg Br* 1992;17:289-310.
17. Soto Hall R. The conservative and operative treatment of fractures of carpal scaphoid. *J Bone Joint Surg* 1941;23A: 841-50.
18. Unay K, Gokcen B, Ozkan K, Poyanli O, Eceviz E. Examination tests predictive of bone injury in patients with clinically suspected occult scaphoid fracture. *Injury* 2009;40:1265-8.
19. Waizenegger M, Barton NJ, Davis TR, Wastie ML. Clinical signs in scaphoid fractures. *J Hand Surg Br* 1994;19:743-7.
20. Calderon SL, Ring D. The diagnostic performance characteristics of imaging techniques used in the management of scaphoid fractures. *Curr Opin Orthop* 2007;18:309-14.
21. Karantanas A, Dailiana Z, Malizos K. The role of MR imaging in scaphoid disorders. *Eur Radiol* 2007;17:2860-71.
22. Raby N. Magnetic resonance imaging of suspected scaphoid fractures using a low field dedicated extremity MR system. *Clin Radiol* 2001;56:316-20.
23. Dorsay TA, Major NM, Helms CA. Cost-effectiveness of immediate MR imaging versus traditional follow-up for revealing radiographically occult scaphoid fractures. *AJR Am J Roentgenol* 2001;177:1257-63.
24. Beeres FJ, Hogervorst M, Kingma LM, Le Cessie S, Coerkamp EG, Rhemrev SJ. Observer variation in MRI for suspected scaphoid fractures. *Br J Radiol* 2008;81:950-4.
25. Tiel-van Buul MM, Roolker W, Verbeeten BW,

- Broekhuizen AH. Magnetic resonance imaging versus bone scintigraphy in suspected scaphoid fracture. *Eur J Nucl Med* 1996;23:971-5.
26. Beeres FJ, Hogervorst M, Rhemrev SJ, Le Cessie S, Arndt JW, Stokkel MP, *et al.* Reliability of bone scintigraphy for suspected scaphoid fractures. *Clin Nucl Med* 2007;32:835-8.
27. Jørgensen TM, Andresen JH, Thommesen P, Hansen HH. Scanning and radiology of the carpal scaphoid bone. *Acta Orthop Scand* 1979;50(6 Pt 1):663-5.
28. Fusetti C, Poletti PA, Pradel PH, Garavaglia G, Platon A, Della Santa DR, *et al.* Diagnosis of occult scaphoid fracture with high-spatial-resolution sonography: A prospective blind study. *J Trauma* 2005;59:677-81.
29. Ilica AT, Ozyurek S, Kose O, Durusu M. Diagnostic accuracy of multidetector computed tomography for patients with suspected scaphoid fractures and negative radiographic examinations. *Jpn J Radiol* 2011;29:98-103.
30. Pillai A, Jain M. Management of clinical fractures of the scaphoid: Results of an audit and literature review. *Eur J Emerg Med* 2005;12:47-51.