

Single Case

Occurrence of a Duodenal Polypoid Lesion During Long-Term Acid Suppression Therapy and Its Regression After Drug Discontinuation

Masako Shintaku^a Masayuki Shintaku^b Kazunari Tominaga^a
Yasumasa Sumitomo^a Takehiro Sando^a

^aDepartment of Gastroenterology, Japan Community Health care Organization, Hoshigaoka Medical Center, Hirakata, Japan; ^bDepartment of Pathology, Hikone Municipal Hospital, Hikone, Japan

Keywords

Duodenum · Polypoid lesion · Gastric acid suppressant · Regression · Gastrin

Abstract

Formation of multiple fundic gland polyps or hyperplastic polyps in the gastric mucosa is one of the well-known adverse effects of the long-term acid suppression therapy for peptic ulcer disease. However, similar phenomenon has not been reported to occur in the duodenum. We report a case of duodenal polypoid lesion that developed after the long-term use of acid suppressants and disappeared after the cessation of the treatment. The patient was a 76-year-old man with a history of heavy cigarette smoking and excessive alcohol intake who had been treated with medication of gastric acid suppressants, including proton pump inhibitors and potassium-competitive acid blockers, for refractory gastroesophageal reflux disease. After receiving the acid suppression therapy for 3 years, a polypoid lesion of 10 mm in diameter was found at the portion of the duodenal bulb. This polypoid lesion disappeared 1.5 months after the cessation of treatment. We hypothesized that changes in serum gastrin levels caused by acid suppression therapy might have been associated with the development and regression of the duodenal polypoid lesion.

© 2021 The Author(s).
Published by S. Karger AG, Basel

Introduction

Drugs with a marked suppressive effect against gastric acid, such as proton pump inhibitors (PPI) or potassium-competitive acid blockers (P-CAB), have been widely used for the treatment of peptic ulcers and gastroesophageal reflux disease (GERD) in recent years. However, some adverse effects of the long-term use of the above acid suppressants have been reported [1]. One of the most notable adverse effects is the formation of multiple fundic gland polyps or hyperplastic polyps in the stomach [1–5]. These polyps occasionally regress or disappear after discontinuation of acid suppressants, and their pathogenesis is considered to have a close relationship with *Helicobacter pylori* (*H. pylori*)-negative status or hypergastrinemia induced by the use of acid suppressants. On the other hand, the occurrence of similar polyps in the duodenum has not been reported to our knowledge.

We report the case of a polypoid lesion in the duodenum that developed after the long-term use of acid suppressants (PPI and P-CAB) and spontaneously disappeared after discontinuation of the drugs. As a mechanism to explain the development and regression of the duodenal lesion, we hypothesized that changes in the serum gastrin levels might have been associated with its pathogenesis.

Case Report

The patient was a 76-year-old man with a history of heavy cigarette smoking (20 cigarettes per day for 53 years) and excessive alcohol intake (whisky 5 L per week for 25 years). His medical history included paraplegia due to myelitis at the age of 42, Wernicke's encephalopathy at the age of 63, and chronic subdural hematoma at the age of 64. He was admitted to a hospital for a hemorrhagic esophageal ulcer due to GERD 3 years ago. At that time, no atrophic change was observed in the gastric mucosa, and IgG antibody against *H. pylori* was 1.8 U/mL (normal range: <10 U/mL). He was treated with PPI (esomeprazole, 20 mg/day for a month, and lansoprazole, 15 mg/day for the following 1.5 months). However, after 4 months, he was emergently transported to a hospital because of hematemesis due to relapse of the esophageal ulcer and multiple small peptic ulcers in the duodenum. He was then referred to our hospital and treated with P-CAB (vonoprazan, 20 mg/day for 8 months and 10 mg/day for the following 3 months) and thereafter with PPI (rabeprazole, 10 mg/day for the following 22 months). His hemostatic conditions were relatively maintained with strict prohibition of smoking and alcohol intake.

Three years after the start of the administration of acid suppressants, endoscopic examination demonstrated a sessile polypoid lesion, measuring about 10 mm in diameter, at the anterior wall of the duodenal bulb. It showed a coarsely lobulated or multinodular appearance, and its surface exhibited irregular, hypertrophic villi-like or gyrus-like features and was slightly pale in color in comparison with the surrounding duodenal mucosa (Fig. 1). Irregular patterns of the stromal microvessels were not observed. The appearance of this lesion resembled adenoma of the gastric type as a whole. This lesion had not been detected by the endoscopy performed 20 months previously. A few small foci of gastric metaplasia were also observed in the vicinity of the polypoid lesion. Biopsy of the polypoid lesion was not performed because endoscopic mucosal resection may become difficult due to scar formation caused by the biopsy procedure. The gastric mucosa did not show atrophy associated with *H. pylori* infection, and a few, small fundic gland polyps were found in the upper corpus. Since esophageal ulcers associated with GERD had already healed, the treatment was changed from the administration of rabeprazole to a histamine H₂ receptor antagonist (famotidine, 40 mg/day).

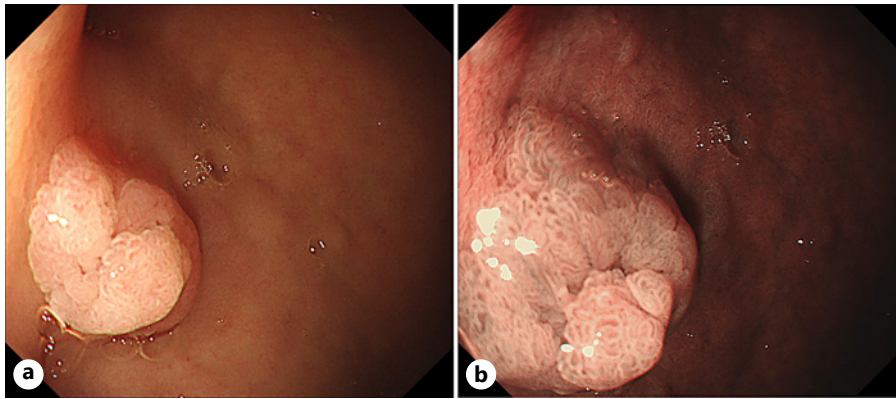


Fig. 1. Endoscopic images of the duodenum. A polypoid lesion of about 10 mm in diameter was found on the anterior wall of the duodenal bulb (**a**: white light, **b**: close-up image using narrow-band imaging).

On endoscopy performed 1.5 months later, the polypoid lesion of the duodenum had regressed and almost completely disappeared (Fig. 2). The serum levels of gastrin after fasting at that time were 150 and 95 pg/mL after 3 months (normal range: <200 pg/mL), although they had not been measured during PPI and P-CAB treatments.

Discussion

Acid suppressants such as histamine H₂ receptor antagonists and PPI have been widely used for various acid-related diseases: gastro-duodenal peptic ulcers and GERD [6]. Additionally, P-CAB provides a more powerful means of suppressing gastric acid secretion. Meanwhile, some adverse effects of long-term acid suppression therapy have become apparent [1]. They include the relatively common appearance of both fundic gland polyps and hyperplastic polyps in the stomach [1–5, 7, 8] and also a peculiar change of the gastric fundic mucosa called “parietal cell protrusion” [9]. Hongo et al. [4] demonstrated an increased incidence of these gastric polyps in patients with the long-term use of acid suppressants in a prospective multi-institutional study. In that study, the development of fundic gland polyps was associated with an *H. pylori*-negative status but not hypergastrinemia, while the development of hyperplastic polyps was related to both an *H. pylori*-positive status and hypergastrinemia [4]. The presence of fundic gland polyps is closely associated with the absence of *H. pylori* infection [5]. At least some of these acid suppressant-induced gastric polyps are reversible, and the regression or disappearance of these polyps (including both hyperplastic and fundic gland polyps) may depend on the discontinuation of acid suppressant use [2, 7, 8].

In the duodenal mucosa, various lesions showing the gastric phenotype, such as heterotopic gastric mucosa, gastric foveolar metaplasia, and a hyperplastic polyp, arise, especially in patients with an increased secretion of gastric acid [10]. These lesions are considered to represent a protective reaction against the excessive influx of gastric acid into the duodenum, and they originate from stem cells in the proliferative zone of the mucosal crypts [10] or from a newly formed proliferative zone within Brunner glands [11]. Some investigators proposed another possibility that goblet cells in the duodenal mucosa are directly transformed to gastric foveolar cells under the influence of local inflammatory mediators [12]. Inflammatory injuries to the duodenal mucosa by *H. pylori* may further stimulate the development of gastric metaplasia [13].

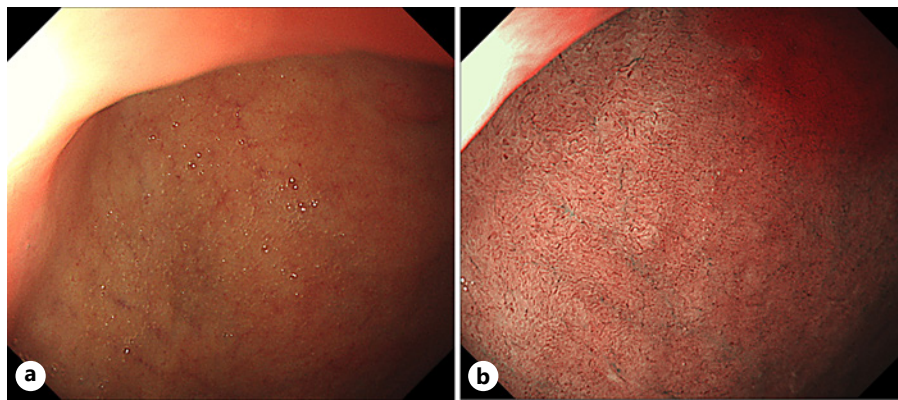


Fig. 2. Endoscopic images of the same region taken (a) 1.5 months and (b) 3 months after the discontinuation of PPI therapy. The polypoid lesion had almost disappeared (a: white light, b: narrow-band imaging). PPI, proton pump inhibitor.

Here, we reported an exceptional case in which a polypoid lesion developed at the portion of the duodenal bulb following long-term acid suppression therapy and thereafter regressed by the cessation of drug administration. This polypoid lesion showed a coarsely lobulated or multinodular appearance with a hypertrophic villi-like or gyriform surface and resembled adenoma of the gastric type. This lesion most likely represented a hyperplastic polyp on the basis of the endoscopic features and rapid regression after the cessation of drugs, although its histology was not confirmed. However, the possibility of a fundic gland polyp or fundic gland polyp-like lesion also cannot be ruled out because there was neither evidence of *H. pylori*-associated gastritis nor features of a hyperplastic polyp, especially the characteristic appearance of microvessels in endoscopic findings.

Reports of duodenal lesions induced by long-term acid suppression therapy are few, and the regression or disappearance of a duodenal polypoid lesion after the discontinuation of acid suppressants has not been reported to our knowledge. It is of interest that the present case showed no evidence of *H. pylori* infection. Watanabe et al. [14] reported that 2 cases of multiple gastric fundic gland polyps regressed following the acquisition of *H. pylori* and stated that *H. pylori* infection exerted an inhibitory effect on the development of fundic gland polyps.

Changes in gastric polyp formation in patients taking acid suppressants are closely related to changes in the serum gastrin level associated with the status of *H. pylori* infection [4, 8]. It is well recognized that the administration of an acid suppressant induces hypergastrinemia [4]. As the influence of the long-term use of acid suppressants to the duodenum, there are 2 possibilities: a direct pharmacological action on the duodenal mucosa and an indirect effect through an increase of serum gastrin. Gastrin has a direct trophic action to promote cell proliferation of the gastrointestinal mucosa as well as enhancement of gastric acid secretion [15]. Miyamoto et al. [7] reported a case of PPI-induced, multiple gastric hyperplastic polyps that markedly decreased in size after the discontinuation of PPI. The decrease was associated with normalization of the serum gastrin level from high levels during the administration of PPI [7]. Since gastrin receptors were expressed on the foveolar epithelium of the polyps, the development and regression of hyperplastic polyps may be regulated by changes of serum gastrin levels through a gastrin-gastrin receptor signal pathway [7].

In conclusion, we hypothesized that long-term acid suppression therapy might have caused hypergastrinemia, gastric metaplasia, and the formation of a polypoid lesion at the portion of the duodenal bulb. By the discontinuation of drugs, the serum gastrin probably decreased, and thereby the duodenal polypoid lesion might have regressed and disappeared.

Statement of Ethics

This study protocol was reviewed, and the need for approval was waived by the Ethical Review Board of Japan Community Health care Organization Hoshigaoka Medical Center. Written informed consent was obtained from the patient for publication of this case report and any accompanying images.

Conflict of Interest Statement

The authors have no conflicts of interest to declare.

Funding Sources

The authors declare that there were no funding sources for this manuscript.

Author Contributions

Masako Shintaku performed the endoscopic examinations and drafted the manuscript and figures. Masayuki Shintaku, Kazunari Tominaga, Yasumasa Sumitomo, and Takehiro Sando discussed with Masako Shintaku on the contents of the articles and gave many critical advices.

Data Availability Statement

All data generated or analyzed during this study are included in this article. Further enquiries can be directed to the corresponding author.

References

- 1 Thomson AB, Sauve MD, Kassam N, Kamitakahara H. Safety of the long-term use of proton pump inhibitors. *World J Gastroenterol*. 2010 May;16(19):2323–30.
- 2 Choudhry U, Boyce HW Jr, Coppola D. Proton pump inhibitor-associated gastric polyps. A retrospective analysis of their frequency, and endoscopic, histologic, and ultrastructural characteristics. *Am J Clin Pathol*. 1998 Nov;110(5):615–21.
- 3 Jalving M, Koornstra JJ, Wesseling J, Boezen HM, De Jong S, Kleibeuker JH. Increased risk of fundic gland polyps during long-term proton pump inhibitor therapy. *Aliment Pharmacol Ther*. 2006 Nov;24(9):1341–8.
- 4 Hongo M, Fujimoto K; Gastric Polyps Study Group. Incidence and risk factor of fundic gland polyp and hyperplastic polyp in long-term proton pump inhibitor therapy. A prospective study in Japan. *J Gastroenterol*. 2010 Jun;45(6):618–24.
- 5 Zelter A, Fernández JL, Bilder C, Rodríguez P, Wonaga A, Dorado F, et al. Fundic gland polyps and association with proton pump inhibitor intake. A prospective study in 1,780 endoscopies. *Dig Dis Sci*. 2011 Jun;56(6):1743–8.
- 6 Klinkenberg-Knol EC, Nelis F, Dent J, Snel P, Mitchell B, Prichard P, et al. Long-term omeprazole treatment in resistant gastroesophageal reflux disease. Efficacy, safety, and influence on gastric mucosa. *Gastroenterology*. 2000 Apr;118(4):661–9.
- 7 Miyamoto S, Kato M, Matsuda K, Abiko S, Tsuda M, Mizushima T, et al. Gastric hyperplastic polyps associated with proton pump inhibitor use in a case without a history of *Helicobacter pylori* infection. *Intern Med*. 2017 Jul;56(14):1825–9.
- 8 Yasugi K, Haruma K, Kawanaka M, Suehiro M, Nakamura J, Urata N, et al. Disappearance of gastric hyperplastic polyps after the discontinuation of proton pump inhibitor in a patient with liver cirrhosis. *Case Rep Gastroenterol*. 2021 Feb;15(1):202–9.

- 9 Krishnamurthy S, Dayal Y. Parietal cell protrusions in gastric ulcer disease. *Hum Pathol*. 1997 Oct;28(10):1126–30.
- 10 James AH. Gastric epithelium in the duodenum. *Gut*. 1964 Aug;5(4):285–94.
- 11 Kushima R, Manabe R, Hattori T, Borchard F. Histogenesis of gastric foveolar metaplasia following duodenal ulcer. A definite reparative lineage of Brunner's gland. *Histopathology*. 1999 Jul;35(1):38–43.
- 12 Shaoul R, Marcon P, Okada Y, Cutz E, Forstner G. The pathogenesis of duodenal gastric metaplasia. The role of local goblet cell transformation. *Gut*. 2000 May;46(5):632–8.
- 13 Wyatt JI, Rathbone BJ, Sobala GM, Shallcross T, Heatley RV, Axon AT, et al. Gastric epithelium in the duodenum. Its association with *Helicobacter pylori* and inflammation. *J Clin Pathol*. 1990 Dec;43(12):981–6.
- 14 Watanabe N, Seno H, Nakajima T, Yazumi S, Miyamoto S, Matsumoto S, et al. Regression of fundic gland polyps following acquisition of *Helicobacter pylori*. *Gut*. 2002 Nov;51(5):742–5.
- 15 Ekundayo AA, Lee CY, Goodlad RA. Gastrin and the growth of the gastrointestinal tract. *Gut*. 1995 Feb;36(2):203–8.