

## CASE REPORT

## Catheter Directed Thrombectomy Under Temporary Catheter Based Filter Protection in Renal Vein Thrombosis and Contraindication to Anticoagulation

Axel Haine <sup>a,\*</sup>, Alexander Rosenov <sup>a</sup>, Nando Mertineit <sup>b</sup>, Iris Baumgartner <sup>a</sup>, Marc Schindewolf <sup>a</sup>

<sup>a</sup> Division of Angiology, Swiss Cardiovascular Centre, Inselspital, Bern University Hospital, University of Bern, Bern, Switzerland

<sup>b</sup> Department of Diagnostic, Interventional and Pediatric Radiology, Inselspital, Bern University Hospital, University of Bern, Bern, Switzerland

**Introduction:** A 55 year old man who suffered from recurrent traumatic multi-organ bleeding presented with deterioration in kidney function and pulmonary embolism caused by a newly diagnosed renal vein thrombosis during hospitalisation.

**Report:** Complete clot removal was performed successfully by catheter directed aspiration. Thrombotic emboli were captured in a temporary filter device. A post-interventional computed tomography scan showed full restoration of the occluded renal vein.

**Discussion:** Use of a temporary catheter based vena cava filter (Capturex) during catheter directed thrombectomy is safe and should be considered to prevent thrombo-embolism in selected cases when any rheolytic therapy is contraindicated.

© 2020 The Author(s). Published by Elsevier Ltd on behalf of European Society for Vascular Surgery. This is an open access article under the CC BY-NC-ND license (<http://creativecommons.org/licenses/by-nc-nd/4.0/>).

Article history: Received 19 February 2020, Revised 11 August 2020, Accepted 11 September 2020,

**Keywords:** Mechanical thrombectomy, Pulmonary embolism, Thrombosis, Vena cava filter

### INTRODUCTION

Renal vein thrombosis (RVT) is a pathology often diagnosed in patients with nephrotic syndrome caused by anti-thrombin deficiency.<sup>1</sup> Other causes include blunt trauma, tumour, venous outflow obstruction, and post kidney transplantation. Early anticoagulation is the standard approach to prevent thrombosis progression and pulmonary embolism (PE), and may be sufficient in asymptomatic patients with preserved normal kidney function. However, for patients with deterioration of kidney function, treatment of the RVT should be considered.<sup>1</sup> Local thrombolysis with or without catheter directed mechanical thrombectomy (CDT) has been proposed for selected cases with RVT.<sup>1,2</sup> Additional temporary catheter based filter placement in the vena cava inferior (IVC), such as the Capturex, offers potential for protection from possible thrombo-embolism during CDT. This is the report of successful unilateral RVT treatment by CDT and thrombus capture using a catheter based temporary filter in a patient with contraindication for rheolytic therapy.

### CASE REPORT

A 55 year old sportsman presented with a traumatic grade IV lesion of both his spleen and left kidney as a result of a fall when mountain biking. Endovascular treatment was performed with selective coil embolisation. On day 7 after this intervention the patient presented with haemodynamic instability, and a second computed tomography (CT) scan showed recurrent splenic bleeding. The CT was discussed between surgeons and interventional angiologists, with agreement for urgent coil embolisation. At that time, CT scan newly demonstrated an obstructive left RVT and unilateral distal PE (Fig. 1). Lower extremity deep vein thrombosis (DVT) was ruled out by compression ultrasound. Kidney function had deteriorated and showed a 40% increase of serum creatinine level (130 µmol/L, estimated glomerular filtration rate [eGFR] 57 mL/min) while respiratory function was preserved. Initial transient hypotensive renal perfusion pressure, partial ischaemic renal damage as a result of coil embolisation, and contrast media exposure were discussed as possible causes of the acute kidney injury. Multidisciplinary discussion on treatment options concluded that renal vein CDT should be performed (AngioJet, Solent Omni, Boston Scientific, Marlborough, MA, USA), in combination with a catheter based filter in the suprarenal segment of the IVC.

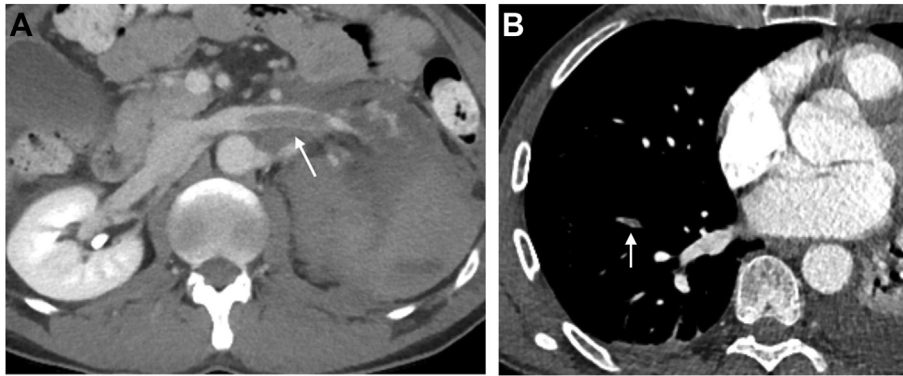
First, the right common femoral vein was punctured under ultrasound guidance and a 6F 10 cm sheath (Glide-sheath Slender, Terumo, Tokyo, Japan) was inserted. The left

\* Corresponding author. Division of Angiology, Swiss Cardiovascular Centre, University Hospital Bern, 3010, Bern, Switzerland.

E-mail address: [axel.haine@gefaesszentrum-bern.ch](mailto:axel.haine@gefaesszentrum-bern.ch) (Axel Haine).

2666-688X/© 2020 The Author(s). Published by Elsevier Ltd on behalf of European Society for Vascular Surgery. This is an open access article under the CC BY-NC-ND license (<http://creativecommons.org/licenses/by-nc-nd/4.0/>).

<https://doi.org/10.1016/j.ejvsf.2020.09.001>



**Figure 1.** Computed tomography scan on day 7 showing (A) left renal vein thrombus (arrow) and (B) right lobe peripheral pulmonary embolism (arrow).

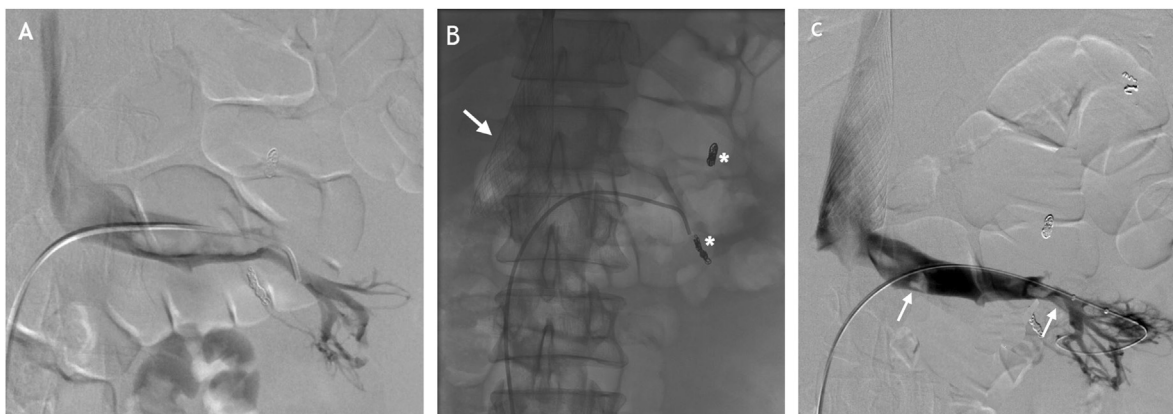
renal vein was selectively catheterised with a 5F shepherd hook shaped catheter (Beacon, Cook, Bloomington, IN, USA) and a venogram was performed (Fig. 2A). Second, the jugular vein was punctured and a 10F 10 cm sheath (Avanti, Cordis, Miami, FL, USA) was inserted. The catheter based filter (Capturex, Straub Medical, Wangs, Switzerland) was placed in the IVC and the filter's distal end opened at the level of the renal vein ostium shaped like a funnel (Figs. 2B and 3). Third, repeated 100 second runs of mechanically assisted CDT (AngioJet, Solent Omni 6F, Boston Scientific) in the left renal vein without rheolytic medication were performed. The final venogram showed subtotal thrombus elimination (Fig. 2C). Lastly, the filter basket containing the thrombotic material was retrieved (Fig. 3). Ultrasound imaging on the following day demonstrated preserved flow in the renal vein without detection of obstructive clots. Anticoagulation with unfractionated heparin in a prophylactic dose of 10 000 units per 24 hours was started one day after thrombus removal and absent signs of organ bleeding. This regimen was changed on day 9 after thrombus removal to subcutaneously administered Clexane (enoxaparin, Sanofi, Paris, France) for treatment of the underlying PE. Serum

creatinine level dropped to 95  $\mu\text{mol/L}$  within 48 hours post CDT and renal function was restored completely based on laboratory assessment one month later (eGFR >90 mL/min). A contemporaneous final CT scan showed both absence of residual thrombosis in the left renal vein and preserved arterial perfusion of the renal parenchyma (Fig. 4A and B).

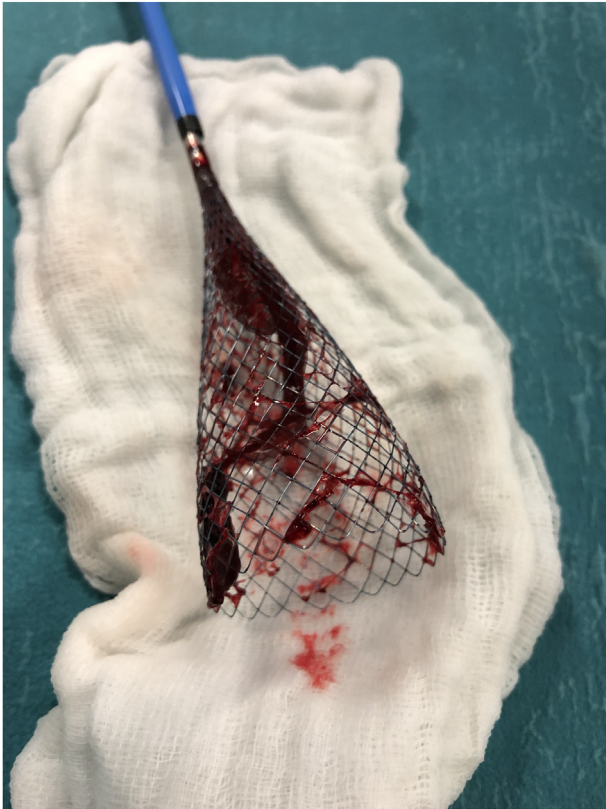This report was prepared following the principles of the Declaration of Helsinki and approved for publishing by the study institution. Ethical approval was obtained as well as written informed consent and consent to publish.

## DISCUSSION

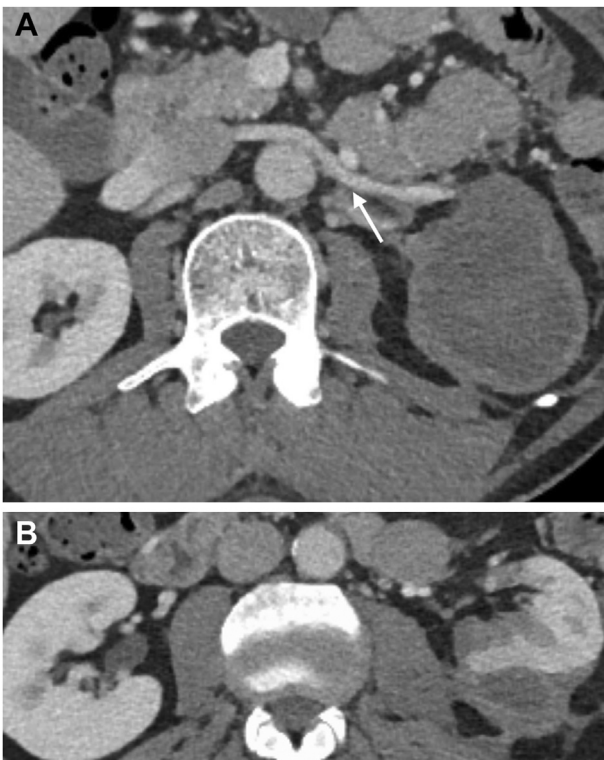
Therapeutic anticoagulation is the standard approach for RVT.<sup>1</sup> CDT with or without thrombolysis is suggested to be a safe and efficient minimally invasive procedure in various settings.<sup>2–4</sup> The choice of manual thrombus aspiration or any specific device for CDT should be guided by local expertise because of missing high level evidence from randomised trials. This technique has been suggested as a first line treatment approach, especially in patients with deteriorating kidney function, and to prevent thrombus



**Figure 2.** (A) Venogram of the selectively catheterised left renal vein prior to thrombus removal (B) Fluoroscopy after deployment of the filter catheter in the inferior vena cava (arrow) with the need to retract the filter 1 cm prior to treatment, and coils placed for initial arterial embolisation (stars) (C) Venogram after catheter directed thrombus removal with minor residual thrombus and restored venous outflow (arrow).



**Figure 3.** Photograph of the catheter based vena cava filter (Capturex), with an elongated thrombus and smaller emboli captured inside.



**Figure 4.** Computed tomography scan six weeks after left renal vein thrombus removal showing (A) no residual thrombus in the vein (arrow) and (B) residual arterial parenchymal perfusion.

progression and consecutive PE.<sup>4</sup> When considering PE during catheter assisted DVT treatment, this treatment option appears to be safe for the overall population that has been studied; however, available data differ significantly between studies as a result of the methods used for the diagnosis of PE. A contemporary meta-analysis by Wang et al. found a pooled PE rate of 3.8% (95% CI 2.5–6.7), limited to cases with known non-use of an IVC filter.<sup>5</sup> The PEARL registry prospectively studied the efficacy of CDT with the AngioJet catheter, in which only one symptomatic PE was detected by CT scan.<sup>6</sup> In contrast, a rate of 15.6% for symptomatic PE was reported from a recent retrospective analysis.<sup>7</sup> There was no difference observed for either CDT or local catheter lysis. As the majority of these analyses focused on symptomatic PE, the overall thrombo-embolic burden including asymptomatic PE may be underestimated. Use of IVC filters to prevent PE is mostly performed by leaving the filters in the IVC, likely to be responsible for the majority of device associated complications as well as requiring potentially complicated retrieval. However, registry data on efficacy and safety of a catheter based filter in patients with DVT are promising in terms of increasing patient safety with regard to PE protection and minor complications.<sup>8</sup>

In the present case, an attempt was made to prevent thrombosis progression, to lower risk of PE, and to restore renal venous outflow to preserve kidney function. An additional risk of a secondary PE was considered associated with CDT manoeuvre. As rheolytic medication was withheld because of recurrent life threatening organ bleeding the same day, the decision was taken for safe thrombus extraction.

Surgical splenectomy with or without placement of a temporary suprarenal vena cava filter with subsequent initiation of anticoagulation may serve as an alternative treatment approach, which could be considered on an individual basis.<sup>9</sup>

In selective clinical situations, that is where rheolytic therapy is withheld despite a need for thrombus removal, or in the presence of a persistent patent foramen ovale with known risk of arterial thrombo-embolism,<sup>10</sup> the combined use of IVC during CDT is strongly recommended. A catheter based cava filter, for example Capturex, seems to have advantages over a standard retrievable IVC filter in terms of its narrow meshed design and complications associated with the device and its easy retrieval.

#### CONFLICT OF INTEREST

None.

#### FUNDING

None.

#### REFERENCES

- 1 Asghar M, Ahmed K, Shah SS, Siddique MK, Dasgupta P, Khan MS. Renal vein thrombosis. *Eur J Vasc Endovasc Surg* 2007;**34**:217–23.

- 2 Srinivas BC, Singh B, Srinivasa S, Reddy SS, Mahadevappa NC, Reddy B. Transcatheter pharmacomechanical approach for acute renal vein thrombosis: a rational technique. *Cardiovasc Interv Ther* 2014;**29**:275–8.
- 3 Lee Carlsson T, Lewis K. Acute Renal Vein Thrombosis: a case report of successful treatment with mechanical thromboaspiration. *Ann Vasc Surg* 2018;**51**:329. e5–.e8.
- 4 Kim HS, Fine DM, Atta MG. Catheter-directed thrombectomy and thrombolysis for acute renal vein thrombosis. *J Vasc Interv Radiol* 2006;**17**:815–22.
- 5 Wang W, Sun R, Chen Y, Liu C. Meta-analysis and systematic review of percutaneous mechanical thrombectomy for lower extremity deep vein thrombosis. *J Vasc Surg Venous Lymphat Disord* 2018;**6**:788–800.
- 6 Garcia MJ, Lookstein R, Malhotra R, Amin A, Blitz LR, Leung DA, et al. Endovascular management of deep vein thrombosis with rheolytic thrombectomy: final report of the prospective multicenter PEARL (peripheral use of AngioJet rheolytic thrombectomy with a variety of catheter lengths) registry. *J Vasc Interv Radiol* 2015;**26**:777–85. quiz 86.
- 7 Loss L, Stefanopoulos S, Siddiq A, Markowiak S, Qu W, Osman M, et al. Catheter directed lysis and thrombectomy are equally effective for extensive deep vein thrombosis. *J Surg Res* 2019;**244**:540–6.
- 8 Taccone FS, Bunker N, Waldmann C, De Backer D, Brohi K, Jones RG, et al. A new device for the prevention of pulmonary embolism in critically ill patients: results of the European Angel Catheter Registry. *J Trauma Acute Care Surg* 2015;**79**:456–62.
- 9 Huang Q, Zhang Q, Xu H, Zu M, Gu Y, Wei N, et al. Application of suprarenal inferior vena cava filter placement in patients with venous thromboembolism. *Zhonghua Yi Xue Za Zhi* 2015;**95**:1997–9.
- 10 Konstantinides S, Geibel A, Kasper W, Olschewski M, Blumel L, Just H. Patent foramen ovale is an important predictor of adverse outcome in patients with major pulmonary embolism. *Circulation* 1998;**97**:1946–51.