

Case Report

Delayed Diagnosis of Psoriatic Arthritis Mutilans due to Arthritis Prior to Skin Lesion

Takeshi Mochizuki ¹, Katsunori Ikari,² and Ken Okazaki²

¹Department of Orthopedic Surgery, Kamagaya General Hospital, Chiba, Japan

²Department of Orthopedic Surgery, Tokyo Women's Medical University, Tokyo, Japan

Correspondence should be addressed to Takeshi Mochizuki; twmutamo@gmail.com

Received 27 August 2018; Revised 17 October 2018; Accepted 21 October 2018; Published 4 November 2018

Academic Editor: Tsai-Ching Hsu

Copyright © 2018 Takeshi Mochizuki et al. This is an open access article distributed under the Creative Commons Attribution License, which permits unrestricted use, distribution, and reproduction in any medium, provided the original work is properly cited.

Psoriatic arthritis (PsA) is a type of inflammatory arthritis characterized by cutaneous psoriasis, peripheral joint damage, axial joint damage, and enthesitis and is usually diagnosed after the appearance of psoriatic skin disease. PsA mutilans is relatively rare in Japan. In the present case, the patient was diagnosed with PsA with foot mutilans deformity only. Hand and spinal radiograph findings were unremarkable. As in the present case arthritis is occurred prior to the onset of skin lesion, we should make early diagnosis to prevent mutilans deformity.

1. Introduction

Psoriatic arthritis (PsA) is a type of inflammatory arthritis characterized by cutaneous psoriasis, peripheral joint damage, axial joint damage, and enthesitis and is usually diagnosed after the appearance of psoriatic skin disease. The prevalence of psoriasis in adults ranges from 0.91% (United States) to 8.5% (Norway) [1]. At 0.34%, the prevalence of psoriasis is lower in Japan than in Europe and the United States [2]. The prevalence of PsA in Japan is 0.001–0.03% in the general population [3]. In contrast, the prevalence of PsA was reported to be 14.3% (range, 8.8–20.4%) among 3,021 Japanese patients with psoriasis between March 2003 and February 2014 in three major Japanese areas; this includes the following types of PsA: distal interphalangeal (DIP) type (8.9%), oligoarthritis type (28.6%), polyarthritis type (60.4%), mutilans type (0.5%), and no peripheral arthritis (0.7%) [4]. In a multicenter study conducted by the Japanese Society for Psoriasis Research, types of PsA among 1,282 newly diagnosed patients were as follows: polyarthritis type (36%), DIP type (26%), oligoarthritis type (22%), spondylitis type (8.1%), mutilans type (1.8%), and unknown (6.1%) according to the Moll and Wright criteria [5].

As mentioned above, PsA mutilans is relatively rare in Japan. In the present case, the patient was diagnosed with PsA with foot mutilans deformity only. We report this case for the purpose of education.

2. Case Report

A 39-year-old female presented to our orthopaedic clinic with plantar pain and a gait disturbance and deformities involving the toes on both feet (Figure 1). One decade ago, she was examined and suspected of rheumatoid arthritis by several orthopaedic surgeons, but she has not been diagnosed a definitive diagnosis and prescribed nonsteroidal anti-inflammatory drugs. Plain radiographs of the feet showed severe joint destruction in the proximal interphalangeal (PIP) joints of the lesser toes, with joint space widening and digit shortening consistent with arthritis mutilans (Figure 2). Hand and spinal radiograph findings were unremarkable. Rheumatoid factor and anticyclic citrullinated peptides antibody were negative, and the C-reactive protein level was normal (0.10 mg/dL). She has no family history of psoriasis, PsA, and rheumatic diseases. Although no skin irregularities were observed on the feet, a rash was noted on the chest (Figure 3). Because PsA was

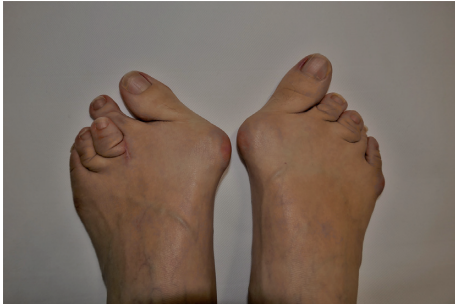

FIGURE 1: Deformities involving the toes on both feet.

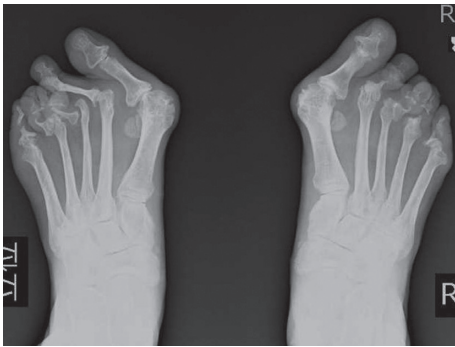

FIGURE 2: Plain radiographs of the feet.

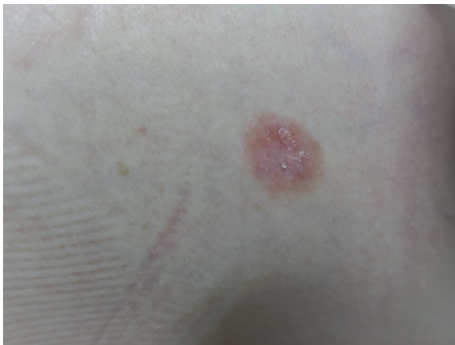

FIGURE 3: The rash on the chest.

suspected, a skin biopsy of the chest was obtained that showed parakeratosis, hyperkeratosis, and regular acanthosis. Histologic findings were consistent with psoriasis (Figure 4). From the results, she diagnosed PsA with mutilans deformity. After treatment with adalimumab, the skin rash resolved and the pain was relieved.

Written informed consent was obtained from the patient.

3. Discussion and Conclusions

The present case was diagnosed as PsA mutilans with feet deformities only and was diagnosed late. PsA mutilans is relatively rare in Japan. The Classification criteria for psoriatic arthritis (CASPAR) are widely used for diagnosis of PsA (sensitivity, 91.4%; specificity, 98.7%) [6]. In short, this system identifies PsA based on the presence of ≥ 3 points by scoring for current evidence of psoriasis, 2 points; and

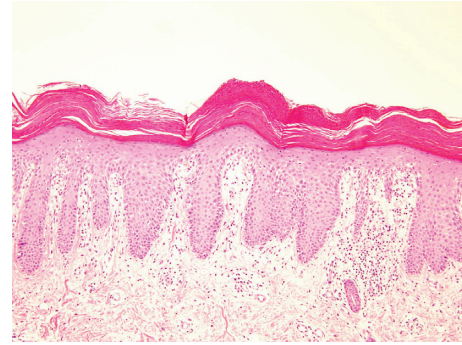


FIGURE 4: Histologic findings (hematoxylin-eosin (HE), $\times 100$).

a personal history or a family history of psoriasis, typical psoriatic nail, a negative test result for the presence of rheumatoid factor, current dactylitis, or radiographic evidence of juxta-articular new bone formation, 1 point each. The present case was assigned a score of 4 by CASPAR criteria.

A case of PsA mutilans type with arthritis has been previously reported in a patient with rheumatoid arthritis [7]. One of the clinical manifestations of this condition is shortening of one or more digits due to severe osteolysis, a deformity called “opera glass finger” or “telescoping finger.” The radiographic findings of PsA mutilans suggest gross osteolysis and pencil-in-cup deformities in joints, as well as rapid progress. Radiographic features in PsA mutilans include bone resorption (41%), joint ankylosis (21%), pencil-in-cup changes (16%), total joint erosion (14%), and joint subluxation (7%) [8]. In the present case, severe progression of bone resorption, joint erosion, and joint subluxation were observed in the feet, particularly in the PIP joints. As a result, the present patient experienced a gait disturbance due to joint destruction of the feet.

Early diagnosis and treatment is important to prevent progression of joint destruction. A delay of ≥ 6 months from symptom onset to the first visit with a rheumatologist contributes to the development of peripheral joint erosions and worse long-term physical function [9]. Psoriasis has been reported to occur prior to the onset of arthritis in 76.2% of patients, with arthritis occurring 11.2 years after psoriasis [5]. Therefore, it is necessary to investigate skin lesions for early diagnosis of psoriasis. Psoriasis typically occurs on the skin of the scalp, knees, elbows, and lower back. In a Japanese survey, the most common skin lesions among patients < 65 years old were the knees (10.8%), elbows (10.6%), back (9.1%), scalp (8.1%), and chest (7.1%) [10]. In the present case, we suspect that the primary skin lesion was on the chest, therefore leading to a delay in the diagnosis of PsA.

In conclusion, PsA mutilans is relatively rare. We have presented a case in which diagnosis of PsA mutilans was delayed and led to dysfunction in daily life. As in the present case arthritis is occurred prior to the onset of skin lesion, we should make early diagnosis to prevent mutilans deformity.

Conflicts of Interest

The authors have no conflicts of interest to disclose.

Authors' Contributions

TM interpreted the patient data and drafted the manuscript. KI revised the manuscript. All authors read and approved the final manuscript.

References

- [1] R. Parisi, D. P. Symmons, C. E. Griffiths, and D. M. Ashcroft, "Identification and management of psoriasis and associated Comorbidity (IMPACT) project team," *Journal of Investigative Dermatology*, vol. 133, no. 2, pp. 377–385, 2013.
- [2] K. Kubota, Y. Kamijima, T. Sato et al., "Epidemiology of psoriasis and palmoplantar pustulosis: a nationwide study using the Japanese national claims database," *BMJ Open*, vol. 14, no. 1, article e006450, 2015.
- [3] T. Yamamoto and A. Kawada, "Clinical characteristics of Japanese patients with psoriatic arthritis: comparison with East Asian countries," *Journal of Dermatology*, vol. 45, no. 3, pp. 273–278, 2018.
- [4] Y. Ohara, M. Kishimoto, N. Takizawa et al., "Prevalence and clinical characteristics of psoriatic arthritis in Japan," *Journal of Rheumatology*, vol. 42, no. 8, pp. 1439–1442, 2015.
- [5] T. Yamamoto, M. Ohtsuki, S. Sano et al., "Epidemiological analysis of psoriatic arthritis patients in Japan," *Journal of Dermatology*, vol. 43, no. 10, pp. 1193–1196, 2016.
- [6] W. Taylor, D. Gladman, P. Helliwell et al., "Classification criteria for psoriatic arthritis: development of new criteria from a large international study," *Arthritis & Rheumatology*, vol. 54, no. 8, pp. 2665–2673, 2006.
- [7] H. G. Mather, "Unusual rheumatoid arthritis (arthritis mutilans)," *Journal of the Royal Society of Medicine*, vol. 47, no. 6, pp. 457–459, 1954.
- [8] A. Haddad, S. R. Johnson, M. Smaily et al., "Psoriatic arthritis mutilans: clinical and radiographic criteria. A systematic review," *Journal of Rheumatology*, vol. 42, no. 8, pp. 1432–1438, 2015.
- [9] M. Haroon, P. Gallagher, and O. FitzGerald, "Diagnostic delay of more than 6 months contributes to poor radiographic and functional outcome in psoriatic arthritis," *Annals of the Rheumatic Diseases*, vol. 74, no. 6, pp. 1045–1050, 2015.
- [10] T. Ito, H. Takahashi, A. Kawada, H. Iizuka, H. Nakagawa, and Japanese Society for Psoriasis Research, "Epidemiological survey from 2009 to 2012 of psoriatic patients in Japanese society for psoriasis Research," *Journal of Dermatology*, vol. 45, no. 3, pp. 293–301, 2018.