

# Reversible cerebral vasoconstriction syndrome at the emergency department

Taerim Kim, Shin Ahn, Chang Hwan Sohn, Dong Woo Seo, Won Young Kim

Department of Emergency Medicine, Asan Medical Center, Ulsan University College of Medicine, Seoul, Korea

**Objective** Reversible cerebral vasoconstriction syndrome (RCVS) is an underestimated cause of thunderclap headache that shares many characteristics with subarachnoid hemorrhage (SAH). This fact makes the two easily confused by emergency physicians. This study evaluated the clinical manifestations, radiological features, and outcomes of patients with RCVS.

**Methods** The electronic medical records of 18 patients meeting the diagnostic criteria of RCVS at our emergency department between January 2013 and December 2014 were retrospectively reviewed.

**Results** The mean patient age was 50.7 years, and 80% were women. Patients with RCVS encountered physicians 4.7 times before receiving an accurate diagnosis. The mean duration of symptoms until diagnosis was 9.3 days. All but one patient experienced severe headache of 8 to 10 on a numerical rating scale. A total of 44% of patients had nausea, and 66% of patients experienced worsening of the headache while gagging, leaning forward, defecating, urinating, or having sexual intercourse. The most frequently affected vessels were the middle cerebral arteries, which demonstrated a characteristic diffuse "string of beads" appearance. Four cases were complicated by SAH.

**Conclusion** Patients with RCVS have a unique set of clinical and imaging features. Emergency physicians should have a high index of suspicion for this clinical entity to improve its rate of detection in patients with thunderclap headache when there is no evidence of aneurysmal SAH.

**Keywords** Headache disorders, primary; Subarachnoid hemorrhage; Emergency service, hospital

eISSN: 2383-4625

Received: 11 August 2015  
Revised: 6 September 2015  
Accepted: 7 September 2015

Correspondence to: Won Young Kim  
Department of Emergency Medicine,  
Asan Medical Center, Ulsan University  
College of Medicine, 88 Olympic-ro  
43-gil, Songpa-gu, Seoul 05505, Korea  
E-mail: wonpia73@naver.com



How to cite this article:

Kim T, Ahn S, Sohn CH, Seo DW, Kim WY.  
Reversible cerebral vasoconstriction  
syndrome at the emergency department.  
Clin Exp Emerg Med 2015;2(4):203-209.

This is an Open Access article distributed under the terms of the Creative Commons Attribution Non-Commercial License (<http://creativecommons.org/licenses/by-nc/3.0/>).

## Capsule Summary

### What is already known

*Reversible cerebral vasoconstriction syndrome remains an under recognized cause of thunderclap headache that shares a similar history with subarachnoid hemorrhage.*

### What is new in the current study

*This study evaluated the clinical manifestations, radiological features, and outcomes of patients with reversible cerebral vasoconstriction syndrome. It also focused on the average number of visits to the physicians before an accurate diagnosis and the mean duration of symptoms until diagnosis revealing a significant under recognition of reversible cerebral vasoconstriction syndrome.*

## INTRODUCTION

Headache is are classified as primary headache syndromes or headaches as a secondary effect.<sup>1-3</sup> Most emergency physicians focus on detecting life threatening conditions in patients with headaches.<sup>2</sup> As stated in the guidelines published by the American College of Emergency Physicians Clinical Policy for Adults with Headache in 2008, the history of the patient plays a major role in evaluation.<sup>4</sup> Thunderclap headache is a sudden-onset, severe headache that reaches maximal intensity within minutes. It can be associated with serious secondary etiologies that have high mortality rates, such as intracranial aneurysm, subarachnoid hemorrhage (SAH), cervical artery dissection, and ischemic stroke.<sup>5,6</sup> However, the recently defined RCVS remains an underestimated cause of thunderclap headache and shares similar characteristics with SAH, particularly in terms of history.<sup>7-14</sup> Although the prognosis of RCVS has been reported to be generally favorable, fatal complications such as seizure, stroke, and SAH can occur a few days after diagnosis, and cerebral vasoconstriction reaches its maximum 2 to 3 weeks after clinical onset.<sup>4,7-11,15-19</sup> Moreover, the result in patients being subjected to unnecessary invasive testing and immunosuppressive therapy.<sup>7,13</sup>

This study evaluated the clinical manifestations, radiological features, and the outcomes of patients with RCVS at an emer-

gency department (ED) with the aim of enabling physicians to maintain a high index of suspicion for RCVS and thereby leading to detection in more patients with thunderclap headache by thorough history taking during initial visits when there is no evidence of aneurysmal SAH.

## METHODS

We retrospectively reviewed the records of ED patients who presented with thunderclap headache and underwent cerebral head angiography at our medical center between January 2013 and December 2014. Before the beginning of this study, the institutional review board approved our review of patient data and waived the requirement for informed consent.

The diagnostic criteria for RCVS used in this study were based on proposed clinical, laboratory, and radiographic findings (Table 1)<sup>8</sup> with some recent modifications. Diagnosis of RCVS was made following the International Classification of Headache Disorders, 3rd edition, 2013, for headaches attributed to RCVS (code 6.7.3) (Table 2).<sup>1</sup> We excluded patients who had experienced cerebral aneurysms, cerebrovascular malformations, brain tumors, strokes, and brain hemorrhage not related to RCVS. We also excluded patients with no evidence of cerebral vasoconstriction detected by cerebral head angiography at the time of their ED visit.

**Table 1.** Diagnostic criteria for reversible cerebral vasoconstriction syndrome

The elements of diagnosis
Acute severe headache (often thunderclap headache) with or without focal deficits or seizures
Uniphase course without new symptoms more than a month after clinical onset
Segmental vasoconstriction of cerebral arteries shown by indirect (e.g., magnetic resonance and computed tomography) or direct catheter angiography
No evidence of aneurysmal subarachnoid hemorrhage
Normal or near-normal cerebrospinal fluid (protein concentration < 100 mg/dL, < 15 white blood cells/ $\mu$ L, normal glucose)
Complete or substantial normalization of arteries shown by follow-up angiography (indirect or direct) within 12 weeks of clinical onset
The criteria proposed in 2007 by Calabrese et al. <sup>8</sup>

**Table 2.** Diagnostic criteria: headache attributed to reversible cerebral vasoconstriction syndrome

The elements of diagnosis
A. Any new headache fulfilling criterion C
B. Reversible cerebral vasoconstriction syndrome has been diagnosed
C. Evidence of causation demonstrated by at least one of the following: <ol style="list-style-type: none"> <li>1. Headache, with or without focal deficits and/or seizures, has led to the performance of angiography (with 'strings and beads' appearance) and a diagnosis of reversible cerebral vasoconstriction syndrome.</li> <li>2. Headache has either or both of the following characteristics:           <ol style="list-style-type: none"> <li>a) Recurrent during 1 month and with thunderclap onset</li> <li>b) Triggered by sexual activity, exertion, Valsalva maneuvers, emotion, bathing, and/or showering</li> </ol> </li> <li>3. No new significant headache occurs &gt; 1 month after onset</li> </ol>
D. Not better accounted for by another International Classification of Headache Disorders, 3rd edition, diagnosis, and aneurysmal subarachnoid hemorrhage has been excluded by appropriate investigations.

The criteria of the International Classification of Headache Disorders, 3rd edition, 2013.<sup>1</sup>

To investigate the clinical manifestations, radiological features, and outcomes of RCVS, we reviewed the baseline data of patients including age, sex, medical history, headache characteristics, duration of symptoms, and relevant laboratory and imaging results. Continuous variables are expressed as means with standard deviations, or as medians and full ranges if the assumption of a normal distribution was violated. Categorical variables are presented as numbers and percentages.

## RESULTS

### Clinical features

After excluding patients according to the exclusion criteria, 18 patients were diagnosed as RCVS on the basis of clinical and radiographic findings. Three patients were men; the average age was 50.7 years at the first ED visit, ranging from 16 to 63 years. Some patients had hyperlipidemia, one had chronic hepatitis B virus infection, one had chronic kidney disease, and one had hypothyroidism. Two patients were taking steroids because of Takayasu's arteritis and rheumatic arthritis. Two patients were taking hormonal agents, but both of them started taking the pills to relieve their pain after their severe headaches began. Before an accurate diagnosis, their headaches were misdiagnosed as postmenopausal symptoms. Other than these seven patients, 11 patients did not have any past medical histories. Only one patient had habitual headache episodes and the other 17 patients re-

ported never experiencing headaches in their lifetime (Table 3). We reviewed the study population for the conditions associated with RCVS, such as pregnancy-related conditions (late pregnancy, early puerperium, pre-eclampsia, and eclampsia); blood product transfusion; surgical procedures; and exposure to various vasoactive medications such as oral contraceptive pills, hormonal agents, selective serotonin reuptake inhibitors, alpha-sympathomimetic decongestants, illicit drugs, and acute migraine medications were reviewed, but no patients reported having these conditions or taking such medications. The mean duration of symptoms until diagnosis was 9.3 days, ranging from 2 hours to 1 month. The average number of ambulatory care visits before diagnosis was 4.7, ranging from 1 to 6.

### Headache profiles

Four patients reported a headache in the middle of the vertex, four in the occipital area, three in the frontal area, and seven over the entire head. Six patients described pulsating headaches, and 11 reported explosive headaches. Seventeen patients, excluding one who reported a pain intensity of 6, experienced severe headaches (pain intensities of 8 to 10 on a numerical rating scale). All patients reported sudden severe headaches that reached maximum intensity within minutes and were sustained for 30 minutes to several hours with residual moderate headaches between the severe exacerbations. Painkillers reduced the intensity of pain but did not eliminate it completely. Patients had to take painkillers

**Table 3.** Characteristics of the study patients

Patient no.	Age (yr)	Sex	Past medical history	Current medication	Habitual headache episodes	Symptom duration until diagnosis	No. of ambulatory care visits before diagnosis
1	55	F	Hyperlipidemia	Hormone therapy For 3 days	No	7 days	3
2	30	M	Hepatitis B virus carrier	Hepsera	No	5 days	1
3	58	F	Hypothyroidism	Synthroid	No	10 days	5
4	49	F	Rheumatic arthritis	Prednisolone	No	10 days	5
5	52	F	None	Hormone therapy For 10 days	No	1 mo	3
6	57	F	None	None	No	7 days	5
7	16	F	Takayasu's arteritis	Prednisolone	No	4 days	1
8	55	F	None	None	No	2 hr	1
9	51	M	None	None	No	12 days	2
10	39	M	None	None	No	3 days	5
11	58	F	Chronic kidney disease	None	No	4 days	3
12	61	F	Hyperlipidemia	None	No	10 days	3
13	52	F	None	None	No	5 days	3
14	56	F	None	None	Yes	2 days	2
15	63	F	None	None	No	3 days	3
16	52	F	None	None	No	9 days	3
17	51	F	None	None	No	7 days	6
18	58	F	None	None	No	3 days	3

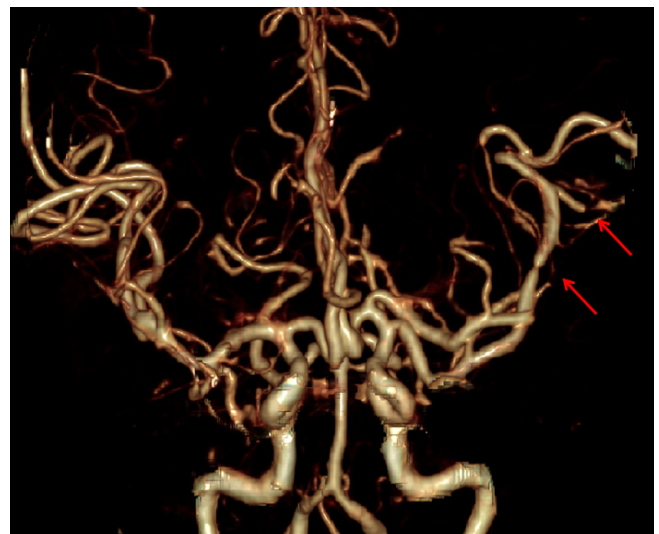
**Table 4.** Headache profiles of the study patients

Patient no.	Pain severity	Pain location	Character	Associated symptoms	Aggravating factors	Blood pressure in the emergency department
1	8	Vertex	Explosive	None	Cold	142/88
2	10	Diffuse	Pulsatile	Nausea	Defecation	177/103
3	10	Vertex	Explosive	Nausea	Defecation, coughing	133/86
4	9	Frontal	Explosive	Nausea Ocular pain	Leaning forward, urination	159/101
5	10	Frontal	Pulsatile	Nausea Ocular pain	Leaning forward, defecation	189/112
6	10	Diffuse	Pulsatile	None	None	145/82
7	8	Occipital	Explosive	None	None	124/82
8	8	Frontal	Tension	Vomiting	None	121/77
9	8	Diffuse	Explosive	Dizziness	Sexual activity	129/94
10	8	Vertex	Explosive	None	None	144/93
11	8	Vertex	Pulsatile	Nausea Vomiting	Valsalva Swimming	188/88
12	10	Diffuse	Explosive	Phonophobia	Coughing, urination	153/120
13	9	Diffuse	Explosive	None	Gagging, swimming	155/96
14	6	Occipital	Explosive	None	Defecation	167/97
15	10	Diffuse	Explosive	None	Wasabi intake Tooth brushing	163/95
16	10	Diffuse	Explosive	Nausea	Leaning forward	152/95
17	10	Occipital	Pulsatile	Nausea	Drinking beer	138/97
18	10	Occipital	Pulsatile	None	Leaning forward, defecation	180/89

over time because the headaches were not relieved easily with non-steroidal anti-inflammatory drugs or acetaminophen. No patient had aura preceding the headache attacks. Nausea and vomiting were reported at the onset of headache in seven patients. Eleven patients reported that strenuous exercise, sexual activity, coughing, defecating, urinating, gagging, or other Valsalva triggering maneuvers exacerbated the headaches. Identified triggering factors in our study were tooth brushing, drinking beer, eating wasabi, swimming, and exposure to cold weather. Even though no patients had a history of hypertension, 15 patients had acute blood pressure elevation during triage, which may have been secondary to pain (Table 4).

**Radiographic findings and clinical course**

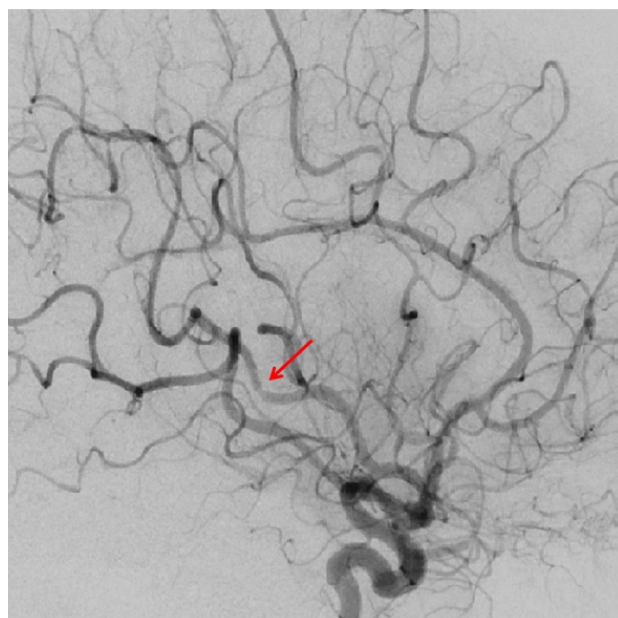Focal neurological deficits and seizures were not observed in any patients. The most frequently affected vessels were the middle cerebral arteries. Computed tomography (CT) angiography of the brain performed in 17 patients demonstrated the characteristic diffuse “string of beads” appearance in the middle cerebral arteries (Figs. 1, 2). The anterior circulation was affected in nine patients and the posterior circulation in six. In 15 patients (except patients 1, 2, and 18), ancillary serum laboratory investigations were performed, including blood count, electrolyte levels, hepatic and renal function tests, erythrocyte sedimentation rate, C-reactive



**Fig. 1.** A computed tomography angiography image of patient 17 on day 7 showing multifocal arterial narrowing of the cerebral arteries.

protein level, antinuclear and antineutrophil cytoplasmic antibody, and rheumatoid factor to exclude underlying connective tissue disorders such as infectious arteritis and inflammatory vasculitis, which share the radiological findings of RCVS. Patients 4, 6, and 11 were positive for rheumatoid factors. Their follow up CT angiography on days 20, 12, and 18 demonstrated complete res-

olution of vasoconstriction. The time to resolution of symptom ranged from 2 days to 4 months, but most patients reported that



**Fig. 2.** A transfemoral cerebral angiography image of patient 17 showing multifocal arterial narrowing of the cerebral arteries.

their headache was resolved within 2 months. All patients were given analgesic medications and bed rest. Nimodipine was administered to 16 patients due to its anti-vasospastic properties. Patients 11 and 14 were not given nimodipine. The blood pressure of these two patients was too low to start calcium channel blocker therapy. All patients reported a monophasic course without new headaches after the clinical diagnosis of RCVS was made. Other than three patients who were lost to follow-up, 15 patients had neither neurologic sequelae nor chronic headaches (Table 5).

## DISCUSSION

RCVS is characterized by acute, severe headaches with or without additional neurological deficits, often triggered by sexual activity, exertion, Valsalva maneuvers, emotion, and constriction of the cerebral arteries that resolves spontaneously within 12 weeks.<sup>1,7,10,11,13,20-22</sup> The diagnostic criteria are based on clinical, laboratory, and radiographic findings (Table 1)<sup>1</sup> and have been modified recently (Table 2).<sup>1,7,15</sup>

The exact incidence of RCVS is unknown, but it does not seem to be especially rare.<sup>7,13</sup> Its incidence is estimated to be between 8.8% and 45.8% in patients with thunderclap headache and those

**Table 5.** Computed tomography angiography manifestations and clinical courses of the study patients

Patient no.	Site of vasoconstriction	CSF findings	Treatment	Complication	Time to symptom resolution	Prognosis
1	Both MCA	Not done	Nimodipine	No	< 1 mo	Favorable
2	Both MCA, ACA Right PCA	Clear	Nimodipine	No	Unknown	Lost to follow up
3	Both MCA	Clear	Nimodipine	No	< 1 mo	Favorable
4	Both MCA, ACA Right PCA	RBC (+)	Nimodipine	SAH	< 2 mo	Favorable
5	Left MCA Both ACA	Not done	Nimodipine	SAH	< 1 mo	Favorable
6	Both ICA, right ACA, PCA	Not done	Nimodipine	No	< 1 mo	Favorable
7	Left MCA	Not done	Nimodipine	No	< 1 mo	Favorable
8	Both MCA	Not done	Nimodipine	No	< 2 day	Lost to follow up
9	Both MCA	Not done	Nimodipine	No	< 1 mo	Favorable
10	Right MCA	Clear	Nimodipine	No	< 1 mo	Favorable
11	Both ACA Right MCA, PCA	Clear	(-)	No	< 3 mo	Favorable
12	Both MCA Right ACA	Clear	Nimodipine	No	< 4 mo	Lost to follow up
13	Both MCA	RBC (+)	Nimodipine	SAH	< 4 mo	Favorable
14	Both MCA, ACA	Clear	(-)	No	< 1 mo	Favorable
15	Both MCA	Clear	Nimodipine	No	< 2 mo	Favorable
16	Both PCA Left MCA, PICA	Clear	Nimodipine	No	< 1 mo	Favorable
17	Both MCA, ACA, PCA	Not done	Nimodipine	SAH	< 2 mo	Favorable
18	Right MCA	Not done	Nimodipine	No	< 2 mo	Favorable

CSF, Cerebrospinal fluid; MCA, middle cerebral artery; ACA, anterior cerebral artery; PCA, posterior cerebral artery; SAH, subarachnoid hemorrhage; ICA, internal carotid artery; PICA, posterior inferior cerebellar artery.



without an obvious secondary cause of headache.<sup>12,23</sup> However, it might be underestimated because there is no research reporting the incidence of RCVS in ED patients, the most common mode of entry for patients presenting with thunderclap headache.

The characteristics of headaches associated with RCVS are severe pain that peaks in minutes, causing screaming, crying, agitation, and even collapse. For these reasons, it can often be confused with a ruptured aneurysm.<sup>24,25</sup> Nausea, vomiting, photophobia, and phonophobia frequently accompany the headaches.<sup>8,10,11,23-27</sup>

The headache is mostly moderate in severity between exacerbations.<sup>7</sup> Headaches caused by RCVS are not relieved easily with non-steroidal anti-inflammatory drugs or acetaminophen, which are the initial recommendations for primary headaches. This causes patients to repeatedly visit doctors seeking relief from the severe pain. In our study, patients with RCVS visited an average of 4.7 physicians before receiving an accurate diagnosis.

In one study by Ducros et al.,<sup>26</sup> vasoconstriction was detected at a mean of 8 days after headache onset, and up to 14 days in some patients. According to the present study, the mean duration of symptoms until diagnosis was 9.3 days. The results reveal that the incidence of RCVS is significantly underestimated and highlight the need for emergency physicians to be aware of RCVS in patients with severe-onset headaches.

Cerebral head angiography is essential for diagnosing RCVS.<sup>14</sup> CT angiography images of our patients showed multifocal segmental narrowing and dilatation of the cerebral arteries. Follow-up CT angiography showed complete regression of vasoconstriction.

The present study was limited by its retrospective nature, the small number of patients included, and the lack of a control group. Further study will be needed to evaluate the treatment of RCVS.

ED physicians should maintain a high index of suspicion for RCVS in order to improve its detection rates in patients with thunderclap headache when there is no evidence of aneurysmal SAH, not only because of its relatively high incidence and clinical manifestation of severe headache, but also because of the easy accessibility of newer, relatively noninvasive technologies such as CT angiography and magnetic resonance angiography to assess the cerebral vasculature. Furthermore, early recognition is important so that symptoms can be managed effectively with the elimination of precipitating factors and unfavorable complications such as seizure, stroke, and SAH.

## CONFLICT OF INTEREST

No potential conflict of interest relevant to this article was reported.

## REFERENCES

1. Headache Classification Committee of the International Headache Society (IHS). The International Classification of Headache Disorders, 3rd edition (beta version). *Cephalalgia* 2013; 33:629-808.
2. Grimaldi D, Cevoli S, Cortelli P. Headache in the emergency department. How to handle the problem? *Neurol Sci* 2008;29 Suppl 1:S103-6.
3. Hainer BL, Matheson EM. Approach to acute headache in adults. *Am Fam Physician* 2013;87:682-7.
4. Edlow JA, Panagos PD, Godwin SA, Thomas TL, Decker WW; American College of Emergency Physicians. Clinical policy: critical issues in the evaluation and management of adult patients presenting to the emergency department with acute headache. *Ann Emerg Med* 2008;52:407-36.
5. Dilli E. Thunderclap headache. *Curr Neurol Neurosci Rep* 2014; 14:437.
6. Schwedt TJ. Thunderclap headache. *Continuum (Minneapolis)* 2015;21:1058-71.
7. Ducros A. Reversible cerebral vasoconstriction syndrome. *Lancet Neurol* 2012;11:906-17.
8. Calabrese LH, Dodick DW, Schwedt TJ, Singhal AB. Narrative review: reversible cerebral vasoconstriction syndromes. *Ann Intern Med* 2007;146:34-44.
9. Calic Z, Choong H, Schlaphoff G, Cappelen-Smith C. Reversible cerebral vasoconstriction syndrome following indomethacin. *Cephalalgia* 2014;34:1181-6.
10. Ducros A. L37. Reversible cerebral vasoconstriction syndrome: distinction from CNS vasculitis. *Presse Med* 2013;42:602-4.
11. Ducros A, Boussier MG. Reversible cerebral vasoconstriction syndrome. *Pract Neurol* 2009;9:256-67.
12. Grooters GS, Sluzewski M, Tijssen CC. How often is thunderclap headache caused by the reversible cerebral vasoconstriction syndrome? *Headache* 2014;54:732-5.
13. Miller TR, Shivashankar R, Mossa-Basha M, Gandhi D. Reversible cerebral vasoconstriction syndrome. Part 1: epidemiology, pathogenesis, and clinical course. *AJNR Am J Neuroradiol* 2015; 36:1392-9.
14. Chen SP, Fuh JL, Wang SJ. Reversible cerebral vasoconstriction syndrome: an under-recognized clinical emergency. *Ther Adv Neurol Disord* 2010;3:161-71.
15. Singhal AB, Hajj-Ali RA, Topcuoglu MA, et al. Reversible cerebral vasoconstriction syndromes: analysis of 139 cases. *Arch Neurol* 2011;68:1005-12.
16. Fugate JE, Wijndicks EF, Parisi JE, et al. Fulminant postpartum cerebral vasoconstriction syndrome. *Arch Neurol* 2012;69:

- 111-7.
17. Geocadin RG, Razumovsky AY, Wityk RJ, Bhardwaj A, Ulatowski JA. Intracerebral hemorrhage and postpartum cerebral vasculopathy. *J Neurol Sci* 2002;205:29-34.
  18. Katz BS, Fugate JE, Ameriso SF, et al. Clinical worsening in reversible cerebral vasoconstriction syndrome. *JAMA Neurol* 2014;71:68-73.
  19. Robert T, Kawkabani Marchini A, Oumarou G, Uske A. Reversible cerebral vasoconstriction syndrome identification of prognostic factors. *Clin Neurol Neurosurg* 2013;115:2351-7.
  20. Papathanasiou A, Zouvelou V, Breen DP, et al. Reversible cerebral vasoconstriction syndrome as a cause of thunderclap headache: a retrospective case series study. *Am J Emerg Med* 2015;33:859.e3-6.
  21. Gupta S, Zivadinov R, Ramasamy D, Ambrus JL Jr. Reversible cerebral vasoconstriction syndrome (RCVS) in antiphospholipid antibody syndrome (APLA): the role of centrally acting vasodilators. Case series and review of literature. *Clin Rheumatol* 2014;33:1829-33.
  22. Liang H, Xu Z, Zheng Z, Lou H, Yue W. Reversible cerebral vasoconstriction syndrome following red blood cells transfusion: a case series of 7 patients. *Orphanet J Rare Dis* 2015;10:47.
  23. Chen SP, Fuh JL, Wang SJ. Reversible cerebral vasoconstriction syndrome: current and future perspectives. *Expert Rev Neurother* 2011;11:1265-76.
  24. Call GK, Fleming MC, Sealton S, Levine H, Kistler JP, Fisher CM. Reversible cerebral segmental vasoconstriction. *Stroke* 1988;19:1159-70.
  25. Nowak DA, Rodiek SO, Henneken S, et al. Reversible segmental cerebral vasoconstriction (Call-Fleming syndrome): are calcium channel inhibitors a potential treatment option? *Cephalalgia* 2003;23:218-22.
  26. Ducros A, Boukobza M, Porcher R, Sarov M, Valade D, Bousser MG. The clinical and radiological spectrum of reversible cerebral vasoconstriction syndrome: a prospective series of 67 patients. *Brain* 2007;130:3091-101.
  27. Singhal AB, Bernstein RA. Postpartum angiopathy and other cerebral vasoconstriction syndromes. *Neurocrit Care* 2005;3:91-7.