






CLINICAL PRACTICE ARTICLE

REVISED Noninvasive fungal rhinosinusitis: a case series [version 2; peer review: 2 approved]

Mohamed Masmoudi ¹, Jihene Chelli², Asma Ben Mabrouk ², Ezer Chebil ¹,
Wadii Thabet¹, Mehdi Hasnaoui¹, Khalifa Mighri¹

¹Department of Otolaryngology - Head and Neck Surgery, Faculty of Medicine of Monastir, Tahar Sfar Hospital, Mahdia, 5100, Tunisia

²Department of Endocrinology and Internal Medicine, Faculty of Medicine of Monastir, Tahar Sfar Hospital, Mahdia, 5100, Tunisia

V2 **First published:** 31 Aug 2021, 10:869
<https://doi.org/10.12688/f1000research.67204.1>
Latest published: 14 Sep 2022, 10:869
<https://doi.org/10.12688/f1000research.67204.2>

Abstract

Introduction: Fungal rhinosinusitis (FRS) remains a rare disease. The noninvasive forms are hard to diagnose. The management protocols remain controversial. We aim to describe the clinical, radiological and pathological features of noninvasive FRS and present our management protocol and follow-up results.

Patients and methods: This descriptive study was conducted in the ear-nose-throat department of the university hospital, Taher Sfar in Mahdia, Tunisia. All patients who responded to the definition of noninvasive FRS (fungal balls and allergic fungal sinusitis) were included. The study was conducted over a three year period (May 2017 – April 2021).

Results: Eleven patients were included in this study: four cases of fungal balls and seven cases of allergic fungal sinusitis. Patients presented with symptoms of chronic recurrent rhinosinusitis with no response to conventional treatments. Computed tomodensitometry scan showed opacification of the paranasal sinuses in all patients. Other signs were heterogeneous opacities, local calcifications and thinning of the bony walls of the sinuses.

Histopathological findings were inflammatory polyps in all cases of allergic FRS with the presence of fungal hyphae in 42.8% of the cases. All patients underwent surgery after a median delay of 12 [6–24] months of the symptom's onset. The used procedures were endoscopic middle meatal antrostomy for all patients, ethmoidectomy (81.8%) and sphenoidotomy (36.4%). None received systemic antifungals or corticosteroids with a favorable outcome in all cases.




Conclusion: Symptoms of noninvasive FRS are nonspecific. The scan images contribute to the diagnosis, but the perioperative findings and the histopathological results remain crucial. The management is mainly surgical.


Keywords


allergic fungal sinusitis, fungal ball, diagnosis, surgery, treatment

Open Peer Review

Approval Status  

| | 1 | 2 |
|---|---|---|
| version 2 (revision) 14 Sep 2022 | |  view |
| version 1 31 Aug 2021 |  view |  view |

1. **Senda Turki** , Université Tunis El Manar, Tunis, Tunisia

2. **Yasser M. Elbeltagy** , Ain Shams University, Cairo, Egypt

Any reports and responses or comments on the article can be found at the end of the article.

Corresponding author: Mohamed Masmoudi (m_masmoudi@yahoo.fr)

Author roles: **Masmoudi M:** Conceptualization, Data Curation, Formal Analysis, Investigation, Methodology, Project Administration, Writing – Original Draft Preparation, Writing – Review & Editing; **Chelli J:** Conceptualization, Methodology, Visualization; **Ben Mabrouk A:** Conceptualization, Investigation, Methodology, Project Administration, Visualization, Writing – Original Draft Preparation, Writing – Review & Editing; **Chebil E:** Conceptualization, Visualization; **Thabet W:** Conceptualization, Visualization, Writing – Original Draft Preparation; **Hasnaoui M:** Validation, Visualization; **Mighri K:** Supervision

Competing interests: No competing interests were disclosed.

Grant information: The author(s) declared that no grants were involved in supporting this work.

Copyright: © 2022 Masmoudi M *et al.* This is an open access article distributed under the terms of the [Creative Commons Attribution License](#), which permits unrestricted use, distribution, and reproduction in any medium, provided the original work is properly cited.

How to cite this article: Masmoudi M, Chelli J, Ben Mabrouk A *et al.* **Noninvasive fungal rhinosinusitis: a case series [version 2; peer review: 2 approved]** F1000Research 2022, **10**:869 <https://doi.org/10.12688/f1000research.67204.2>

First published: 31 Aug 2021, **10**:869 <https://doi.org/10.12688/f1000research.67204.1>

REVISED Amendments from Version 1

Some information was initially ambiguous and some details were added to clarify it.

Lund - Mckay CT assessment was added to the radiological data (Table 1).

New references were added to enrich the manuscript based on the reviewers' advice.

Any further responses from the reviewers can be found at the end of the article

Introduction

Fungal rhinosinusitis (FRS) consists of a group of heterogeneous affections¹. At one time FRS was considered a rare disease but its incidence seems to be increasing all over the world². The diagnosis is particularly difficult. On one hand, the clinical presentation is non-specific and sometimes misleading. On the other hand, fungal colonization of the sinuses is very common making it hard to be certain of its implication in the genesis of the pathology^{3,4}. The most used classification is based on histopathological evidence of tissue invasion by fungi. It divides FRS into invasive and noninvasive forms. The invasive FRS includes acute invasive, granulomatous invasive FRS, and chronic invasive FRS. The noninvasive FRS includes fungal colonization, fungal ball, and allergic fungal sinusitis⁵. The aim of this study is to describe the clinical, radiological and pathological features of noninvasive FRS in our ear-nose-throat (ENT) department and present our management protocol and follow-up results.

Patients and methods

This descriptive study was conducted in the ENT department of the university hospital, Taher Sfar in Mahdia. All patients who responded to the definition of noninvasive fungal rhinosinusitis (fungal balls and allergic fungal sinusitis) according to the 2009 consensus were included⁵. The study was conducted over a three-year period between May 2017 and May 2021.

The patients' medical records were consulted and data including demographic characteristics, clinical examination findings, computed tomodensitometry scan results, cytopathology findings and management details were collected.

Computed tomodensitometry scan images were obtained using a General Electric BrightSpeed Elite 16 slice CT scanner. Coronal and sagittal views were reformatted with a 1.25 mm slice thickness.

Magnetic resonance imaging was not available in our hospital, so, it was only realized for patients who could afford to pay for it in the private sector.

Statistical analysis was carried out with Statistical Package for Social Sciences (SPSS) Statistics, version 23, (IBM Corp., Armonk, NY. Released 2015). The results were expressed as numerical values (percentages) for categorical variables, medians [interquartile range] for continuous variables when Kolmogorov-Smirnov p-value was inferior to 0.05 and

means \pm standard deviation when Kolmogorov-Smirnov p-value was superior to 0.05. Univariate analysis was performed using the chi-square tests. Co-variables retained in the final model were the ones significant at the level of 5%.

Results

Eleven patients were included in this study, four cases of fungal balls and seven cases of allergic fungal sinusitis (Table 1). The median age was 33 [25–42] years with a sex ratio of 0.83. Two patients were diabetics and one patient had asthma.

None of the patients reported a history of dental infection or endodontic procedure.

The median delay between the consultation and the symptom's onset was 12 [9–60] months. The main symptoms, patients presented with, were nasal obstruction (N=9; 81.8%), rhinorrhoea (N=5; 45.5%), anosmia (N=4; 36.4) and epistaxis (N=3; 27.3%).

None of the patients presented with fever. Anterior rhinoscopy was performed for all patients. Polyps were found in six cases (54.5%). The presence of mucopurulent drainage was noted in four patients (36.4%). A septal deviation was found in four cases (36.4%).

Computed tomodensitometry scan showed opacification of the paranasal sinuses in all patients, unilateral in eight cases (72.7%) and bilateral in three cases (27.3%). The affection consisted of pansinusitis in eight cases (72.7%). The other radiological signs were heterogeneous opacities within the sinus cavity (N=5; 45.5%), local calcifications (N=4; 36.4%) and thinning of the bony walls of the sinuses (N=4; 36.4%) (Figure 1).

MRI of the facial mass was performed in four patients. In all cases, it showed T2 hypointense (signal void) images suggestive of the mycotic origin (Figure 2).

Histopathological findings were inflammatory polyps in all cases of allergic FRS with the presence of fungal hyphae in 45.8% of the cases. For fungal balls, masses of aspergillus mycelia along with inflammatory cells were found in 75% of the cases (Table 1).

All patients underwent surgery after a median delay of 12 [6–24] months of the symptom's onset. The used procedures were endoscopic middle meatal antrostomy for all patients (100%), ethmoidectomy for nine patients (81.8%), sphenoidotomy for four patients (36.4%), septoplasty for three patients (27.3%) and turbinoplasty for one patient (9.1%). Details of the surgical procedures and perioperative findings are presented in Table 1, Figure 3 and Figure 4. None of the patients received systemic antifungal treatment. All were prescribed a local treatment with nasal saline topical. The seven patients diagnosed with allergic FRS received nasal steroid sprays (63.6%). After a median follow-up delay of three [1–12] months, all patients had a favorable outcome, and no recurrence was reported during this period. However, in the case of allergic FRS, the recovery seemed to take more time, and symptoms seemed to persist a little longer than the fungal ball cases.

Table 1. Report of the 11 cases of noninvasive fungal rhinosinusitis.

| | Age (years) | Gender | Sinusitis type | Scan results | Lund - Mckay score | MRI of the sinuses | Perioperative findings | Surgical procedure | Cytopathology results |
|---|-------------|--------|----------------|---|--------------------|--|---|---|---|
| 1 | 23 | F | AFRS | Unilateral opacification of the ethmoidal, frontal and maxillary sinuses | 6 | - | Mucin within the ethmoidal and maxillary sinuses | Endoscopic middle meatal antrostomy + anterior ethmoidectomy | Inflammatory polyps + fungal hyphae |
| 2 | 42 | F | AFRS | Bilateral opacification of all sinuses | 24 | - | Mucin within the two maxillary sinuses | Endoscopic middle meatal antrostomy + total ethmoidectomy + sphenoidotomy | Inflammatory polyps |
| 3 | 34 | F | AFRS | Unilateral opacification of all sinuses | 12 | - | Mucin within the ethmoidal and maxillary sinuses | Endoscopic middle meatal antrostomy + total ethmoidectomy | Inflammatory polyps + fungal hyphae + Charcot Leyden crystals |
| 4 | 33 | M | AFRS | Bilateral opacification of all sinuses + thinning of the bony walls of the frontal sinus | 24 | T1: central hypointensity T2: a signal void | Polyps of the middle meatal + mucin | Endoscopic middle meatal antrostomy + total ethmoidectomy + sphenoidotomy | Inflammatory polyps + aspergillus hyphae |
| 5 | 35 | M | AFRS | Unilateral opacification of the ethmoidal, sphenoidal and maxillary sinuses + thinning of the bony walls of the maxillary sinus | 6 | - | Mucin within the sinuses | Endoscopic middle meatal antrostomy + total ethmoidectomy + sphenoidotomy + septoplasty | Inflammatory polyps |
| 6 | 30 | F | AFRS | Unilateral opacification of all sinuses + calcifications + thinning of the bony walls of the ethmoidal and sphenoidal sinuses | 12 | T1: central hypointensity T2: a signal void | Mucin within the sinuses | Endoscopic middle meatal antrostomy + total ethmoidectomy + sphenoidotomy | Inflammatory polyps |
| 7 | 25 | M | AFRS | Unilateral opacification of all sinuses + calcifications + thinning of the bony walls of the frontal and sphenoidal sinuses | 12 | T1: central hypointensity T2: a signal void | Mucin within the sphenoidal and maxillary sinuses | Endoscopic middle meatal antrostomy + total ethmoidectomy + sphenoidotomy + septoplasty | Inflammatory polyps |

| | Age (years) | Gender | Sinusitis type | Scan results | Lund - Mckay score | MRI of the sinuses | Perioperative findings | Surgical procedure | Cytopathology results |
|----|-------------|--------|----------------|--|--------------------|---|--|--|---|
| 8 | 33 | F | FB | Unilateral opacification of all sinuses + calcifications | 12 | T1: isointensity T2: hyper intensity | Scattered purulent material within the ethmoidal and maxillary sinuses | Endoscopic middle meatal antrostomy + total ethmoidectomy | Inflammatory polyps + aspergilloma |
| 9 | 62 | M | FB | Unilateral opacification of the maxillary sinus + a thickening of the bony walls | 2 | - | Scattered purulent material within the maxillary sinus | Endoscopic middle meatal antrostomy + septoplasty | Masses of aspergillosis mycelia, inflammatory cells, fibrin and mucus |
| 10 | 56 | M | FB | Unilateral opacification of the maxillary sinus + calcifications + a thickening of the bony walls | 2 | - | Scattered purulent material within the maxillary sinus | Endoscopic middle meatal antrostomy + turbinoplasty | Masses of aspergillosis mycelia, inflammatory cells, fibrin and mucus |
| 11 | 25 | F | FB | Unilateral opacification of the ethmoidal, frontal and maxillary sinuses + thickening of the bony walls of the sinuses | 6 | - | Necrotic formations of the ethmoidal and maxillary sinuses | Endoscopic middle meatal antrostomy + anterior ethmoidectomy | Inflammatory polyps |

F= Female, M= Male, AFRS= Allergic fungal rhinosinusitis, FB= Fungal ball, MRI= Magnetic resonance imaging

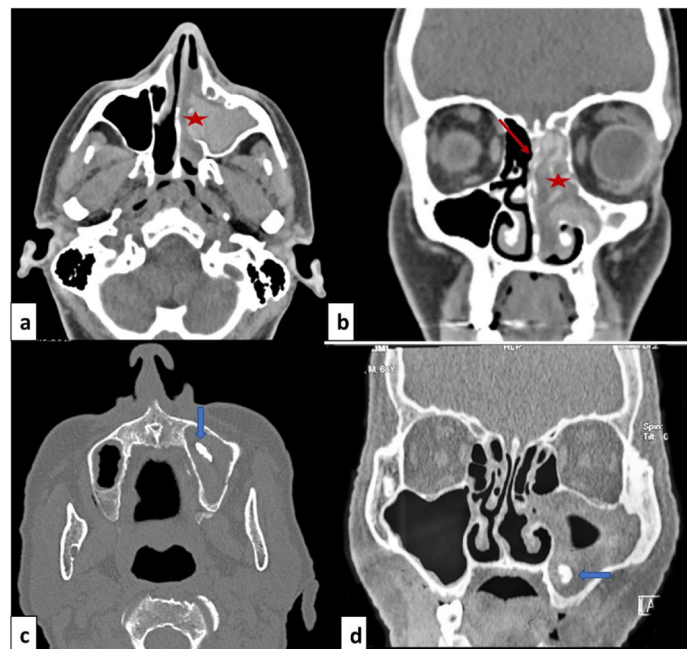


Figure 1. Facial mass computed tomodensitometry with axial cut (a, c) and coronal cut (b, d). (a, b): Allergic fungal rhinosinusitis: heterogeneous opacity of the nasal cavity and ethmoido-maxillary cavities (red star) and thinning of the bony walls (red arrow). (b, d): Fungal ball: opacity of the right maxillary sinus with local calcification in maxillary sinus (blue arrow).

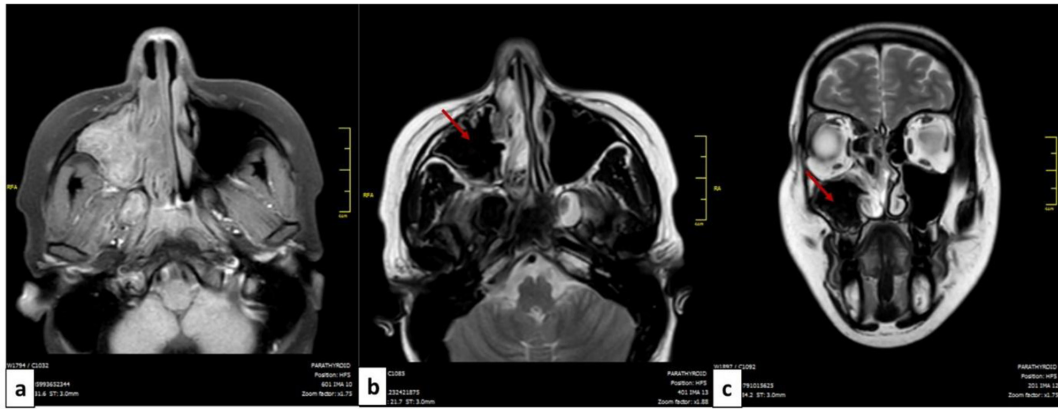

Figure 2. MRI of the facial mass of a patient with allergic fungal rhinosinusitis: axial cut (a,b) and coronal cut (c). The filling of the left maxillary sinus is presented in isosignal T1 (a) and in hyposignal T2 or signal void (red arrow) (b,c).

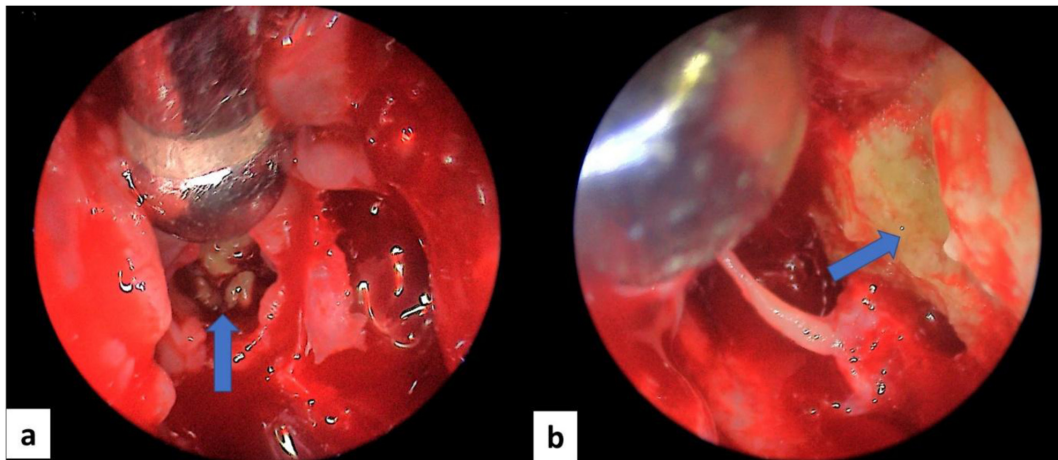


Figure 3. Intraoperative endoscopic view of a case of allergic fungal rhinosinusitis: mucin (blue arrow) within ethmoidal cells (a) and of the left maxillary sinus (b).

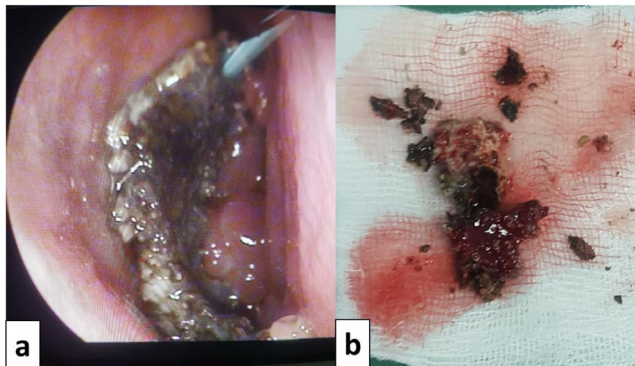


Figure 4. Intraoperative view of a case of fungal ball: a: fungal ball taken from the left maxillary sinus. b: fungal ball specimen.

None of the symptoms such as nasal obstruction, rhinorrhoea, anosmia and epistaxis, was associated with either of the forms (fungal balls or allergic fungal sinusitis) with respective p-values of 1, 1, 0.2 and 1.

Discussion

Although sinusitis is very common, fungal sinusitis remains rare, but the prevalence seems to be rising all over the world, *Aspergillus* sp. being the most implicated fungal agent⁶.

The fungi's implication in rhinosinusitis has been widely discussed and many diagnostic criteria have been proposed in order to identify the different forms. The most used classification is the one dividing FRS into invasive and noninvasive sinusitis based on histopathological findings. On one hand, the invasive forms include acute invasive FRS,

granulomatous invasive FRS, and chronic invasive FRS. On the other hand, noninvasive forms include saprophytic fungal infestation, fungal ball, and fungus related-eosinophilic FRS, mainly allergic FRS⁵. In this study, we only focused on noninvasive FRS presenting as fungal balls or allergic fungal sinusitis. This pathology, as found in our results, mainly occurs among young adults⁷.

In line with our findings, individuals with allergic FRS or fungal balls are reported to present with the typical symptoms of chronic rhinosinusitis, including nasal congestion, facial pain when pressuring the sinuses, and nasal discharge¹. The symptoms are chronic (> three months), recurrent and resistant to conventional treatments usually prescribed for chronic rhinosinusitis⁶. These two forms, despite their common clinical presentation, have different physiopathology. In the case of fungal balls, the fungi colonizing the sinus mucosa produce a dense conglomeration of hyphae within the maxillary sinus or, less frequently, in the sphenoid sinus⁸. In the case of allergic FRS, a profound Th2 lymphocyte response associated with eosinophilic mucin within the sinus was noted⁸. Many studies suggest that fungi may have an effect on sinus mucosa in susceptible individuals. The absence of convincing immunological data and the controversial role of antifungal agents make it hard to conclude the real role of fungi in the genesis of allergic FRS³. Some suggest that the mechanism is similar to allergic bronchopulmonary aspergillosis, fungal antigens induce a type I hypersensitivity reaction with the production of IgE, IgA and IgG⁶.

According to the recent classification of Chronic Rhinosinusitis, the fungal ball is most often related to an endodontic history. For the 4 cases of fungal ball in our series, there was no history of dental infection nor procedure⁹. All patients were referred to a dentist for a specialized dental examination and eventual treatment of a dental cause to reduce the risk of recurrence.

Anterior rhinoscopy findings reported in the literature are congruent with our findings, mainly congestive mucosa, mucopurulent discharge and polyps especially in the case of allergic FRS¹⁰.

The computed tomodensitometry scan images contribute to the diagnosis. In the case of fungal balls, the affection mostly concerns the maxillary sinus. The most reported features were calcifications within the maxillary sinus followed by complete opacification, partial opacification with an irregular surface and bony sclerosis or bone thickening¹¹. These signs remain nonspecific and could be seen in sinusitis of other origins or neoplasms. The MRI is more performant, the fungal ball is hypointense on T1-weighted and T2-weighted images. In the case of allergic FR, scan images typically show bilateral pansinusitis. The opacification of the sinuses is explained by the hyperattenuated mucin. In many cases, as noted for our patients, expansion and thinning of sinus walls were reported.

T1-weighted MRI images may show mixed signal intensities. T2-weighted images are mostly hypointense but may show flow voids¹.

Histopathological findings are the main diagnostic criterion. It is the only element to confirm the noninvasive form of the disease. The other findings reported were copious mucin, abundant eosinophils, Charcot-Leyden crystals, with rare noninvasive fungal hyphae in case of allergic FRS. Tightly packed fungal hyphae without allergic mucin are the characteristic feature of fungal balls¹².

The results of fungal cultures were not presented in our study. In the literature, *Aspergillus fumigatus* is the most incriminated fungal species in the genesis of fungal balls, but the fungal cultures were negative in 65% of cases. In allergic FRS, the use of type I hypersensitivity testing is a fundamental diagnosis criterion. This test is unfortunately unavailable in our settings. Fungal cultures are not useful since studies have shown a difference between the fungal species cultured and fungal-specific sensitivities revealed by the allergy testing¹.

The diagnosis of fungal balls is easily confirmed when there is radiological evidence of sinus opacification with or without radiographic heterogeneity, a mucopurulent or necrotic material in the sinus and a histological aspect associating a dense conglomeration of hyphae and inflammation of the mucosa without invasion⁵.

The diagnosis of allergic FRS is less evident, based on the association of many criteria; type I hypersensitivity to fungi, nasal polyposis, fungi on staining, eosinophilic mucin without fungal invasion into sinus tissue, and characteristic radiological findings on CT scanning⁶. The determination of serum IgE level could be an additional element in the diagnosis¹³. But, this biomarker was not available in our laboratory.

The management of noninvasive FRS is mainly surgical. Surgical opening of the natural sinus ostium with the evacuation of fungal debris is the treatment of choice in the case of fungal balls. An inferior meatal window combined with the middle meatal antrostomy could reduce the risk of leaving residual debris¹³. After the removal of fungal hyphae, no additional treatment is necessary according to most recommendations^{1,6}.

The management of allergic FRS is less consensual. Surgical management was adopted by most series to remove polyps, open sinus ostia, and clear the eosinophilic fungal mucin.

Many medical therapies were tried in the management of allergic FRS. Oral corticosteroid therapy over a period of 2 to 6 months, with close monitoring of side effects and topical steroids were the most used medications with a reported improvement of the symptoms and reduction of recurrences¹³. Oral antifungals such as voriconazole and itraconazole and topical antifungal agents have been proposed by some authors,

especially, in immunocompromised patients in order to prevent invasive forms of FRS. However, these therapies remain unsupported by solid data^{6,14}. Leukotriene antagonists and immunotherapy have also been used with no evidence of a better outcome^{1,15}. Our management protocol was based on endoscopic surgery with postoperative topical steroids with a favorable outcome.

This study is, to our knowledge, the first to report cases of noninvasive FRS in Tunisia. This disease, once rare, is reported more and more. Our management protocol seems to have good results, but we conducted a single-center study with a limited number of cases. On the other hand, the follow-up period was limited, and recurrences may occur in the future. Multicenter studies with a longer follow-up could refine the results and help draw better conclusions.

Conclusion

Noninvasive FRS is to be evoked when a patient presents with symptoms of chronic recurrent rhinosinusitis with no response to conventional treatments. Scan images could help steer toward the diagnosis, but the perioperative findings and the histopathological results remain crucial. Surgical treatment is the milestone in the management of FRS.

Consent

Written informed consent for publication of their clinical details and clinical images was obtained from the patients.

Data availability

All data underlying the results are available as part of the article and no additional source data are required.

References

- Soler ZM, Schlosser RJ: **The role of fungi in diseases of the nose and sinuses.** *Am J Rhinol Allergy.* 2012; **26**(5): 351–8. [PubMed Abstract](#) | [Publisher Full Text](#) | [Free Full Text](#)
- Singh V: **Fungal Rhinosinusitis: Unravelling the Disease Spectrum.** *J Maxillofac Oral Surg.* 2019; **18**(2): 164–79. [PubMed Abstract](#) | [Publisher Full Text](#) | [Free Full Text](#)
- Ebbens FA, Georgalas C, Fokkens WJ: **Fungus as the cause of chronic rhinosinusitis: The case remains unproven.** *Curr Opin Otolaryngol Head Neck Surg.* 2009; **17**(1): 43–9. [PubMed Abstract](#) | [Publisher Full Text](#)
- Fokkens WJ, Ebbens F, van Drunen CM: **Fungus: A Role in Pathophysiology of Chronic Rhinosinusitis, Disease Modifier, A Treatment Target, or No Role at All?** *Immunol Allergy Clin North Am.* 2009; **29**(4): 677–88. [PubMed Abstract](#) | [Publisher Full Text](#)
- Chakrabarti A, Denning DW, Ferguson BJ, et al.: **Fungal rhinosinusitis: a categorization and definitional schema addressing current controversies.** *Laryngoscope.* 2009; **119**(9): 1809–18. [PubMed Abstract](#) | [Publisher Full Text](#) | [Free Full Text](#)
- Lafont E, Aguilar C, Vironneau P, et al.: **[Fungal sinusitis].** *Rev Mal Respir.* 2017; **34**(6): 672–92. [PubMed Abstract](#) | [Publisher Full Text](#)
- Makni F, Cheikhrouhou F, Sellami A, et al.: **Les sinusites aspergillaires : à propos de trois cas dans l'hôpital de Sfax, Tunisie.** *J Mycol Med.* 2008; **18**(2): 103–5. [Publisher Full Text](#)
- Denning DW, Chakrabarti A: **Pulmonary and sinus fungal diseases in non-immunocompromised patients.** *Lancet Infect Dis.* 2017; **17**(11): e357–66. [PubMed Abstract](#) | [Publisher Full Text](#)
- Grayson JW, Hopkins C, Mori E, et al.: **Contemporary Classification of Chronic Rhinosinusitis Beyond Polyps vs No Polyps: A Review.** *JAMA Otolaryngol Head Neck Surg.* 2020; **146**(9): 831–8. [PubMed Abstract](#) | [Publisher Full Text](#)
- Delbet C, Barth I, Teitelbaum J, et al.: **Mycozes aspergillaires des sinus maxillaires.** *Chirurgie orale et maxillo-faciale.* 2013.
- Lee DH, Yoon TM, Lee JK, et al.: **Computed tomography-based differential diagnosis of fungus balls in the maxillary sinus.** *Oral Surg Oral Med Oral Pathol Oral Radiol.* 2020; **129**(3): 277–81. [PubMed Abstract](#) | [Publisher Full Text](#)
- Granville L, Chirala M, Cernoch P, et al.: **Fungal sinusitis: histologic spectrum and correlation with culture.** *Hum Pathol.* 2004; **35**(4): 474–81. [PubMed Abstract](#) | [Publisher Full Text](#)
- Fokkens WJ, Lund VJ, Hopkins C, et al.: **European Position Paper on Rhinosinusitis and Nasal Polyps 2020.** *Rhinology.* 2020; **58**(Suppl S29): 1–464. [PubMed Abstract](#) | [Publisher Full Text](#)
- Chan KO, Genoway KA, Javer AR: **Effectiveness of itraconazole in the management of refractory allergic fungal rhinosinusitis.** *J Otolaryngol Head Neck Surg.* 2008; **37**(6): 870–4. [PubMed Abstract](#)
- Klossek JM, Kauffman-Lacroix C, Dufour X: **Agent fongique et pathologie rhinosinusienne Fungal infection and rhinosinusitis.** *Rev Française d'Allergologie d'Immunologie Clin.* 2005; **45**(1): 25–8. [Publisher Full Text](#)

Open Peer Review

Current Peer Review Status:  

Version 2

Reviewer Report 30 September 2022

<https://doi.org/10.5256/f1000research.136141.r150422>

© 2022 Elbeltagy Y. This is an open access peer review report distributed under the terms of the [Creative Commons Attribution License](#), which permits unrestricted use, distribution, and reproduction in any medium, provided the original work is properly cited.



Yasser M. Elbeltagy 

Department of Otorhinolaryngology, Ain Shams University, Cairo, Egypt

The authors mentioned reasonable explanations to my questions. I accept their answers. Thank you for your reply.

Competing Interests: No competing interests were disclosed.

Reviewer Expertise: Rhinology

I confirm that I have read this submission and believe that I have an appropriate level of expertise to confirm that it is of an acceptable scientific standard.

Version 1

Reviewer Report 22 November 2021

<https://doi.org/10.5256/f1000research.70803.r93107>

© 2021 Elbeltagy Y. This is an open access peer review report distributed under the terms of the [Creative Commons Attribution License](#), which permits unrestricted use, distribution, and reproduction in any medium, provided the original work is properly cited.



Yasser M. Elbeltagy 

Department of Otorhinolaryngology, Ain Shams University, Cairo, Egypt

1. The nasal endoscopic examination should be mentioned & performed in the study design, not only anterior rhinoscopy.

2. Concerning imaging studies used in the article, the authors did not mention MRI in the study design. They mentioned it later in the results that made the matter perplexing.
3. Concerning the evaluation of CT findings in cases studied, I would prefer Lund - Mckay scores for the accurate evaluation of the severity of sinusitis numerically rather than a descriptive one.
4. The authors did not mention the progressive course of illness of the 2 patients (the diabetic one & the asthmatic one) as they are expected to have severer presentation than other ones.

Is the background of the cases' history and progression described in sufficient detail?

Partly

Are enough details provided of any physical examination and diagnostic tests, treatment given and outcomes?

No

Is sufficient discussion included of the importance of the findings and their relevance to future understanding of disease processes, diagnosis or treatment?

Partly

Is the conclusion balanced and justified on the basis of the findings?

Partly

Competing Interests: No competing interests were disclosed.

Reviewer Expertise: Rhinology

I confirm that I have read this submission and believe that I have an appropriate level of expertise to confirm that it is of an acceptable scientific standard, however I have significant reservations, as outlined above.

Author Response 12 Jul 2022

Mohamed Masmoudi, Faculty of Medicine of Monastir, Mahdia, Tunisia

The nasal endoscopic examination should be mentioned & performed in the study design, not only anterior rhinoscopy.

Author response: Anterior rhinoscopy and nasal endoscopic examination were performed for all patients. It was an omission in the initial manuscript.

Concerning imaging studies used in the article, the authors did not mention MRI in the study design. They mentioned it later in the results that made the matter perplexing.

Author response: Magnetic resonance imaging was not available in our hospital, so, it was

only realized for patients who could afford to pay for it in the private sector. We added this sentence to the manuscript.

Concerning the evaluation of CT findings in cases studied, I would prefer Lund - Mckay scores for the accurate evaluation of the severity of sinusitis numerically rather than a descriptive one.

Author response: The score was calculated and added to table I.

The authors did not mention the progressive course of illness of the 2 patients (the diabetic ones (3 + 10) & the asthmatic one (2) as they are expected to have a severer presentation than other ones.

Author response: The two diabetic patients (3 and 10 in the table) and the asthmatic one (2 in the table) did not have anything in particular concerning their presentation or their outcome.

Thank you for your advice that helped improve this manuscript.

Competing Interests: No competing interests were disclosed.

Reviewer Report 17 September 2021

<https://doi.org/10.5256/f1000research.70803.r93106>

© 2021 Turki S. This is an open access peer review report distributed under the terms of the [Creative Commons Attribution License](#), which permits unrestricted use, distribution, and reproduction in any medium, provided the original work is properly cited.



Senda Turki 

Service ORL, Hôpital FSI, Faculté de Médecine de Tunis, Université Tunis El Manar, Tunis, Tunisia

The topic addressed in this study is particularly interesting because it deals with a frequent pathology whose diagnosis is difficult and whose early treatment makes it possible to avoid the evolution to serious complications. If the treatment is undoubtedly based on a complete surgical procedure, the place of an associated medical treatment (whether preoperative or postoperative) remains a matter of controversy.

This study is easy to follow, well-structured, and illustrated with endoscopic views and well-captioned radiologic images. Given the fact that it is a small series, the statistical study is considered to be modest. On the other hand, the different cases are very clearly presented in Table 1. The main points are correctly detailed in the discussion section.

However, I have a few remarks that the authors might consider:

1. According to the recent classification of Chronic Rhinosinusitis (CRS), the fungal ball is a

secondary CRS and is most often related to an endodontic history (more than 80% of cases). For the 4 fungal balls of the series, there is no information regarding the dental history, the specialized dental examination, the dentascans. The treatment of dental causes should be combined with surgical treatment to reduce the risk of recurrence. "Contemporary Classification of Chronic Rhinosinusitis Beyond Polyps vs No Polyps: A Review"¹. Jessica W Grayson, Claire Hopkins, Eri Mori, Brent Senior, Richard J Harvey.

2. An inferior meatal window combined with the middle meatal antrostomy for the treatment of fungal balls would reduce the risk of leaving residual debris (EPOS2020)²
3. An MRI was requested in 4 patients: What were the clinical or radiologic criteria that motivated the request for an additional MRI? What were the radiological elements that the MRI had to specify?
4. Concerning the cases of allergic fungal rhinosinusitis: a/ The determination of serum IgE level would be an additional element in the diagnosis. b/ Postoperative oral corticosteroid therapy over a period of 2 to 6 months (with close monitoring of side effects) demonstrated a net benefit on faster amendment of symptoms and reducing recurrences (EPOS2020)²
5. You could have added in the references, The European Position Paper on Rhinosinusitis and Nasal Polyps 2020² (the update of similar evidence-based position papers published in 2005 and 2007 and 2012): EPOS2020.

By no means do the remarks diminish the value of this work which, as the authors propose, should be complemented by a multicenter Tunisian study with greater follow-up in order to optimize diagnostic and therapeutic strategies.

References

1. Grayson J, Hopkins C, Mori E, Senior B, et al.: Contemporary Classification of Chronic Rhinosinusitis Beyond Polyps vs No Polyps. *JAMA Otolaryngology-Head & Neck Surgery*. 2020; **146** (9). [Publisher Full Text](#)
2. Fokkens WJ, Lund VJ, Hopkins C, Hellings PW, et al.: European Position Paper on Rhinosinusitis and Nasal Polyps 2020. *Rhinology*. 2020; **58** (Suppl S29): 1-464 [PubMed Abstract](#) | [Publisher Full Text](#)

Is the background of the cases' history and progression described in sufficient detail?

Yes

Are enough details provided of any physical examination and diagnostic tests, treatment given and outcomes?

Yes

Is sufficient discussion included of the importance of the findings and their relevance to future understanding of disease processes, diagnosis or treatment?

Yes

Is the conclusion balanced and justified on the basis of the findings?

Yes

Competing Interests: No competing interests were disclosed.

Reviewer Expertise: Rhinology, Otology, Balance diseases and vertigo, Sleep Apnea, Neck surgery

I confirm that I have read this submission and believe that I have an appropriate level of expertise to confirm that it is of an acceptable scientific standard.

Author Response 12 Jul 2022

Mohamed Masmoudi, Faculty of Medicine of Monastir, Mahdia, Tunisia

According to the recent classification of Chronic Rhinosinusitis (CRS), the fungal ball is a secondary CRS and is most often related to an endodontic history (more than 80% of cases). For the 4 fungal balls of the series, there is no information regarding the dental history, the specialized dental examination, the dentaScan. The treatment of dental causes should be combined with surgical treatment to reduce the risk of recurrence. "Contemporary Classification of Chronic Rhinosinusitis Beyond Polyps vs No Polyps: A Review"¹. Jessica W Grayson, Claire Hopkins, Eri Mori, Brent Senior, Richard J Harvey.

Author response: We specified that none of our patients had a history of dental infection or procedure. We added in the discussion part that they were all referred to a dentist for a specialized examination.

An inferior meatal window combined with the middle meatal antrostomy for the treatment of fungal balls would reduce the risk of leaving residual debris (EPOS2020)²

Author response: This was added to the discussion.

An MRI was requested in 4 patients: What were the clinical or radiologic criteria that motivated the request for an additional MRI? What were the radiological elements that the MRI had to specify?

Author response: We added in the method part the limitation we had since MRI is not available in our center. So it was only indicated for patients who could afford it for further specifications.

Concerning the cases of allergic fungal rhinosinusitis: a/ The determination of serum IgE level would be an additional element in the diagnosis. b/ Postoperative oral corticosteroid therapy over a period of 2 to 6 months (with close monitoring of side effects) demonstrated a net benefit on faster amendment of symptoms and reducing recurrences (EPOS2020)²

Author response: This information was added, the serum IgE level was not possible, since unavailable.

You could have added in the references, The European Position Paper on Rhinosinusitis and Nasal Polyps 2020² (the update of similar evidence-based position papers published in 2005

and 2007 and 2012): EPOS2020.

Author response: These references were added.

Thank you for your remarks that showed the special interest you paid to our manuscript and helped improve its quality.

Competing Interests: No competing interests were disclosed.

The benefits of publishing with F1000Research:

- Your article is published within days, with no editorial bias
- You can publish traditional articles, null/negative results, case reports, data notes and more
- The peer review process is transparent and collaborative
- Your article is indexed in PubMed after passing peer review
- Dedicated customer support at every stage

For pre-submission enquiries, contact research@f1000.com

F1000Research