

Two-stage Radiofrequency-assisted Lipoabdominoplasty

Michael J. Stein, MD*†
Spero Theodorou, MD*†
Christopher T. Chia, MD*†

Summary: Decades of lipoabdominoplasty safety, reliability, and efficacy have permitted more aggressive contouring of the abdominoplasty flap without increased risk for wound healing complications. However, the recent introduction of unrestricted liposuction of all vascular zones and high-definition liposculpting continue to challenge the vascularity of the abdominoplasty flap, particularly in high-risk patients. The present study reviews the authors' approach to abdominal lipodystrophy, and introduces a technique which maximizes fat extraction and skin excision while reducing risk of complication (two-stage radiofrequency-assisted liposuction and abdominoplasty). (*Plast Reconstr Surg Glob Open* 2022;10:e4212; doi: 10.1097/GOX.0000000000004212; Published online 25 April 2022.)

INTRODUCTION

A rapidly growing demand for minimally invasive abdominal contouring has paralleled broadening indications for traditional abdominoplasty. Surgeons therefore are facing an anatomically diverse patient population with unique requests with respect to scarring, recovery, and ancillary procedures. The changing landscape of abdominal contouring has added a multitude of new technological adjuncts to the surgeon's armamentarium to keep up with patient demand.

Abdominoplasty technique has evolved from traditional pannus excision to zone 3 lipoabdominoplasty,¹ and now, to large volume liposuction of all vascular territories, superficial dermal etching for anatomical definition,² and new elevation and plication techniques.³⁻⁴ Although these maneuvers each theoretically challenge the vascularity of the abdominoplasty flap and can potentially increase wound healing complications, their popularity continues to grow.

Radiofrequency (RF)-assisted devices have recently emerged as a promising adjunct to abdominal contouring, either in the form of bipolar RF (BodyTite; InMode, Lake Forest, Calif.) or fractional bipolar microneedling (Morpheus8, InMode).⁵ They have been particularly useful in addressing the so-called treatment gap⁶ patient, with skin redundancy not significant enough to warrant an abdominoplasty, but enough laxity that liposuction alone might exacerbate redundancy. The ability to effectively

improve abdominal skin contractility in these patients opened the door to many patients with abdominal lipodystrophy that would have otherwise never sought out a plastic surgeon in the first place, and, if they did, were commonly under or overtreated.

The role of radiofrequency-assisted liposuction (RFAL) in abdominoplasty is not well established, and potentially adds a third vascular insult to an already compromised abdominoplasty flap following liposuction. The objective of the present review is to demonstrate the role of RF-skin tightening in body contouring, and to introduce a modified technique we call two-stage radiofrequency-assisted lipoabdominoplasty (RALA), which we have found is effective in optimizing final contour and reducing complications in higher BMI patients.

RADIOFREQUENCY-ASSISTED SKIN TIGHTENING

RFAL delivers controlled energy to the skin and subcutaneous tissues to induce soft-tissue contraction following fat extraction. Heat-mediated fat liquefaction and thickening of the fibroseptal network contribute to skin rejuvenation and contraction.⁷⁻⁸ Volumetric analyses support contraction of the soft tissues as high as 31%, significantly higher than competing energy-assisted technologies,⁹ and with more skin retraction than suction-assisted liposuction alone.¹⁰

RFAL can be used safely and effectively in the office setting under local anesthesia. In appropriately selected patients, outcomes are comparable to RFAL under general anesthesia, albeit with faster recovery time, high patient satisfaction and decrease operational costs for the surgeon.¹¹⁻¹⁴

From the *Manhattan Eye, Ear and Throat Hospital, New York, N.Y.; and †Lenox Hill Hospital, New York, N.Y.

Received for publication October 9, 2021; accepted January 31, 2022.

Copyright © 2022 The Authors. Published by Wolters Kluwer Health, Inc. on behalf of The American Society of Plastic Surgeons. This is an open-access article distributed under the terms of the [Creative Commons Attribution-Non Commercial-No Derivatives License 4.0 \(CCBY-NC-ND\)](https://creativecommons.org/licenses/by-nc-nd/4.0/), where it is permissible to download and share the work provided it is properly cited. The work cannot be changed in any way or used commercially without permission from the journal.

DOI: 10.1097/GOX.0000000000004212

Disclosure: Drs. Theodorou and Chia are consultants for InMode. Dr. Stein has nothing to disclose.

Related Digital Media are available in the full-text version of the article on www.PRSGlobalOpen.com.

In our practice, patients presenting for body contouring are categorized based on the degree of lipodystrophy and skin redundancy. Group 1 patients are typically younger, more athletic, and have good skin quality with mild to moderate lipodystrophy. These patients benefit less from RFAL as their skin turgor and elasticity are of minimal concern. For these patients, we use power-assisted liposuction (Microaire, Charlottesville, Va.) with superficial high-definition etching to enhance muscular definition. Group 2 patients have decreased skin recoil/elasticity, mild/moderate skin redundancy and moderate adioposity. Most of these patients can be treated effectively and reliably with RFAL. We find that the combination of liposuction of the abdomen/ flanks and radiofrequency-assisted soft tissue contraction delivers a reliable aesthetic in most patients. In group 2 patients who have more significant skin excess or who have rectus diastasis, an abdominoplasty is performed after RFAL. Group 3 patients have a higher BMI, significant skin redundancy, and moderate/severe lipodystrophy. This patient population has a higher complication rate at baseline and requires a longer operative time due to the simultaneous large volume liposuction of the abdomen, flanks, and sometimes back, followed by full or extended abdominoplasty. As such, we find these patients are commonly undertreated, presumably due to surgeon concern for the long duration of surgery and risk of complication. To achieve an optimal trunk aesthetic, we have started to treat these patients in a staged fashion, with RFAL of the abdomen/flank/back, followed by traditional abdominoplasty 3 months later (Fig. 1A–D). (See table, Supplemental Digital Content 1, which shows lipodystrophy classification and authors' preferred treatment, <http://links.lww.com/PRSGO/B983>.)

OPERATIVE TECHNIQUE

Both stages of the RALA procedure are performed at an American Association for Accreditation of Ambulatory Facility (AAAASF)-accredited surgical facility. The first

Takeaways

Question: Can the safety and aesthetic outcomes of lipoabdominoplasty be improved by staging the procedure (liposuction and radiofrequency-assisted skin tightening in the first stage and abdominoplasty in the second stage)?

Findings: Two-stage radiofrequency-assisted lipoabdominoplasty (RALA) facilitates increased lipoaspirate volumes and enhanced advancement and draping of the abdominoplasty flap.

Meaning: Consider staging lipoabdominoplasty in patients with moderate to severe lipodystrophy and skin excess.

stage is performed awake under local anesthesia with the assistance of a technician. In the preoperative holding area 1 hour before surgery, patients take 10 mg diazepam, 5/325 mg hydrocodone/acetaminophen and 500 mg cephalexin. In the operating room, 1 ml solution of 1% lidocaine with 1:100,000 epinephrine and 0.84% sodium bicarbonate is injected around each of the five 5 mm access incisions using a 30-gauge needle. Tumescent solution (1000 mg lidocaine, 1.5 ml of 1:1000 epinephrine, 10 ml of 8.4% sodium bicarbonate, 1 L of Ringers Lactate) is infiltrated using either a 14-gauge Wells-Johnson cannula or the 4 mm Microaire liposuction cannula using a simultaneous separation and tumescence (SST) technique. Notably, the blunt tipped cannula is first passed through scarpas fascia to infiltrate the deep subcutaneous fat before moving to more richly innervated superficial and subdermal layers. Continual verbal feedback from the patient ensures adequacy of analgesia throughout the case.

Bipolar RF is then performed with power set at 40 W to target a skin surface temperature of 38–42°C. This is followed by power-assisted liposuction as extensive as the soft-tissue anatomy will allow, with the understanding that the resultant skin laxity will be addressed at the second stage.

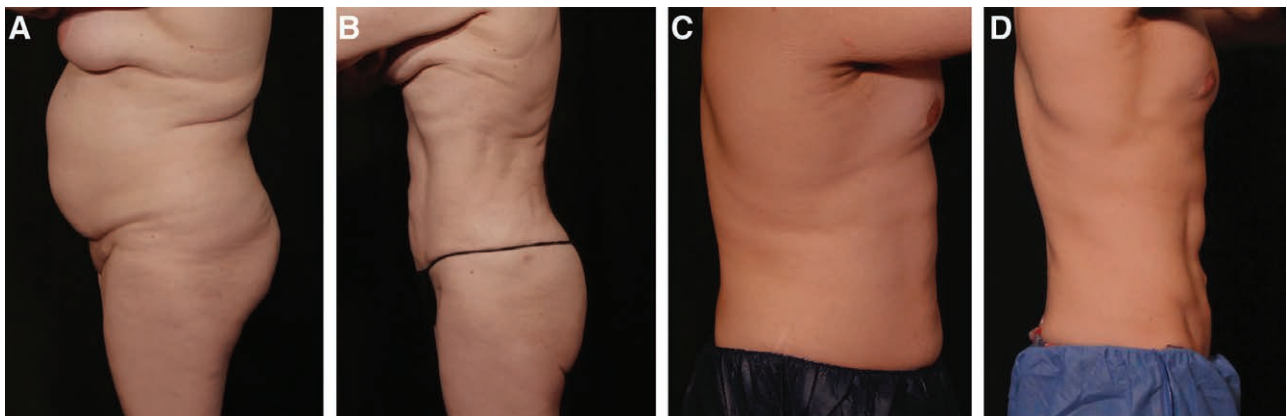


Fig. 1. Before and after photographs of group 3 and group 2 patients treated with RFAL. A and B, A 42-year-old woman (group 3 patient) with rectus diastasis, moderate-to-severe abdominal/flank/back adiposity, and skin excess. She was a good candidate for the RALA procedure. Before and after photographs are taken from the first stage of the procedure. A total of 3 L of fat was aspirated under local anesthesia from the abdomen, flank, and back. Radiofrequency-assisted skin tightening was performed. Abdominoplasty was performed under general anesthesia 3 months later. C and D, Before and after of 37-year-old man (group 2 patient) with moderate adiposity and skin excess who underwent single-stage radiofrequency-assisted liposuction and mini abdominoplasty under general anesthesia.

Lipoaspirate volumes vary depending on the patient's body habitus. The total operative time for the first stage of the RALA procedure ranges from 1 to 2 hours based on the amount of lipodystrophy.

Patients ambulate immediately after surgery and are discharged after a 1-hour observation period. Our office contacts every patient the evening of surgery and the morning after surgery to monitor for signs of lidocaine toxicity. Compression garments are worn for 4 weeks after surgery.

The second stage of the RALA procedures commences 3 months later at the same facility under general anesthetic and in the presence of an anesthesiologist. This is sufficient time for vascular delay of the abdominoplasty flap and is early enough that subcutaneous scarring due to collagen remodeling is not a significant impediment to flap mobilization. The abdominoplasty is then performed, using traditional maneuvers, albeit with wider undermining for improved redraping of the abdominoplasty flap. Rectus plication is performed with a #2 polydioxanone quill and excess tissue removed with body in a flexed position. Final closure is performed with absorbable layers approximating Scarpas fascia and dermis over two 15 mm JP drains. Surgical time for the second stage ranges from 1 to 2 hours. Postoperatively, the patient is monitored in the recovery room for 2 hours and then discharged home with close follow-up.

CONCLUSIONS

Patients with significant lipodystrophy and skin excess require a longer surgery and are at higher risk for complications. We find staging pannus excision from RFAL facilitates larger lipoaspirate volumes and skin resections. Notably, improved aesthetic outcomes are achieved at the benefit of both the patient and surgeon. From a patient perspective, decreasing operative times may lower the risk of thromboembolic event. The absence of tumescent infiltration during abdominoplasty also decreases the risk of volume overload and prolonged swelling, which can slow clinical recovery. From the surgeon's perspective, staging the operation decreases operator fatigue in refocusing on a large abdominoplasty after a long liposuction procedure. The larger lipoaspirate volumes lead to more skin redundancy, resulting in larger pannus resections and wider dissection for improved flap redraping. Although the overall skin redundancy increases, the RF-mediated fibroseptal network and dermal contraction improve the integrity of the abdominoplasty flap, which may lower wound healing complications during the abdominoplasty at the second stage. Last, staging reduces surgeon-perspective operating costs by reducing staffing requirements

(only the second stage is done under general anesthetic with regular operating room staff). Large cohort studies with long-term follow-up are now required to support our initial positive experiences with body contouring using the RALA procedure.

Christopher T. Chia, MD

Zucker School of Medicine

Hofstra University

128 Central Park South

New York, NY 10019

E-mail: christophertchia@yahoo.com

REFERENCES

1. Matarasso A. Traditional abdominoplasty. *Clin Plast Surg.* 2010;37:415–437.
2. Hoyos A. Commentary on: abdominal etching: past and present. *Aesthet Surg J.* 2019;39:1378–1379.
3. Babaitis R, Villegas FJ, Hoyos AE, et al. TULUA male high-definition abdominoplasty. *Plast Reconstr Surg.* 2022;149:96–104.
4. Villegas F. TULUA lipoabdominoplasty: no supraumbilical elevation combined with transverse infraumbilical plication, video description, and experience with 164 patients. *Aesthet Surg J.* 2021;41:577–594.
5. Dayan E, Burns AJ, Rohrich RJ, et al. The use of radiofrequency in aesthetic surgery. *Plast Reconstr Surg Glob Open.* 2020;8:e2861.
6. Theodorou SJ, Del Vecchio D, Chia CT. Soft tissue contraction in body contouring with radiofrequency-assisted liposuction: a treatment gap solution. *Aesthet Surg J.* 2018;38(suppl_2):S74–S83.
7. Chia CT, Neinstein RM, Theodorou SJ. Evidence-based medicine: liposuction. *Plast Reconstr Surg.* 2017;139:267e–274e.
8. Dayan E, Chia C, Burns AJ, et al. Adjustable depth fractional radiofrequency combined with bipolar radiofrequency: a minimally invasive combination treatment for skin laxity. *Aesthet Surg J.* 2019;39(suppl_3):S112–S119.
9. Paul M, Blugerman G, Kreindel M, et al. Three-dimensional radiofrequency tissue tightening: a proposed mechanism and applications for body contouring. *Aesthetic Plast Surg.* 2011;35:87–95.
10. Paul M, Mulholland RS. A new approach for adipose tissue treatment and body contouring using radiofrequency-assisted liposuction. *Aesthetic Plast Surg.* 2009;33:687–694.
11. Theodorou S, Chia C. Radiofrequency-assisted liposuction for arm contouring: technique under local anesthesia. *Plast Reconstr Surg Glob Open.* 2013;1:e37.
12. Dayan E, Rovatti P, Aston S, et al. Multimodal radiofrequency application for lower face and neck laxity. *Plast Reconstr Surg Glob Open.* 2020;8:e2862.
13. Theodorou SJ, Paresi RJ, Chia CT. Radiofrequency-assisted liposuction device for body contouring: 97 patients under local anesthesia. *Aesthetic Plast Surg.* 2012;36:767–779.
14. Chia CT, Marte JA, Ulvila DD, et al. Second generation radiofrequency body contouring device: safety and efficacy in 300 local anesthesia liposuction cases. *Plast Reconstr Surg Glob Open.* 2020;8:e3113.