



Ultrasonographic Assessment of the Cutaneous Changes Induced by Topical Use of Novel Peptides Comprising Laminin 5

Kyong Chan Park, MD¹ Se Young Kim, MD² Galina Khan, MD¹ Eun Soo Park, MD, PhD¹

¹Department of Plastic and Reconstructive Surgery and College of Medicine, Soonchunhyang University, Bucheon, Korea

²Department of Plastic and Reconstructive Surgery and College of Medicine, Soonchunhyang University, Gumi, Korea

Address for correspondence Eun Soo Park, MD, PhD, Department of Plastic and Reconstructive Surgery, Soonchunhyang University Bucheon Hospital, 1174, Jomaru-ro, Wonmi-gu, Bucheon-si, Gyeonggi-do 14584, South Korea (e-mail: peunsoo@schmc.ac.kr).

Arch Plast Surg 2022;49:304–309.

Abstract

Background Laminin 5, which is found in the basement membrane of dermal-epidermal junction (DEJ), is a major adhesive component and associated with proliferating and migrating keratinocytes. In this study, we hypothesized that the topical application of the skin care products containing the novel peptides might restore the DEJ structure by deriving deposition of laminin 5 and promoting the keratinocyte migration. Here, we evaluated the restoration of DEJ by measuring the skin thickness.

Methods Single-center retrospective analysis was performed on a total of 13 patients who underwent skin care using Baume L.C.E. (France, Laboratoires d'Anjou) between January and March 2021. All patients applied the skin care agent for 2 weeks only on their left hand dorsum. Before the initiation of the application and after 2 weeks, both their hands were evaluated on photography and ultrasound. And the patients were asked to rate their satisfaction with the questionnaire after 2 weeks.

Results There was no obvious improvement in photographic assessment and questionnaire. The post–pre difference of skin thickness in ultrasound images was, in left hand, 0.1 ± 0.37 in distal point and 0.1 ± 0.35 in proximal point; and, in right hand, 0 ± 0.17 in distal point and 0 ± 0.15 in proximal point, respectively. The pre–post difference was statistically significant in proximal point ($p = 0.035$).

Conclusion Topical application of novel peptide derivative comprising laminin 5 demonstrated cutaneous changes including skin thickness, as assessed by ultrasound. Further studies using other modalities including dermal density measurement, three-dimensional photography, optical coherence tomography, or skin biopsy would be helpful to determine the skin-improving effects.

Keywords

- ▶ basement membrane
- ▶ laminin
- ▶ ultrasound

DOI <https://doi.org/10.1055/s-0042-1748642>.
ISSN 2234-6163.

© 2022. The Korean Society of Plastic and Reconstructive Surgeons. All rights reserved.

This is an open access article published by Thieme under the terms of the Creative Commons Attribution-NonDerivative-NonCommercial-License, permitting copying and reproduction so long as the original work is given appropriate credit. Contents may not be used for commercial purposes, or adapted, remixed, transformed or built upon. (<https://creativecommons.org/licenses/by-nc-nd/4.0/>)

Thieme Medical Publishers, Inc., 333 Seventh Avenue, 18th Floor, New York, NY 10001, USA

Skin is the outermost tissue of the human body and consists of the epidermis and the dermis. The basement membrane (BM) at the dermal-epidermal junction (DEJ) separates the epidermal and dermal compartments of the skin and functions as a biochemical interface between the dermis and the epidermis. The epithelial BM consists of a complex network of extracellular matrix (ECM) molecules that tightly binds the epidermis to the dermis, provides resistance to shearing, controls exchange of molecules between epithelial and stromal compartments of the skin, and mediates the polarity of the epidermis, controlling cell organization and differentiation, as well as tissue repair and tumorigenesis.¹⁻³

Electron microscopy shows that the BM consists of three layers: the lamina lucida (electron-lucent), lamina densa (electron-dense), and lamina fibro-reticularis (electron-lucent). Lamina lucida is located directly beneath the plasma membranes of basal keratinocytes, and contains anchoring filaments linking keratinocyte hemidesmosome adhesion complexes to the lamina densa.^{4,5} The wavelike structure is created by both downward projections of epidermis (rete ridges) and upward projections of dermis (dermal papillae), which is a unique histological feature of the DEJ. With aging, the DEJ structure is usually observed with thinning and flattening changes, resulting in decreased mechanical stability and structural integrity.⁶ In addition to the structural changes, the BM proteins composing of DEJ decrease with, including collagen I, collagen IV, collagen VII, collagen XVII, nidogen, integrin 4, and laminin 332.^{7,8} Laminin 5, which is found in the BM of stratified and transitional epithelium, is associated with the extracellular anchoring filaments of the lamina lucida and is a specific substrate for adhesion in proliferating and migrating keratinocytes.^{9,10} Baume L.C.E. (France, Laboratories d' Anjou) is a skin care product containing peptides composed with following sequence: TALRIRATYGEY (SEQ ID No.1), which comprises the short arm of the laminin γ 2-chain. Previous study reported that the γ 2 short arm drives deposition of laminin 5 (laminin 332) into the ECM and sustains cell adhesions.⁹ And it was reported that the keratinocyte migration on plastic, fibronectin or collagen IV substrates requires endogenous laminin 5 deposition.¹¹ In this study, we hypothesized that the specific skin products might restore the DEJ structure by deriving deposition of laminin 5 and promoting the keratinocyte migration. Here, we evaluated the restoration of DEJ by measuring the skin thickness.

Methods

Patients and Data Extraction

We performed a single-center retrospective analysis on a total of 13 patients who underwent skin care using Baume L.C.E. (France, Laboratories d' Anjou) between January and March 2021. This retrospective study received approval from the Institutional Review Board of our Hospital (IRB No. 2021-06-001) and was performed in accordance with the principles of the Declaration of

Helsinki. We excluded the patients who had symptoms of local skin infection or a history of allergic reactions to other skin care agents or a history of aesthetic procedures on hand including filler injection. Patients without a follow-up period of at least 2 weeks were excluded. All outcome data including questionnaires, photographic findings, and ultrasound findings were reviewed before and after the application. This study conformed to the Declaration of Helsinki. Informed consents were obtained from all patients for the application and the publication of the results including photographs.

Application Protocol

All participants were asked to adhere to the same daily personal care routine during the 2 weeks. All patients applied the skin care agent (Baume L.C.E., France, Laboratories d' Anjou) everyday morning and afternoon for 2 weeks, only on their left hand dorsum from fingers to wrist. Before the application, their hands were washed off with soap and water. They were asked to refrain from using any personal care product during 2 weeks except a mild body wash. The patients were educated to avoid direct sunlight and recommended to lead a normal daily life. We educated the patients to visit hospital immediately when they had any adverse effect.

Assessment

Before the initiation of the application and after 2 weeks, both their hands were evaluated on photography and ultrasound. Photographic evaluations were performed using standardized photograph using wide-angled digital camera. The photographs were taken with both hands from the front. Ultrasound evaluations (iU22, Philips Healthcare) were performed with the L15-7io probe (7-15 MHz) at two spots on dorsal aspect of both hands by a single radiologist. The first spot is the distal point 3 cm proximal from third metacarpophalangeal joint. The second spot is the proximal point, the midpoint of dorsal wrist crease (**► Fig. 1**). One focal zone was set at the junction between dermis and hypodermis. The skin thickness was assessed on ultrasound finding by measuring

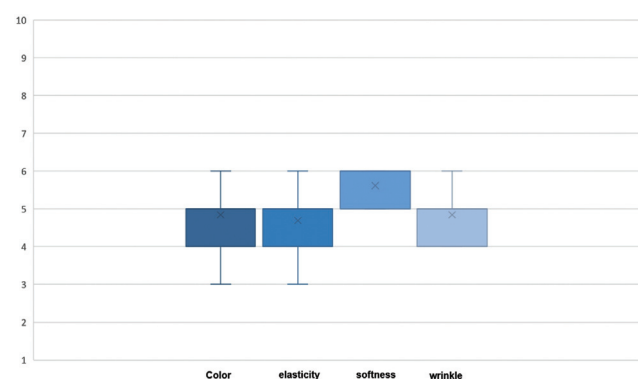


Fig. 1 Illustration of ultrasonographic evaluation points. Ultrasound evaluations were performed at two spots on dorsal aspect of both hands. The first spot is the distal point, which is 3 cm proximal from third metacarpophalangeal joint. The second spot is the proximal point, the midpoint of dorsal wrist crease.

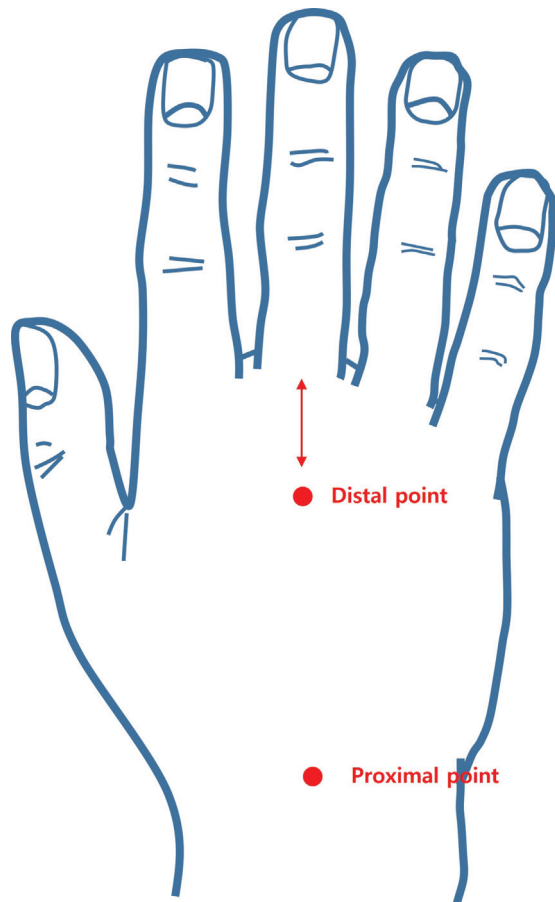


Fig. 2 Ultrasonographic evaluation. Case of a 72-year-old female patient: distal point of left hand (left) before the study, (right) 2 weeks after. The ultrasound image distinguished the skin layer; the epidermis, characterized by a hyper-echoic band; the dermis, visualized as a hypo-echoic band compared with the dermis; and the hypodermis, which showed the lowest reflecting capacity. Skin thickness was measured perpendicular from the skin surface to the junction between dermis and hypodermis (white bar). To reduce variability due to probe pressure, the probe was positioned ~ 1 cm medial or lateral side from the measurement point (white thick arrow).

the perpendicular distances, from the skin surface to dermal-hypodermal junction (\rightarrow Fig. 2). Thickness of the epidermis and dermis was calculated in millimeters (mm), digitally using Pixera software image analyzing system (Compix Inc.). Since the skin thickness of hand dorsum is thin, normally 2 mm, we established the following measurement principles to improve accuracy.¹² First, we placed the probe on the vertical axis between overlying skin and the third metacarpal bone or midpoint of wrist. To reduce variability due to probe pressure, the probe was positioned ~ 1 cm medial or lateral side from the measurement point.

The photographs and ultrasound findings were assessed for gross improvement and skin thickness, by two plastic surgeons, who were blinded for patient information.

At the end of the period of 2 weeks, the patients were asked to rate their satisfaction with their skin improvement, consisting of four parameters: color, elasticity, softness, and wrinkle (1 = worsened, 10 = improved).

Statistical Analysis

All analyses were performed with IBM Statistical Package for the Social Sciences (version 24.0; IBM Corp., Armonk, NY). The numeric variables were non-normally distributed, confirmed by normality test including the Kolmogorov-Smirnov test and the Shapiro-Wilk test. So, the comparison of skin thickness between left and right hands was performed using Wilcoxon signed-rank test. We consider p -values < 0.05 as an indication of statistical significance.

Results

A total of 13 patients applied the skin care products, and their ages ranged from 30 to 72 years (mean, 44 years). Twelve women (93%) and one man (3%) participated in this study. Since no one withdrew due to loss of follow-up or skin irritation, a total of 13 patients were enrolled. After 2 weeks, the skin improvement including improved elasticity and color or decreased wrinkle was not shown in photographic evaluation (\rightarrow Fig. 3).

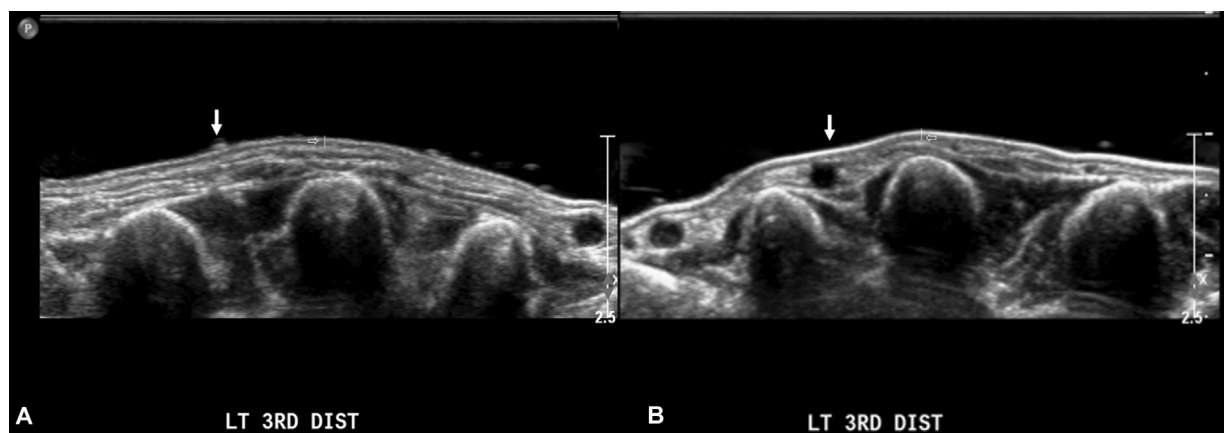


Fig. 3 Clinical photographs. Case of a 72-year-old female patient: (A) before the study, (B) 2 weeks after. After 2 weeks, there was no visible improvement in skin elasticity and color, or reduction in wrinkles.

Table 1 The post–pre differences of distance

Sex/Age, y	Left hand		Right hand	
	Distal point (mm)	Proximal point (mm)	Distal point (mm)	Proximal point (mm)
F/72	-0.3	0.5	-0.1	0.1
F/68	0.1	1.1	0.3	0.1
F/70	0.5	0	0	-0.1
F/69	0.3	0.2	-0.1	-0.2
F/68	0	-0.1	0	0
F/62	-1	-0.4	-0.1	-0.1
F/44	0.3	0.1	0.1	0
F/43	0.5	0.2	0	-0.1
F/30	0	-0.2	-0.4	-0.4
F/35	0.2	0	0.1	0
F/36	0.1	0	0.2	-0.1
M/34	0.2	0.3	0	0
F/30	-0.1	0.3	-0.2	0.3
^a Mean ± SD	0.1 ± 0.37	0.1 ± 0.35	0 ± 0.17	0 ± 0.15
	Distal point	Proximal point		
Wilcoxon signed-rank test	0.269	^b 0.035		

Abbreviations: F, female; SD, standard deviation; y, years.

Note: Post–pre difference: the difference of skin thickness after 2 weeks and before the study. *p*-Value of difference values determined using Wilcoxon signed-rank test.

^aData are presented as mean ± standard deviation.

^bSignificant at *p* < 0.05.

The post–pre difference of skin thickness in ultrasound images was, in left hand, 0.1 ± 0.37 (mean ± standard deviation) in distal point and 0.1 ± 0.35 in proximal point; and, in right hand, 0 ± 0.17 in distal point and 0 ± 0.15 in proximal point, respectively (► **Table 1**). The pre–post difference was statistically significant in proximal point (*p* = 0.035) using Wilcoxon signed-rank test.

The median of patient's satisfaction for skin improvement was 5 points (interquartile range [IQR]: 4–5) in color, elasticity, and wrinkle, and 6 points (IQR: 5–6) in softness (► **Fig. 4**).

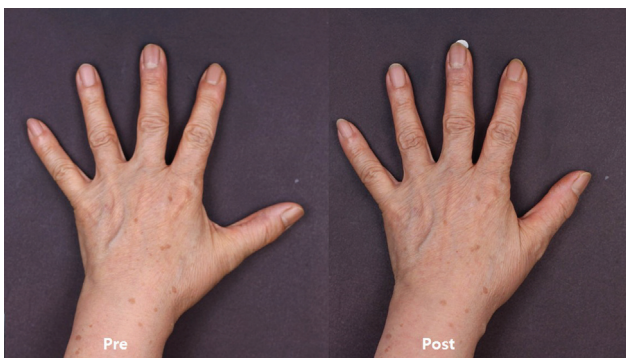

Fig. 4 Patient's assessment for improvement of skin. Patient satisfaction for skin improvement in color, elasticity, softness, and wrinkle using 10-point scale (1 = worsened, 10 = improved). The median of values was 5 (IQR: 4–5) in color, 5 (IQR: 4–5) in elasticity, 6 (IQR: 5–6) in softness, and 5 (IQR: 4–5) in wrinkle. IQR, interquartile range; x, mean.

Discussion

One of the most important roles of skin is to function as a protective barrier. To play this role, the DEJ contributes to the structural integrity of the skin. The structural component of DEJ is primarily composed of two polymeric networks formed of laminin and collagen IV, which are linked by nidogen and perlecan.^{13,14} Collagen IV and laminin are both trimeric proteins that are put together into independent networks. Whereas collagen IV contributes to tensile strength, laminin is considered the foundational unit for the initial formation of BM.¹⁵ Laminins, the most abundant glycoproteins in the BM, also play important roles in supporting the structure of tissues.¹⁶ By regulating cellular activities including adhesion, proliferation, migration, apoptosis, and differentiation, laminins are responsible for skin reepithelization and wound healing.¹⁷

Laminins, which are large glycoproteins, exist in various types, consisting of three chains: α , β , and γ . The functional domains on laminin chains allow the laminin to interact with molecules in the ECM. The functional domains in N-terminal region (or short arm) of the three chains are mainly responsible for matrix assembly.¹⁸ In the newly proposed terminology, laminin 1 ($\alpha 1\beta 1\gamma$) and laminin 5 ($\alpha 3\beta 3\gamma 2$) were named laminin 111 and laminin 332, respectively. However, this article uses the name of laminin 5, which has been used for a long time as laminin 332.¹⁹ Among the many laminin isoforms, laminin 5 is unique in both structure and activity

and is a major adhesive component of the BM.^{20,21} Various structural and biological changes accompany skin aging due to intrinsic and extrinsic factors, weakening the DEJ substructure and its functions. Most changes are associated with impairment of the mechanical properties of matrix cells, including decreased turnover or alteration of posttranslational modifications.²² In addition to the structural impairment, the reduction in laminin 5 in aged skin was previously reported.⁸ Based on the important roles of the DEJ, modulation of the proteins comprising the DEJ has been used for improving aging skin.

Recently, topical application of the novel peptides complex significantly increased dermal collagen expression, as well as expressions of laminin, resulting in improvement in the structural properties of the DEJ through its ability to stimulate BM proteins. As a result, significant improvement in skin wrinkles were observed after 2 weeks, as assessed by skin topographic measurements.²³

The use of high-frequency ultrasound above 10 MHz can assess the cutaneous microstructure (epidermis, dermis, subcutaneous tissue) and age-related echogenicity as well as dermal density, which are useful parameters for quantifying the skin regeneration process.²⁴ Ultrasound evaluation with probes of at least 20 MHz can identify the tumoral extension, inflammatory infiltrate, etc.²⁵ The cutaneous changes induced by topical prednisone therapy or antiaging natural supplement therapies were successfully assessed by ultrasonographic evaluation.²⁶

In this study, we tested the cutaneous changes suggestive of antiaging benefits induced by topical application of novel peptides comprising laminin 5, by measuring the skin thickness using ultrasound. Although practically difficult, a study using pathologic evaluation would be more precise to evaluate the skin-improving effects.

There was no obvious improvement in photographic assessment. And the patients did not perceive any improvement in their skin, as assessed by the questionnaire. However, it was found that there was a significant increase in skin thickness in proximal point as measured by the ultrasound. It is considered that the proximal point is more sensitive to measurement of skin thickness, due to its thick nature. And it is assumed that the period of 2 weeks was too short to reflect the skin improvement in photographs and questionnaire.

Although the limitation of this study is the small number of study subjects and the short period, there are many other studies that showed antiaging effects with similar subjects and study period.²⁷⁻³⁰ And, as mentioned above, the skin thickness was measured at a location away from the probe contact point to minimize the bias caused by the pressure of the probe.

To the best of our knowledge, no study has evaluated the skin-improving effect of peptides comprising laminin, using ultrasound. Further studies involving larger sample sizes and longer periods using high-frequency ultrasound are needed.³¹ Further studies using other modalities including dermal density measurement, three-dimensional photography, optical coherence tomography, or skin biopsy would be helpful to determine the skin-improving effects.

In this study, we hypothesized that the topical application of the skin care products containing the novel peptides might restore the DEJ structure by deriving deposition of laminin 5 and promoting the keratinocyte migration. And we found a significant increase in skin thickness, when assessed by ultrasound.

Author Contributions

Conceptualization: E.S.P. Data curation: S.Y.K. and G.K. Project administration: E.S.P. Visualization: K.S.P. Writing-original draft: K.C.P. Writing-review and editing: K.C.P.

Ethical Approval

The study was approved by the Institutional Review Board of Soonchunhyang University Bucheon Hospital (IRB No. 2021-06-001) and performed in accordance with the principles of the Declaration of Helsinki.

Patient Consent

The patients provided written informed consent for the publication and the use of their images.

Funding

This work was supported by the Soonchunhyang University Research Fund.

Conflict of Interest

None declared.

References

- Ryan MC, Christiano AM, Engvall E, et al. The functions of laminins: lessons from in vivo studies. *Matrix Biol* 1996;15(06): 369-381
- Ko MS, Marinkovich MP. Role of dermal-epidermal basement membrane zone in skin, cancer, and developmental disorders. *Dermatol Clin* 2010;28(01):1-16
- Breitkreutz D, Koxholt I, Thiemann K, Nischt R. Skin basement membrane: the foundation of epidermal integrity-BM functions and diverse roles of bridging molecules nidogen and perlecan. *BioMed Res Int* 2013;2013:179784
- Ghohestani RF, Li K, Rousselle P, Uitto J. Molecular organization of the cutaneous basement membrane zone. *Clin Dermatol* 2001;19(05):551-562
- Villone D, Fritsch A, Koch M, Bruckner-Tuderman L, Hansen U, Bruckner P. Supramolecular interactions in the dermo-epidermal junction zone: anchoring fibril-collagen VII tightly binds to banded collagen fibrils. *J Biol Chem* 2008;283(36):24506-24513
- Newton VL, Bradley RS, Seroul P, et al. Novel approaches to characterize age-related remodelling of the dermal-epidermal junction in 2D, 3D and in vivo. *Skin Res Technol* 2017;23(02): 131-148
- Mondon P, Hillion M, Peschard O, et al. Evaluation of dermal extracellular matrix and epidermal-dermal junction modifications using matrix-assisted laser desorption/ionization mass spectrometric imaging, in vivo reflectance confocal microscopy, echography, and histology: effect of age and peptide applications. *J Cosmet Dermatol* 2015;14(02):152-160
- Langton AK, Halai P, Griffiths CE, Sherratt MJ, Watson REB. The impact of intrinsic ageing on the protein composition of the dermal-epidermal junction. *Mech Ageing Dev* 2016;156:14-16
- Gagnoux-Palacios L, Allegra M, Spirito F, et al. The short arm of the laminin gamma2 chain plays a pivotal role in the incorporation of

- laminin 5 into the extracellular matrix and in cell adhesion. *J Cell Biol* 2001;153(04):835–850
- 10 Rousselle P, Aumailley M. Kalinin is more efficient than laminin in promoting adhesion of primary keratinocytes and some other epithelial cells and has a different requirement for integrin receptors. *J Cell Biol* 1994;125(01):205–214
 - 11 Decline F, Rousselle P. Keratinocyte migration requires alpha2-beta1 integrin-mediated interaction with the laminin 5 gamma2 chain. *J Cell Sci* 2001;114(Pt 4):811–823
 - 12 Oltulu P, Ince B, Kokbudak N, Findik S, Kilinc F. Measurement of epidermis, dermis, and total skin thicknesses from six different body regions with a new ethical histometric technique. *Turk J Plast Surg* 2018;26:56–61
 - 13 Yurchenco PD. Basement membranes: cell scaffoldings and signaling platforms. *Cold Spring Harb Perspect Biol* 2011;3(02):a004911
 - 14 Sekiguchi R, Yamada KM. Basement membranes in development and disease. *Curr Top Dev Biol* 2018;130:143–191
 - 15 McKee KK, Harrison D, Capizzi S, Yurchenco PD. Role of laminin terminal globular domains in basement membrane assembly. *J Biol Chem* 2007;282(29):21437–21447
 - 16 Ishihara J, Ishihara A, Fukunaga K, et al. Laminin heparin-binding peptides bind to several growth factors and enhance diabetic wound healing. *Nat Commun* 2018;9(01):2163
 - 17 Iorio V, Troughton LD, Hamill KJ. Laminins: roles and utility in wound repair. *Adv Wound Care (New Rochelle)* 2015;4(04):250–263
 - 18 Colognato H, Yurchenco PD. Form and function: the laminin family of heterotrimers. *Dev Dyn* 2000;218(02):213–234
 - 19 Aumailley M, Bruckner-Tuderman L, Carter WG, et al. A simplified laminin nomenclature. *Matrix Biol* 2005;24(05):326–332
 - 20 Rousselle P, Lunstrum GP, Keene DR, Burgeson RE. Kalinin: an epithelium-specific basement membrane adhesion molecule that is a component of anchoring filaments. *J Cell Biol* 1991;114(03):567–576
 - 21 Carter WG, Ryan MC, Gahr PJ. Epiligrin, a new cell adhesion ligand for integrin $\alpha 3 \beta 1$ in epithelial basement membranes. *Cell* 1991;65(04):599–610
 - 22 Roig-Rosello E, Rousselle P. The human epidermal basement membrane: a shaped and cell instructive platform that aging slowly alters. *Biomolecules* 2020;10(12):1607
 - 23 Jeong S, Yoon S, Kim S, et al. Anti-wrinkle benefits of peptides complex stimulating skin basement membrane proteins expression. *Int J Mol Sci* 2019;21(01):73
 - 24 Crisan D, Crisan M, Moldovan M, Lupsor M, Badea R. Ultrasonographic assessment of the cutaneous changes induced by topical flavonoid therapy. *Clin Cosmet Investig Dermatol* 2012;5:7–13
 - 25 Crisan D, Lupsor M, Boca A, Crisan M, Badea R. Ultrasonographic assessment of skin structure according to age. *Indian J Dermatol Venereol Leprol* 2012;78(04):519
 - 26 Béguin A. A novel micronutrient supplement in skin aging: a randomized placebo-controlled double-blind study. *J Cosmet Dermatol* 2005;4(04):277–284
 - 27 Watson RE, Long SP, Bowden JJ, Bastrilles JY, Barton SP, Griffiths CE. Repair of photoaged dermal matrix by topical application of a cosmetic 'antiageing' product. *Br J Dermatol* 2008;158(03):472–477
 - 28 dal Farra C, Oberto G, Berghi A, Domloge N. An anti-aging effect on the lips and skin observed in in vivo studies on a new fibronectin-like peptide. *J Am Acad Dermatol* 2007;56(2, Suppl2):AB88
 - 29 Barba C, Méndez S, Roddick-Lanzilotta A, Kelly R, Parra JL, Coderch L. Cosmetic effectiveness of topically applied hydrolysed keratin peptides and lipids derived from wool. *Skin Res Technol* 2008;14(02):243–248
 - 30 Barba C, Méndez S, Roddick-Lanzilotta A, Kelly R, Parra JL, Coderch L. Wool peptide derivatives for hand care. *J Cosmet Sci* 2007;58(02):99–107
 - 31 Van Mulder TJ, de Koeijer M, Theeten H, et al. High frequency ultrasound to assess skin thickness in healthy adults. *Vaccine* 2017;35(14):1810–1815