




ELSEVIER

Contents lists available at [ScienceDirect](https://www.sciencedirect.com)

## Trauma Case Reports

journal homepage: [www.elsevier.com/locate/tcr](http://www.elsevier.com/locate/tcr)

## Case Report

## Right atrial appendage rupture and cardiac tamponade secondary to blunt trauma

Cecil S. Johnny<sup>a,b,c,f,\*,\*\*</sup>, Mayank Vasudeva<sup>a,b</sup>, Julian Gooi<sup>d</sup>, Benedict Waldron<sup>e</sup>, Ee Jun Ban<sup>a,b,f,g</sup>, Nathan Durbridge<sup>c</sup>, Mark C. Fitzgerald<sup>a,b,f</sup><sup>a</sup> Alfred Trauma Service, Melbourne, Victoria, Australia<sup>b</sup> National Trauma Research Institute, Melbourne, Victoria, Australia<sup>c</sup> Emergency and Trauma Centre, The Alfred Hospital, Melbourne, Victoria, Australia<sup>d</sup> Department of Cardiothoracic Surgery, The Alfred Hospital, Melbourne, Victoria, Australia<sup>e</sup> Department of Anaesthetics & Perioperative Medicine, The Alfred Hospital, Melbourne, Victoria, Australia<sup>f</sup> Department of Surgery, Monash University, Melbourne, Victoria, Australia<sup>g</sup> Department of HPB Surgery, The Alfred Hospital, Melbourne, Victoria, Australia

## ARTICLE INFO

## Keywords:

Blunt chest trauma  
Pericardial tamponade  
Right atrial appendage  
FAST  
Thoracotomy

## ABSTRACT

**Background:** Right atrial appendage rupture from blunt trauma is exceedingly rare, even more so when no other chest wall injuries are found. Very few cases have been documented with respect to survival from such an injury.**Purpose:** To highlight the optimal management of such cases, namely through timely and safe transport to a trauma centre, maintaining a high degree of clinical suspicion for tamponade, early diagnostic ultrasound use, pericardial decompression, haemorrhage control and situational control.**Case presentation:** A case report delineating the diagnostic and therapeutic approach to an individual with right atrial appendage rupture. Subsequent post-operative and convalescent course till hospital discharge.

A young male patient involved in a high-speed motor vehicle accident was hypotensive at the scene with altered sensorium. Transport to a trauma centre was delayed due to entrapment and geographical location. An ultrasound done on arrival identified cardiac tamponade, which was successfully treated with an emergent left lateral thoracotomy, pericardial decompression, and haemorrhage control from a ruptured right atrial appendage, with definitive closure in the operating theatre.

**Conclusion:** Whilst rare, haemodynamic compromise in the absence of obvious thoracic trauma following high-energy, rapid deceleration mechanisms should raise suspicion for right atrial appendage rupture with pericardial tamponade. Aggressive resuscitation, early diagnostic ultrasound use and urgent pericardial decompression are essential in maximising the likelihood of positive outcomes.

\* Corresponding author at: Alfred Trauma Service and National Trauma Research Institute, The Alfred Hospital, Level 4, Burnet Building, 89 Commercial Road, Melbourne, Victoria 3181, Australia.

\*\* Corresponding author at: PO Box 315, Prahran, Victoria 3181, Australia.

E-mail address: [c.johnny@alfred.org.au](mailto:c.johnny@alfred.org.au) (C.S. Johnny).<https://doi.org/10.1016/j.tcr.2022.100620>

Accepted 17 February 2022

Available online 22 February 2022

2352-6440/© 2022 The Authors. Published by Elsevier Ltd. This is an open access article under the CC BY-NC-ND license

<http://creativecommons.org/licenses/by-nc-nd/4.0/>.

## Introduction

Blunt cardiac injury ranges from minor myocardial contusions to multi-chamber cardiac rupture. Cardiac chamber rupture is associated with a high mortality rate - mostly attributed to the resultant cardiac tamponade [1]. Successful management of acute cardiac tamponade requires a high degree of clinical suspicion with early diagnosis facilitated by ultrasonography linked to timely operative intervention [2,3].

Cardiac chamber rupture represents 0.041% of all trauma cases with an overall mortality rate of 89.2% [4] and is associated with high-impact mechanisms such as motor-vehicle crashes or falls from height. Patients often sustain concomitant thoracic wall injuries such as sternal and rib fractures [4].

Survival following an isolated rupture of the right atrial appendage (RAA) secondary to blunt truncal trauma with no other chest injury present is rare, with few reported cases in literature [1,2,4-7].

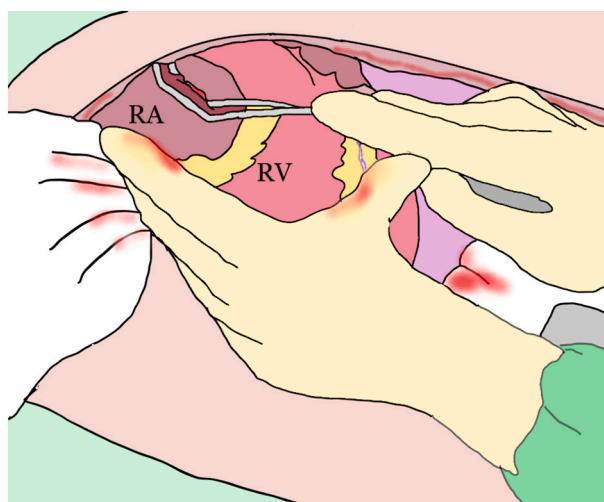
## Case

A 23-year-old male driving at 110 km/h on a highway crashed into stationary cars. The vehicle was then rear-ended by a truck. The initial systolic blood pressure was 80 mmHg and initial Glasgow Coma Scale 4/15 on arrival of paramedics. There was a prolonged extrication time of 50 min due to entrapment. Rapid sequence intubation was performed using intravenous Ketamine 80 mg and Rocuronium 50 mg. The patient was given two further doses of Rocuronium 50 mg each and ongoing sedation maintained with Fentanyl 70 µg/h and Midazolam 2 mg/h, en route to the hospital via rotary wing ambulance. A prehospital FAST (Focused Assessment with Sonography in Trauma) was reported as showing fluid in the right upper quadrant. The patient remained hypotensive throughout a 40-minute transfer to a Level 1 Trauma Centre, despite receiving four units of packed red cells. A noradrenaline (norepinephrine) infusion had been commenced prior to the intubation and had been titrated up to 30 µg/min prior to arrival at hospital. The total pre-hospital time was 120 min.

On Trauma Centre arrival, the heart rate was 150/min, blood pressure 80/50 mmHg, and oxygen saturation 100% (FiO<sub>2</sub> of 1.0). Primary examination revealed equal and sluggishly reactive pupils, and no external signs of a torso injury. There was a swollen, tense right leg which was suggestive of compartment syndrome. Bilateral finger thoracostomies were performed. An 8.5Fr Arrow™ rapid infusion catheter was inserted for ongoing blood product resuscitation and a radial arterial line was placed for invasive blood pressure monitoring. A chest X-ray performed on arrival appeared normal. A concurrently done FAST demonstrated pericardial fluid with evidence of tamponade, as well as fluid in Morrison's pouch. A left anterolateral resuscitative thoracotomy at 13 min post-arrival revealed a tense and distended pericardium. The tamponade was relieved following an antero-longitudinal pericardial incision. Further exploration identified bleeding originating from a ruptured RAA. Haemostasis was achieved by initially applying direct digital pressure and then a Satinsky tangential occlusion clamp. The urgency of the situation demanded immediate intervention and hence the normal procedure of saving images was missed. We have drawn a pictorial representation (Fig. 1) of the occlusion of the RAA rupture site, using a Satinsky clamp.

At 34 min post-arrival, the patient was transferred to the nearby operating room (OR) and underwent definitive repair by the Cardiothoracic Surgery unit. The atrial appendage wall was repaired using two 4-0 prolene pledgeted sutures with TISSEEL™ (Baxter Healthcare Corporation, Westlake Village, CA, USA) application over the suture line to ensure adequate haemostasis.

Right lower limb X-rays done on arrival revealed displaced mid-tibial and proximal fibular shaft fractures, which were subsequently managed with fasciotomy and external fixation of the underlying fractures. The patient remained haemodynamically stable in



**Fig. 1.** Intraoperative view after a left lateral thoracotomy and clamping of the ruptured RAA using a tangential Satinsky clamp.

the OR after which he was transferred for computed tomography scans.

CT confirmed a moderate amount of intraperitoneal fluid with suspicion for a Grade 1 splenic injury. The rest of the scans demonstrated no abnormality, apart from the changes consistent with the thoracotomy and the right leg fractures. A subsequent exploratory laparotomy revealed haemo-serous fluid in the abdomen with no evidence of solid organ or hollow viscous injury.

The patient was post-operatively transferred to the Intensive Care Unit and had an uneventful extubation the next day. A left sided intercostal catheter inserted in the OR had a delayed removal on the ninth post-operative day (POD) due to ongoing haemo-serous output.

Hospital stay was complicated by right lower lobe subsegmental pulmonary embolus, a right below-knee deep vein thrombosis (DVT) and a left arm DVT. The patient was subsequently started on therapeutic anticoagulation. After definitive fixation of the leg fractures and fasciotomy wound repair, hospital discharge occurred on day 20. At follow up three-months post discharge there were no reported issues.

## Discussion

"Few surgical emergencies present so great a diagnostic challenge or provide as great a therapeutic reward," wrote Driscoll in 1973, whilst discussing cardiac chamber rupture in blunt trauma. Whilst Beck's triad is present in only one third of trauma cases of pericardial tamponade [6], the bedside ultrasound has ameliorated previous diagnostic challenges [2,3]. Ultrasound sensitivity and specificity for pericardial effusion have been reported as 96% and 98% respectively when performed by emergency physicians [8].

Even in the absence of overt clinical signs of tamponade, pericardial free fluid coupled with the appropriate mechanism of injury raises suspicion for tamponade and/or chamber rupture [2].

A retrospective analysis by Teixeira et al. [4] of blunt cardiac trauma autopsy findings revealed that the right chambers were the most frequently injured cardiac structures (30% right atrium and 27% right ventricle). The left atrium and the left ventricle were injured in 17% and 19% of the cases, respectively [4].

It had been previously postulated that right sided ruptures have a lower mortality, presumably due to a contained tear in a low-pressure cavity, increasing the likelihood of surviving until surgical intervention [6]. However, more recent studies have indicated that a higher survival rate in right-sided injuries may be associated with a higher frequency of right sided injuries [4].

There are several proposed mechanisms of blunt cardiac chamber injury. One hypothesized process is direct compression of the heart between the sternum and thoracic vertebrae [5]. However, whilst the reported association of blunt cardiac rupture with sternal and rib fractures varies (between 26 and 96%) [4,6], this case highlights that blunt cardiac rupture may occur without associated sternal and rib fractures [6].

The RAA is the most common site of atrial rupture, and this observation is mainly attributed to its low intra-cavity pressure ( $-2$  to  $+2$  mmHg) and its relatively thin wall ( $0.53 \pm 0.33$  mm) compared to the right atrial wall ( $1.11 \pm 0.42$  mm) [7].

Alternative mechanistic processes include the 'water hammer effect' [9,10], when sudden compression of the abdomen and lower limbs causes a precipitous rise in the venous pressure transmitted directly to the atrium, leading to rupture. Another considered cause is shearing associated with rapid deceleration. The deceleration force usually causes a disruption of the veno-atrial junctions, due to the differential deceleration points of the relatively mobile heart and tethered veins posteriorly, resulting in distraction-avulsion injury [10]. The patient usually presents with cardiac tamponade if the pericardium is intact or may have pericardial tear (up to 30%) presenting with a haemothorax, mediastinal collection or more rarely cardiac herniation [1].

## Conclusion

Whilst rare, blunt isolated right atrial rupture with pericardial tamponade occurring without evidence of chest trauma should be considered in the hemodynamically compromised patient following high-energy, rapid deceleration. Aggressive resuscitation, early diagnostic ultrasound and pericardial decompression are keys to achieving an optimal outcome.

## Author's contributions

CJ and MV collated the patient case information, performed the literature review, and wrote the manuscript and prepared it for publication. MF revised the manuscript prior to submission. All authors read and approved the final manuscript.

## Ethics approval and consent to participate

Not applicable.

## Consent for publication

Written informed consent was obtained from the patient for publication of this case report.

## Availability of data and material

Data sharing is not applicable to this article as no datasets were generated or analysed during the current study.

## Funding

There was no funding for this paper.

## Declaration of competing interest

The authors declare that they have no competing interests.

## Acknowledgements

Not applicable.

## References

- [1] D. Baldwin, K.L. Chow, H. Mashbari, E. Omi, J.K. Lee, Case reports of atrial and pericardial rupture from blunt cardiac trauma, *J. Cardiothorac. Surg.* 13 (1) (2018) 71.
- [2] M. Fitzgerald, J. Spencer, F. Johnson, S. Marasco, C. Atkin, T. Kossmann, Definitive management of acute cardiac tamponade secondary to blunt trauma, *Emerg. Med. Australas.* 17 (5–6) (2005) 494–499.
- [3] M.C. Fitzgerald, M.S. Yong, K. Martin, A. Zimmet, S.F. Marasco, J. Mathew, et al., Emergency department resuscitative thoracotomy at an adult major trauma Centre: outcomes following a training programme with standardised indications, *Emerg. Med. Australas.* 32 (4) (2020) 657–662.
- [4] P.G. Teixeira, K. Inaba, D. Oncel, J. DuBose, L. Chan, P. Rhee, et al., Blunt cardiac rupture: a 5-year NTDB analysis, *J. Trauma* 67 (4) (2009) 788–791.
- [5] B.J. Leavitt, J.A. Meyer, J.R. Morton, D.E. Clark, W.E. Herbert, C.A. Hiebert, Survival following nonpenetrating traumatic rupture of cardiac chambers, *Ann. Thorac. Surg.* 44 (5) (1987) 532–535.
- [6] W.C. Pevec, A.O. Udekwo, A.B. Peitzman, Blunt rupture of the myocardium, *Ann. Thorac. Surg.* 48 (1) (1989) 139–142.
- [7] T. Maraqa, M.A.T. Mohamed, K.L. Wilson, V. Perinjelil, G.R. Sachwani-Daswani, L. Mercer, Isolated right atrial rupture from blunt trauma: a case report with systematic review of a lethal injury, *J. Cardiothorac. Surg.* 14 (1) (2019) 28.
- [8] D.P. Mandavia, R.J. Hoffner, K. Mahaney, S.O. Henderson, Bedside echocardiography by emergency physicians, *Ann. Emerg. Med.* 38 (4) (2001) 377–382.
- [9] E.F. Bright, C.S. Beck, Nonpenetrating wounds of the heart: a clinical and experimental study, *Am. Heart J.* 10 (3) (1935) 293–321.
- [10] T.D. Martin, T.C. Flynn, B.J. Rowlands, R.E. Ward, R.P. Fischer, Blunt cardiac rupture, *J. Trauma* 24 (4) (1984) 287–290.