



# Morton's interdigital neuroma: instructional review

Nikolaos Gougoulis<sup>1</sup>  
 Vasileios Lampridis<sup>1</sup>  
 Anthony Sakellariou<sup>1</sup>

- The terminology 'Morton's neuroma' may represent a simplification of the clinical condition as the problem may not be a benign tumour of the nerve, but neuropathic foot pain associated with the interdigital nerve.
- Foot and ankle pathomechanics leading to metatarsalgia, clinical examination and differential diagnosis of the condition and imaging of the condition, for differential diagnosis, are discussed.
- Nonoperative management is recommended initially. Physiotherapy, injections (local anaesthetic, steroid, alcohol), cryotherapy, radiofrequency ablation and shock-wave therapy are discussed.
- Operative treatment is indicated after nonoperative management has failed. Neuroma excision has been reported to have good to excellent results in 80% of patients, but gastrocnemius release and osteotomies should be considered so as to address concomitant problems.
- Key factors in the success of surgery are correct diagnosis with recognition of all elements of the problem and optimal surgical technique.

**Keywords:** interdigital nerve; metatarsalgia; Morton's neuroma

Cite this article: *EFORT Open Rev* 2019;4:14-24.  
 DOI: 10.1302/2058-5241.4.180025

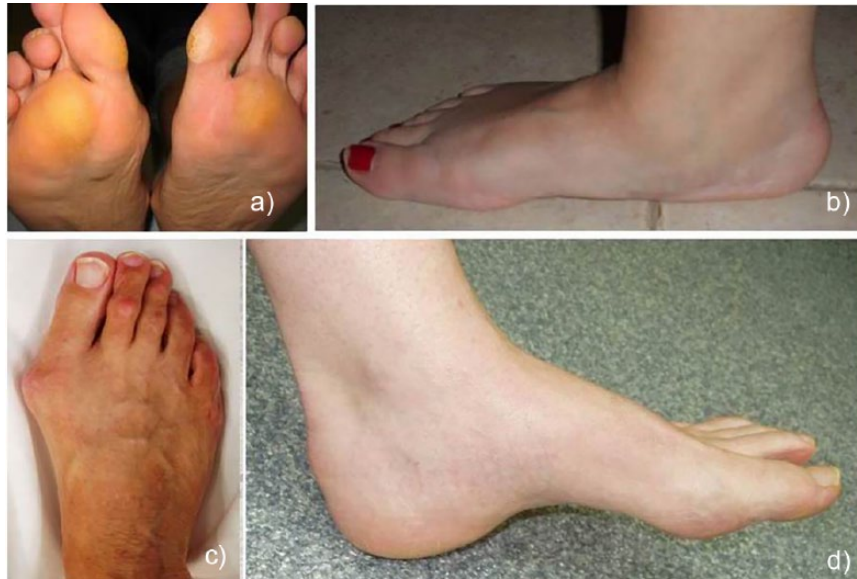## Morton's neuroma: what is it?

The term 'Morton's neuroma' is in itself controversial. Histological examinations have shown that the histopathological features of resected 'neuromata' are not any different than those of biopsies from second/third intermetatarsal space nerves in feet with no pain. Only the dimension/width of the neuroma is different in that they are larger than that of a normal nerve.<sup>1</sup> So does a 'neuroma' of the interdigital space really exist? It is important to mention that Morton himself described in 1876 a painful syndrome of the fourth metatarsophalangeal joint, rather than a nerve problem,<sup>2</sup> whereas others before him

had described a 'painful clinical syndrome of the forefoot'.<sup>3</sup> Thus, the widely used terminology of 'Morton's neuroma' may represent an over-simplification of the clinical condition and may be misleading for doctors and patients. It is important for doctors who deal with this condition to realize that the problem is not a benign tumour of the nerve (as the terminology would imply), but a neuropathic pain in the forefoot that is associated with the interdigital nerve (most commonly the one between the third and fourth metatarsal heads), and to educate their patients accordingly. Furthermore, we have to appreciate the functional and biomechanical issues that may underlie the problem and the potential associated deformities and anatomical variations that produce plantar forefoot pain (metatarsalgia). As we will describe in the following paragraphs, 'Morton's neuroma' is a painful forefoot syndrome, usually related to the third interdigital nerve, that is associated with overloading and altered pressure distribution in the foot because of deformity and/or calf muscle tightness.

## Foot and ankle pathomechanics leading to metatarsalgia

To understand why metatarsalgia occurs, one needs to have a basic understanding of foot and lower-leg biomechanics during stance and gait. The foot, in terms of architecture and function, is designed to act as a tripod. In a balanced foot, the heel, the first metatarsal head and the fifth metatarsal head are the three areas of major absorption of pressure when a foot is statically plantigrade on the ground. Thus, valgus or varus alignment will shift the pressure towards the lateral or medial sides of the foot, respectively (Fig. 1). In a similar fashion, equinus contraction, tight calf muscles or wearing high heeled shoes are conditions that reduce the pressure in the heel area and instead transfer pressure distally towards the metatarsal heads. If we also take the gait cycle into consideration and the three rockers of gait (heel strike, midstance phase and toe-off), we would realize that, dynamically, certain areas of the forefoot will become overloaded during mid-stance

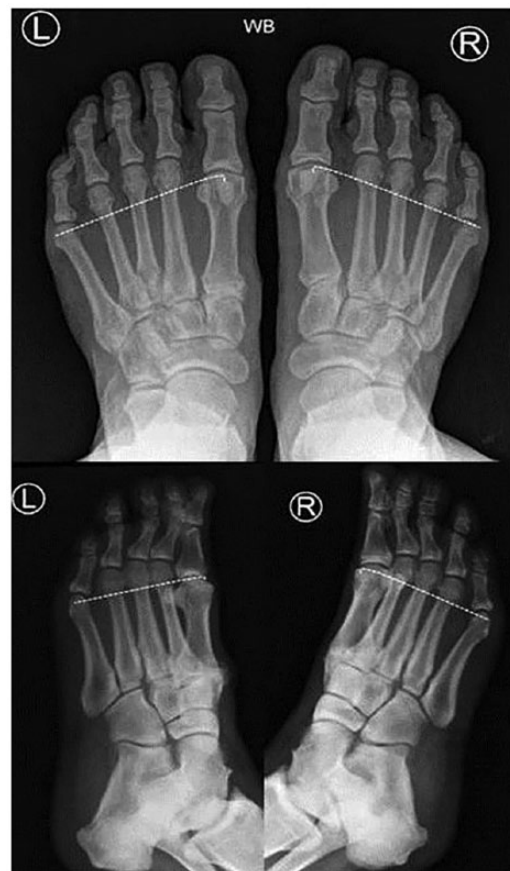

**Fig. 1** Pictures a–d are of different patients presenting with plantar forefoot pain associated with Morton's neuroma. Plantar skin callosities are evidence of forefoot overload (a). Planovalgus feet (b) and feet with hallux valgus deformities (c) result in first ray elevation and overload of the second and third rays, whereas cavus feet (d) are often associated with plantar prominence of the metatarsal heads.

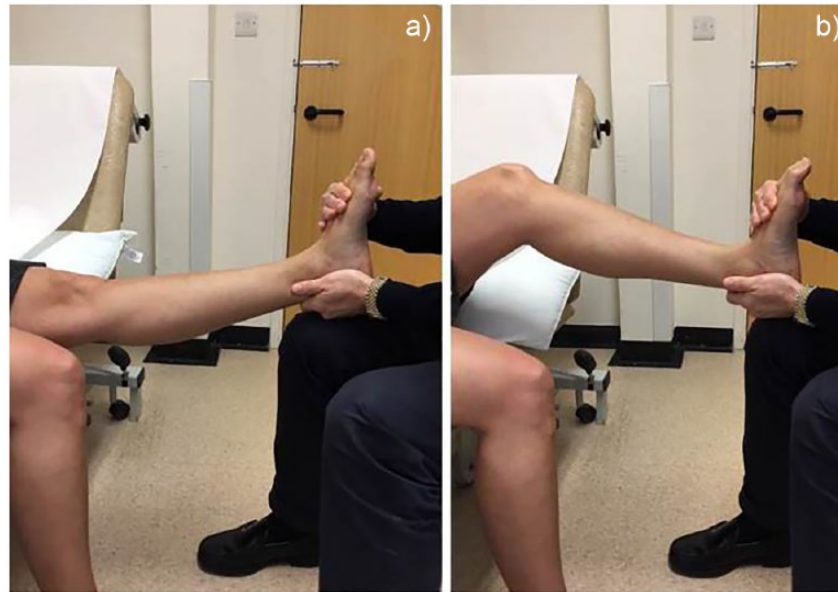
and toe-off. For example, in a planovalgus foot or even in a foot with an isolated hallux valgus deformity, forefoot hyperpronation and functional elevation of the first ray will lead to overloading of the lesser rays during mid-stance and toe-off. Similarly, when the calf muscles are tight, the so-called 'windlass mechanism' (that normally tightens and supinates the foot in order to progress from mid-stance to the toe-off phase of gait), is relatively dysfunctional. Thus, it leads to hyperpronation and metatarsalgia for the reasons mentioned previously. It is also important to say that calf muscle tightness very often accompanies deformity (valgus or varus). A high arched (cavus) foot, on the other hand, does not properly pronate during gait, leading to reduced loading of the first ray, whereas, at the same time, the lesser rays become overloaded and these patients then often present with callosities on the plantar aspect of the metatarsal heads.

Another type of deformity, less often recognized, is the one associated with long second and third metatarsals. When these are longer than the first metatarsal (even in the absence of hallux valgus deformity sometimes), they make contact with the ground early (and are, therefore, overloaded) during gait and that shifts pressure distribution towards the lesser rays (Fig. 2).

An anatomical feature of the foot that should also be considered is that the third intermetatarsal space is the junction between the medial and lateral columns of the foot. The first, second and third metatarsals and the adjacent midfoot joints are relatively stiff and significantly inclined in relation to the ground, whereas the fourth and fifth are more flexible and their axes are more parallel to



**Fig. 2** The dotted lines represent the 'normal forefoot cascade'. The longer second, third, and fourth metatarsals result in overload.



**Fig. 3** When the knee is extended the ankle cannot be passively dorsiflexed to 90 degrees. This is a sign of tight calf muscles. Knee flexion results in release of the tension of gastrocnemius, allowing ankle dorsiflexion beyond neutral. If the ankle cannot be dorsiflexed despite knee flexion, then the tightness affects the gastrosoleus complex and/or the Achilles tendon and not just the gastrocnemius (Silfverskiold test).

the ground. As such, the junction between the two columns may represent an area of increased relative motion, leading to the potential for ‘irritation’ of the interdigital nerve in this intermetatarsal space even in the absence of obvious deformity.

Many foot and ankle specialists therefore advocate that there are likely different biomechanical causes for neuromata affecting the third versus the second web space, respectively. Many believe that third interdigital neuroma pain may be a ‘true neuroma’, whereas second interdigital nerve-related pain may have a different underlying cause and possibly requires a different management approach. This has not, however, been scientifically proven.

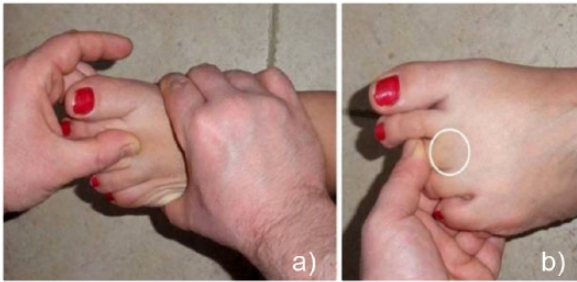
### Clinical presentation and differential diagnosis

It is of particular importance that the doctor has sufficient training and experience in assessing patients with foot problems, and that he/she spends adequate time listening to the patient reveal the history of the problem and the character of pain and, of course, thoroughly examining the foot and the lower leg. The diagnosis of pain related to Morton’s interdigital neuroma is not always straightforward and simple, and often other pathologies co-exist.

The patient (usually female in their late 40s or early 50s) presents with pain usually on the plantar aspect of the forefoot. Many of the patients are quite active, and activities such as running and dancing can be associated with the diagnosis of Morton’s neuroma. Frequently

patients give a description of ‘walking on a piece of stone or pebble’ and sometimes they describe ‘pins and needles’ and/or numbness in the toes, or sharp, burning, neuropathic pain radiating proximally towards their leg and back. Less often they may present complaining of cramping in their toes or pain on the lateral edge of their foot. Most patients are worse with closed shoes, but tolerate sandals or slippers, whereas others will say that they cannot walk when barefoot. High heeled or narrow shoes usually aggravate the problem. Usually the pain is sharp and often excruciating according to patients’ descriptions, whereas sometimes they may describe it as dull and diffuse across the midfoot. The patient should also be asked whether the pain is activity-related and predictable (e.g. associated with certain activities or footwear), or whether it is felt at night.

Clinical examination starts with observation of the foot and lower leg, asking the patient to expose both her/his legs below the knee. The plantar aspect of the foot should be also examined (e.g. for hard skin, callosities), as well as the patient’s shoes for increased ‘wear and tear’ in certain parts of the shoe soles. It is useful to ask the patient to point to the spot or area where they feel the pain. One should then assess the neurovascular status of the foot by palpating the dorsalis pedis and tibial artery pulses, and assessing sensation in the foot and ankle region. Performing the Silfverskioldt test<sup>4</sup> is an essential part of the examination to assess for gastrocnemius muscle tightness (Fig. 3), as it can contribute to forefoot pain, as discussed earlier.



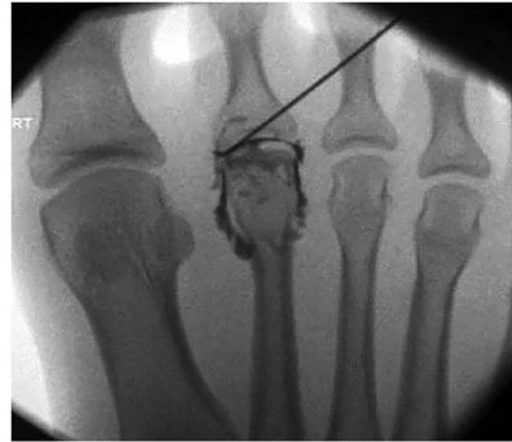**Fig. 4** Web-space tenderness, aggravated by squeezing the foot (a) is usually positive in patients with Morton's neuroma. Dorsal pain at the level of the metatarsophalangeal joint (white circle, b) when passively plantarflexing the toe is a sign of metatarsophalangeal joint synovitis.

Although clinical examination should focus on the forefoot, one should, at least briefly, examine the hindfoot and the midfoot for deformity, tendon pathology (e.g. Achilles, tibialis posterior, peroneals), and joint-related pain and mobility, as any of these conditions may affect biomechanics and, consequently, the pressure distribution in the forefoot. Plantar heel pain and tenderness at the plantar fascia calcaneal origin are clinical features that can indicate a pathological windlass mechanism which is often associated with tightness of the foot intrinsics and forefoot pain. Furthermore, midfoot tenderness due to degeneration at the level of the tarsometatarsal joints may cause referred pain towards the forefoot, or may be an additional pathology in patients with long second and third metatarsals who also present with forefoot pain.

Hallux valgus, hallux rigidus, or previous first ray surgery (e.g. Keller's procedure, or other 'old-fashioned' osteotomies that cause excessive shortening, failed forefoot surgery), are factors that can result in shortening or elevation and secondary de-functioning of the first ray, thus causing transfer load metatarsalgia and pain in the lesser rays of the forefoot.

Special attention should obviously be paid to detecting the exact area of tenderness in the forefoot, in order to distinguish, if possible, between pain and tenderness arising from the metatarsophalangeal (MTP) joints and pain arising from the intermetatarsal space (Fig. 4 and Fig. 5). Often it can be difficult to accurately discriminate between MTP joint and intermetatarsal space tenderness. Pain and tenderness on the dorsum of the MTP joints may indicate the presence of synovitis, capsulitis, and/or subluxation of joints. Pain more proximally could be the result of metatarsal stress fracture (although this is usually associated with subtle swelling as well), and pain/tenderness on the plantar aspect may be the result of plantar prominent metatarsal heads and plantar plate degeneration or rupture.

To specifically detect a potential Morton's neuroma one has to perform the following clinical tests:



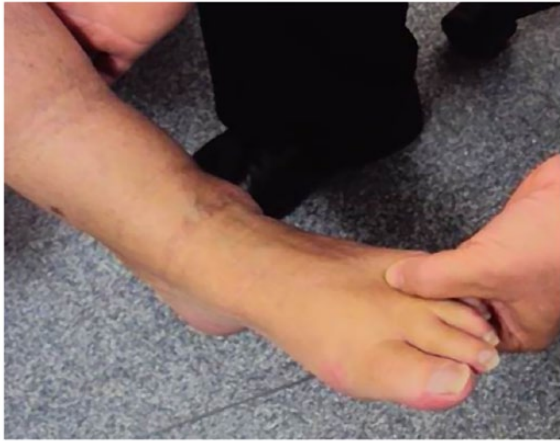**Fig. 5** When metatarsophalangeal-joint related pain is suspected, an image-guided injection (demonstrating an arthrogram) can aid differential diagnosis.

- Web-space tenderness test (Fig. 6).
- Squeeze test. While palpating the web space, the examiner compresses the forefoot with his/her other hand (Fig. 4). This can produce a painful, palpable 'click' (Mulder's click – only considered true if a painful click).
- Plantar percussion test (Fig. 7).
- Toe-tip numbness. The opposing surfaces of the adjacent toes are examined for reduced sensation.

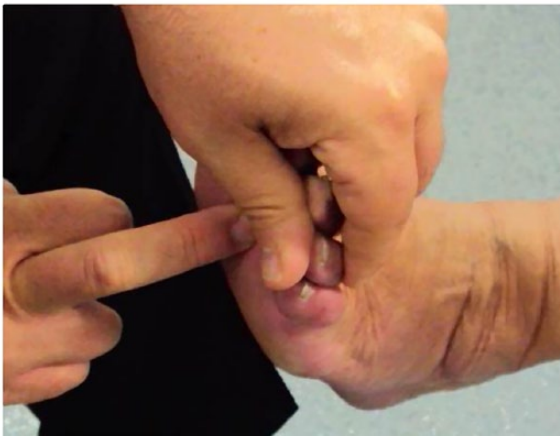In a previous retrospective study it was shown that in patients with a confirmed Morton's neuroma after surgery, the web-space tenderness and squeeze tests were positive in more than 92% according to the records of the preoperative clinical examination.<sup>5</sup>

The lesser toes should also be carefully inspected. Sometimes one can clearly see widening of the affected web space (possibly due to space occupying perineural fibrosis or intermetatarsal/perineural bursitis), and the patient will have very often noticed this gradually developing, in association with symptoms becoming apparent. Lesser toe deformities (e.g. clawed, or hammer toes) are often the result of chronic degeneration and rupture of the plantar plate and are indicative of forefoot overload.

In conclusion, a patient's description of activity-related, sharp, burning pain with or without paraesthesiae, and the feeling of 'walking on a piece of stone', together with positive web-space tenderness and forefoot squeeze tests, is highly indicative of the diagnosis of Morton's interdigital neuroma. The differential diagnosis includes any pathological condition that can cause metatarsalgia and sometimes more than one pathology can co-exist. Thorough examination of the lower leg, including examination of alignment and muscle tightness, is essential in order to identify the biomechanical factors that may underlie the problem.



**Fig. 6** The examiner pushes with the side of his/her thumb deep into the intermetatarsal space.



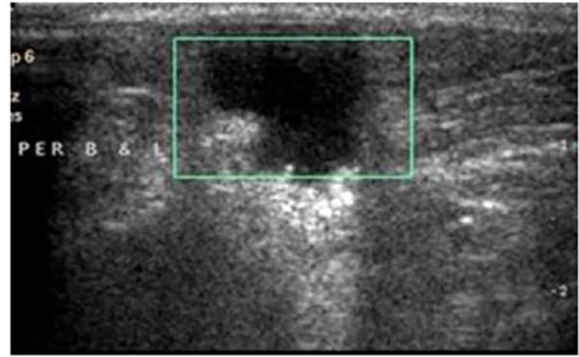
**Fig. 7** Positive Tinel sign on percussion of the plantar intermetatarsal space can be a sign of Morton's neuroma.

## Imaging

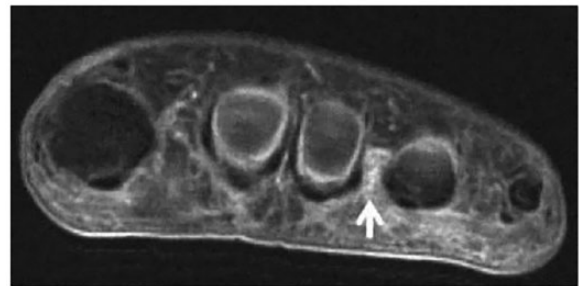
The diagnosis of Morton's neuroma is based on clinical examination findings. Imaging studies can, however, contribute to confirmation of the clinical diagnosis, as well as size and site of the neuroma and to exclude other causes of pain, depending on the differential diagnosis.

Plain – weight-bearing – foot radiographs are essential in patients with suspected Morton's neuroma in order to assess the relative length of the metatarsals ('forefoot cascade') (Fig. 2) for reasons mentioned previously. At the same time one can detect or exclude stress fractures, degenerative changes, subluxation of the MTP joints etc.

Ultrasound scan (Fig. 8), in the hands of an experienced operator, is an excellent, dynamic and inexpensive diagnostic modality for Morton's neuroma. The diagnostic process can be combined with a guided injection around



**Fig. 8** The hypoechoic area within the green margins represents a Morton's neuroma.



**Fig. 9** Morton's neuroma of the third interdigital space (white arrow) shown on MRI.

the neuroma, the outcome of which can contribute to the diagnosis and can also often be therapeutic. An MRI scan (Fig. 9) can be highly sensitive and specific in diagnosing Morton's neuroma. However, it is more expensive than ultrasound.<sup>6</sup> It is probably superior if the patient does not have typical symptoms and other conditions are suspected, or if no musculoskeletal ultrasound expertise is available.

## Nonoperative management

Once the diagnosis of Morton's neuroma is established, nonoperative management is recommended initially. This may include physiotherapy (intrinsic and gastrocnemius muscle stretching), modification of activities, use of appropriate (wide-fitting) footwear, injections (local anaesthetic, steroid, alcohol), cryotherapy, radiofrequency ablation, shockwave therapy.

Corticosteroid combined with local anaesthetic injections are probably the most widely used interventional nonoperative treatment modality. Half of the patients may require surgery within two years and young age and neuroma size have been shown to be predictive factors.<sup>7</sup> The use of ultrasound guidance does not seem to increase the success rate of the injection, compared to injections

performed without guidance by an orthopaedic foot and ankle specialist.<sup>8</sup> One randomized trial has shown that at three and six months, local anaesthetic injections were as efficient for pain and function improvement as cases where corticosteroid was used in addition,<sup>9</sup> whereas another randomized trial had shown that injections containing corticosteroid were superior at three months.<sup>10</sup>

Alcohol injections have only been shown to be effective in 30% of patients after five years, and can be associated with significant morbidity.<sup>11</sup> One study has shown a treatment response of up to 60%, but mainly in patients under 55 years old.<sup>12</sup> A more recent study showed improvement in more than 80% of cases, but only when considering this as reduction of pain by more than 50% using a numeric rating scale, and the authors concluded that other forefoot pathology should carefully be considered.<sup>13</sup>

Ultrasound-guided radiofrequency ablation is a novel treatment modality and short-term success rates of 80–85% have been reported.<sup>14,15</sup> Similarly cryoneurolysis has been shown to be effective in 15 out of 20 patients in the short term,<sup>16</sup> whereas shockwave therapy has also been used for the management of Morton's neuroma with positive results, compared to a placebo control group.<sup>17</sup>

There is some evidence too, that high-dose Vitamin B6 and B1 can reduce nerve symptoms.<sup>18</sup>

## Operative management: techniques and outcomes

Operative treatment is indicated if nonoperative management has failed to adequately control the patient's symptoms. Key issues to the success of surgery are the correct diagnosis and, of course, optimal surgical technique. As stated earlier, metatarsalgia associated with Morton's interdigital neuroma is usually part of a spectrum of biomechanical factors that can co-exist and result in forefoot overload (e.g. tight gastrocnemius, hindfoot malalignment, long lesser metatarsals, synovitis or subluxation/instability of MTP joints). Therefore, unsuccessful outcome of surgery may, sometimes, be related to the fact that not all elements of the problem have been addressed.

Several studies have shown good to excellent results in 70–80% of patients after neurectomy.<sup>19–21</sup> Interestingly, and quite consistently, only about half of the patients report no pain after surgery, whereas approximately 30% are better than preoperatively but with residual pain, and one in ten is worse than before the surgery.<sup>19–21</sup> One study showed similar results between neurectomy and neurectomy combined with intramuscular implantation of the nerve stump.<sup>22</sup> The procedure can be performed either through a dorsal or plantar approach, depending on the surgeon's training and preference. No difference in

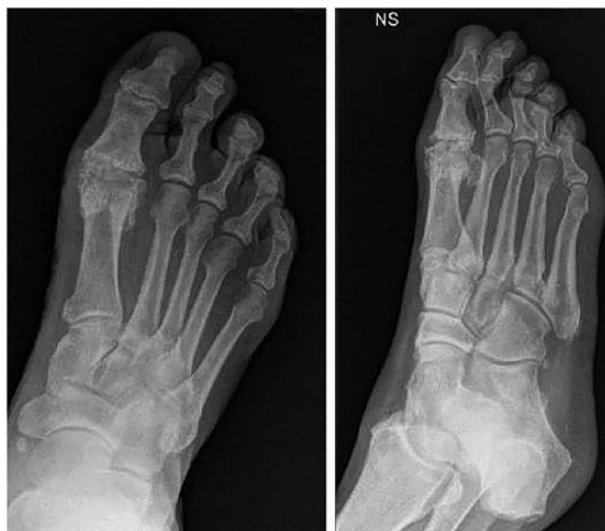outcomes has been demonstrated that is related to the surgical approach, although earlier post-op weight-bearing and patient preference favour a dorsal approach.<sup>23</sup> One study compared distal intermetatarsal ligament release with metatarsal shortening osteotomy and found the latter procedure to be more successful.<sup>24</sup> Other authors reported that almost all patients they treated with either open neurectomy or with percutaneous distal metatarsal osteotomies and deep transverse intermetatarsal ligament release were pain-free after two years, and outcomes of the percutaneous procedure were better than those of neurectomy.<sup>25</sup>

Ongoing pain after neuroma excision is a challenging situation. Revision surgery can be complicated<sup>26,27</sup> and patient outcomes can be even worse compared to those after the primary exploration and neurectomy.<sup>21</sup> The term 'recurrent neuroma' is probably misleading. The ongoing pain may be a result of nerve stump irritation (e.g. by scar tissue), or incomplete neuroma resection. Interestingly, most studies seem to focus solely on the interdigital nerve, and do not mention the status of the foot alignment, muscle tightness or anatomical factors (e.g. long metatarsals). It has been, logically, proposed that repeat web-space exploration is justified if the patient responds to a local anaesthetic injection.<sup>25</sup> However, as with primary surgery, one has to also consider (and address) the biomechanical factors that can maintain forefoot overload and other pathologies that can cause metatarsalgia (Fig. 10 and Fig. 11).

In this section we will describe surgical procedures that can be undertaken in patients with Morton's neuroma à la carte, depending on the clinical examination and imaging findings. Often, comorbidities, recovery time and a patient's ability to comply with postoperative instructions may influence decisions regarding the type of surgery to be performed. Nevertheless, the pros and cons should be discussed preoperatively with the patients and their expectations should be managed accordingly. Given that the failure rate of surgery is relatively high, informed consent should be obtained after explaining the nature of the problem and the realistic prospects of success.

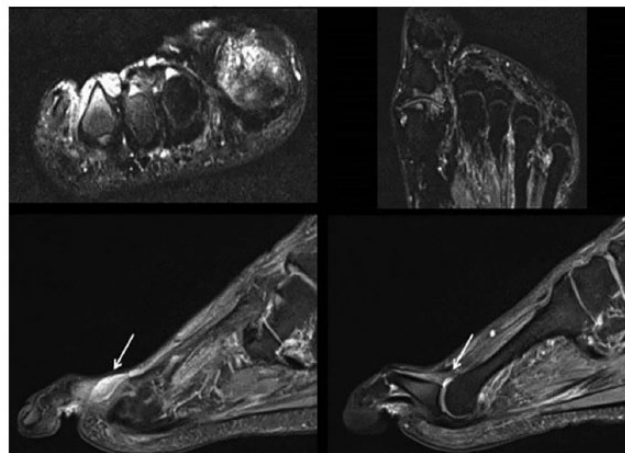
### *Proximal posteromedial gastrocnemius muscle release (PMGR)*

Reduced ankle dorsiflexion, due to isolated gastrocnemius muscle tightness, has been shown to be more common in patients with forefoot pathology presenting with metatarsalgia than in asymptomatic controls.<sup>28,29</sup> Gastrocnemius muscle tightness can be detected by performing the Silverskiold test.<sup>4</sup> If the patient's gastrocnemius muscle remains tight, even after several months of nonoperative management that includes physiotherapy and eccentric stretching, a PMGR can be performed,<sup>30</sup> sometimes simultaneously with Morton's neuroma excision. This largely



**Fig. 10** A 68-year-old male patient is dissatisfied after ‘failed’ surgery to excise a third-web-space Morton’s neuroma at another hospital. He still has forefoot pain. On examination he has diffuse, poorly localized pain across the forefoot, a stiff and painful hallux metatarsophalangeal joint and significant gastrocnemius tightness. He has had an ultrasound showing a ‘probable nerve stump neuroma’, whereas a guided injection offered no pain relief. He has never had foot radiographs before. Radiographs show the advanced degenerative changes in the hallux metatarsophalangeal joint, and clawing of the second toe.

depends on the intensity of neuropathic pain arising from the interdigital nerve and whether the patient had a positive response to a previous web-space steroid injection. In such cases neurectomy can result in resolution of the neuropathic pain, and PMGR can reduce forefoot overload and prevent ongoing metatarsalgia and even nerve stump neuroma irritation. Also, if the patient presents with two neuromata (e.g. of the second and third interdigital spaces) and also has diffuse forefoot pain, it may be worth avoiding a forefoot procedure and only performing a PMGR. Options have to be discussed with the patient who should have an understanding of the operative plan. In the senior authors’ experience PMGR has been shown to be beneficial in patients with symptomatic Morton’s neuromata and tight gastrocnemius that have not responded to nonoperative treatment. In a single surgeon’s series at our institution, 126 consecutive patients underwent surgery for Morton’s neuroma from 2009–2016. PMGR was performed simultaneously with neurectomy in five patients, whilst in another three patients it had to be performed at a later stage (after the neurectomy was performed) due to ongoing forefoot overload and diffuse metatarsalgia, although the neuropathic sharp pain had resolved with the neurectomy. Thus, a total of 8 out of 126 patients (6.3%) underwent PMGR in addition to neurectomy, and forefoot pain resolved in all patients. Further



**Fig. 11** The MRI scan of the patient’s foot discussed in Figure 10 revealed intermetatarsal bursitis (white arrow, left), synovitis (white arrow, right) and no nerve stump neuroma.

clinical research is required to confirm to what extent the procedure could improve symptoms in patients with Morton’s neuroma and gastrocnemius muscle tightness.

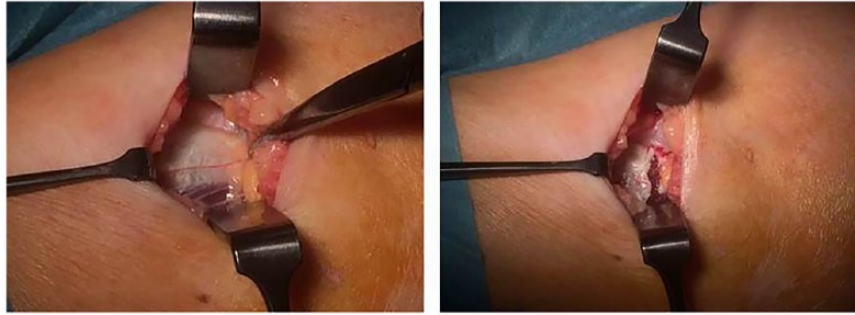
It is also worth mentioning that PMGR alone may reduce the effects of hindfoot alignment on forefoot pressure distribution, where a major procedure to an asymptomatic hindfoot (e.g. calcaneal osteotomy or tendon reconstruction) may not be justified.

PMGR is performed as a day case procedure under general or local anaesthesia and sedation. Use of tourniquet is not essential. The patient is positioned in a recovery position on the operated side,<sup>31</sup> or prone. A horizontal incision 1 inch distal to the posterior knee crease is made, overlying the proximal part of the medial gastrocnemius muscle belly (Fig. 12). The muscle aponeurosis is incised, avoiding iatrogenic injury to the hamstrings insertion on the medial side of the proximal tibia. One should also avoid lateral dissection (the lateral gastrocnemius head does not require release), so as to avoid damaging the common peroneal nerve.

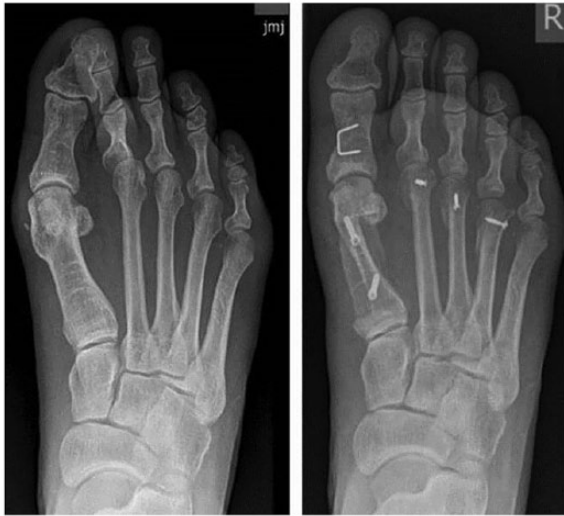In contrast to a Strayer’s procedure, PMGR does not require cast immobilization and is not associated with noticeably reduced calf strength. Immediate weight bearing as tolerated is allowed as is gradual return to ordinary activities. Stretching exercises should be initiated once the wound has healed, whereas high-impact activities are best avoided for six weeks. Patients’ individual thrombosis risk assessment is recommended, and high-risk patients may need to be given chemical thromboprophylaxis.

#### *Metatarsal osteotomies (and other osseous procedures)*

Correction of any hallux valgus deformity associated with transfer loading and Morton’s neuroma is sometimes essential in order to restore more normal foot biomechanics and



**Fig. 12** The medial gastrocnemius muscle aponeurosis is released at its proximal end.

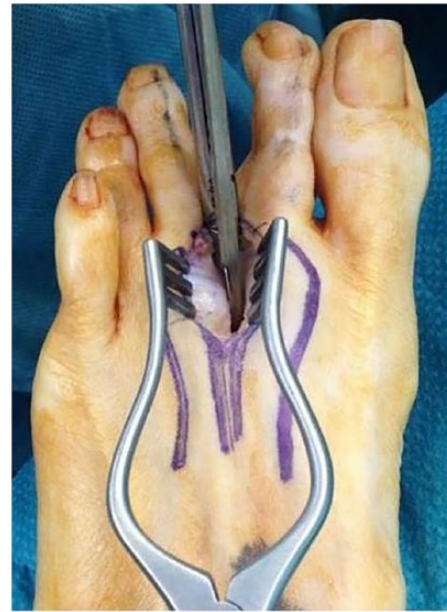

**Fig. 13** A 42-year-old female patient presented with recurrent hallux valgus, second-toe progressive deformity and neuritic symptoms arising from the second web space. A forefoot reconstruction was needed, in addition to the neurectomy.

plantar forefoot pressure distribution (Fig. 13). If the neuroma is not significantly painful, a hallux valgus corrective procedure alone can lead to gradual resolution of the neuritic symptoms.

Arthritis of the hallux MTP joint (hallux rigidus) in association with Morton's neuroma may require arthrodesis of the joint. This is often also the solution for previous failed first-ray surgeries (e.g. Keller's), or failed osteotomies for hallux valgus correction.

Long and/or plantar prominent lesser metatarsals, even in the absence of hallux valgus deformity, may require shortening and/or elevating osteotomies, e.g. Weil's metatarsal head – distal – osteotomies (if shortening and elevation is required), or dorsal closing wedge proximal metatarsal osteotomies (e.g. BRT [Barouk-Rippstein-Toullec] osteotomies, if elevation only is required). The indication to perform osteotomies at the same time as (or instead of) neurectomy is tenderness



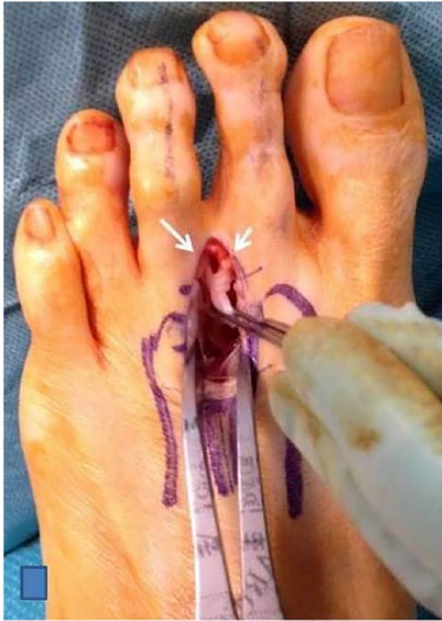**Fig. 14** The intermetatarsal ligament is cut through a dorsal approach.

associated with the MTP joints, together with radiographic signs of subluxation of the MTP joints and long lesser metatarsals. When performing lesser metatarsal osteotomies care has to be taken in order to restore a normal forefoot cascade.

One must also consider the additional morbidity and recovery time associated with metatarsal osteotomies, educate the patient accordingly and involve her/him in the decision-making process. The patient has to be warned that neuroma excision alone may improve/resolve the sharp, burning (neuritic) pain, but that some discomfort may still be experienced postoperatively.

In a single surgeon series at our institution simultaneous hallux valgus correction and/or lesser metatarsal osteotomies were performed in 23 out of 126 feet (18%) with symptomatic Morton's neuroma that required excision.



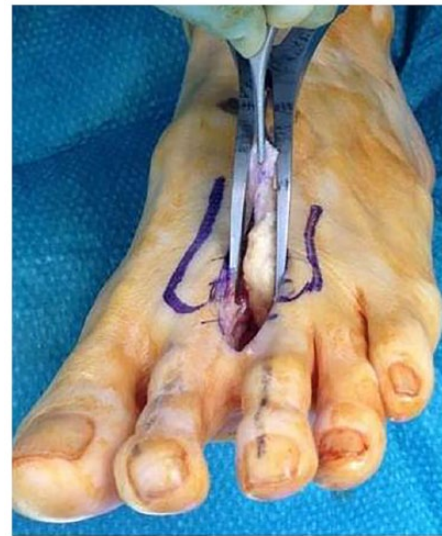

**Fig. 15** It is essential to dissect the two digital branches distally, to ensure that the interdigital neuroma has been correctly identified.

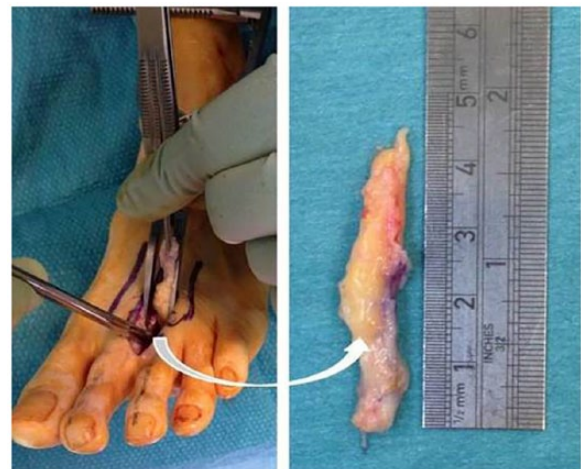
*Excision of Morton’s neuroma*

In the majority of patients with a diagnosis of Morton’s neuroma, the surgeon may have to perform a neurectomy, sometimes in combination with other procedures as previously discussed. It should be realized that this is not a ‘cure’ for the problem, as the primary problem is not the nerve itself.

The correct interdigital space has to be clearly marked on the skin prior to administration of anaesthesia and after reviewing the patient’s medical records, imaging studies and examining the patient prior to her/his transfer to the operating room. The procedure can be done under general or regional (e.g. spinal) anaesthesia and we strongly advocate the use of tourniquet. We advocate the use of one dose of perioperative antibiotic administration so as to reduce the potential infection risk associated with local skin flora in the foot. The patient lies supine on the operating table with elevation under the ipsilateral hip to allow for slight foot internal rotation. We advocate the use of the dorsal approach (Fig. 14). The intermetatarsal tissues are dissected and the deep transverse intermetatarsal ligament is visualized and incised parallel to the metatarsals. A laminar spreader can be inserted between the metatarsal heads. Application of some pressure on the plantar skin (in the intermetatarsal space area), in a plantar to dorsal direction, will often allow clear visualization of the thickened part of the interdigital nerve (neuroma) that is sometimes surrounded by inflamed bursal tissue. The nerve is then dissected first distally, until the bifurcation of the two digital branches becomes apparent (Fig. 15). The



**Fig. 16** The nerve trunk is dissected proximally from the plantar aspect. It is important to dissect a long segment, deep into the foot.



**Fig. 17** A long segment of nerve (3–4cm) is dissected out, in order to ensure that the nerve stump retracts proximal to the weight-bearing area of the metatarsal heads.

distal nerve branches are cut distally, and proximal dissection on the plantar aspect of the nerve is performed (Fig. 16). The surgeon should take care to detect any anatomic variations of the nerve branches. Proximal dissection of the nerve trunk has to continue for at least 3–4 cm, in order to ensure that the sectioned nerve ending retracts proximal to the weight-bearing part of the forefoot. Thus, a long segment of the nerve has to be removed (Fig. 17) to reduce the risk of a symptomatic stump neuroma. The nerve stump area can be infiltrated with local anaesthetic and meticulous haemostasis should be performed prior to skin closure.

Postoperatively (if this is an isolated procedure) the patient is advised to maintain elevation of the foot whenever possible and to keep the wound dry for two weeks. Partial weight bearing, using a postoperative flat shoe, is recommended for 48 hours and then progression to full weight bearing as tolerated. Once the wound has healed, manual massaging of the dorsal scar and the plantar aspect in the area of the nerve stump is recommended, in order to avoid tender scar formation and to desensitize the nerve stump, respectively. High-impact activities should be avoided for 12 weeks.

## Conclusions

Morton's interdigital neuroma can cause burning pain and significant activity-related discomfort. It is the result of altered foot biomechanics and forefoot overload, and the treating doctor must consider the bigger picture which should include calf muscle tightness, hindfoot or forefoot deformity and long lesser metatarsals. History, clinical presentation and examination usually reveal the diagnosis, whereas imaging studies (standing radiographs, ultrasound, MRI scans) aid in the differential diagnosis process. Accurate diagnosis, with recognition of all elements of the problem and education of the patient and management of her/his expectations, are all key factors for successful management. Nonoperative management options (all with variable success rates – especially alcohol injections and cryotherapy) include physiotherapy, modification of activities, use of appropriate footwear, injections (local anaesthetic, steroid, alcohol), cryotherapy, radiofrequency ablation, shockwave therapy and high-dose vitamin B6 and B1. A la carte surgery (including osteotomies and sometimes gastrocnemius release) should be considered when nonoperative management has failed. Neuroma excision requires a meticulous surgical technique so as to identify the nerve and excise a long segment of it. Good to excellent results with neuroma excision have been reported in 70–80% of cases, but one in ten patients may end up worse and revision surgery may not offer a solution.

### AUTHOR INFORMATION

<sup>1</sup>Frimley Health NHS Foundation Trust, Frimley Park Hospital, UK.

Correspondence should be sent to: N. Gougoulias, Frimley Health NHS Foundation Trust, Frimley Park Hospital, Portsmouth Road, Frimley, Surrey, GU16 7UJ, UK.  
Email: gougoulias@yahoo.com

### ICMJE CONFLICT OF INTEREST STATEMENT

N. Gougoulias and A. Sakellariou declare travel/accommodation/meeting expenses from EFAS, activity outside the submitted work.

### FUNDING STATEMENT

No benefits in any form have been received or will be received from a commercial party related directly or indirectly to the subject of this article.

### LICENCE

© 2019 The author(s)

This article is distributed under the terms of the Creative Commons Attribution-Non Commercial 4.0 International (CC BY-NC 4.0) licence (<https://creativecommons.org/licenses/by-nc/4.0/>) which permits non-commercial use, reproduction and distribution of the work without further permission provided the original work is attributed.

### REFERENCES

- Morscher E, Ulrich J, Dick W.** Morton's intermetatarsal neuroma: morphology and histological substrate. *Foot Ankle Int* 2000;21:558–562.
- Morton TG.** A peculiar and painful affection of the fourth metatarso-phalangeal articulation. *Am J Med Sci* 1876;71:37–45.
- Di Caprio F, Meringolo R, Eddine MS, Ponziani L.** Morton's interdigital neuroma of the foot: a literature review. *Foot Ankle Surg* 2017;24:92–98.
- Singh D.** Nils Silfverskiöld (1888–1957) and gastrocnemius contracture. *Foot Ankle Surg* 2013;19:135–138.
- Owens R, Gougoulias N, Guthrie H, Sakellariou A.** Morton's neuroma: clinical testing and imaging in 76 feet, compared to a control group. *Foot Ankle Surg* 2011;17:197–200.
- Bignotti B, Signori A, Sormani MP, Molfetta L, Martinoli C, Tagliafico A.** Ultrasound versus magnetic resonance imaging for Morton neuroma: systematic review and meta-analysis. *Eur Radiol* 2015;25:2254–2262.
- Mahadevan D, Salmasi M, Whybra N, Nanda A, Gaba S, Mangwani J.** What factors predict the need for further intervention following corticosteroid injection of Morton's neuroma? *Foot Ankle Surg* 2016;22:9–11.
- Mahadevan D, Attwal M, Bhatt R, Bhatia M.** Corticosteroid injection for Morton's neuroma with or without ultrasound guidance: a randomised controlled trial. *Bone Joint J* 2016;98-B:498–503.
- Lizano-Díez X, Ginés-Cespedosa A, Alentorn-Geli E, et al.** Corticosteroid injection for the treatment of Morton's neuroma: a prospective, double-blinded, randomized, placebo-controlled trial. *Foot Ankle Int* 2017;38:944–951.
- Thomson CE, Beggs I, Martin DJ, et al.** Methylprednisolone injections for the treatment of Morton neuroma: a patient-blinded randomized trial. *J Bone Joint Surg Am* 2013;95:790–798.
- Gurdezi S, White T, Ramesh P.** Alcohol injection for Morton's neuroma: a five-year follow-up. *Foot Ankle Int* 2013;34:1064–1067.
- Musson RE, Sawhney JS, Lamb L, Wilkinson A, Obaid H.** Ultrasound guided alcohol ablation of Morton's neuroma. *Foot Ankle Int* 2012;33:196–201.
- Perini L, Perini C, Tagliapietra M, et al.** Percutaneous alcohol injection under sonographic guidance in Morton's neuroma: follow-up in 220 treated lesions. *Radiol Med (Torino)* 2016;121:597–604.
- Moore JL, Rosen R, Cohen J, Rosen B.** Radiofrequency thermoneurolysis for the treatment of Morton's neuroma. *J Foot Ankle Surg* 2012;51:20–22.
- Chuter GS, Chua YP, Connell DA, Blackney MC.** Ultrasound-guided radiofrequency ablation in the management of interdigital (Morton's) neuroma. *Skeletal Radiol* 2013;42:107–111.

- 16. Friedman T, Richman D, Adler R.** Sonographically guided cryoneurolysis: preliminary experience and clinical outcomes. *J Ultrasound Med* 2012;31:2025–2034.
- 17. Fridman R, Cain JD, Weil L Jr.** Extracorporeal shockwave therapy for interdigital neuroma: a randomized, placebo-controlled, double-blind trial. *J Am Podiatr Med Assoc* 2009;99:191–193.
- 18. Bae S-Y, Jung EY, Oh SC.** Pyridoxine in the treatment of peripheral nerve related foot pain. *J Korean Foot Ankle Soc* 2013;17:203–208.
- 19. Coughlin MJ, Pinsonneault T.** Operative treatment of interdigital neuroma: a long-term follow-up study. *J Bone Joint Surg Am.* 2001;83-A:1321–1328.
- 20. Kasperek M, Schneider W.** Surgical treatment of Morton’s neuroma: clinical results after open excision. *Int Orthop* 2013;37:1857–1861.
- 21. Bucknall V, Rutherford D, MacDonald D, Shalaby H, McKinley J, Breusch SJ.** Outcomes following excision of Morton’s interdigital neuroma: a prospective study. *Bone Joint J* 2016;98-B:1376–1381.
- 22. Rungprai C, Cychosz CC, Phruetthiphat O, Femino JE, Amendola A, Phisitkul P.** Simple neurectomy versus neurectomy with intramuscular implantation for interdigital neuroma: a comparative study. *Foot Ankle Int* 2015;36:1412–1424.
- 23. Akermark C, Crone H, Skoog A, Weidenhielm L.** A prospective randomized controlled trial of plantar versus dorsal incisions for operative treatment of primary Morton’s neuroma. *Foot Ankle Int* 2013;34:1198–1204.
- 24. Park EH, Kim YS, Lee HJ, Koh YG.** Metatarsal shortening osteotomy for decompression of Morton’s neuroma. *Foot Ankle Int* 2013;34:1654–1660.
- 25. Bauer T, Gaumetou E, Klouche S, Hardy P, Maffulli N.** Metatarsalgia and Morton’s disease: comparison of outcomes between open procedure and neurectomy versus percutaneous metatarsal osteotomies and ligament release with a minimum of 2 years of follow-up. *J Foot Ankle Surg* 2015;54:373–377.
- 26. Richardson DR, Dean EM.** The recurrent Morton neuroma: what now? *Foot Ankle Clin* 2014;19:437–449.
- 27. Stamatis ED, Myerson MS.** Treatment of recurrence of symptoms after excision of an interdigital neuroma: a retrospective review. *J Bone Joint Surg Br* 2004;86:48–53.
- 28. DiGiovanni CW, Kuo R, Tejwani N, et al.** Isolated gastrocnemius tightness. *J Bone Joint Surg Am* 2002;84-A:962–970.
- 29. Jastifer J, Marston J.** Gastrocnemius contracture in patients with and without foot pathology. *Foot Ankle Int* 2016;37:1165–1170.
- 30. Barouk P.** Technique, indications, and results of proximal medial gastrocnemius lengthening. *Foot Ankle Clin* 2014;19:795–806.
- 31. Gougoulias N, Dawe EJ, Sakellariou A.** The recovery position for posterior surgery of the ankle and hindfoot. *Bone Joint J* 2013;95-B:1317–1319.