



A de novo case of minimal change disease following the first dose of the Moderna mRNA-1273 SARS-CoV-2 vaccine without relapse after the second dose

Reika Ikegami Mochizuki¹ · Naohiro Takahashi¹ · Ken Ikenouchi¹ · Wakana Shoda¹ · Tamaki Kuyama¹ · Daiei Takahashi¹

Received: 9 February 2022 / Accepted: 29 March 2022 / Published online: 18 April 2022

© The Author(s) under exclusive licence to The Japan Society of Nephrology 2022

Abstract

In recent times, new onset or relapse of nephrotic syndrome following the first dose of SARS-CoV-2 vaccines has been reported. Although the vaccination could trigger nephrotic syndrome, the question of whether the same vaccine should be administered as the second dose remains unanswered. A 25-year-old woman had taken the Moderna mRNA-1273 SARS-CoV-2 vaccine (mRNA-1273) and 26 days later, she noticed facial and peripheral edema. One week later she was referred and admitted to our hospital, wherein laboratory tests revealed that her serum creatinine level, serum albumin level, and urine protein–creatinine ratio were respectively 0.79 mg/dL, 2.5 g/dL, and 7.0 g/gCr. After a thorough inpatient examination including renal biopsy, she was diagnosed with minimal change disease (MCD) and treatment with steroids was initiated. She achieved complete remission the next day and did not experience a relapse upon receiving the second mRNA-1273 dose 56 days after the first, under treatment with 35 mg/day of oral prednisolone. This case report yields insight into determining whether patients who develop de novo MCD after the first mRNA-1273 dose should receive the second dose.

Keywords COVID-19 · SARS-CoV-2 vaccine · Moderna · Minimal change disease · Nephrotic syndrome

Introduction

We have been in the midst of a global severe acute respiratory syndrome coronavirus 2 (SARS-CoV-2) pandemic since 2019. Multiple vaccines have been developed. While vaccines have benefits such as reduction of mortality and disease severity, some of the side effects are not fully clarified.

In recent times, several cases of new onset of autoimmune diseases such as autoimmune liver disease, Guillain–Barré syndrome, and systemic lupus erythematosus have been reported after administration of SARS-CoV-2 vaccine. However, whether any causal relationship exists between SARS-CoV-2 vaccination and the onset of autoimmune disease has yet to be clarified [1].

With regard to renal disease, Bomback et al. reported cases of new onset or recurrence of nephrotic syndrome after the administration of the first dose of SARS-CoV-2 vaccine [2]. According to this study, IgA nephropathy and minimal change disease (MCD) have been reported as causative diseases of nephrotic syndrome after SARS-CoV-2 vaccination, and the number of reports of these disorders is greater than that of other causative ones such as vasculitis. A recent clinical report has noted a correlation with gross hematuria following SARS-CoV-2 vaccination in patients with glomerulonephritis, particularly IgA nephropathy [3]. In this report, Matsuzaki et al. suggested that CD4+ and CD8+ T cells activated by mRNA vaccination might produce several proinflammatory cytokines and that mRNA vaccination might affect the production of glycosylation-abnormal IgA through Toll-like receptor signaling.

In MCD that develops after SARS-CoV-2 vaccination, as in IgA nephropathy, it is presumed that the vaccine's effect on the immune response is related to the development of renal disease, and several studies have reported about MCD after SARS-CoV-2 vaccination [4–6]. However, to the best of our knowledge, there are only a few case reports of de

✉ Reika Ikegami Mochizuki
reika.mochizuki@gmail.com

¹ Department of Nephrology, Musashino Red Cross Hospital, 1-26-1, Kyonann-cho, Musashino-shi, Tokyo 180-8610, Japan

novo MCD after vaccination and safe completion of a second dose of the same type of vaccine. Herein, we report the case of a 25-year-old woman with no remarkable medical history who developed MCD following the first dose of mRNA-1273 vaccine without relapse after the second dose.

Case report

Our patient was a previously healthy 25-year-old woman with no medical history. She had received regular physical examinations and never reported any renal dysfunction or abnormal urinalysis.

She denied using any prescription or over-the-counter medications, including nonsteroidal anti-inflammatory drugs. She received the first dose of Moderna SARS-CoV-2 mRNA-1273 vaccine, and after 26 days, she experienced facial and peripheral edema. One week later, she was referred and admitted to our hospital.

On admission, she was 160 cm tall and weighed 58.6 kg, showing a weight gain of 6.6 kg over her normal weight. Her blood pressure and heart rate were 132/83 mm Hg and 71 beats/min, respectively. Physical examination revealed pitting edema in the upper and lower extremities, face, and

abdomen. Respiratory sounds were clear, and no pulmonary murmurs were detected. Laboratory tests revealed the following: serum creatinine, 0.79 mg/dL; serum urea nitrogen, 15.8 mg/dL; albumin, 2.5 g/dL; total cholesterol, 241 mg/dL; triglycerides, 57 mg/dL. Test results for hepatitis B surface antigen and antibodies to hepatitis C virus were negative. The levels of complement C3 and C4 were within reference ranges, and tests for anti-neutrophil cytoplasmic antibody, anti-glomerular basement membrane antibodies, and antinuclear antibody were also negative. Urinalysis revealed protein (3+), and urinary sediment showed 1–4 red blood cells per high-power field, glass cylinders, and epithelial cylinders. The urine protein–creatinine ratio was 7.06 g/g Cr (Table 1). Chest X-ray imaging revealed a small amount of pleural effusion. On abdominal ultrasonography, the kidneys had normal size, and there was no evidence of urinary tract obstruction.

A diagnosis of de novo nephrotic syndrome was given, which was subsequently treated with 500 mg/day of methylprednisolone administered intravenously for 3 days and then 45 mg/day of prednisolone administered orally.

On day 9 of hospitalization, a percutaneous kidney biopsy was performed. The results are shown in Fig. 1. Thirteen glomeruli were observed, with no adhesions, crescent

Table 1 Laboratory data on admission

Blood cell count			Immunology			Urinalysis		
WBC	5600	/μL	CRP	0.05	mg/dL	pH	7	
Hb	13.2	g/dL	ASLO	28	U/mL	Gravity	1.005	
Plt	201	10 ³ /μL	RF	13	IU/mL	Protein	(3+)	
			IgG	976.8	mg/dL	Sugar	(–)	
Blood chemistry			IgA	213.9	mg/dL	Blood	(±)	
TP	5.3	g/dL	IgM	200.3	mg/dL	RBC	1–4	/HF
Alb	2.5	g/dL	C3	88.2	mg/dL	Glass cylinder	5–9	/HF
AST	25	U/L	C4	22.8	mg/dL	Epithelial cylinder	1–4	/HF
ALT	31	U/L	CH50	28.6	U/mL	Na	16	mEq/L
T-Bil	1.1	U/L	Antinuclear antibody	<40		K	8.9	mEq/L
UN	15.8	mg/dL	PR3-ANCA	<1	U/mL	Cl	15	mEq/L
Cr	0.79	mg/dL	MPO-ANCA	<1	U/mL	Cr	29.74	mg/dL
eGFR	73.7	mL/min/1.73 m ²	anti GBM antibody	<2	U/mL	UN	182.2	mg/dL
Na	140	mEq/L				TP	210.1	mg/dL
K	4.5	mEq/L				TP/Cr	7.06	g/g Cr
Cl	106	mEq/L				Selectivity index	0.09	
HDL-chol	99	mg/dL						
LDL-chol	130.7	mg/dL						
T-chol	241	mg/dL						
TG	57	mg/dL						

WBC white blood cell, Hb hemoglobin, Plt platelet, TP total protein, Alb albumin, AST aspartate aminotransferase, ALT alanine aminotransferase, T-Bil total bilirubin, UN urea nitrogen, Cr creatinine, eGFR estimated glomerular filtration rate, HDL-chol high-density lipoprotein cholesterol, LDL-chol low-density lipoprotein cholesterol, T-chol total cholesterol, TG triglyceride, CRP C-reactive protein, ASLO anti streptolysin O, RF rheumatoid factor, CH50 complement activity, PR3-ANCA proteinase3-anti-neutrophil cytoplasmic antibody, MPO-ANCA myeloperoxidase anti-neutrophil cytoplasmic antibody, anti GBM antibody anti-glomerular basement membrane antibodies, RBC red blood cell

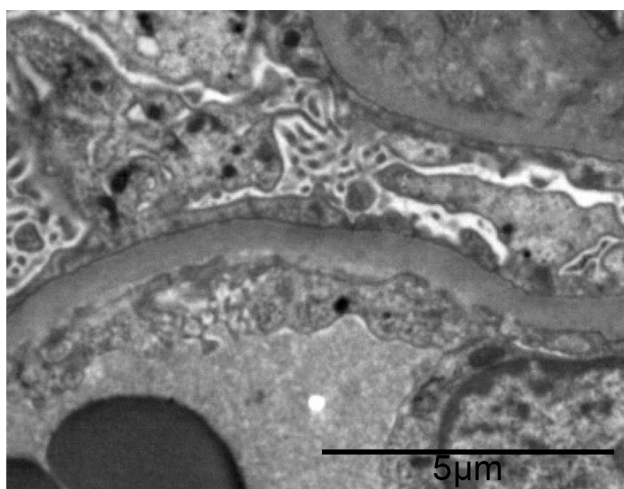


Fig. 1 Electron micrograph featuring a glomerular capillary loop with diffuse podocyte effacement (black bar = 5 μ m)

formation, sclerosis, or segmental lesions, and all glomeruli were intact. The lumen of the glomerular capillaries was well maintained, and no increase in cellular components in the mesangium or thickening of the basement membrane was observed. The tubular epithelium was congested and swollen. Sclerotic changes in the small vasculature were mild. Immunofluorescent antibody assay showed no significant immune complex deposition.

Four glomeruli were examined by electron microscopy. No melting-like changes or tear images were observed in the basement membrane. The loss of foot processes was observed locally, and the swelling of epithelial cells was

mild. There were no remarkable electron-dense deposits. These findings were consistent with MCD.

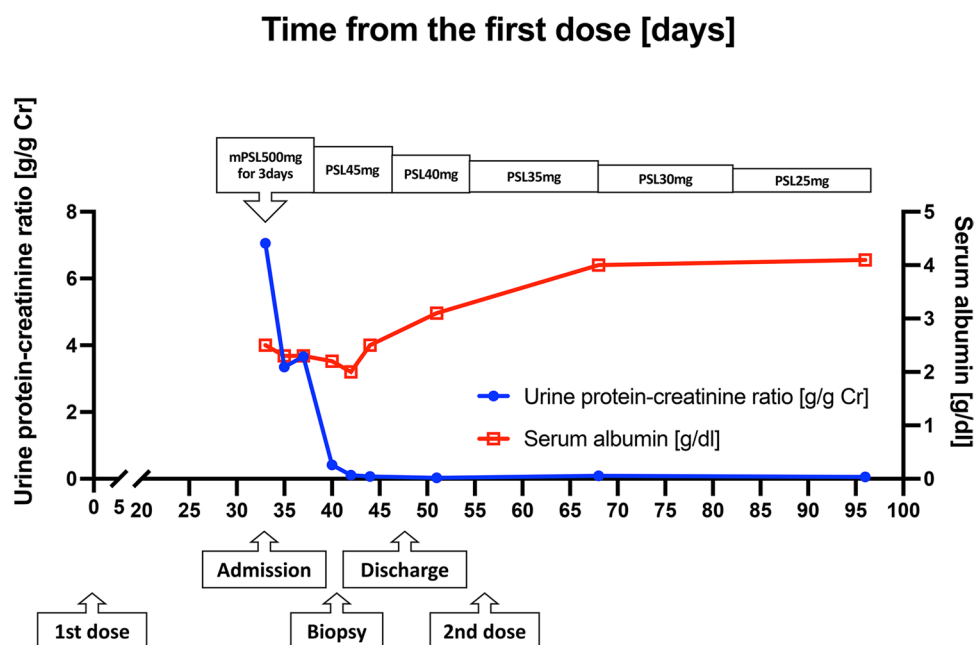
The patient achieved complete remission the next day and did not experience a relapse upon receiving the second mRNA-1273 dose 56 days after the first while under treatment with 35 mg/day of oral prednisolone (Fig. 2).

Discussion

There have been several reports of the onset and recurrence of nephrotic syndrome after administration of mRNA SARS-CoV-2 vaccine [2]. A study revealed that an individual's antibody production peaks 2–4 weeks after receiving mRNA-1273 vaccine [7]. Here, our patient was diagnosed with de novo nephrotic syndrome nearly 4 weeks after the first mRNA-1273 dose, coinciding with the time when antibody production peaks [7]. Collectively, this suggests that the vaccine was involved in the development of her MCD. Therefore, a second dose of the same vaccine can induce relapse of MCD. While this risk may exist, two doses of mRNA-1273 showed high efficacy in preventing SARS-CoV-2 infection [8]. Thus, it should be clarified if and when the second dose of the same vaccine should be given to the patient with de novo MCD following first vaccination.

Few case reports of de novo MCD after vaccination and successful completion of the second dose of the same vaccine type have been available [2, 9]. Our patient experienced this condition 26 days after receiving the first mRNA-1273 dose, although remission quickly occurred following administration of intravenous methylprednisolone and was

Fig. 2 Timeline of clinical events from the first vaccination to the last hospital visit. *mPSL* methylprednisolone, *PSL* prednisolone



maintained with 35 mg/day of oral prednisolone even after she was given the second mRNA-1273 dose.

Interestingly, compared with BioNTech/Pfizer SARS-CoV-2 vaccine (BNT162b2), mRNA-1273 was proven to stimulate the production of a larger number of antibodies [10]. Serologic testing from an investigation by Steensels et al. [10] showed that 6–10 weeks after administering the second mRNA-1273 dose to a subset of participants, these individuals were found to have titers of antibodies against the SARS-CoV-2 nucleocapsid protein that were 2.5 times higher than those detected in participants vaccinated with BNT162b2. Nevertheless, from two related studies, it appears that such antibody activity does not endure beyond 6 months; one noted that pseudovirus neutralization activities decreased by 81% within 2 weeks to 6 months following the second mRNA-1273 dose (50% inhibitory dilution [ID₅₀] of geometric mean titers: 358 [95% CI 297–430] at 14 days postvaccination vs. 67 [95% CI 49–92] at 180 days postvaccination; $P < 0.001$) [11], and another reported an 84% decline in pseudovirus neutralization activities during this same timeframe after the second BNT162b2 dose [12]. Heeding these outcomes, it is not unreasonable to presume that immunogenicity will be greater and last longer upon vaccination with mRNA-1273 relative to BNT162b2, at least over the shorter term.

Based on previous research, MCD is believed to result from podocyte injuries caused by an abnormal T-cell response [13]. As such, considering that immunogenicity from mRNA-1273 is likely stronger than that of BNT162b2, physicians might need to prescribe immunosuppressive treatments for longer periods to individuals vaccinated with the former. It will also be important that they monitor the clinical course of patients to ensure that MCD relapse does not occur, though the duration of this therapy will depend on the longevity of the antibody titer and immunogenicity induced by the vaccine. However, answers to these questions remain presently unclear.

This case report yields insight into determining whether patients who develop de novo MCD after the first mRNA-1273 dose should receive the second dose. Our data tentatively suggest that it may be safely administered alongside immunosuppressive treatment, so long as the patient has achieved complete remission. However, the patient was taking 35 mg/day of steroids at the time of the second vaccination, and we must consider the possibility that nephrotic syndrome would have relapsed after the second vaccination if the steroid dosage at that time had been lower. Moreover, the appropriate type and dosage of immunosuppressive medications to prevent relapse of nephrotic syndrome after vaccination has not yet been clarified. Future investigations on similar cases are warranted to elucidate mechanisms underlying the emergence of MCD after SARS-CoV-2 mRNA vaccinations.

Declarations

Conflict of interest All the authors have declared no competing interest.

Research involving human participants and/or animals This article does not contain any studies with human participants performed by any of the authors.

Informed consent Informed consent was obtained from the patient included in the study.

References

- Chen Y, Xu Z, Wang P, Li XM, Shuai ZW, Ye DQ, et al. New-onset autoimmune phenomena post-COVID-19 vaccination. *Immunology*. 2021. <https://doi.org/10.1111/imm.13443>.
- Bomback AS, Kudose S, D'Agati VD. De novo and relapsing glomerular diseases after COVID-19 vaccination: what do we know so far? *Am J Kidney Dis*. 2021. <https://doi.org/10.1053/j.ajkd.2021.06.004>.
- Matsuzaki K, Aoki R, Nihei Y, Suzuki H, Kihara M, Yokoo T, et al. Gross hematuria after SARS-CoV-2 vaccination: questionnaire survey in Japan. *Clin Exp Nephrol*. 2022;26:316–22. <https://doi.org/10.1007/s10157-021-02157-x>.
- D'Agati VD, Kudose S, Bomback AS, Adamidis A, Tartini A. Minimal change disease and acute kidney injury following the Pfizer-BioNTech COVID-19 vaccine. *Kidney Int*. 2021;100:461–3. <https://doi.org/10.1016/j.kint.2021.04.035>.
- Komaba H, Wada T, Fukagawa M. Relapse of Minimal Change Disease Following the Pfizer-BioNTech COVID-19 Vaccine. *Am J Kidney Dis*. 2021. <https://doi.org/10.1053/j.ajkd.2021.05.006>.
- Salem F, Rein J, Mon-Wei Yu S, Abramson M, Cravedi P, Chung M. Report of three cases of minimal change disease following the second dose of mRNA SARS-CoV-2 vaccine. *Kidney Int Rep*. 2021. <https://doi.org/10.1016/j.ekir.2021.07.017>.
- Jackson LA, Anderson EJ, Roupheal NG, Roberts PC, Makhene M, Coler RN, et al. An mRNA vaccine against SARS-CoV-2—preliminary report. *N Engl J Med*. 2020;383:1920–31. <https://doi.org/10.1056/NEJMoa2022483>.
- Baden LR, El Sahly HM, Essink B, Kotloff K, Frey S, Novak R, et al. Efficacy and safety of the mRNA-1273 SARS-CoV-2 vaccine. *N Engl J Med*. 2021;384:403–16. <https://doi.org/10.1056/NEJMoa2035389>.
- Mancianti N, Guarnieri A, Tripodi S, Salvo DP, Garosi G. Minimal change disease following vaccination for SARS-CoV-2. *J Nephrol*. 2021;34:1039–40. <https://doi.org/10.1007/s40620-021-01091-1>.
- Steensels D, Pierlet N, Penders J, Mesotten D, Heylen L. Comparison of SARS-CoV-2 antibody response following vaccination with BNT162b2 and mRNA-1273. *JAMA*. 2021. <https://doi.org/10.1001/jama.2021.15125>.
- Doria-Rose N, Suthar MS, Makowski M, O'Connell S, McDermott AB, Flach B, et al. Antibody persistence through 6 months after the second dose of mRNA-1273 vaccine for Covid-19. *N Engl J Med*. 2021;384:2259–61. <https://doi.org/10.1056/NEJMc2103916>.
- Canaday DH, Oyeibanji OA, Keresztesy D, Payne M, Wilk D, Carias L, et al. Significant reduction in humoral immunity among healthcare workers and nursing home residents 6 months after COVID-19 BNT162b2 mRNA vaccination. *Center Innov*

- Long-Term Serv Supp. 2021. <https://doi.org/10.1101/2021.08.15.21262067>.
13. Vivarelli M, Massella L, Ruggiero B, Emma F. Minimal change disease. Clin J Am Soc Nephrol. 2017;12:332–45. <https://doi.org/10.2215/CJN.05000516>.

Publisher's Note Springer Nature remains neutral with regard to jurisdictional claims in published maps and institutional affiliations.