

Immunohistochemistry in Primary B-cell Lymphoma of Tibia Masquerading as Chronic Osteomyelitis

Abstract

The diagnosis between chronic osteomyelitis, Ewing sarcoma and lymphoma often is being confusing in many occasions. As the latter two conditions are malignant, early diagnosis and interventions are crucial. We present a 28 year old male with features of chronic osteomyelitis of right tibia 2 years back then changed through Ewing sarcoma to B-cell lymphoma in the histological diagnosis. This case report highlights the difficulties that arise in diagnosing primary bone lymphomas which may masquerade as chronic osteomyelitis and hence the need for immunohistochemistry in chronic recurrent osteomyelitis.

Keywords: Chronic osteomyelitis, Ewing sarcoma, immunohistochemistry, lymphoma

MeSH terms: Osteomyelitis, Ewing's tumour, lymphoma, magnetic resonance imaging

**Raju Karuppal,
Samarth Manjunath,
Rajendran V
Raman¹,
S Sandhya²**

Departments of Orthopedics,

¹Radiodiagnosis and

²Ophthalmology, Kerala

University of Health Sciences,

Government Medical College,

Kozhikode, Kerala, India

Introduction

Bone malignancies can present with signs and symptoms mimicking osteomyelitis. Hence there is possibility of delayed diagnosis of malignancy or it may be initially misdiagnosed as osteomyelitis, which can adversely affect the outcome. We would like to highlight through this article that biopsy and immunohistochemistry may be considered in those cases of chronic osteomyelitis where there is any deviation from its typical natural history, progression or unexpected histological/laboratory findings.

Case Report

A 28 year old male patient presented initially in December 2013 with clinical features of acute osteomyelitis of right tibia. His haemogram was normal and the blood culture was negative for bacterial study. The erythrocyte sedimentation rate was 22 mm/h and C-reactive protein of 34 mg/dl. Polymerase chain reaction and culture for *Mycobacterium tuberculosis* were negative. There was no regional or generalized lymphadenopathy. X-ray of the right leg showed an osteolytic lesion of the right tibia within distinct margins, cortical breach, and moth-eaten appearance. Magnetic resonance imaging (MRI) scan done prior to the biopsy was reported as osteomyelitis of tibia. Biopsy report

came as inflammatory granulation tissue densely infiltrated by lymphocytes and histiocytes consistent with nonspecific chronic osteomyelitis. Tissue cultures were negative for bacterial or fungal elements. Tumor markers or special stains were not done. The patient was treated with antibiotics and anti-inflammatory drugs. He was then discharged from the hospital once his pain subsided and was kept under close followup.

He remained asymptomatic except a diffuse swelling over the anteromedial part of the right tibial shaft. After 6 months, he presented again with complaints of pain and rapidly increasing swelling on his right leg, which increased to a size of 10 cm [Figure 1]. There was no regional lymphadenopathy. X-ray showed a permeative lesion with significant periosteal reaction over the mid-diaphysis of the tibia. We suspected some type of aggressive bone tumors in view of the rapidly increasing swelling and the permeative lesions in the X-ray. Hence, his chest X-ray, computed tomography of chest, and ultrasound abdomen were taken which were negative for any lesion. This prompted us to take a repeat MRI contrast study, which showed (coronal image) altered signal intensity and irregular patchy enhancement lesion involving the marrow of the diaphysis of the tibia. There is enhancing soft tissue component as well [Figure 2a]. The sagittal image shows diffuse marrow and soft tissue

Address for correspondence:

Dr. Raju Karuppal,
Department of Orthopedics,
Kerala University of Health
Sciences, Government Medical
College, Kozhikode - 673 009,
Kerala, India.

E-mail: dranjuortho@rediffmail.com

Access this article online

Website: www.ijoonline.com

DOI:
10.4103/0019-5413.209952

Quick Response Code:



How to cite this article: Karuppal R, Manjunath S, Raman RV, Sandhya S. Immunohistochemistry in primary B-cell lymphoma of tibia masquerading as chronic osteomyelitis. Indian J Orthop 2017;51:477-80.

This is an open access article distributed under the terms of the Creative Commons Attribution-NonCommercial-ShareAlike 3.0 License, which allows others to remix, tweak, and build upon the work non-commercially, as long as the author is credited and the new creations are licensed under the identical terms.

For reprints contact: reprints@medknow.com

involvement with posterior cortical irregularity [Figure 2b]. Fine-needle aspiration cytology (FNAC) done from the lesion composed of sheets of small cells with high nuclear to cytoplasmic ratio. The cytoplasm was scant and eosinophilic suggestive of Ewing sarcoma [Figure 3]. Due to the disparity in the two Histopathological reports (initial report of non specific chronic osteomyelitis and the present report of Ewing sarcoma), confirmatory biopsy with immunohistochemistry was done. Incision biopsy showed the sheets of medium-sized atypical lymphoid cells suggestive of B-cell lymphoma [Figure 4].

Immunohistochemistry showed CD99 negativity (specific of Ewing sarcoma). Then, the immunohistochemistry study of lymphoma was suggested as it is the next possible condition. The CD45 (leukocyte common antigen [LCA]) (for differentiating to lymphomas) [Figure 5] and CD20 (specific of B-cell lymphomas) [Figure 6] were positive. Then, the final diagnosis was made as a primary B-cell lymphoma. He was started on combined treatment modality with chemotherapy and radiotherapy. There was no evidence of recurrence at the 15th month followup.

Discussion

Primary bone lymphoma constitutes 3% of primary bone tumor and 5% of extranodal lymphomas. Males are affected more commonly than females.¹ Although primary bone lymphoma is uncommon, all ages may be affected. Common sites of involvement include femur, humerus, tibia, spine, pelvis, sternum, ribs, and bones of the skull and face in the decreasing order. The exact etiology of primary bone lymphoma is unknown, in some cases; immunosuppression or viral agents are attributed. Bone pain is the most common presenting feature of bone lymphoma. As of now, there is no report of lymphomas being developed secondarily in chronic inflammatory conditions.

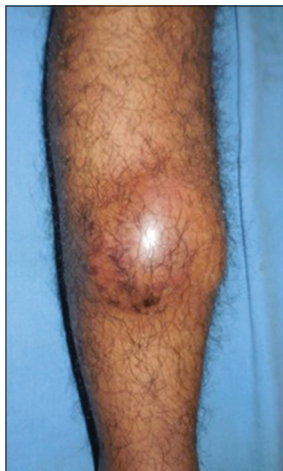

Figure 1: Clinical picture showing a swelling over the anteromedial surface of the right leg

The diagnostic criteria of primary bone lymphoma were described by Giudici *et al.*: (a) The patient demonstrates a primary focus in a single bone, (b) histological proof has to be obtained from the skeletal focus (not from a metastasis) and (c) the onset of symptoms of the primary skeletal lesion precedes the appearance of distant metastases by at least 6 months.² Presenting features often are palpable swelling and pathological fracture. Systemic symptoms such as fever, night sweats, and weight loss are seen in <10% of patients. Regional lymphnodes may be involved in some patients although this occurs more commonly in cases of bone involvement in patients with systemic lymphoma.²

It has been reported that malignant lesions may be misdiagnosed as a rise or accompany osteomyelitis.³ There are only a very few such case reports in the literature regarding primary bone lymphomas.⁴⁻⁷ Blum *et al.* Published a series of three lymphomas masquerading as infection.⁸ Our case is another example of misdiagnosis of primary lymphoma of bone. Histologically, there are many types of inflammatory cells in lymphoma, the most common being the T-lymphocyte infiltrate, which will obscure the lymphoma cells and gives an incorrect diagnosis of osteomyelitis. Lymphoma cells, although are, may also be spindle shaped and can be arranged in a storiform pattern which may masquerade as sarcoma. These may be the reason why our case was initially misdiagnosed as osteomyelitis and later as Ewing sarcoma mistakenly.

The first-line marker for differentiating between lymphomas (CD45⁺) and poorly differentiated nonhemopoietic tumors (CD45⁻) is the monoclonal antibodies directed against the leukocyte common antigen (CD45).⁹ Most common type of malignant lymphoma of bone is B-cell neoplasms. Lymphoid origin can be confirmed by CD45 (LCA) stain.⁹ Most B-cell neoplasms show the presence of CD20

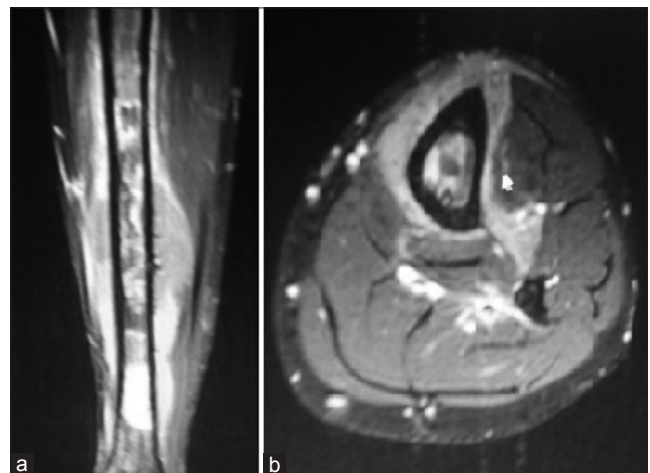


Figure 2: (a) Magnetic resonance imaging contrast study (coronal image) showing altered signal intensity and irregular patchy enhancement lesion involving the marrow of the diaphysis of the tibia. (b) The sagittal image showing diffuse marrow and soft tissue involvement with posterior cortical irregularity

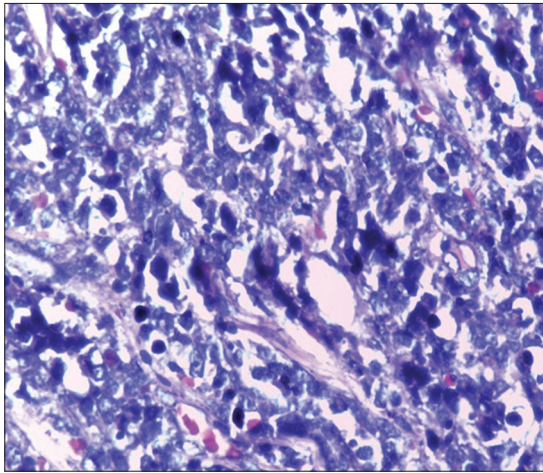


Figure 3: Photomicrograph of Ewing sarcoma showing scant and eosinophilic cytoplasm with sheets of small cells with high nuclear to cytoplasmic ratio

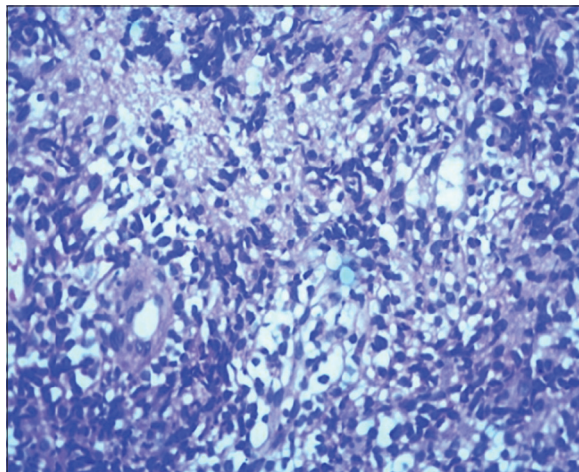


Figure 4: Photomicrograph of B-cell lymphoma showing sheets of medium-sized atypical lymphoid cells (H and E) $\times 400$

on the cells and are absent on otherwise similar appearing T-cell neoplasms. The B-cell lineage can be by CD20 stain.⁹ It is very useful in diagnosing conditions such as B-cell lymphomas; however, the presence or absence of CD20 in such tumors is not relevant to prognosis.¹⁰ In our case, CD99 was negative which is specific of Ewing sarcoma, and both CD45 and CD20 were positive to prove it is a B-cell lymphoma without any confusion.

Delays in establishing the diagnosis have serious effects on the prognosis. The disease stage being often considered as the most important prognostic indicator.¹¹ Hence, earliest diagnosis prior to leukemic spread or metastasis highly essential. In any patient with osteomyelitis like picture and bone pain refractory to medical treatment, the detailed diagnostic workup should be done, and unusual neoplasms like primary lymphoma of bone should be considered in the diagnostic armamentarium. In our case, the misdiagnosis/diagnostic delays were due to the variable investigative findings, i.e., the MRI findings suggestive of infection

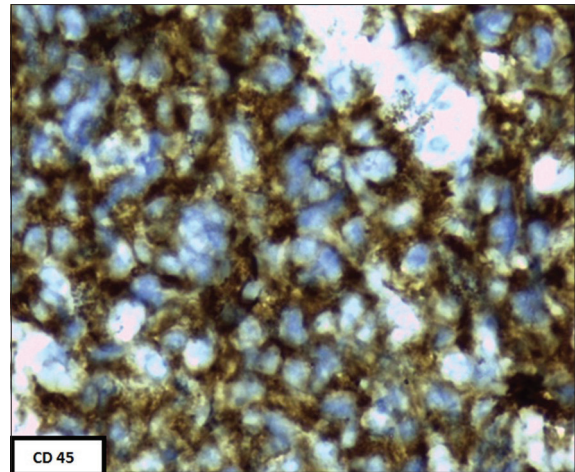


Figure 5: Photomicrograph of B-cell lymphoma showing CD20 positivity




Figure 6: Photomicrograph of B-cell lymphoma showing CD45 (leukocyte common antigen) positivity

and the histology report of chronic osteomyelitis at the initial presentation followed by Ewing sarcoma in the FNAC. Finally, incision biopsy and immunohistochemistry have confirmed the diagnosis. In the misdiagnosed case of lymphoma as osteomyelitis, their symptoms may be relieved probably due to the effects anti-inflammatory drugs. A similar incidence was reported before by Mika *et al.*¹ This could be the reason for the initial symptomatic improvement that our patient had. Commonly, lymphoma is expected to have a progressively worsening course, but one of the types of primary B-cell lymphoma has an indolent (slow-growing) course or has clinical regression. We believe our case might be of this variety.

This case highlights the definite role of immunohistochemistry in all cases of chronic osteomyelitis to rule out masquerading malignancies.

Conclusion

Non-Hodgkins lymphoma, chronic osteomyelitis, and Ewing sarcoma are the three condition which often

makes some diagnostic challenges. Immunohistochemistry (CD45[LCA] and CD20) is a very important tool in diagnosing a non-Hodgkins lymphoma. It is highly useful to differentiate it from the other two mimicking conditions. The patient's life and death depend on early diagnosis and treatment. Hence, biopsy and immunohistochemistry may be considered in all cases of chronic osteomyelitis which has any deviation from its normal course of the clinical presentation, progression, or unexpected histological/laboratory findings. There is no true recorded incidence of a lymphoma being misdiagnosed as chronic osteomyelitis and Ewing sarcoma in the literature, which makes this report even more significant.

Financial support and sponsorship

Nil.

Conflicts of interest

There are no conflicts of interest.

References

1. Mika J, Schleicher I, Gerlach U, Adler CP, Uhl M, Knoeller SM. Primary bone lymphomas thought to be osteomyelitis urgently demand a rapid diagnosis in bone pathology. *Anticancer Res* 2012;32:4905-12.
2. Giudici MA, Egli KD, Moser RP Jr., Roloff JS, Frauenhoffer EE, Kransdorf MJ. Case report 730. Malignant large cell lymphoma of tibial epiphysis. *Skeletal Radiol* 1992;21:260-5.
3. Cabanela ME, Sim FH, Beabout JW, Dahlin DC. Osteomyelitis appearing as neoplasms. A diagnostic problem. *Arch Surg* 1974;109:68-72.
4. Ganapathi M, Lake DN, Griffiths AP. Periprosthetic high-grade B-cell lymphoma complicating an infected revision total hip arthroplasty. *J Arthroplasty* 2001;16:229-32.
5. Irvani S, Singleton TP, Ross CW, Schnitzer B. Precursor B lymphoblastic lymphoma presenting as lytic bone lesions. *Am J Clin Pathol* 1999;112:836-43.
6. Plath T, Herzog K, Anagnostopoulos I. Manifestation of a highly malignant B-cell lymphoma simulating osteomyelitis of the mandible. *Mund Kiefer Gesichtschir* 1997;1:150-3.
7. Remadi S, Korbi S, Kuffer R. Malignant lymphoma of the mandible. *Ann Pathol* 1992;12:29-33.
8. Blum YC, Esterhai JL, Esmail AN, Lackman RD, Donthineni-Rao R. Lymphoma masquerading as infection. *Clin Orthop Relat Res* 2005;432:267-71.
9. Inaba T, Nishimura H, Saito J, Yamane Y, Yuasa S, Hosokawa Y, *et al.* A case of CD45-negative diffuse large B-cell lymphoma in thyroid gland. *Lab Hematol* 2008;14:12-4.
10. Cooper K, Leong AS. *Manual of Diagnostic Antibodies for Immunohistology*. 2nd ed. London: Greenwich Medical Media; 2003.
11. Ostrowski ML, Unni KK, Banks PM, Shives TC, Evans RG, O'Connell MJ, *et al.* Malignant lymphoma of bone. *Cancer* 1986;58:2646-55.