

Case Report

Fluorotic cervical compressive myelopathy, 20 years after laminectomy: A rare event

Praveen Kumar, AK Gupta¹, Shashank Sood, Ashok Kumar Verma

Departments of Radiodiagnosis and ¹Orthopaedic Surgery, GSVM Medical College, Kanpur, India

E-mail: *Praveen Kumar - pkpatelrld@yahoo.co.in; AK Gupta - guptadrakg@rediffmail.com; Shashank Sood - sood_shashank1@yahoo.co.in;
Ashok Kumar Verma - ashokve@gmail.com

*Corresponding author

Received: 4 October 10

Accepted: 6 October 10

Published: 24 January 11

Surg Neurol Int 2011, 2:11

This article is available from: <http://www.surgicalneurologyint.com/content/1/2/11>

Copyright: © 2011 Kumar P. This is an open-access article distributed under the terms of the Creative Commons Attribution License, which permits unrestricted use, distribution, and reproduction in any medium, provided the original author and source are credited.

This article may be cited as:

Kumar P, Gupta AK, Sood S, Verma AK. Fluorotic cervical compressive myelopathy, 20 years after laminectomy: A rare event *Surg Neurol Int* 2011;2:11
Available FREE in open access from: <http://www.surgicalneurologyint.com/text.asp?2011/1/2/76148>

Abstract

Background: Spinal cord compression in flourosis is a common complication. These complications are mainly due to compression of the spinal cord by thickening and ossification of posterior longitudinal ligament and ligamentum flavum. Surgical decompression is the treatment of choice for fluorotic spinal cord compression. The recurrence of spinal cord compression after surgical decompression in flourosis is a rare event.

Case Description: We are presenting a case of a 63-year-old man who belonged to Kanpur, an endemic fluorosis region in India, with symptoms of cervical cord compression cranial to the operative site, 20 years after laminectomy for cervical fluorotic myelopathy. Urinary and serum fluoride levels were elevated. The patient underwent a skeletal survey: computed tomography and magnetic resonance imaging of the cervical spine showed a postoperative defect of laminectomy, osteosclerosis, osteophyte formation, calcification of the intraosseus membrane in the forearm, thickening and ossification of the posterior longitudinal ligament at C1, thickening and ossification of the residual ligamentum flavum at C1/C2, and dural calcification at the C2 vertebral level and compressive myelopathy. The patient refused surgical decompression and was managed with tizanidine HCl (an antispasticity medicine), a sublingual single night dose, 8 mg for symptomatic relief.

Conclusion: The recurrence of spinal cord compression in the fluorotic spine 20 years after laminectomy is a very unusual event and hence the patient should be kept under observation for a long duration. This case report contributes to the literature associated with the management of fluorotic spine.

Key Words: Fluorosis, compressive myelopathy, laminectomy, magnetic resonance imaging, cervical

Access this article online

Website:

www.surgicalneurologyint.com

DOI:

10.4103/2152-7806.76148

Quick Response Code:



INTRODUCTION

Chronic fluoride intoxication (fluorosis) is endemic in areas where fluoride content is high in drinking

water. Endemic skeletal fluorosis is widely prevalent in India, China, and many countries around the world.^[20] Cases of endemic skeletal fluorosis have been reported primarily from Southern Rajasthan, Andhra Pradesh,

and Kanpur district of Uttar Pradesh in India.^[13] The primary manifestations of fluorosis are mottling of teeth, osteosclerosis, soft tissue calcification, and marginal bony overgrowth. The secondary effects include damage to the nervous system. Patients of fluorosis can be asymptomatic or present as severe crippling deformities, due to skeletal involvement and neurological compression. Symptoms range from mild motor and sensory loss to spastic paraplegia, and spastic quadriplegia with bladder and bowel incontinence.

CASE REPORT

We are reporting a case of a 63-year-old man, who hailed from the Kanpur district, Uttar Pradesh, India, an endemic fluorosis region. He presented with numbness and weakness in all four limbs 20 years back. Skeletal survey and computed tomography (CT) [Figure 4a] scan was done revealing osteosclerosis, cervical canal narrowing due to thickening and ossification of the posterior longitudinal ligament at the C2–C7 vertebral level, and was diagnosed as a case of compressive cervical myelopathy due to skeletal fluorosis. He underwent laminectomy at the C2–C7 level, with excision of the calcified ligamentum flavum and adequate decompression. The patient was relieved of symptoms. He was on serpentine 50 mg twice daily for 20 years.

Now, he presented with recurrence of symptoms. The weakness had increased in severity to the point that he was unable to sit or stand without support. There was no associated bladder or bowel dysfunction.

Higher mental functions and cranial nerves were intact. Motor examination revealed positive pyramidal signs and decreased power (4/5) in all four limbs without any atrophy/fasciculation. On sensory examination, pain, temperature, and joint position sense were impaired at C1 and C2 dermatomes areas.

Laboratory tests showed raised serum fluoride and urinary fluoride levels. However, complete blood count, erythrocyte sedimentation rate, electrolytes including calcium, magnesium and phosphorus were normal.

The patient underwent a skeletal survey, CT scan and magnetic resonance imaging (MRI) of the cervical spine. The skeletal survey showed osteosclerosis, postoperative changes of laminectomy at the C2–C7 vertebral level, large osteophyte formation, soft tissue calcification, and calcification of the interosseous membrane in the forearm [Figures 1-3]. CT scan revealed thickening and ossification of the posterior longitudinal ligament at the C1 level, thickening and ossification of the residual ligamentum flavum at C1/C2, and dural calcification at the C2 vertebral level, leading to dorsal thecal sac indentation with a residual canal space measuring 5.4 mm. A defect in posterior elements of the cervical

spine was seen suggestive of the previous laminectomy procedure [Figure 4b].

MRI revealed severe compression on the dorsal spinal cord at the C1 and C2 vertebral level with T2 hyperintensity in the cervical spinal cord suggestive of severe compressive myelopathy [Figure 5]. The patient was advised operative decompression, but he refused. He was on supportive management: tizanidine HCl (an antispasticity medicine), sublingual single night dose, 8 mg. Spasticity decreased significantly from the pretreatment level of grade 2 to grade 1 according to the modified Ashworth scale.^[3]

DISCUSSION

Fluorosis is a disease caused by an excessive intake of fluoride. Fluorosis is endemic in at least 25 countries across the world being more widespread in India and China.^[14] About 60 million Indians are living in about 200 districts of 20 states with high water fluoride levels and are at risk of developing fluorosis.^[15] The optimum upper safe limit for fluoride intake is not more than 6 mg per day.^[19] The possible predisposing factors include: (a) continued high fluoride exposure through water and food; (b) strenuous physical activity; (c) malnutrition with deranged renal function;^[6] and (d) abnormal concentrations of certain trace elements.

Fluorosis in humans predominantly has dental and skeletal manifestation. Dental fluorosis is an early and sensitive manifestation in children presenting as white chalky opacities or pitting on the enamel. It is seen only if the child has resided in the endemic area during the eruptive period of the teeth and it has been taken as an index of endemicity in epidemiological surveys.^[18] In the early stage of fluorosis, patients are asymptomatic or gastrointestinal symptoms may be present.

In the advanced stages, skeletal fluorosis causes crippling deformities and neurological complications. Neurological complications occur in 5–10% of cases of skeletal fluorosis.^[10] It is due to the compression of the spinal cord and nerve roots, and till date the evidence for direct neurotoxicity of fluoride is lacking. These features usually develop after exposure to a high fluoride content (greater than 4 parts per million [PPM]) for longer than 10 years.^[2]

Spinal cord involvement is common in the cervical region followed by thoracic and lumbar region.^[5] These complications are mainly due to the compression of the spinal cord and nerve roots by the protruding osteophytes, thickening of the posterior longitudinal ligament, and thickening of the ligamentum flavum resulting in compressive myeloradiculopathy, compressive myelopathy, and/or compressive radiculopathy.

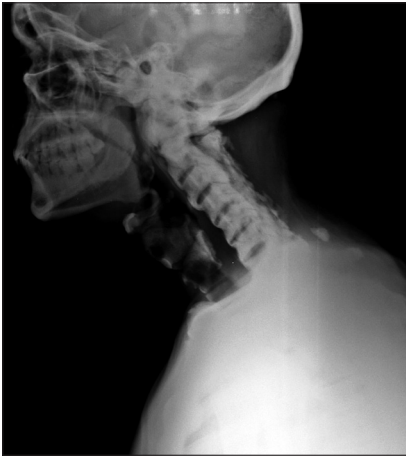

Figure 1: X-ray Cervical spine lateral view reveals- osteosclerosis with post op defect of laminectomy with ossification of interspinous ligament, anterior longitudinal ligament.

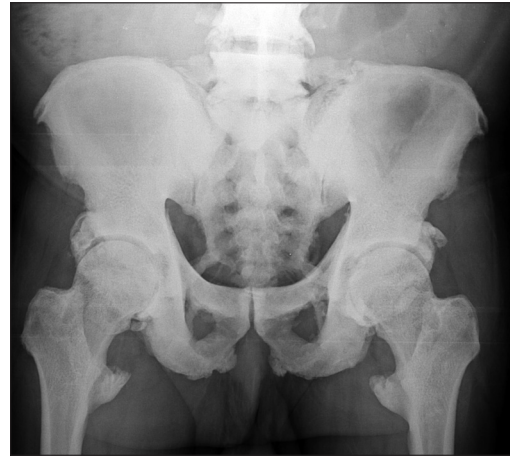

Figure 2: X-ray Pelvis AP view- reveals Osteosclerosis with ossification of sacrotuberous ligament, sacrospinous ligament, iliolumbar and lumbosacral ligaments and bony overgrowth at ligamentous attachment site.

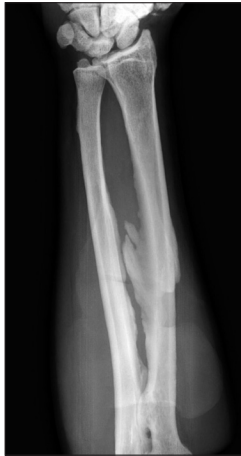

Figure 3: X-ray Left forearm AP reveals- Osteosclerosis with interosseous membrane calcification.

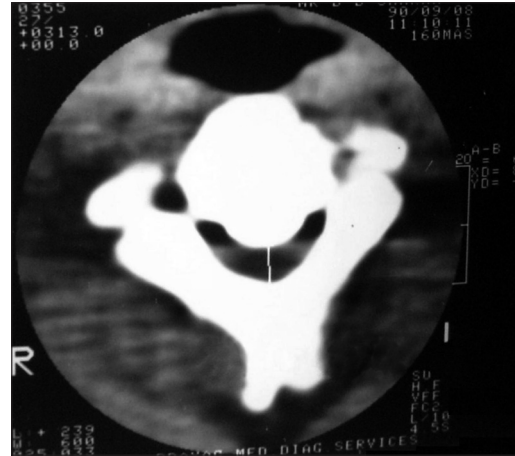


Figure 4a: Preoperative CT scan cervical Spine done 20 years back reveals – spinal canal narrowing due to thickening/ossification of posterior longitudinal ligament at C2 vertebral level

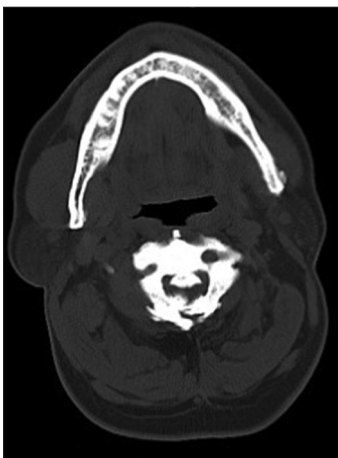


Figure 4b: Recent CT scan cervical spine reveals- Post op defect of laminectomy with recurrence of spinal canal narrowing due to thickening/ossification of ligamentum flavum and thickening/ossification of posterior longitudinal ligament at C2 vertebral level

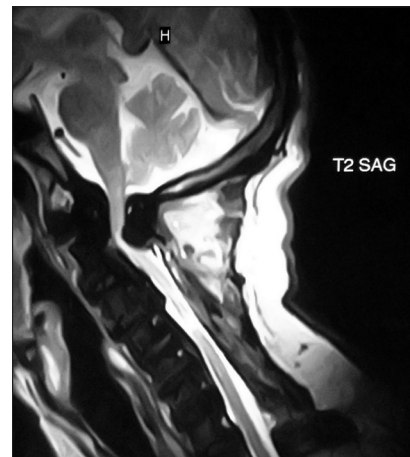


Figure 5: MRI cervical spine T2 sagittal images- hyperintensity in cervical cord at C1 and C2 vertebral level suggestive of compressive myelopathy

There is a linear relation between urinary fluoride levels and fluoride intake, and a 24-h sample of urine is a good indicator of the fluoride intake.^[7,8] The urinary fluoride level ranges from 0.1 to 2.0 PPM (average 0.4 PPM) whereas the fluoride content of drinking water is 0.3 PPM.^[8] The urinary level of fluorides varies between 0.68 and 7.80 PPM with a mean of 3.28 PPM in fluorosis patients.^[9] The bone fluoride content measures the extent of bone fluoride retention and varies between 6000 and 8400 PPM in bone ash against the normal value, 500–1000 PPM.

In skeletal fluorosis, technetium-labeled methylene diphosphonate (^{99m}Tc-MDP) bone scanning shows mostly a superscan appearance with a diffuse linear tracer activity along the ligamentous attachments.^[10]

Characteristic radiological changes of a fluorotic spine include osteophyte formation, calcification of ligaments, and ossification of the posterior longitudinal ligament and ligamentum flavum and sclerotic bone.^[17]

Gupta *et al.* reported that compressive myelopathy in fluorosis is due to thickening with the ossification of the posterior longitudinal ligament and ligamentum flavum.^[1]

Experiments showed that calcium, magnesium, and aluminum salts could reduce fluoride absorption and also increased its excretion from the body. Serpentine was used to increase fluoride excretion in human fluorosis with some success.^[11]

Prevention is the best possible approach to tackle fluorosis, since no cure at present is possible once disease sets in.^[12]

In fluorosis, the recurrence of compressive myelopathy can occur at different levels, but is an uncommon phenomenon. We are reporting a case of compressive myelopathy due to fluorosis, recurred cranial to a previous cervical laminectomy site, laminectomy done 20 years ago.

Mohindra *et al.* reported five patients of Indian origin with the ossification of the thoracic yellow ligament. Neurologic improvement followed decompressive laminectomy and excision of the ligamentum flavum though persistent spasticity due to irreversible changes within the cord was seen in some patients. One patient was followed up over a span of 10 years. Though the disease was progressive, no mention of recurrent compressive myelopathy had been made.^[4] The recurrence

of compression in fluorosis after 20 years has not been reported till date. In the present case, the recurrence of spinal cord compression was cranial (at the C1 and C2 vertebral level) due to thickening with the ossification of the posterior longitudinal ligament and ligamentum flavum, and dural calcification. We suggest that a patient with compressive fluorotic myelopathy following posterior decompression should be kept under observation for a long duration.

REFERENCES

- Gupta RK, Agarwal P, Kumar S, Surana PK, Lal JH, Misra UK. Compressive myelopathy in fluorosis: MRI. *Neuroradiology* 1996;38:338-42.
- Haimanot RT. Neurological complications of endemic skeletal fluorosis, with special emphasis on radiculo-myelopathy. *Paraplegia* 1990;28:244-51.
- MacKenzie CR, Charlson ME. Standards for the use of ordinal scales in clinical trials. *Br Med J* 1986;292:40-3.
- Mohindra S, Chhabra R, Mukherjee KK, Gupta SK, Vaiphei K, Khosla VK. Spinal compression due to ossified yellow ligament: A short series of 5 patients and literature review. *Surg Neurol* 2006;65:377-84.
- Naidu MR, Reddy DR, Reddy PK, Sastry Kolluri VR. Fluorotic cervical spinal cord disease. *Rev Chir Orthop Reparatrice Appar Mot* 1989;75:228-31.
- Naidu MR, Sastry KV, Reddy PK, Reddy DR. Skeletal fluorosis secondary to occult renal disease. *Fluoride* 1986;19:166-8.
- Reddy DR, Murthy JM, Rammohan S. Spinal cord studies in fluorotic dogs. *Fluoride* 1987;20:290-1.
- Reddy DR, Rammohan Rao MV, Murthy JM. Urinary fluoride excretion in skeletal fluorosis. *Fluoride* 1984;17:243-6.
- Reddy DR, Deme SR. Fluorosis. In: 'Neurology in tropics'. Chopra JS, Sawhney IM, editors. New Delhi: 1998. p. 82-92.
- Reddy DR, Prasad VS, Reddy JJ. *Neuroradiology of skeletal fluorosis*. Clin Neurosci Ann Acad Singapore 1993;22:493-500.
- Reddy DR. Trial of intravenous magnesium hydroxide in fluorosis. Proceedings of the symposium on fluorosis. October 1974. Indian academy of Geoscience, Hyderabad-India: 1977. p. 449-56.
- Reddy DR. Neurology of endemic skeletal fluorosis. *Neurol India* 2009;57:7-12.
- Singh VP. Fluoride disorders: Geological Linkages, Human Health and Preventive Measures. Proceedings: Workshop on Medical Geology, IGCP-454, GSI Special Publication no. 83, Nagpur, India: 2004. p. 118-22.
- Skeletal fluorosis in India and its relevance to the West. Fluoride Action Network. May 2004.
- Susheela AK. Fluorosis: An easily preventable disease through practice of interventions. Delhi: Fluorosis Research and Rural Development Foundation; 2005.
- Teotia M, Teotia SP, Kunwar KB. Endemic skeletal fluorosis. *Arch Dis Child* 1971;46:686-91.
- Teotia SP, Teotia M. Endemic skeletal fluorosis-clinical and radiological variants (Review of 25 years of personal research). *Fluoride* 1988;21:39-44.
- Teotia SP. Dental fluorosis. *Nat Med J India* 1999;12:96-8.
- World Health Organization. Environmental Health Criteria 227, Fluorides. Geneva: W.H.O.; 2002. p. 14-6.
- World Health Organization. Guidelines for drinking-water quality. Vol.2. Geneva: W.H.O.; 2nd ed, 1999.