

## Defining transposition: What have we learnt?

Max E. Roderick<sup>1,2\*</sup>, Nikita Maria<sup>1,2\*</sup>, Adrian Crucean<sup>1,2</sup>, John Stickley<sup>1</sup>, David J. Barron<sup>1</sup>, Robert H. Anderson<sup>1</sup>

<sup>1</sup>Department of Paediatric Cardiac Surgery, Birmingham Children's Hospital, Birmingham, United Kingdom, <sup>2</sup>Institute of Clinical Sciences, University of Birmingham, Birmingham, United Kingdom

\*Joint first authorship

### ABSTRACT

Understanding transposition is important for all who hope to effectively treat patients with the condition. The variants of the condition are frequently debated in the literature. We describe an unusual variant of transposition, in which despite the arterial roots being supported by morphologically inappropriate ventricles, the roots themselves were normally related, with the intrapericardial arterial trunks spiraling as they extended into the mediastinum. The specimen was identified following the re-categorization of our archive, and we subsequently conducted a detailed analysis of the underlying morphology. Using the principles of sequential segmental analysis, we compared the morphology with standard examples previously described. We show how it was the recognition of such hearts that promoted that concept that the combination of connections across the atrioventricular and ventriculo-arterial junctions was the essence of transposition. In the most common variant, the arrangements are concordant at the atrioventricular junctions, but discordant at the ventriculo-arterial junctions. We suggest that the overall arrangement of discordant ventriculo-arterial connections is best described simply as "transposition." When the discordant ventriculo-arterial connections are combined with similarly discordant connections at the atrioventricular junctions, the transposition is congenitally corrected. We point out that the use of "d" and "l" as prefixes does not distinguish between transposition and its congenitally corrected variant. For those using segmental notations, the correct description for the rare variant found in the setting of a posteriorly located aortic root with the usual atrial arrangement is transposition (S, D, NR).

**Keywords:** Arterial relationships, discordant ventriculo-arterial connections, infundibular morphology, posterior transposition, ventriculo-arterial junctions

### DESCRIPTION OF SPECIMEN

This heart specimen has the usual atrial arrangement and normal venoatrial connections. The intrapericardial arterial trunks are normally arranged, with the aortic root positioned posteriorly and rightward relative to the pulmonary root. The arterial trunks then spiral as they extend into the mediastinum [Figure 1].

The ventricular mass has right-handed topology, but surprisingly, the right-sided aortic root is supported exclusively by the right-sided morphologically right

ventricle [Figure 2 – left hand panel]. The anterosuperior leaflet of the tricuspid valve is separated from the leaflets of the aortic valve by the right-sided ventriculo-infundibular fold. The fold, however, is attenuated in the septal aspect of the roof of the right ventricle, where there is fibrous continuity between the leaflets of the aortic and mitral valves in the roof of a ventricular septal defect. The defect opens into the outlet of the right ventricle between the limbs of the septomarginal trabeculation. The pulmonary root, supported by a completely muscular infundibulum,

This is an open access journal, and articles are distributed under the terms of the Creative Commons Attribution-NonCommercial-ShareAlike 4.0 License, which allows others to remix, tweak, and build upon the work non-commercially, as long as appropriate credit is given and the new creations are licensed under the identical terms.

**For reprints contact:** WKHLRPMedknow\_reprints@wolterskluwer.com

**How to cite this article:** Roderick ME, Maria N, Crucean A, Stickley J, Barron DJ, Anderson RH. Defining transposition: What have we learnt?. *Ann Pediatr Card* 2021;14:63-6.

#### Access this article online

Quick Response Code:



Website:

www.annalspc.com

DOI:

10.4103/apc.APC\_181\_19

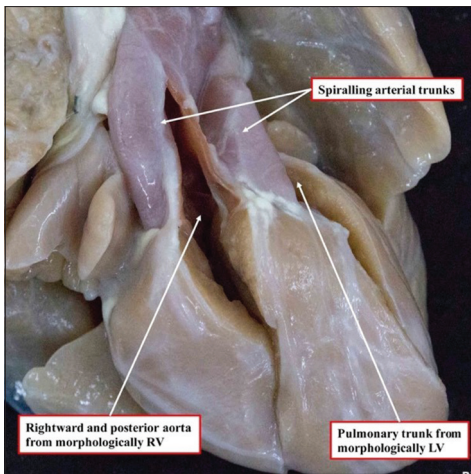
**Address for correspondence:** Dr. Adrian Crucean, Department of Paediatric Cardiac Surgery, Birmingham Women's and Children's Hospital, Steelhouse Lane, Birmingham, B4 6NH, England, UK. E-mail: adrian.crucean@nhs.net

Submitted: 28-Nov-2019

Revised: 21-Feb-2020

Accepted: 04-Aug-2020

Published: 23-Sep-2020



**Figure 1: (original) The heart is viewed from the front, in attitudinally appropriate fashion. The arterial roots are normally related, with the aortic root positioned posteriorly and rightward relative to the pulmonary root. The intrapericardial trunks spiral as they extend into the mediastinum (RV: Right ventricle, LV: Left ventricle)**

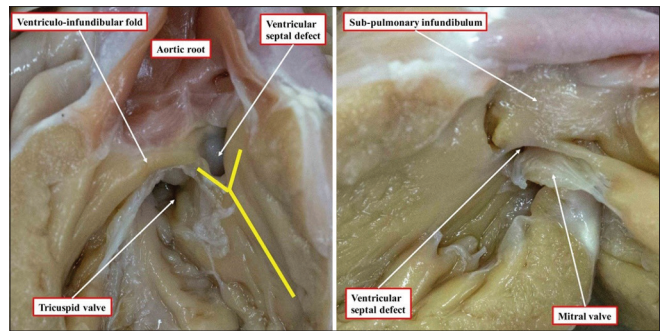
arises exclusively from the morphologically left ventricle [Figure 2 – right hand panel]. This means that, despite the relationships of the arterial roots, the ventriculo-arterial connections are discordant. The margins of the ventricular septal defect are shown in greater detail in Figure 3. The right hand panel of this figure shows the completely muscular infundibulum supporting the origin of the pulmonary trunk from the morphologically left ventricle.

The coronary arteries arise from the sinuses of the aortic root adjacent to the pulmonary root. The left-handed adjacent sinus gives rise to the main stem of the left coronary artery, which passes behind the pulmonary root before branching into the circumflex and anterior interventricular arteries. The right-handed sinus gives rise to the right coronary artery.

The ventricular septal defect has unique features when assessed from the aspect of the morphologically right ventricle. Although its roof is fibrous, made up of continuity between the leaflets of the aortic and mitral valves, the remaining rims are exclusively muscular, with the caudal limb of the septomarginal trabeculation fusing posteroinferiorly with the ventriculo-infundibular fold [Figure 3]. There is no continuity, however, between the leaflets of the aortic and pulmonary valves because of the completely muscular subpulmonary infundibulum. The defect, therefore, is neither perimembranous nor doubly committed, but has a muscular posteroinferior rim (with an intact membranous septum), which would have protected the atrioventricular conduction axis [Figure 3].

## DISCUSSION

It is now almost half a century since a significant polemic occurred regarding the appropriate definition

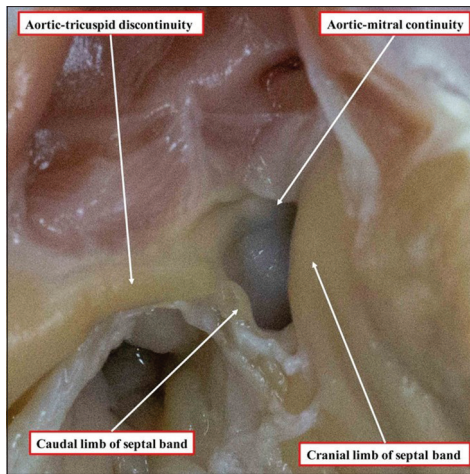


**Figure 2: (original) Views from the right-sided morphologically ventricle (left image) and from the left-sided morphologically left ventricle (right image)**

for “transposition.”<sup>[1,2]</sup> This centered on a small series of cases in which, although the arterial trunks originated from morphologically inappropriate ventricles, the roots themselves were “normally related,” with the intrapericardial arteries spiraling into the mediastinum.<sup>[3]</sup> At that time, to diagnose “transposition,” in other words discordant ventriculo-arterial connections, it was also the rule to expect the aorta to be positioned anteriorly relative to the pulmonary trunk, and for the aortic valve to be supported above the morphologically right ventricle by a completely muscular infundibulum.<sup>[4]</sup> Many pediatric cardiologists, at that time, considered any heart having an anterior aorta to demonstrate “transposition.” Hence, many would describe “double outlet right ventricle with transposition” when both arterial trunks arose from the morphologically right ventricle, but with an anterior aortic root. This approach was also taken for the so-called “anatomically corrected” variant, where the aorta, despite being located anteriorly, originated from the morphologically left ventricle, with the pulmonary trunk originating from the morphologically right ventricle.<sup>[5]</sup>

Despite significant progress having been made since then, problems remain. Jagers *et al.*<sup>[6]</sup> refer to the major advances made by Van Praagh *et al.*<sup>[3]</sup> in understanding abnormal ventriculo-arterial connections. In their landmark description of the implications of the posteriorly located aorta arising from the morphologically right ventricle, Van Praagh *et al.* stated that “transposition of the great arteries is a relation, not an entity.”<sup>[3]</sup> This is surprising, since it was their account itself which established the origin of the arterial trunks from inappropriate ventricles as the essence of transposition. Jagers *et al.*,<sup>[6]</sup> however, following Van Praagh, then described transposition in terms of “alignments.”

For hearts having discordant ventriculo-arterial connections, we had suggested the most common patterns could be distinguished in terms of “complete” rather than “congenitally corrected.”<sup>[7]</sup> As correctly pointed out by Jagers *et al.*,<sup>[6]</sup> all examples with discordant ventriculo-arterial connections are “complete.” This is because “complete” had initially been used to distinguish



**Figure 3: (original).** The magnified view of the ventricular septal defect shows the muscular posteroinferior margins as seen from the right ventricle, but the presence of fibrous continuity between the leaflets of the aortic and mitral valves in the roof of the defect

transposition itself from double outlet right ventricle, previously described as “partial” transposition. As set out by Jagers *et al.*,<sup>[6]</sup> the logic is unquestionable. We would now argue, nonetheless, that the default option for use of “transposition” is simply the combination of concordant atrioventricular and discordant ventriculo-arterial connections.

We continue to question whether it is satisfactory to distinguish this variant from the congenitally corrected version using the terms “d-transposition” as opposed to “l-transposition.” During our recent examination of a large series of autopsied hearts having discordant ventriculo-arterial connections, comparisons were made with the large cohort of patients who have undergone the arterial switch procedure at this hospital. In both series, we encountered patients with the segmental combination of transposition (S, D, L). Among our surgical cohort, we also encountered patients having transposition (I, L, L). In all of these patients, the transposition was properly described as being “L-transposition,” yet was not congenitally corrected. Perhaps surprisingly, no patient with “posterior transposition” was found in this large series of patients undergoing the arterial switch procedure. Nor is such a patient cited in the recent large study reported from Poland.<sup>[8]</sup> Could it be, therefore, that posterior transposition goes unnoticed in the clinical setting? There are very few case reports<sup>[9,10]</sup> since the descriptions offered by Van Praagh *et al.*<sup>[3]</sup> and the subsequent description of a series by Wilkinson *et al.*<sup>[11]</sup>

It was the hearts with normally related arterial trunks that prompted Van Praagh *et al.* to promote the ventricular origin of the arterial trunks as the defining feature of “transposition.”<sup>[3]</sup> It is perhaps unfortunate that he and his followers subsequently chose to describe the union of the chambers and the arterial trunks in

terms of “alignments,” rather than “connections.” The argument being that the ventricular outlet components or “conuses,” are interposed between the ventricles and the arterial trunks. This approach, however, fails to recognize that the infundibulum is an integral part of the ventricular mass. In “posterior” transposition, the alignments of the arterial roots suggest the ventriculo-arterial junctions are concordant. In reality, the connections are discordant, with the entirety of both arterial roots supported exclusively by morphologically inappropriate ventricles [Figure 2].

It is the use of the prefix “d” to describe transposition, nonetheless, which creates the greatest problem with nomenclature. With posterior transposition, the arterial roots are normally related. Hence, it is inappropriate to use “d” to describe this arrangement, although this is common with recent descriptions.<sup>[9,10]</sup> The hearts show right-handed ventricular topology, so the appropriate segmental description is transposition (S, D, NR). It is also inappropriate to use “l-transposition” as synonymous with congenitally corrected transposition.<sup>[7]</sup> How, then, can we best describe the significant variants of transposition? We now suggest that it is sufficient to use “transposition” simply to describe the combination of concordant atrioventricular and discordant ventriculo-arterial connections. The variant associated with discordant atrioventricular connections is then well described as being congenitally corrected. The other variants require full segmental description so as fully to do them justice.

#### Financial support and sponsorship

Nil.

#### Conflicts of interest

There are no conflicts of interest.

#### REFERENCES

1. Van Mierop LH. Transposition of the great arteries. I. Clarification or further confusion? *Am J Cardiol* 1971;28:735-8.
2. Van Praagh R. Transposition of the great arteries. II. Transposition clarified. *Am J Cardiol* 1971;28:739-41.
3. Van Praagh R, Perez-Trevino C, López-Cuellar M, Baker FW, Zuberbuhler JR, Quero M, *et al.* Transposition of the great arteries with posterior aorta, anterior pulmonary artery, subpulmonary conus and fibrous continuity between aortic and atrioventricular valves. *Am J Cardiol* 1971;28:621-31.
4. Grant RP. Morphogenesis of transposition of the great vessels. *Circulation* 1962;26:819-40.
5. van Praagh R, van Praagh S. Anatomically corrected transposition of the great arteries. *Br Heart J* 1967;29:112-9.
6. Jagers JJ, Cameron DE, Herlong JR, Ungerleider RM. *Congenital Heart Surgery Nomenclature and Database*

- Project: Transposition of the great arteries. *Ann Thorac Surg* 2000;69:S205-35.
7. Becker AE, Anderson RH. How should we describe hearts in which the aorta is connected to the right ventricle and the pulmonary trunk to the left ventricle? *Am J Cardiol* 1983;51:911-2.
  8. Moll M, Michalak KW, Sobczak-Budlewska K, Moll JA, Kopala M, Szymczyk K, *et al.* Coronary Artery Anomalies in Patients With Transposition of the Great Arteries and Their Impact on Postoperative Outcomes. *Ann Thorac Surg* 2017;104:1620-8.
  9. Tam S, Murphy JD, Norwood WI. Transposition of the great arteries with posterior aorta. Anatomic repair. *J Thorac Cardiovasc Surg* 1990;100:441-4.
  10. Benatar A, Antunes MJ, Levin SE. Posterior d-transposition of the great arteries with an unusual form of aortic obstruction. *Pediatr Cardiol* 1990;11:170-2.
  11. Wilkinson JL, Arnold R, Anderson RH, Acerete F. 'Posterior' transposition reconsidered. *Heart* 1975;37:757-66.