

## Clinical Report

# Allograft adenovirus nephritis

Kirsty Rady<sup>1\*</sup>, Giles Walters<sup>1</sup>, Michael Brown<sup>2</sup> and Girish Talaulikar<sup>1</sup>

<sup>1</sup>Department of Nephrology, The Canberra Hospital, Canberra, ACT, Australia and <sup>2</sup>Department of Pathology, The Canberra Hospital, Canberra, ACT, Australia

\*Correspondence and offprint requests to: Kirsty Rady; E-mail: kirstyrady@hotmail.com

### Abstract

We present an uncommon case of allograft adenovirus tubulointerstitial nephritis in a 63-year-old male 6 weeks following cadaveric renal transplantation for end-stage renal failure secondary to hypertensive nephrosclerosis. The patient presented with acute onset of fevers, dysuria, haematuria and diarrhoea with acute graft dysfunction. A renal biopsy demonstrated necrotizing tubulointerstitial nephritis with viral cytopathic changes and no evidence of rejection. Adenovirus was identified as the pathogen. Treatment involved the reduction in the patient's usual immunosuppression, intravenous immunoglobulin, piperacillin–tazobactam and ganciclovir. We present the clinical and pathological findings of necrotizing adenoviral nephropathy, highlighting the importance of considering this diagnosis in renal transplant recipients presenting with interstitial nephritis in the setting of a systemic illness.

**Keywords:** adenovirus; nephritis; renal; transplant

### Background

With the rising number of solid organ transplantations worldwide, and the subsequent growing population of immunosuppressed patients, we treat an increasing number of opportunistic infections [1, 2]. Viral pathogens are a common cause in renal transplant recipients, complicating the course and possibly compromising allograft survival.

Adenoviruses are a family of double-stranded DNA viruses that readily infect human epithelial cells exhibiting a characteristic cytopathic effect. While most infections associated with adenoviruses are self-limiting, those occurring in immunocompromised hosts can be more severe, or even fatal [3]. The most common urologic manifestation of adenovirus infection in adults is haemorrhagic cystitis [2, 4]. In the immunocompromised patient, adenovirus, specifically subgroup B types 11, 34 and 35, has been shown to cause both haemorrhagic cystitis and tubulointerstitial nephritis [2, 5]. Although more commonly caused by human polyoma viruses, there have been multiple case reports of adenovirus-related renal allograft tubulointerstitial nephritis over the past 30 years.

In this report we present the clinical and pathological findings of necrotizing adenoviral nephropathy and highlight the importance of considering this diagnosis in renal transplant recipients presenting with interstitial nephritis in the setting of a systemic infective illness.

### Case presentation

A 63-year-old male with a background of end-stage renal failure secondary to hypertensive nephrosclerosis underwent

a deceased donor renal transplant in June 2013. The patient was sensitized with a five-antigen mismatch and cytomegalovirus (CMV) sero-discordance with donor-positive and recipient-negative status. His course was initially complicated by difficult surgery and intra-operative hypotension associated with a supraventricular tachycardia, requiring a brief ICU admission, and temporary dialysis in the initial post-operative period. There was a long ischaemic time with delayed graft function. Induction immunosuppression consisted of basiliximab and methylprednisolone, and maintenance immunosuppression included mycophenolate mofetil 1 g BD, tacrolimus 6 mg BD and prednisolone 12.5 mg daily. His tacrolimus level at this admission was 13.2 µg/L, within the expected range (10–20) in the initial 3 months post-transplantation. His postoperative CMV prophylaxis consisted of valganciclovir three times weekly.

The patient's medical history includes hypertension, dyslipidaemia, hyperparathyroidism, gastro-oesophageal reflux disease and depression.

The patient was admitted to hospital 6 weeks post-transplant with acute onset of fevers, dysuria, haematuria and diarrhoea in the setting of acute graft dysfunction. The patient was commenced on a broad-spectrum antibiotic and an antiviral. His immunosuppression was also reduced, with his tacrolimus decreased to 5 mg BD on the day of admission and mycophenolate reduced to 500 mg BD the following day. Over the subsequent days, the tacrolimus was further reduced to 3 mg BD and the mycophenolate to 360 mg BD.

On admission, urinalysis was positive for leukocytes, erythrocytes and proteinuria. Stool microscopy and culture were unremarkable. The allograft function continued to

deteriorate over the initial stages of admission from his baseline creatinine of 150  $\mu\text{mol/L}$ , peaking at 300  $\mu\text{mol per L}$ . Ultrasound on admission did not demonstrate any hydronephrosis. However, on imaging there was a suspicion of extrusion of the ureteric stent placed during transplantation. This was later removed with no change in the patient's condition. A subsequent diethylene triamine pentaacetic acid scan was suggestive of impaired function of the graft with delayed emptying of the collecting system, but no scintigraphic evidence of obstruction.

An allograft biopsy demonstrated necrotizing tubulointerstitial nephritis of viral aetiology, and adenovirus was identified in the necrotic epithelial cells by PCR. In addition, visualization under electron microscopy demonstrated viral particles of a diameter of 75 nm, consistent with adenovirus (Figs 1 and 2). Immunostaining was not performed. Urine cytology demonstrated necrotic debris, reactive squamous cells and degenerate cells with nuclei showing features of probable viral cytopathic effect. Viral PCR performed on the urine was also positive for adenovirus and negative for cytomegalovirus, BK virus and herpes simplex virus Types 1 and 2 (Fig. 3).

The patient was treated with intravenous piperacillin-tazobactam to cover possible bacterial infection, intravenous immunoglobulin (IVIG) (a total of 32 g in five divided doses) and was commenced on ganciclovir pending CMV

PCR. His renal function improved on this treatment regime, with a fall in his creatinine to 167 at the time of discharge. The patient remained well with stable renal function on clinic follow-up 1 month post-discharge.

## Discussion

This report describes a case of necrotizing tubulointerstitial allograft nephritis due to adenovirus infection. Our patient presented 6 weeks post-transplant with typical symptoms of fever, dysuria, haematuria and diarrhoea in the setting of acute graft dysfunction. On review of the literature, a significant proportion of patients presented within 8 months of transplant with gross haematuria, dysuria, fever and acute renal failure [4–9]. Other less common presentations have been described, including obstructive uropathy and adenovirus nephritis associated with an inflammatory renal mass [4, 5].

While the optimal investigative strategy remains to be defined, conventionally, the diagnosis of adenoviral infection has been made by obtaining positive viral culture from blood, urine or tissue, the sensitivity of which has increased with the use of PCR assays [4, 10]. In our patient, adenovirus was detected on urine PCR and in the renal allograft. Adenovirus PCR was not performed on blood. In order to obtain a conclusive diagnosis, a renal biopsy with typical cytopathic changes is required [4, 10, 11]. Detection of viral DNA in the urine is non-specific and often represents asymptomatic urinary viral shedding. However, in our patient the clinical signs together with the histopathological changes were highly suggestive of active infection (Fig. 4).

A renal allograft biopsy is also essential to differentiate adenoviral nephritis from that of acute rejection or other pathology. Typical pathological findings in adenovirus nephropathy include tubular cell necrosis associated with severe interstitial inflammation and viral cytopathic effects including peripheral condensed chromatin, basophilic nuclear inclusions and nuclear enlargement [12]. Immunoperoxidase staining is subsequently employed to confirm the presence of adenovirus within the tissue. These viral particles within the tubular epithelial cells are visible under electron microscopy.

Given the rarity of this condition, standard treatment guidelines are yet to be developed. Therefore, in approaching

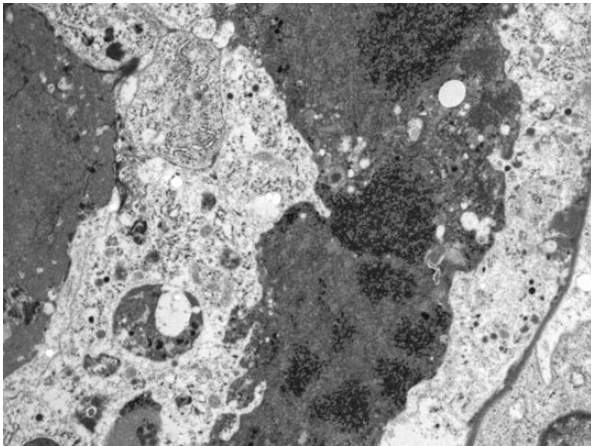


Fig. 1. Adenoviral particles on electron microscopy.

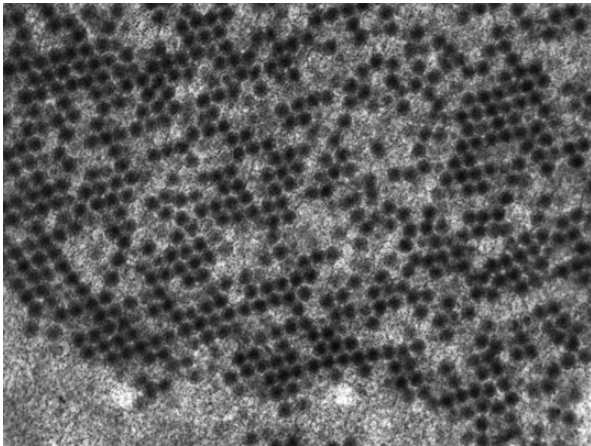


Fig. 2. Adenoviral particles at high power.

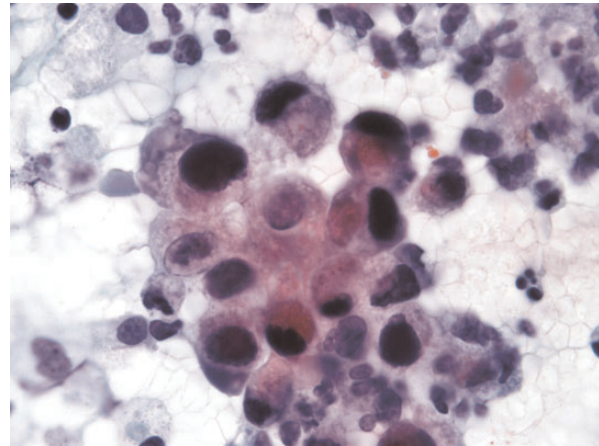
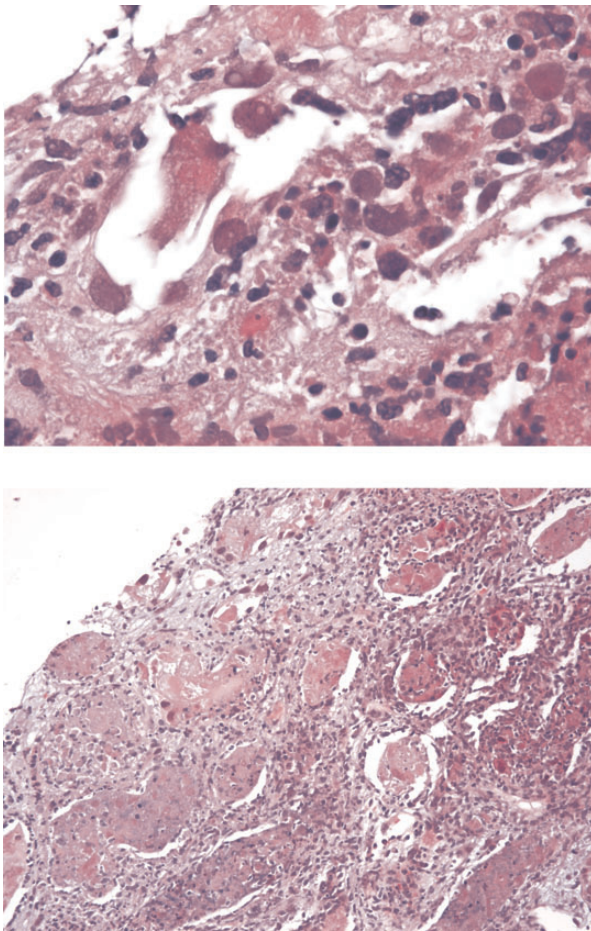


Fig. 3. Viral cytopathic changes identified in urine cytology.





**Fig. 4.** Renal biopsy demonstrated widespread tubular damage with necrosis and a patchy but severe interstitial infiltrate.

the treatment of our patient, general principles of management were implemented, including the reduction of immunosuppression, commencement of antiviral treatment for common infections (particularly CMV) and IVIG.

There is limited literature on the optimal treatment of adenovirus nephritis. Furthermore, the role of antiviral therapy remains uncertain, with no particular therapy having proven clinical effect against this virus [10, 12]. Antiviral therapy also conveys a real risk of nephrotoxicity, which must be considered. There are data to support the use of ribavirin, cidofovir and immunoglobulin preparations, particularly in patients with hypogammaglobulinaemia who are at increased risk of severe opportunistic infections. Of note, our patient was on a mycophenolate-containing immunosuppressive regime, which is theoretically prone to inducing hypogammaglobulinaemia [12, 13]. It is well documented that T-cell-mediated immunity is essential in the immune response to adenoviral infection [12], and thus reduction in immunosuppression is vital in the treatment of this infection. There remains a paucity of data relating to particular immunosuppressive regimes and appropriate dosing schedules, which allow for optimal viral clearance with maintenance of anti-rejection effect.

Our patient responded rapidly to the treatment regime, with a significant and sustained improvement in his renal function. The two components of treatment that likely had the greatest contribution to his improvement are first,

reduction of his immunosuppression, and secondly the administration of IVIG. Another possible contributing factor was the administration of ganciclovir, which was given prior to the final biopsy results to provide cover for possible CMV infection. The role of ganciclovir is uncertain; however, there are case reports suggesting possible effect in the setting of adenovirus nephritis [3, 5, 14].

Cidofovir is another antiviral showing promise in both *in vitro* and *in vivo* studies [10, 15–17]. Cidofovir, a nucleoside analogue, has been shown to have a broad spectrum of antiviral activity against polyomaviruses, papillomaviruses, poxviruses, herpesviruses, retroviruses and all serotypes of adenovirus in *in vitro* studies [17]. The virologic and clinical efficacy of cidofovir has been demonstrated in animal models and despite the lack of randomized trials in humans there is growing evidence from case reports and retrospective data demonstrating lower mortality rates from adenoviral infections in patients treated with this antiviral [10, 17]. Unfortunately, cidofovir can cause significant nephrotoxicity, in addition to haematologic and ocular toxicity [10], which may limit its use in this setting. However, a new lipid conjugate of cidofovir, which seems to be less nephrotoxic, is currently in trials and may be a favourable alternative when available [10].

It is evident that there are many areas of uncertainty with regard to clinical presentation, diagnosis and optimal management strategies in the context of adenovirus nephropathy. While the mainstay of treatment remains the reduction in immunosuppression, the role of various antivirals, particularly ganciclovir in the case of our patient, and cidofovir need further focused investigation. The numerous case reports in renal transplant recipients highlight the need for a better understanding of the natural history and risk factors for this infection.

In summary, this case highlights the importance of considering adenovirus as a potential pathogen in any renal transplant patient presenting with interstitial nephritis in the setting of a systemic infective illness. In addition, it supports the role of early allograft biopsy for histological diagnosis in order to implement appropriate treatment and reduction in immunosuppression. This case also identifies the need for further evaluation of appropriate antiviral therapy, particularly investigation of the possible role of ganciclovir and the emerging role of cidofovir.

### Patient consent

Informed consent has been obtained from the patient on which this report is based.

### Authors' contribution

K.R. participated in the writing and review of the paper; G.W. participated in writing and review of the paper. M.B. participated in preparation of figures and review of the paper. G.T. participated in review of the paper.

*Acknowledgements.* There are no acknowledgements.

*Conflict of interest statement.* No conflict of interest. The results presented in this paper have not been published previously in whole or part, except in abstract form.

## References

1. Asim M, Chong-Lopez A, Nickleit V. Adenovirus infection of a renal allograft. *Am J Kidney Dis* 2003; 41: 696–702
2. UpToDate. Epidemiology and clinical manifestations of adenovirus infections [Internet], 2013. <http://www.uptodate.com>
3. Duggan JM, Farrehi J, Duderstadt S et al. Treatment with ganciclovir of adenovirus pneumonia in a cardiac transplant patient. *Am J Med* 1997; 103: 439–440
4. Kolankiewicz L, Pullman J, Raffield M et al. Adenovirus nephritis and obstructive uropathy in a renal transplant recipient: case report and literature review. *Nephrol Dial Transplant* 2010; 3: 388–392
5. Lim AKH, Parsons S, Ierino F. Adenovirus tubulointerstitial nephritis presenting as a renal allograft space occupying lesion. *Am J Transplant* 2005; 5: 2062–2066
6. Emovon OE, Chavin J, Rogers K et al. Adenovirus in kidney transplantation: an emerging pathogen. *Transplantation* 2004; 77: 1474–1475
7. Gaspert A, Luthi B, Mueller NJ et al. Subacute allograft failure with dysuria and haematuria in a kidney transplant recipient. *Am J Kidney Dis* 2009; 54: 154–158
8. Hensley JL, Sifri CD, Cathro HP et al. Adenoviral graft-nephritis: case report and review of the literature. *Transpl Int* 2009; 22: 672–677
9. Barraclough K, Oliver K, Playford EG et al. Life-threatening adenovirus infection in a kidney transplant recipient. *Nephrol Dial Transplant* 2009; 2: 250–253
10. Ison MG. Adenovirus infections in transplant recipients. *Clin Infect Dis* 2006; 43: 331–339
11. Ison MG. Adenovirus in solid organ transplant recipient. *Am J Transplant* 2009; 9: S161–S165
12. Florescu M, Miles C, Florescu D. What do we know about adenovirus in renal transplantation? *Nephrol Dial Transplant* 2013; 28: 2003–2010
13. Keven K, Sahin M, Kutlay S et al. Immunoglobulin deficiency in kidney allograft recipients: comparative effects of mycophenolate mofetil and azathioprine. *Transpl Infect Dis* 2003; 5: 181–186
14. Chen FE, Liang RH, Lo JY et al. Treatment of adenovirus-associated haemorrhagic cystitis with ganciclovir. *Bone Marrow Transpl* 1997; 20: 997–999
15. Ljungman P, Ribaud R, Eyrich M et al. Cidofovir for adenovirus infections after allogeneic hematopoietic stem cell transplantation: a survey by the Infection Diseases Working Party of the European Group for Blood and Marrow Transplantation. *Bone Marrow Transplant* 2003; 31: 481–486
16. Nagafuji K, Aoki K, Henzan H et al. Cidofovir for treating adenoviral hemorrhagic cystitis in hematopoietic stem cell transplant recipients. *Bone Marrow Transplant* 2004; 34: 909–914
17. Josephson MA, Williams JW, Chandraker A et al. Polyomavirus-associated nephropathy: update on antiviral strategies. *Transpl Infect Dis* 2006; 8: 95–101

Received for publication: 5.1.14; Accepted in revised form: 19.2.14