

# Incidence of Remote Cerebellar Hemorrhage in Patients with a Dural Tear during Spinal Surgery: A Retrospective Observational Analysis

Daisuke Numaguchi<sup>1)</sup>, Keiji Wada<sup>2)</sup>, Mitsuru Yui<sup>2)</sup>, Ryo Tamaki<sup>2)</sup> and Ken Okazaki<sup>2)</sup>

1) Department of Orthopedics Surgery, Tomei Atsugi Hospital, Kanagawa, Japan

2) Department of Orthopedics Surgery, Tokyo Women's Medical University, Tokyo, Japan

## Abstract:

**Introduction:** The incidence of remote cerebellar hemorrhage (RCH) in patients with a dural tear during spinal surgery is unclear. The purpose of this study was to determine the incidence of RCH and the causative factors in these patients.

**Methods:** Two hundred and thirty-nine patients underwent spinal surgery at our institution between March 2015 and September 2016. Eleven of these patients needed dural suturing intraoperatively. All patients underwent CT of the head on the first postoperative day and were categorized according to whether they had RCH or not. The mean values for the amount of intraoperative bleeding, maximum perioperative blood pressure, postoperative drainage volume, and complaints of headache during the first 24 h postoperatively were compared between the two groups using the Welch's two-sample *t*-test and Fisher's exact test. The follow-up duration was 12 months.

**Results:** There were four patients in the RCH group and seven in the non-RCH group. The incidence of RCH was 36.4%. There were three cerebellar hemorrhages and one interhemispheric fissure hemorrhage in the RCH group. The mean intraoperative bleeding volume was 284 mL in the RCH group and 569 mL in the non-RCH group. The mean respective values for maximum perioperative blood pressure and postoperative drainage volume were 132 mmHg and 547 mL in the RCH group and 144 mmHg and 567 mL in the non-RCH group; none of the differences was statistically significant. However, complaints of headache in the first 24 h postoperatively were significantly more common in the RCH group than in the non-RCH group (100% vs. 14.3%;  $p = 0.01$ ). All patients with intracranial bleeding had recovered 3 months after surgery.

**Conclusions:** The incidence of RCH following a dural tear during spinal surgery was 36.4%. There was a significant association between RCH and increased reporting of headache during the first 24 h postoperatively.

## Keywords:

remote cerebellar hemorrhage, dural tear, spine surgery

Spine Surg Relat Res 2019; 3(2): 141-145  
dx.doi.org/10.22603/ssrr.2018-0019

## Introduction

Supratentorial subdural hematoma is a well-known complication following cerebral surgery, but remote cerebellar hemorrhage (RCH) caused by spinal surgery is less common. The pathologic mechanism that accounts for RCH is unclear, but an interventional or post-interventional loss of cerebrospinal fluid (CSF) seems to be involved in most cases<sup>1,2)</sup>. Furthermore, the exact incidence of remote intracranial hemorrhage after spinal surgery is not known because computed tomography (CT) of the head is not routinely per-

formed postoperatively. Therefore, we performed CT of the head in a series of patients who required intraoperative dural sutures to determine the incidence of RCH. Here, we report on four patients who developed RCH following intraoperative suturing of a dural tear and discuss the possible causative factors.

## Materials and Methods

The study was approved by our institutional review board, and written informed consent was obtained from all patients.

Corresponding author: Daisuke Numaguchi, numaguchidaisuke@gmail.com

Received: April 12, 2018, Accepted: July 3, 2018, Advance Publication: August 25, 2018

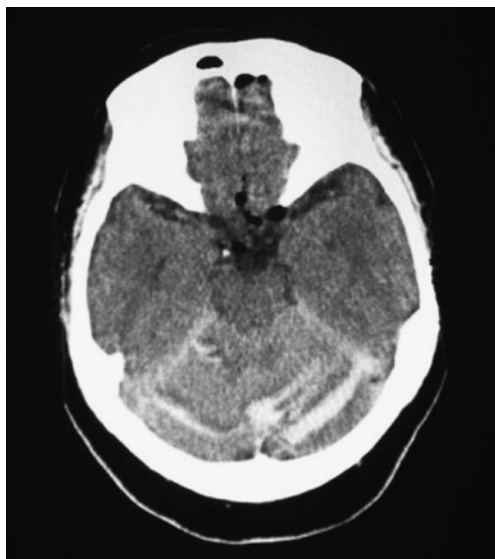Copyright © 2019 The Japanese Society for Spine Surgery and Related Research

Spinal surgery was performed in 239 patients in our department between March 2015 and September 2016. Eleven of these patients needed intraoperative suturing of a dural tear that was created accidentally or occurred as a result of cutting the dura mater to remove an intradural tumor. The dura mater was sutured in a watertight fashion using fibrin glue spray. One or two closed suction drains were placed under the muscle layer. We explained to all patients beforehand that if we injured dura during surgery, we would take the head CT for searching intracranial bleeding. Therefore, we routinely performed head CT in cases of dural damage on the first postoperative day, and the results of the head CT were interpreted by the radiologists. Next, we categorized the 11 patients into two groups according to whether they had RCH or not. The RCH group included patients with intracranial bleeding involving either the cerebellum or a cerebral fissure. RCH was typically characterized by a streaky bleeding pattern caused by spreading of blood in the cerebellar sulci (Fig. 1). The non-RCH group included patients who did not have intracranial hemorrhage. For the RCH group, head CT was performed to check the status of bleed-

ing 1 week after surgery. The usual steps undertaken in patients who complained of headache were maintaining a blood pressure <140 mmHg by administration of intravenous nicardipine hydrochloride, placing the patient in a supine position, and drain removal. We kept the patient in a supine position until we confirmed in the follow-up head CT that bleeding stopped. The mean values for intraoperative bleeding volume, maximum perioperative blood pressure, postoperative drainage volume, and frequency of reports of headache in the first 24 h postoperatively were compared between the groups. This is because excessive CSF drainage and arterial hypertension postoperatively have been identified as factors potentially predisposing to RCH<sup>3-7</sup>. Welch's two-sample *t*-test was used to compare the mean values for continuous variables (i.e., amount of intraoperative bleeding, perioperative blood pressure, and postoperative drainage), and Fisher's exact test was used to compare the proportions of categorical variables (e.g., postoperative headache). The follow-up duration was 12 months.

## Results

The RCH group included four patients (two men, and two women) with a mean age of 62.2 years, and the non-RCH group included seven patients (five men, and two women) with a mean age of 68.9 years. Two patients in each group were receiving anticoagulant therapy. The incidence of RCH following suturing of the dura mater during spinal surgery was 36.4% (4/11). The surgical procedures performed in the RCH group included two posterior interbody fusions ( $n = 2$ ), thoracolumbar posterior decompression ( $n = 1$ ), and tumorectomy for a thoracic neurinoma ( $n = 1$ ; Table 1). We performed multiple interbody fusions in the non-RCH group, except in a decompression case (Table 2). We selected a negative drainage pressure in three cases and a positive pressure for one case in the RCH group and selected negative pressure for all cases in the non-RCH group. The drainage pressure for every patient after surgery was decided by the surgeon. Intracranial bleeding occurred in the cerebellum in three cases and in the interhemispheric fissure in one case in the RCH group. All patients in the RCH group didn't have any previous head trauma. The mean intraopera-



**Figure 1.** Computed tomography of the head showing a cerebellar hemorrhage (the Zebra sign) in the RCH group.

**Table 1.** Demographic and Clinical Characteristics of Patients with Remote Cerebellar Hemorrhage.

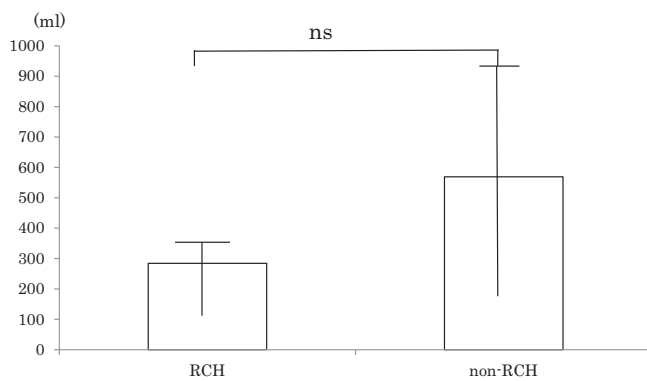
Case	Age, years	Sex	Diagnosis	Operation	Drain pressure	Anticoagulant therapy	Intracranial hemorrhage	Past medical history
1	71	M	Intradural extramedullary tumor at T11	Tumorectomy	Positive	Apixaban	Cerebellum	CI
2	75	F	Lumbar spinal canal stenosis	L4/5 PLIF	Negative	None	Cerebellum	None
3	19	F	Idiopathic scoliosis	T4-L3 PLF	Negative	None	Interhemispheric fissure	None
4	84	M	Lumbar spinal canal stenosis and thoracic myelopathy	T11, 12, L3, 4 Laminectomy	Negative	Aspirin	Cerebellum	CI

CI, cerebral infarction; PLF, posterior lateral fusion; PLIF, posterior interbody fusion

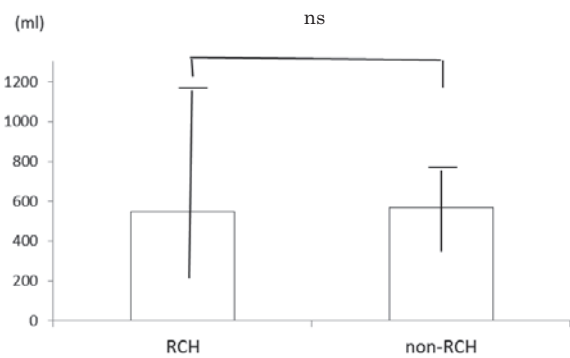
**Table 2.** Demographic and Clinical Characteristics of Patients without Remote Cerebellar Hemorrhage.

Case	Age, years	Sex	Diagnosis	Operation	Drain pressure	Anticoagulant therapy	Intracranial hemorrhage	Past medical history
5	80	M	Destructive spondyloarthropathy	L4/5 PLIF	Negative	None	None	DM, HD
6	81	F	Lumbar spinal canal stenosis	L2-5 PLF	Negative	Pravastatin	None	Prostate cancer, CI
7	76	M	Lumbar spinal canal stenosis	L3/4 PLIF, L4-5 PL L2-5 laminectomy	Negative	None	None	HT, DM
8	63	M	T12 metastasis	T10-L2 PLF	Negative	None	None	Prostate Cancer
9	56	M	Lumbar spinal canal stenosis	L4/5 S/S1 PLIF	Negative	None	None	None
10	68	M	Destructive spondyloarthropathy	L5/S1 PLIF	Negative	Aspirin	None	HD, Renal transplantation
11	F	67	Facet cyst	L4/5 Cyst resection	Negative	None	None	Hyperparathyroidism

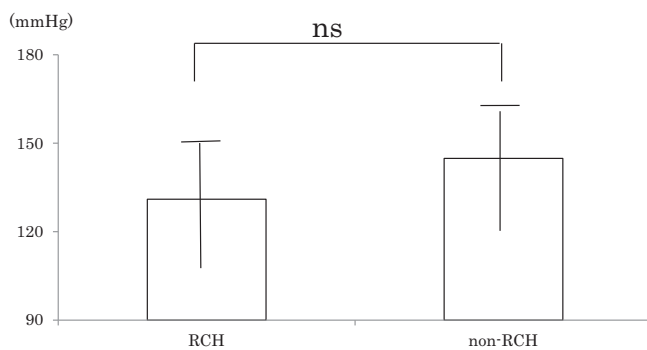
CI, cerebral infarction; HD, hemodialysis; PLF, posterior lateral fusion; PLIF, posterior interbody fusion



**Figure 2.** Mean intraoperative bleeding volume in the two groups.



**Figure 4.** Mean postoperative drainage volume in the two groups.



**Figure 3.** Mean peak perioperative blood pressure in the two groups.

tive bleeding volume was 284 mL in the RCH group and 569 mL in the non-RCH group ( $p = 0.08$ ; Fig. 2). The mean peak perioperative blood pressure was 132 mmHg in the RCH group and 144 mmHg in the non-RCH group ( $p = 0.33$ ; Fig. 3). The mean postoperative drainage volume was 547 mL in the RCH group and 567 mL in the non-RCH group ( $p = 0.93$ ; Fig. 4). Complaints of headache in the first 24 h postoperatively were significantly more common in the

**Table 3.** Complaints of Headache in the First 24 H Postoperatively in the Two Groups.

Headache	RCH group	non-RCH group	P value
Yes	4 (100%)	1 (14.3%)	$p=0.015$
No	0 (0%)	6 (85.7%)	
Total	4	7	

RCH: remote cerebellar hemorrhage

RCH group than in the non-RCH group (100% vs. 14.3%;  $p = 0.015$ ; Table 3). The headaches were aggravated by sitting or standing. The location of the headache was different in each patient. One patient in the RCH group was admitted to the intensive care unit because of a low level of consciousness. All patients who experienced intracranial bleeding were treated conservatively and had recovered 3 months after surgery.

### Discussion

Intracerebral hematoma after craniotomy is a common

complication in neurosurgical practice<sup>3,4,8,9</sup>). Some of these hematomas occur at the surgical site, whereas others develop at remote locations. Hemorrhage after cranial or spinal surgery can occur in the intracerebral, cerebellar, epidural, or subdural compartments. A previous study reported that the incidence of RCH in lumbar spine surgery is 0.08%<sup>10</sup>, but a report by Morofuji suggests that the incidence is likely to be higher<sup>11</sup>. There are numerous reports of patients in whom RCH developed as a delayed complication of spinal surgery<sup>5,12-16</sup>. Chaddock first described RCH after a spinal procedure in 1981<sup>13</sup>. Thomas et al. subsequently reported on a patient in whom supratentorial, infratentorial, and intraparenchymal hemorrhage developed after spinal surgery<sup>6</sup>. Chaddock postulated that elevated blood pressure might cause an increased gradient between intravascular and CSF pressure, thus inducing hemorrhage into the cerebellar parenchyma<sup>13</sup>. Andrews and Koci speculated that their case of cerebellar infarction resulted from transient traction, kinking, or spasm of the superior cerebellar arteries and reported that hemorrhage occurred upon reperfusion<sup>12</sup>. Some researchers have theorized that excessive CSF drainage postoperatively could cause the cerebellum to become dislocated inferiorly, with possible tearing of the superior vermian vein<sup>5-7</sup>. Several other factors, including arterial hypertension, anticoagulation therapy, coagulopathy, aneurysm, arteriovenous malformation, and previous head injury, have been identified as factors potentially predisposing to RCH<sup>3,4,6,17</sup>. CT scan in patients with this type of hemorrhage typically shows a streaky bleeding pattern, known as the Zebra sign, which is caused by blood spreading in the cerebellar sulci<sup>2</sup>. In our cases, the drainage volume was not significantly different between the RCH group and the non-RCH group (547 vs. 567 mL). The most common clinical symptoms of RCH are headache and impaired consciousness, and these are most likely to occur during the first 10 h postoperatively<sup>1</sup>. In the present study, complaints of headache were significantly more common during the first 24 h postoperatively in the RCH group ( $p < 0.05$ ). When a tentative diagnosis of RCH is made, the suction drain should be removed promptly, and the patient should be treated as soon as possible to prevent worsening of RCH<sup>18</sup>. Small cerebellar hematomas can be managed medically and followed up with serial imaging. However, large hematomas that cause a significant mass effect in the posterior fossa may require surgical decompression<sup>5,12-15,19</sup>. Decompression is necessary if there are signs and symptoms of brainstem compression as a result of increased intracranial pressure. Expanded suboccipital craniotomy and duraplasty are the procedures used to decompress the posterior fossa. The outcome is generally good, with more than 50% of cases having either complete recovery or only mild residual neurologic symptoms, although there is a mortality risk of 10%-15%<sup>1</sup>. Fortunately, no patients required surgical intervention among our cases.

## Conclusion

In summary, this study investigated the occurrence of RCH in spinal surgery following intraoperative suturing of the dura with sump drain placement. This study also investigated the factors associated with a significantly increased risk of RCH. The incidence of RCH following suturing of the dura mater during spinal surgery was 36.4%. There was a significant association between postoperative headache during the first 24 h and occurrence of RCH. However, the postoperative drainage volume did not differ significantly between the two groups. Thus, massive CSF leakage may not account for RCH in this series. We surmise that complaints of headache during the first 24 h postoperatively enabled the detection of RCH.

**Conflicts of Interest:** The authors declare that there are no relevant conflicts of interest.

**Author Contributions:** Daisuke Numaguchi wrote the manuscript, and all authors participated in the design of the study. All authors read, reviewed, and approved the final version of the manuscript.

## References

1. Brockmann MA, Groden C. Remote cerebellar hemorrhage: a review. *Cerebellum*. 2006;5(1):64-8.
2. Brockmann MA, Nowak G, Reusche E, et al. Zebra sign: cerebellar bleeding pattern characteristic of cerebrospinal fluid loss. Case report. *J Neurosurg*. 2005;102(6):1159-62.
3. Papanastassiou V, Kerr R, Adams C, et al. Contralateral cerebellar hemorrhagic infarction after pterional craniotomy: report of five cases and review of the literature. *Neurosurgery*. 1996;39(4):841-52.
4. Toczek MT, Morrel MJ, Silverberg GA, et al. Cerebellar hemorrhage complicating temporal lobectomy. *J Neurosurg*. 1996;85(4):718-22.
5. Friedman JA, Ecker RD, Piepgras DG, et al. Remote cerebellar hemorrhage after spinal surgery: report of two cases and literature review. *Neurosurgery*. 2002;50(6):1361-4.
6. Thomas G, Jayaram H, Cudlip S, et al. Supratentorial and infratentorial intraparenchymal hemorrhage secondary to intracranial CSF hypotension following spinal surgery. *Spine*. 2002;27(18):E410-2.
7. Yoshida S. Cerebellar hemorrhage after supratentorial craniotomy report of three cases. *Neurol Med Chir* 1990;30(10):738-43.
8. Brisman MH, Bederson JB, Sen CN, et al. Intracerebral hemorrhage occurring remote from the craniotomy site. *Neurosurgery*. 1996;39(6):1114-22.
9. Kalfas IH, Little JR. Postoperative hemorrhage: a survey of 4992 intracranial procedures. *Neurosurgery*. 1988;23(3):343-7.
10. Cevik B, Kibas I, Cakir B, et al. Remote cerebellar hemorrhage after lumbar spinal surgery. *Eur J Radiol*. 2008;70(1):7-9.
11. Morofuji Y, Tsunoda K, Hiu T, et al. Remote cerebellar hemorrhage after cervical spine surgery: two case reports and literature review. *No Shinkei Geka* 2009;37(11):1117-22.
12. Andrews RT, Koci TM. Cerebellar herniation and infarction as a complication of an occult postoperative lumbar dural defect. *Am J Neuroradiol*. 1995;16(6):1312-5.

13. Chaddock WM. Cerebellar hemorrhage complicating cervical laminectomy. *Neurosurgery*. 1981;9(2):185-9.
14. Gobel F, Heidecke V, Hube R, et al. Cerebellar hemorrhage as an early complication of spinal operations. Two case reports and review of the literature. *Z Orthop Ihre Grenzgeb*. 1999;137(4):371-5.
15. Mikawa Y, Watanabe R, Hino Y, et al. Cerebellar hemorrhage complicating cervical durotomy and revision C1-2 fusion. *Spine*. 1994;19(10):1169-71.
16. Morandi X, Riffaud L, Carsin-Nicol B, et al. Intracerebral hemorrhage complicating cervical “hourglass” schwannoma removal. *J Neurosurg*. 2001;94(1):150-3.
17. Morimoto T, Shiraki M, Otani K, et al. Supratentorial subdural hemorrhage of a previous head injury and cerebellar hemorrhage after cervical spinal surgery: a case report and review of the literature. *Spine*. 2014;39(12):E743-7.
18. Choi BW, Lee SM, Yoon MG, et al. Cerebellar hemorrhage after posterior lumbar decompression and interbody fusion complicated by dural tear. *J Korean Society of Spine Surg*. 2014;21(4):183-8.
19. Satake K, Matsuyama Y, Iwata H, et al. Cerebellar hemorrhage complicating resection of a cervical intramedullary tumor. *Spinal Cord*. 2000;38(8):504.

Spine Surgery and Related Research is an Open Access journal distributed under the Creative Commons Attribution-NonCommercial-NoDerivatives 4.0 International License. To view the details of this license, please visit (<https://creativecommons.org/licenses/by-nc-nd/4.0/>).