

STUDY OF THE TREATMENT OF FEMORAL HEAD FRACTURES

Rodrigo Pereira Guimarães¹, Gilliat Saeki de Souza², Sandro da Silva Reginaldo³, Nelson Keiske Ono⁴, Emerson Kiyoshi Honda⁵, Giancarlo Cavalli Polesello⁶, Walter Riccioli Junior⁶

ABSTRACT

Objective: To establish guidelines for the treatment of femoral head fractures and to determine the best form of access in cases treated surgically. *Methods:* We evaluated the clinical and radiological results from 13 patients (13 fractures) treated surgically, between May 1986 and July 1996, at the Department of Orthopedics and Traumatology, Santa Casa de Misericórdia de São Paulo (SCMSP), Fernandinho Simonsen Wing. *Results:* Out of six cases of Pipkin 1 fractures, five underwent resection of the fragment, resulting in four excellent and one good result. The good result had fixation of the fragment. Three patients presented Pipkin 2 fractures and all of them had fixation of the fragment, resulting in two excellent and one regular result. Two patients had Pipkin 3 fractures and underwent primary arthroplasty. Among the two patients with Pipkin 4 lesions, one was treated with reduction and osteosynthesis of the acetabular fracture, without addressing the head fragment, which had reduced significantly, resulting in early arthrosis; and the other patient was treated with total arthroplasty as the primary treatment. *Conclusion:* Upon comparing the literature review and our patients' treatment results, we concluded that femoral head fracture treatment needs to be surgical and that the choice of surgical access depends on the type of fracture.

Keywords – Femur; Femoral head; Fracture fixation; Fracture consolidation

INTRODUCTION

Femoral head fractures were described for the first time by 1869, subsequent to necropsy. They are a rare type of injury, but their incidence has increased proportionally with the number of car accidents, which is the most frequent etiological factor. Most cases of such fractures are associated with posterior hip dislocation, with occasional reports of associations with anterior dislocation.

In addition to closed surgical treatment, there are other surgical options ranging from resection of the femoral head to fixation, arthrodesis or primary arthroplasty.

Lack of uniformity among the criteria used by different authors for lesion classification and assessment of the clinical evolution, associated with the small number of cases, makes it difficult to compare the results in or-

der to produce guidelines for treating these lesions.

The aim of the present study was to compare a review of the literature with our results, in order to establish the best management in relation to treatment and, when treatment was surgical, the best access route.

MATERIALS AND METHODS

Between May 1986 and July 1996, in the Department of Orthopedics and Traumatology, Santa Casa de Misericórdia de São Paulo (SCMSP), "Fernandinho Simonsen" Wing, 13 femoral head fractures were treated in 13 patients.

In this study, cases of pressure fracture of the femoral head were not evaluated.

The patients' ages ranged from 17 to 55 years (mean = 33.7 years).

1 – MSc from FCMSCSP and Lecturer; Attending physician in the Hip Group, Department of Orthopedics and Traumatology, FCMSCSP.

2 – Orthopedist and former trainee in the Hip Group, Department of Orthopedics and Traumatology, FCMSCSP.

3 – PhD from FCMSCSP and Assistant Professor; Head of the Hip Group, Department of Orthopedics and Traumatology, FCMSCSP.

4 – PhD from FCMSCSP and Lecturer; Senior Member of the Hip Group, Department of Orthopedics and Traumatology, FCMSCSP.

5 – PhD from FCMSCSP and Assistant Professor; Attending Physician in the Hip Group, Department of Orthopedics and Traumatology, FCMSCSP.

6 – Orthopedist and Attending Physician in the Hip Group, Department of Orthopedics and Traumatology, FCMSCSP.

Work performed within the Hip Diseases Group, Department of Orthopedics and Traumatology, Irmandade Santa Casa de Misericórdia de São Paulo, "Fernandinho Simonsen" Wing.

Correspondence: Rua Cesário Mota Júnior 112, Vila Buarque, 01221-900 São Paulo, SP. E-mails: clinicaguimaraes@gmail.com and dot.quadril@hotmail.com

We declare that there is no conflict of interests in this article

Regarding sex, 10 (76.9%) were male and three were female.

In relation to the side affected, nine hips (69.2%) were on the right side and four, on the left side.

The etiology of the 13 fractures consisted of a car accident in 11 cases (84.6%), being run over by a train in one case (7.69%) and falling from a height in one case (7.69%). All the cases presented an association with posterior hip dislocation.

To diagnose fractures of the femoral head, a complete radiographic investigation was performed on all the patients. This consisted of the anteroposterior and internal and external oblique views of the pelvis and the lateral view of the coxofemoral joint on the side affected. We used computed tomography only in two cases in which the radiographs were insufficient for a precise diagnosis of the fracture.

The patients were classified in accordance with Pipkin's proposal⁽¹⁾ (Table 1).

Table 1 – Distribution of patients according to Pipkin classification

Pipkin classification	Definition	Numbers of cases (percentage)
Type 1	Fragment caudal to fovea	6 (46.15%)
Type 2	Fragment cephalic to fovea	3 (23.07%)
Type 3	Association of type 1 or type 2 with femoral neck fracture	2 (15.3%)
Type 4	Association of type 1 or type 2 with acetabular fracture	2 (15.3%)

Surgical treatment was performed in all cases.

Among the six type 1 cases, five were treated by means of resection of the fragment of the femoral head and connection using Steinmann wires. The access route used was anterior in three cases, anterolateral in one and posterior in two cases.

Type 2 fractures were treated by means of internal fixation: one using Steinman wires, one with threaded wires and one with two screws in small fragments. The access routes used were anterolateral, lateral and posterior (one in each case).

The patients with type 3 fractures underwent primary total hip arthroscopy.

In one type 4 case, reduction and fixation were performed using a plate and screws on the fracture of the posterior wall, by means of the posterior access. Since the fragment of the head had been well reduced and was stable, no fixation was used. In the other case, it was

decided to perform total hip arthroplasty because, at the time of the surgery, three months had already elapsed since the trauma and the acetabular fracture already presented defective consolidation.

The postoperative results were analyzed from the clinical and radiographic points of view separately, in accordance with the criteria of Thompson and Epstein⁽²⁾ (Table 2).

Table 2 – Clinical and radiographic evaluation criteria for patients with hip dislocation according to Thompson and Epstein

	Clinical criteria	Radiographic criteria
Excellent	Absence of pain No claudication Total mobility	Normal relationship between acetabulum and femoral head Normal joint space Normal femoral head density No osteophytes No soft-tissue calcification
Good	No pain Slight claudication At least 75% mobility	Normal relationship between acetabulum and femoral head Small diminution of joint space Little osteophyte formation Minimal capsule calcification
Regular	Non-incapacitating pain Antalgic gait Moderate limitation of mobility	Normal relationship between acetabulum and femoral head Moderate diminution of joint space Moderate osteophyte formation Moderate soft-tissue calcification Depression of subchondral bone in femoral head
Poor	Incapacitating pain Severe limitation on mobility Contracture in adduction New dislocation	Marked diminution of joint space Increased femoral head density Subchondral cysts Severe femoral heads deformity Severe osteophyte formation Acetabular sclerosis

Source: Thompson VP, Epstein HC. Traumatic dislocation of the hip: a survey of two hundred and four cases covering a period of twenty-one years. *J Bone Joint Surg Am.* 1951;33:746-77.

The mean duration of postoperative follow-up was six years and two months (minimum of one year and maximum of 11 years and six months). For the follow-up purposes, cases that underwent total primary hip arthroplasty.

RESULTS

Among the five cases of Pipkin 1 fractures that underwent resection of the fractured fragment, four presented results that were both clinically and radiographically excellent, while one patient was considered good from the clinical and radiographic points of view. The patient with a type 1 fracture who was treated by means of fixation using two Steinmann wires presented good clinical and radiographic results.

The three cases of Pipkin 2 fracture underwent fixation of the fragment; two of them presented clinically and radiographically excellent results. The other case (case 3) was classified as regular, since this patient presented pain after intense physical effort, moderate limitation of hip movements and moderate degenerative arthritis.

The results from the two patients with Pipkin 3 fractures and the one patient with a type 4 lesion (who underwent total primary hip arthroplasty) were not analyzed, since the aim of the present study did not include analysis on the results from arthroplasty.

The patient with a Pipkin 4 fracture, who was treated with fixation of the acetabular fracture, presented intense pain and significant restriction of hip movement four months after the surgery. This patient also showed evident radiographic signs of arthrosis, with marked diminution of the joint space. The result was considered to be poor and total hip arthroplasty was indicated (Table 3).

Table 3 – Patient distribution according to epidemiological data and results

Patient	Age	Sex	Side	Pipkin classification	Clinical/Radiographic Results
1	30 years	M	R	1	Good/Good
2	27 years	F	R	1	Excellent/Excellent
3	41 years	M	R	2	Regular/Regular
4	32 years	M	R	3	PTA
5	30 years	M	L	3	PTA
6	17 years	M	R	1	Good/Good
7	41 years	M	R	1	Excellent/Excellent
8	50 years	M	L	4	Poor/Poor
9	21 years	F	R	2	Excellent/Excellent
10	22 years	M	R	1	Excellent/Excellent
11	55 years	M	L	4	ATP
12	51 years	M	L	2	Excellent/Excellent
13	22 years	F	R	1	Excellent/Excellent

M – male; F – female; R – right side; L – left side; PTA – primary total arthroplasty

DISCUSSION

Since the publication of the first case in 1869, fracture of the femoral head has been the topic described in a small number of cases. However, today, its occurrence has increased proportionally with the increase in the number of car accidents, which is the main etiological factor⁽³⁾. This was responsible for 11 of the 13 fractures that we studied.

The most common injury mechanism in car accidents is knee trauma against the panel of the car, with the hip flexed less than 60°. The force is transmitted along the longitudinal axis of the femur, thus pushing the femoral head against the rigid upper part of the acetabulum and causing fracture of the head before hip dislocation⁽⁴⁻⁷⁾. The positioning of the lower limb at the moment of the trauma (i.e. whether it is in adduction or in abduction) will determine whether the fracture will occur above or below the fovea, respectively⁽⁸⁾. Epstein *et al*⁽³⁾ alerted to the possibility of hip dislocation in all the patients who presented bruising or scraping of the knee together with hip adduction and established a routine of performing pelvic radiography on all patients with severe trauma, especially in situations affecting the lower limbs. Another injury mechanism cited for fractures or dislocations of the hip has been direct trauma to the greater trochanter⁽⁹⁾.

In most of the published cases, femoral head fracture was associated with posterior hip dislocation. We only found one case described in the literature in which a fracture occurred without the presence of hip dislocation⁽¹⁰⁾ and few cases associated with anterior hip dislocation⁽¹¹⁻¹⁴⁾. The largest sample of the latter was reported by DeLee *et al*⁽¹⁵⁾, consisting of 13 patients.

Lang-Stevenson and Getty⁽⁸⁾ presented three cases in which the diagnosis of femoral head fracture was not made when the case was first seen. They emphasized the importance of conducting a complete radiographic examination, including the oblique views described by Judet *et al*⁽¹⁶⁾, which Schwartsmann *et al*⁽¹⁷⁾ also considered to be indispensable. Moed and Maxey⁽¹⁸⁾ cited the importance of associating radiography and tomography for better evaluation of the degree of dislocation of the fracture and the joint congruence.

According to some authors, in cases of doubt, computed tomography should be performed whenever it is available, not only for diagnostic purposes but also to define the treatment^(19,20). Among the cases that we studied, tomography was performed only in the cases of two patients for whom there was doubt regarding the diagnosis and the classification of the fracture.

Among the great difficulties in adequately analyzing femoral head fractures, in addition to the small number of cases presented by different authors, there is the lack of uniform criteria for classifying these lesions and evaluating the results from the treatment. This often hinders making trustworthy comparisons.

For hip dislocations, the best known classifications are the one by Thompson and Epstein⁽²⁾, which divi-

des dislocations into five types, among which type V is associated with femoral head fracture; and the one by Stewart and Milford⁽²¹⁾, which divides these lesions into four grades, among which grade IV is associated with fractures of the femoral head or neck.

Specifically in relation to femoral head fractures, the classification that is most accepted, and which we used, is the one by Pipkin⁽¹⁾, which divides the fractures into four types: type 1, dislocation with fracture of the femoral head caudally to the fovea; type 2, dislocation with fracture of the femoral head cephalically to the fovea; type 3, consisting of type 1 or type 2 in association with fracture of the femoral neck; and type 4, consisting of type 1 or type 2 in association with fracture of the acetabulum.

In making the final analysis on the treatment, Hougaard and Thomsen⁽²²⁾ considered that good results were those in which there was no pain, the hip movement was normal and the radiographs did not show any diminution of the joint space, even if there were degenerative abnormalities in the lower region of the hip. The presence of other clinical or radiographic abnormalities was considered to represent poor results. However, what we noted was that several authors used very subjective criteria for analyzing their results, which makes statistical comparisons between studies difficult. In the cases that we studied, we used the criteria of Thompson and Epstein⁽²⁾, who analyzed the clinical and radiographic factors separately.

The main controversy lies in the treatment administered to these lesions. While some authors recommend non-surgical treatment, others advocate surgery. Among the latter, there is also the debate on whether to perform resection or fixation of the fragments from the fractured head. Furthermore, there are also advocates of arthroplasty or arthrodesis as the initial procedure.

Christopher⁽²³⁾ analyzed 15 cases described in the literature and concluded that the treatment of choice was non-surgical reduction of the dislocation with early movement of the hip. Although Butler⁽²⁴⁾ also considered that non-surgical treatment was the first option, this author recommended that the hip should be placed under traction, in extension, for at least six weeks.

From the point of view of Urist⁽²⁵⁾, the type of fracture was much more important for determining the prognosis than the treatment that was carried out. For this reason, this author recommended non-surgical treatment as the least aggressive option.

Several authors have recommended non-surgical treatment except in situations when non-surgical reduction is impossible, or there is interposition of intra-articular

fragments and hip instability after the reduction. In such situations, surgical intervention would become necessary^(1,26-29).

According to Blankensteijn *et al*⁽⁷⁾, performing computed tomography is indispensable for analyzing the fracture reduction. Chakraborti and Miller⁽⁵⁾ did not place much value on anatomical reduction and accepted small dislocations and even rotation of the fragment. However, in all the cases analyzed by these authors, the fragment was found outside of the support area, which perhaps would explain the good results achieved with non-surgical treatment.

In analyzing 45 cases of hip dislocation that were treated by means of non-surgical reduction followed by a period of one to twelve weeks of traction, Kristensen and Stougaard⁽³⁰⁾ found a statistically significant difference between the patients who did not have any fracture and those who presented femoral head fracture, such that the latter group had a worse result (60% with poor results). This result coincided with that of Armstrong⁽³¹⁾, thus showing that the severity of the lesion increases when there femoral head fractures are present.

According to the literature^(6,29,32), the main complication from non-surgical reduction is the occurrence of fractures of the femoral neck, thus iatrogenically transforming initial type 1 or type 2 Pipkin lesions into type 3.

Another point that has led to much debate is the importance of early reduction of the hip dislocation in determining the final result, which was considered fundamental by Epstein⁽³³⁾, Hougaard and Thomsen⁽²²⁾ and Vermeiren and Hoye⁽³⁴⁾, with the purpose of avoiding occurrences of avascular necrosis of the femoral head. Among our cases, we had one patient (case 13) of 22 years of age, with a Pipkin 1 fracture and posterior hip dislocation that had occurred three months earlier. After surgical treatment with resection of the fractured fragment and reduction of the hip dislocation, the patient presented an excellent result according to the criteria of Thompson and Epstein⁽²⁾, with a follow-up of one year and five months. This shows that avascular necrosis does not always occur when there is a delay in performing reduction of the hip dislocation.

There is also polemic regarding resection of the fracture fragments, which was advocated by Menandro⁽³⁵⁾ and Gordon and Greiberg⁽⁹⁾. Silvello *et al*⁽³⁶⁾ advocated resection of Pipkin 2 lesions because, according to these authors, the fragments in this situation are avascular and there is no advantage in undertaking osteosynthe-

sis. This proposition contradicts the information from Epstein⁽³⁷⁾ and Palin and Richmond⁽³⁸⁾, who stated that removal of the fragment belonging to the load surface would lead to a poor result. According to Hougaard and Thomsen⁽²²⁾, resection is contraindicated in type 2 lesions and unnecessary in type 1.

Epstein *et al*⁽³⁾ contraindicated performing repeated attempts at non-surgical reduction of hip dislocation, because of the additional trauma that this causes. The recommended that primary open reduction should be performed on all fractured hip dislocations, with resection of the femoral head fracture fragment in cases of Pipkin 1 and 2 lesions, except in cases of fractures that represented more than one third of the head size, in which case the fracture should be fixed.

Roeder and DeLee⁽⁶⁾ and Lang-Stevenson and Getty⁽⁸⁾ agreed that primary open reduction of the dislocation should be performed, but they recommended fixation and not resection of the fractured fragment.

Fixation of the fracture, even if deinsertion of the round ligament is necessary, has been advocated by several authors^(12,13,39-41). One good fixation option is to use Herbert screws, which provide compression at the focus of the fracture, do not present intra-articular protrusion and are technically easy to emplace^(42,43). The use of absorbable screws may avoid complications that occur with metal implants, particularly migration. This also enables better assessment of the conditions of the femoral head using magnetic resonance or computed tomography during the postoperative period⁽⁴⁴⁾.

Primary hip arthroplasty was the treatment of choice for Kelly and Lipscomb⁽⁴⁵⁾ for lesions affecting betwe-

en one third and half of the head or the load surface. Stewart⁽³²⁾ indicated this for type 2 lesions in elderly people, while for young adults, this author suggested that arthrodesis should be used. These procedures were considered by Epstein to be for exceptional use⁽³³⁾.

In our opinion, reduction of hip dislocation should be done non-surgically as a matter of urgency. The treatment for femoral head fractures is surgical, and the technique used will depend on the type of fracture.

The difference in approach between type 1 and type 2 lesions is the relationship between the fracture area and the loading zone of the femur, which was very well demonstrated in the experimental study by Greenwald and Haynes⁽⁴⁶⁾. Whereas the loading zone is not involved in type 1 fractures, it is affected in type 2.

For Pipkin type 1 fractures, we recommend that the fractured fragment should be resected, since its removal does not interfere with the loading zone of the femur, and does not have biomechanical repercussions for the joint. We believe that non-surgical treatment is not a good option, since it would impede early mobilization, due to pain and the risk of fragment interposition. All of our cases of Pipkin 1 fractures, including one case treated with fixation of the fragment, presented satisfactory final results, which makes us think that fixation of the fragment is unnecessary and that its resection is important (Figure 1).

In type 2 fractures, we recommend that the fragment should be anatomically fixed, so that the loading zone of the femur can be biomechanically preserved. If, after non-surgical reduction of the hip dislocation, the fragment has become reduced, its fixation should be at-

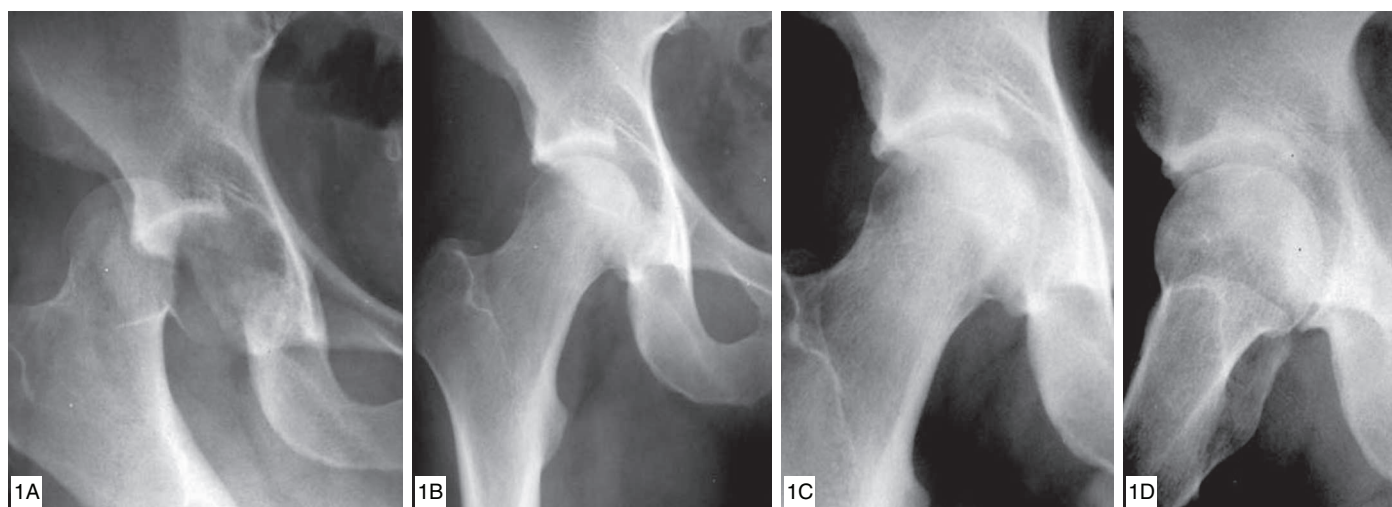


Figure 1 (case 10) – A) 22-year-old male patient who was a victim of a car accident. Pipkin 1 fracture. B) One year and five months after resection of the femoral head fragment. C and D) Eleven years and six months after the operation: asymptomatic patient.

tempted without performing hip arthrotomy. In cases in which subluxation of the hip occurs, arthrotomy should be performed to look for intra-articular fragments that might be interfering with the reduction, since subluxated hips evolve after only a short time into severe joint degeneration, as observed in the experimental study by King and Richards⁽⁴⁷⁾.

Pipkin 3 fractures are the most severe and most difficult to treat. In young and active adults, fixation of the fractures of the femoral head and neck should be attempted, although we recommend that planning for arthroplasty or arthrodesis should be undertaken, given that comminution of the fragments may make it impossible to achieve osteosynthesis. In type 4 fractures, the acetabular and femoral head lesions should be dealt with separately. Femoral head fractures are treated as described above, while acetabular fractures may require osteosynthesis, depending on the size and location of the lesion. In one of our cases, we were obliged to carry out primary total hip arthroplasty, since the case presented defective consolidation and anatomical reduction of the fragments was not possible.

Another polemical point in the approach to treatment is the choice of access route.

Connolly⁽⁴⁸⁾ considered that the posterior access route was the only one that, after a second hip dislocation, made complete inspection of the lesions possible.

The use of an anterior or posterior access route following the direction in which the dislocation occurred has been advocated by several authors, with the argument that this would preserve the only part of the capsule in which the circulation was preserved after the trauma^(3,12,32,34,36). However, in a report on five cases of avascular necrosis, of which four were operated using a posterior access route, Stannard *et al*⁽³⁹⁾ considered that the anterior route was as effective as the posterior route, in terms of functional results.

Swiontkowski *et al*⁽⁴⁹⁾ conducted a comparative study between patients operated using the anterior and posterior routes. They found similar functional results in the two groups. However, they recommended the anterior route in cases of Pipkin 1 and 2 fractures, despite the significantly greater number of cases of heterotopic ossification without clinical repercussion, since there was a decrease in the duration of the operation and amount of bleeding, along with better viewing and fixation of the fracture.

In relation to access route, our management method varies according to the type of fracture. For type 1 frac-

tures, we use the anterior route because we take the view that resection of the fragment, which is located anteroinferiorly, will not require new dislocation of the hip and therefore it will simplify the procedure. In addition, this is a more anatomical route, since it passes along a plane between muscles and between nerves. For type 2 fractures, we make a small lateral access that can be extended anteriorly if arthrotomy becomes necessary. For type 3 fractures, we make a posterior access, already thinking that arthroplasty may be needed. For type 4 lesions, the need to fix the acetabular fracture will determine whether the access route is anterior or posterior. If fixation of the wall or anterior column of the acetabulum is needed, the posterior route is used.

Lesions of the sciatic nerve occur in around 10% of the cases of femoral head fracture with posterior hip displacement. These are thought to be caused by excessive internal rotation at the moment of dislocation, thus leading to distension of the nerve⁽³⁾. This is a complication that was present in some authors' series^(6,23,31), although we did not observe it among our cases. Another complication that has been cited is the occurrence of ossifying myositis after the surgical treatment^(13,37,50), which we also did not have in our series.

CONCLUSION

Based on our review of the literature and on the analysis of the 13 cases of femoral head fracture that we treated, we conclude that:

- The treatment for femoral head fracture should be surgical;
- In Pipkin 1 fractures, the resection of the fragment from the head should be done using an anterior access;
- In Pipkin 2 fractures, fixation of the fragment should be performed in order to restore the anatomy of the loading zone of the femur, using a lateral access that can be extended anteriorly if hip arthrotomy is needed;
- Primary total arthroplasty is the treatment of choice for Pipkin 3 fractures, except for young adult patients, in whom osteosynthesis should be attempted. The access route should be made thinking of the possibility of arthroplasty;
- In Pipkin 4 fractures, acetabular and femoral head lesions should be dealt with separately. Head fractures are treated as described above. The need for fixation and the location of the acetabular fracture will determine the best access route.

REFERENCES

1. Pipkin G. Treatment of grade IV fracture-dislocation of the hip. *J Bone Joint Surg Am.* 1957;39(5):1027-42.
2. Thompson VP, Epstein HC. Traumatic dislocation of the hip; a survey of two hundred and four cases covering a period of twenty-one years. *J Bone Joint Surg Am.* 1951;33(3):746-78.
3. Epstein HC, Wiss DA, Cozen L. Posterior fracture dislocation of the hip with fractures of the femoral head. *Clin Orthop Relat Res.* 1985;(201):9-17.
4. Davis JB. Simultaneous femoral head fracture and traumatic hip dislocation. *Am J Surg.* 1950;80(7):893-5.
5. Chakraborti S, Miller IM. Dislocation of the hip associated with fracture of the femoral head. *Injury.* 1975;7(2):134-42.
6. Roeder LF Jr, DeLee JC. Femoral head fractures associated with posterior hip dislocation. *Clin Orthop Relat Res.* 1980;(147):121-30.
7. Blankensteijn JD, Lorie CA, van der Werken C. Traumatic dislocation of the hip with fracture of the femoral head. *Neth J Surg.* 1986;38(4):121-4.
8. Lang-Stevenson A, Getty CJ. The Pipkin fracture-dislocation of the hip. *Injury.* 1987;18(4):264-9.
9. Gordon EJ, Greiberg JA. Posterior dislocation of the hip with fracture of the head of the femur. *J Bone Joint Surg Am.* 1949;31(4):869-72.
10. Van der Werken C, Blankensteijn JD. Fracture of the femoral head without dislocation. A case report. *Acta Orthop Scand.* 1987;58(2):173-4.
11. Scham SM, Fry LR. Traumatic anterior dislocation of the hip with fracture of the femoral head. A case report. *Clin Orthop Relat Res.* 1969;62:133-5.
12. Mowery C, Gershuni DH. Fracture dislocation of the femoral head treated by open reduction and internal fixation. *J Trauma.* 1986;26(11):1041-4.
13. Richards BS, Howe DJ. Anterior perineal dislocation of the hip with fracture of the femoral head. A case report. *Clin Orthop Relat Res.* 1988;(228):194-201.
14. Terahata N, Matsui H, Makiyama N. Bilateral anterior dislocation of the hips. A case report. *Int Orthop.* 1996;20(2):125-6.
15. DeLee JC, Evans JA, Thomas J. Anterior dislocation of the hip and associated femoral-head fractures. *J Bone Joint Surg Am.* 1980;62(6):960-4.
16. Judet R, Judet J, Letourmel E. Fractures of the acetabulum: classification and surgical approaches for open reduction. Preliminary report. *J Bone Joint Surg Am.* 1964;46:1615-46.
17. Schwartzmann CR, Andrade D, Faga A, David A. Fraturas da cabeça do fêmur: relato de cinco casos. *Rev Bras Ortop.* 1983;18(4):121-4.
18. Moed BR, Maxey JW. Evaluation of fractures of the femoral head using the CT-directed pelvic oblique radiograph. *Clin Orthop Relat Res.* 1993;(296):161-7.
19. Sauser DD, Billimoria PE, Rouse GA, Mudge K. CT evaluation of hip trauma. *AJR Am J Roentgenol.* 1980;135(2):269-74.
20. Ordway CB, Xeller CF. Transverse computerized axial tomography of patients with posterior dislocation of the hip. *J Trauma.* 1984;24(1):76-9.
21. Stewart MJ, Milford LW. Fracture-dislocation of the hip; an end-result study. *J Bone Joint Surg Am.* 1954;36(2):315-42.
22. Hougaard K, Thomsen PB. Traumatic posterior fracture-dislocation of the hip with fracture of the femoral head or neck, or both. *J Bone Joint Surg Am.* 1988;70(2):233-9.
23. Christopher F. Fractures of the head of the femur. *Arch Surg.* 1926;12:104961.
24. Butler JE. Pipkin Type-II fractures of the femoral head. *J Bone Joint Surg Am.* 1981;63(8):1292-6.
25. Urist MR. Fracture-dislocation of the hip joint; the nature of the traumatic lesion, treatment, late complications and end results. *J Bone Joint Surg Am.* 1948;30(3):699-727.
26. Kelly RP, Yarbrough SH 3rd. Posterior fracture-dislocation of the femoral head with retained medial head fragment. *J Trauma.* 1971;11(2):97-108.
27. Larson CB. Fracture dislocations of the hip. *Clin Orthop Relat Res.* 1973;(92):147-54.
28. Guiral J, Jerez J, Oliart S. Bilateral Pipkin type II fracture of the femoral head. *Injury.* 1992;23(6):417-8.
29. Zehi K, Karray S, Litaïem T, Douik M. [Fracture-luxation of the femur head. Apropos of 10 cases]. *Acta Orthop Belg.* 1997;63(4):268-73.
30. Kristensen O, Stougaard J. Traumatic dislocation of the hip. Results of conservative treatment. *Acta Orthop Scand.* 1974;45(2):206-12.
31. Armstrong JR. Traumatic dislocation of the hip joint; review of 101 dislocations. *J Bone Joint Surg Br.* 1948;30(3):430-45.
32. Stewart MJ. Management of fractures of the head of the femur complicated by dislocation of the hip. *Orthop Clin North Am.* 1974;5(4):793-8.
33. Epstein HC. Traumatic dislocations of the hip. *Clin Orthop Relat Res.* 1973;(92):116-42.
34. Vermeiren JA, van Hoye M. Three cases of femoral head fracture in a single car accident. *J Trauma.* 1991;31(4):579-81.
35. Menandro MB. Luxação do quadril com fratura da cabeça do fêmur: relato de 2 casos. *Rev Bras Ortop.* 1968;3(2):83-8.
36. Silvello L, Scarponi R, Magnoni R, Cadlolo R. Posterior hip dislocation with slice fracture of the femoral head: removal of the cephalic fragment. *Ital J Orthop Traumatol.* 1990;16(2):279-83.
37. Epstein HC. Posterior fracture-dislocations of the hip: comparison of open and closed methods of treatment in certain types. *J Bone Joint Surg Am.* 1961;43:1079-98.
38. Palin HC, Richmond DA. Dislocation of the hip with fracture of the femoral head: a report of three cases. *J Bone Joint Surg Br.* 1954;36:442-4.
39. Stannard JP, Harris HW, Volgas DA, Alonso JE. Functional outcome of patients with femoral head fractures associated with hip dislocations. *Clin Orthop Relat Res.* 2000;(377):44-56.
40. Sarmiento A, Laird CA. Posterior fracture-dislocation of the femoral head. Report of a case. *Clin Orthop Relat Res.* 1973;(92):143-6.
41. Nast-Kolb D, Ruchholtz S, Schweiberer L. [Treatment of Pipkin fractures]. *Orthopade.* 1997;26(4):360-7.
42. Murray P, McGee HM, Mulvihill N. Fixation of femoral head fractures using the Herbert screw. *Injury.* 1988;19(3):220-1.
43. Leite NM, Reis FB, Lourenço AF, Laredo Filho J. Luxação traumática bilateral do quadril associada com fratura bilateral da cabeça do fêmur: tratamento com parafusos de Herbert. *Rev Bras Ortop.* 1990;25(7):214-8.
44. Jukkala-Partio K, Partio EK, Hirvensalo E, Rokkanen P. Absorbable fixation of femoral head fractures. A prospective study of six cases. *Ann Chir Gynaecol.* 1998;87(1):44-8.
45. Kelly PJ, Lipscomb PR. Primary vitallium-mold arthroplasty for posterior-dislocation of the hip with fracture of the femoral head. *J Bone Joint Surg Am.* 1958;40(3):675-80.
46. Greenwald AS, Haynes DW. Weight-bearing areas in the human hip joint. *J Bone Joint Surg Br.* 1972;54(1):157-63.
47. King D, Richards V. Fracture-dislocations of the hip joint. *J Bone Joint Surg.* 1941;23:533-51.
48. Connolly JF. Acetabular labrum entrapment associated with a femoral-head fracture-dislocation. A case report. *J Bone Joint Surg Am.* 1974;56(8):1735-7.
49. Swionkowski MF, Thorpe M, Seiler JG, Hansen ST. Operative management of displaced femoral head fractures: case-matched comparison of anterior versus posterior approaches for Pipkin I and Pipkin II fractures. *J Orthop Trauma.* 1992;6(4):437-42.