

Ultrasound of the ankle

Cheryl Jane Bass and Peter John Marriott

Victoria House Medical Imaging, Prahran, Victoria 3181, Australia.

Correspondence to Cheryl Bass via ASUM. Email author@asum.com.au

Introduction

The ankle is characterised by long tendons with strong muscles. Tendon failure occurs due to overuse of the tendons as a result of repetitive contraction of the muscles. It also occurs because these tendons often pivot around a bony fulcrum or beneath a retinaculum, creating points of friction. The third area where ankle tendons fail is where they join to bone, either directly into the bone or via an accessory ossicle, in which case there may be a stress injury between the ossicle and the main bone^{1,2,3}.

The posterior ankle

The Achilles tendon is the largest tendon in the body. It does not have a tendon sheath but it does have a U-shaped paratenon wrapping around the tendon from its dorsal aspect. The Achilles tendon is the archetypical tendon with a linear fibrillar pattern. It is formed in the mid-calf from the medial and lateral gastrocnemius muscles and is joined by the soleal tendon in the distal calf. It inserts into a relatively small footprint on the posterosuperior aspect of the calcaneus. Plantar flexing the ankle will allow the true insertion of the Achilles tendon to be recognised. Between the calcaneus and the Achilles tendon there is a retrocalcaneal bursa. A normal bursa is thin walled and contains only a slither of fluid.

Overuse injuries of the Achilles tendon

These occur in the mid-tendon and are characterised by fusiform enlargement, hypoechogenicity and hypervascularity. Initially the fibrillar pattern is maintained but as the fibres start to break, the tendon develops a grainy appearance. (Figs. 1a, 1b and 1c) Linear insubstance tears may develop^{4,5}.

Rupture of the Achilles tendon

Complete tears of the Achilles tendon are usually a traumatic event. Tears commonly occur in the mid tendon and can be misdiagnosed because the resultant haemorrhage and oedema filling the gap can mimic tendinopathy (Fig. 2). This is a bad “miss”. If in doubt, dorsiflex the ankle, the tendon remains slack, the gap opens up and the proximal tendon doesn’t move. Occasionally tears are incomplete, in which case it is important to document what percentage of the ten-

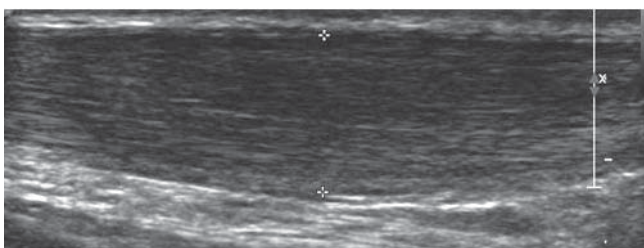


Fig. 1a: Longitudinal section through thickened hypoechoic mid Achilles tendinopathy.

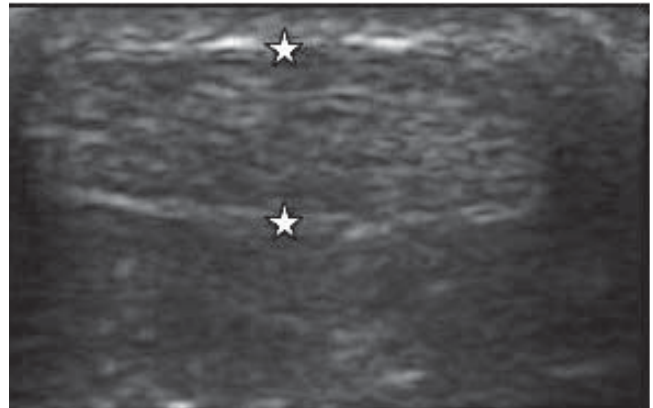


Fig. 1b: Transverse sections through the Achilles tendon with stars measuring the AP diameter note flattened shape.

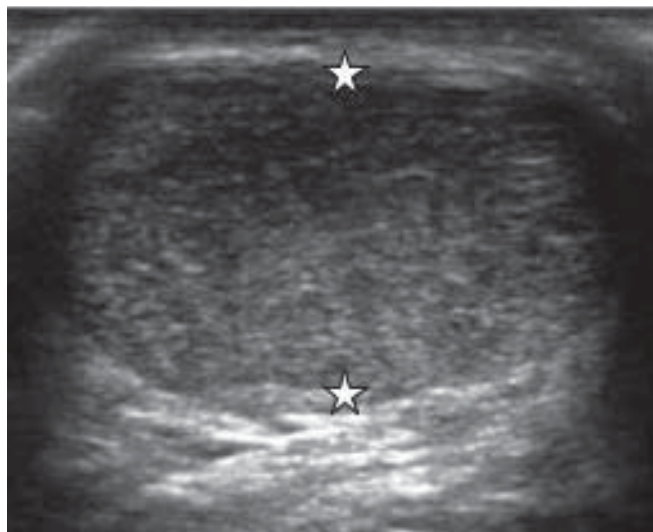


Fig. 1c: Transverse section through the Achilles tendon at the level of the crosses demonstrates marked increased in AP dimension with rounding off of the tendon consistent with moderate tendinopathy.

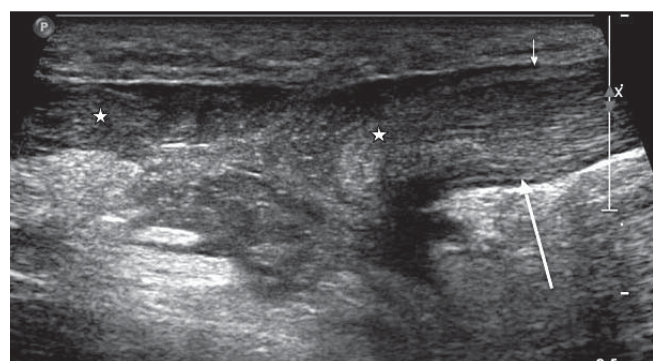


Fig. 2: Complete rupture of the Achilles tendon with haemorrhage and debris filling the gap between the torn ends (stars). The arrows point to the distal tendon which has a slack appearance due to loss of tension.

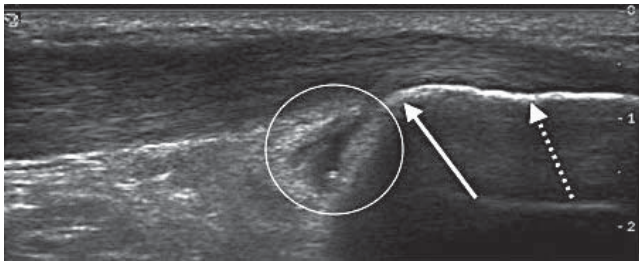


Fig. 3a: Superior extent of the insertion of the Achilles tendon (broken arrow), unbroken arrow points to the postero-superior corner of the Achilles tendon, circle surrounds the thick walled retrocalcaneal bursa which extends between the bone and the Achilles tendon as far down as the broken arrow. The Achilles tendon itself looks thickened and hypoechoic.

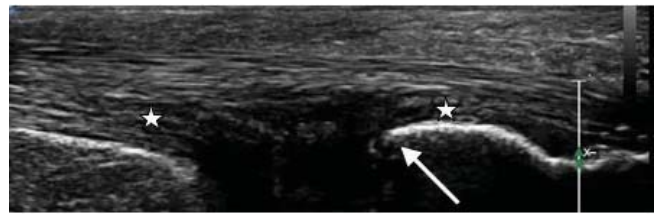


Fig. 3b: Deep surface severe tendinopathy of the distal Achilles tendon between stars, postero-superior corner of calcaneus which is indenting the tendon (arrow).

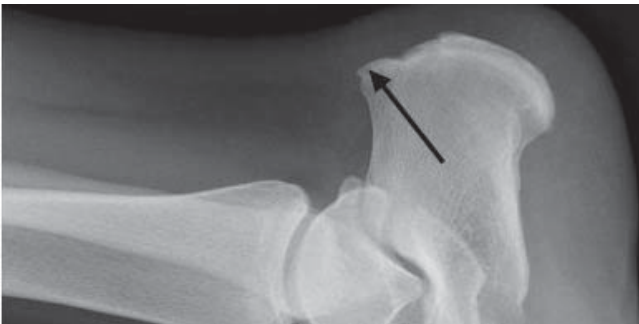


Fig. 3c: Haglund's deformity.

don is still intact.

Insertional problems of the Achilles tendon

Traction stress occurs where the Achilles inserts into the calcaneus. Proximally directed bone spurs are visible on x-ray and ultrasound. The spurs are within the tendon and variable degrees of insertional tendinopathy associated with hyperaemia both within the tendon and in the surrounding soft tissues are seen.

There may be pre-calcaneal bursitis. Careful targeted ultrasound is essential and correlation with where the patient is sore⁶.

Bursitis

The retrocalcaneal bursa is a protective structure to allow glide of the Achilles tendon over the postero-superior cor-

ner of the calcaneus. A small amount of fluid in the bursa is normal. When friction occurs the bursa can become thick walled, hyperaemic and contain fluid and is often associated with deep surface Achilles tendinopathy. A pointed shape to the postero-superior corner of the calcaneus "Haglund's deformity" may be visible on US and x-ray (Figs. 3a, 3b, 3c).

Paratenonitis

Normally barely visible, the paratenon becomes thickened, hypoechoic and hyperaemic (Figs. 4a, 4b). The thickening may be concentric or only involve a segment of the paratenon. It can occur in isolation or in association with tendinopathy. Take care to avoid mistaking edge artefact for the paratenon. It is an important diagnosis to recognise as treatment is different to that required for Achilles' tendinopathy.

Plantaris

This is a small, said to be residual tendon, and although is not always present, it is seen in most patients. It is easiest to find it on the medial side of the distal Achilles tendon approximately 1 cm above the insertion. It can then be followed proximally and laterally. It is not always ruptured when the Achilles tendon ruptures and the presence of an intact plantaris should not be mistakenly interpreted as part of the Achilles tendon still being intact.

Fusiform tendinopathy usually develops where the plantaris tendon passes between the soleus and gastrocnemius muscles (a point of friction). Spontaneous rupture is seen as discontinuity, proximal retraction and haemorrhage.

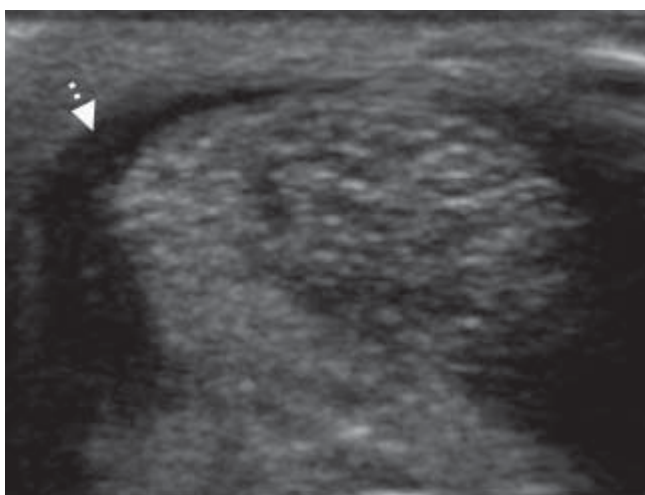


Fig. 4a: Eccentrically thickened hypoechoic paratenon.

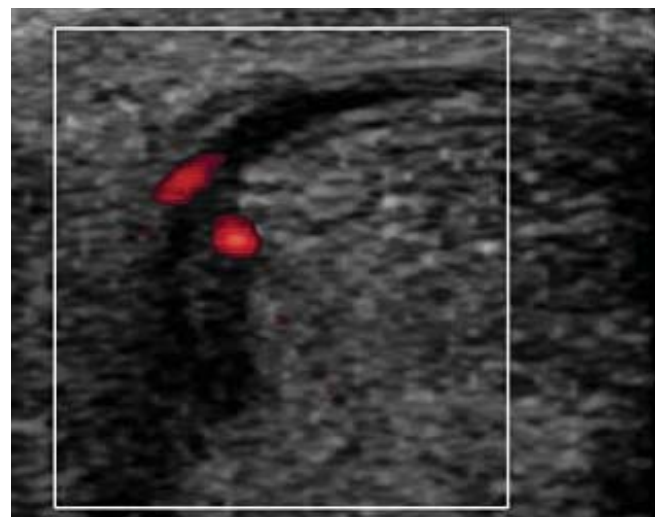


Fig. 4b: Associated hyperaemia.

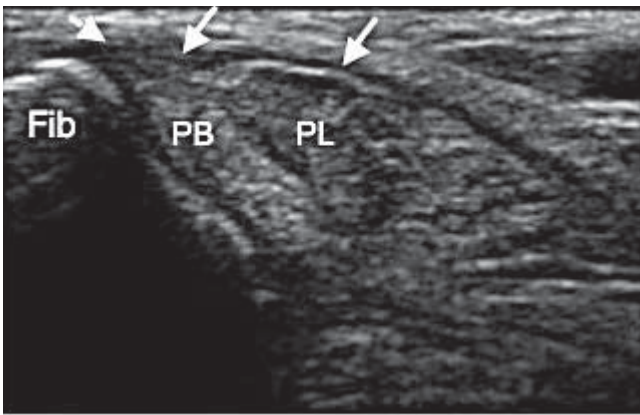


Fig. 5a: Transverse section through the lateral ankle at the level of the lateral malleolus demonstrating normal appearing peroneus brevis, peroneus longus and a normal thickness to the superior peroneal retinaculum (arrows).

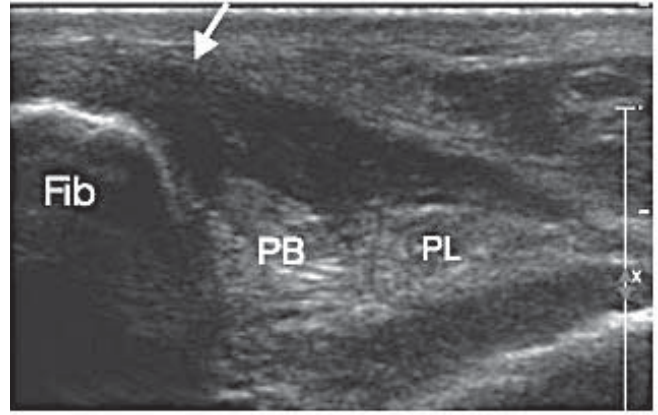


Fig. 5b: Markedly thickened superior peroneal retinaculum (arrow) secondary to stress injury following inversion. The peroneal tendons appear normal.

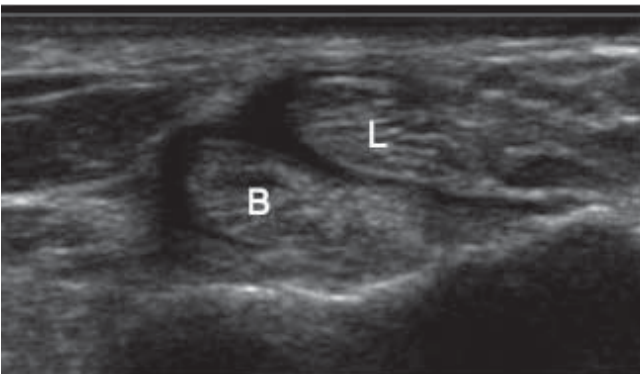


Fig. 6a: Small amount of fluid in the tendon sheath surrounding peroneus longus and brevis.

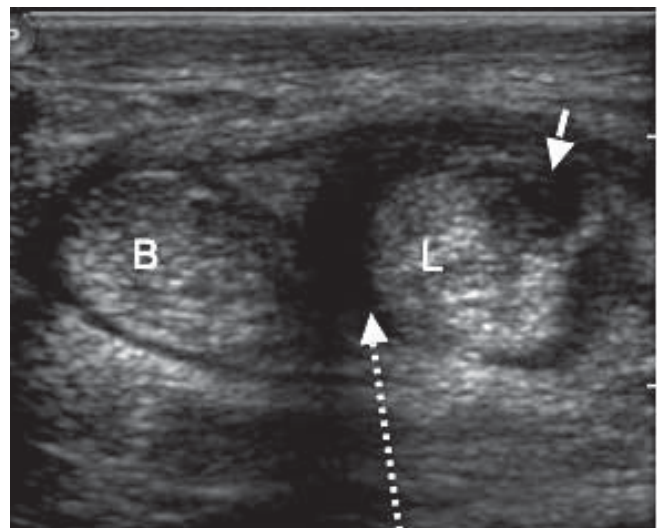


Fig. 6b: The peroneal tendons are thickened and there is an insubstance round split (solid arrow) within peroneus longus and a moderate amount of fluid within the sheath (broken arrow).

The lateral ankle

Peroneus longus and brevis

The lateral ankle tendons are the peroneus longus and brevis. They arise from the lateral fibula and are the main everters of the hindfoot. The peroneals can easily be followed in transverse plane from their origin to the level of the lateral malleolus. They hook behind the retromalleolar sulcus of the fibula and are stabilised by the superior peroneal retinaculum (Figs. 5a, 5b).

The superior peroneal retinaculum runs from the fibula to the lateral calcaneus or anterior sheath of the Achilles. Distal to the lateral malleolus the peroneals diverge with peroneus brevis passing anterior to the peroneal tubercle of the calcaneum to insert into the base of the fifth metatarsal. Distally brevis is a thin tendon. Peroneus longus passes postero-inferior to the tubercle, around the lateral side of the foot to insert into the plantar aspect of the base of the first metatarsal and medial cuneiform.

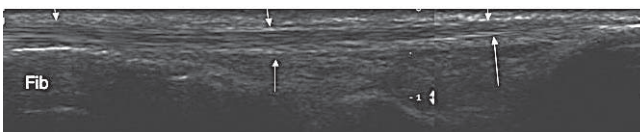


Fig. 7a: Longitudinal section through the peroneus brevis from the fibula to the insertion into the base of the fifth metatarsal. Note, in a normal patient, this is a thin tendon.

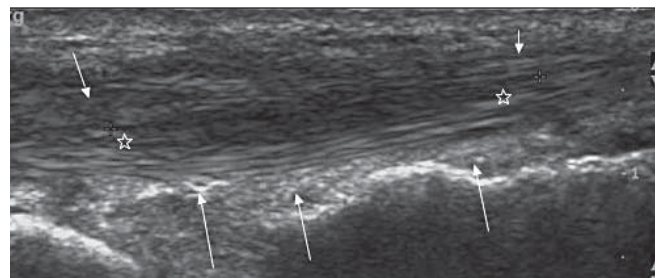


Fig. 7b: Longitudinal section through a thickened peroneus brevis with a grainy insubstance split. Hypervascularity was seen on colour Doppler.

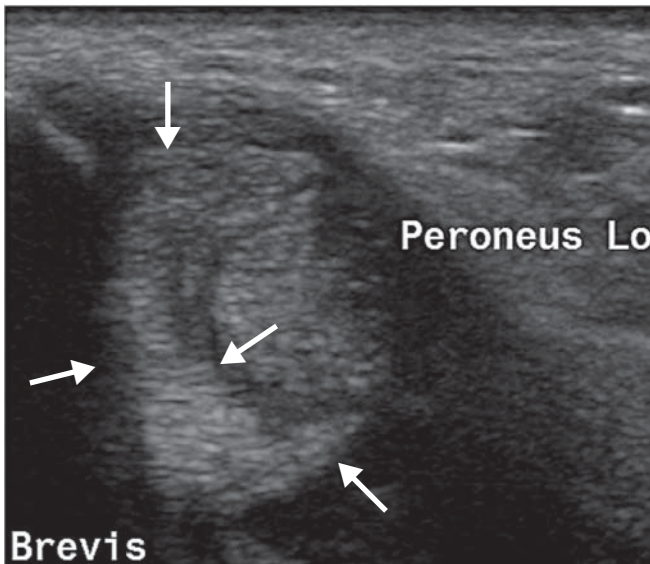


Fig. 8: Transverse section at the level of the lateral malleolus. The peroneus brevis has taken on a C-shape and is being indented by the peroneus longus tendon.

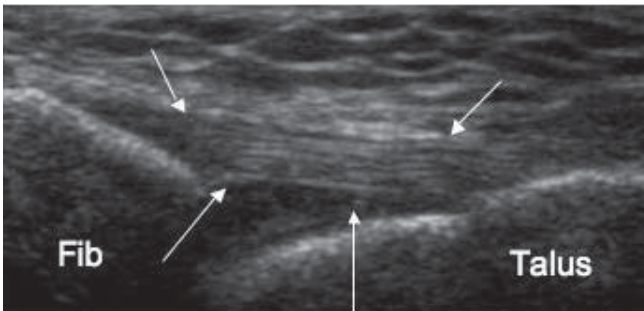


Fig. 9a: Normal well defined ATAF with nice fibrillar pattern and parallel echogenic margins stretching between the fibula and talus.

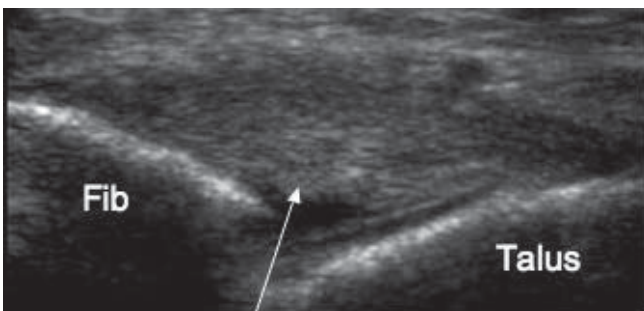


Fig. 9b: Moderately thickened and hypoechoic ATAF.

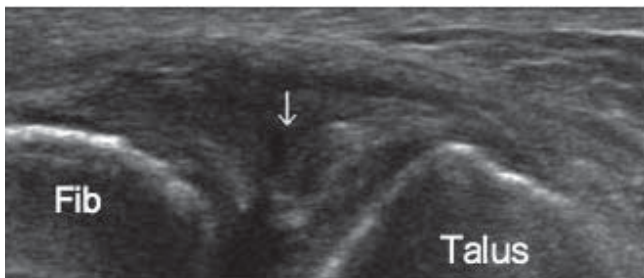


Fig. 9c: Discontinuity of the ATAF with fluid surrounding the torn ends (arrow).

abnormal finding, it is probably a degenerative process resulting in splitting of brevis but it is seen in many asymptomatic patients and therefore the presence of a C-shaped brevis tendon alone is not necessarily significant (Fig. 8).

Tendinopathy can also occur as the peroneus longus pivots

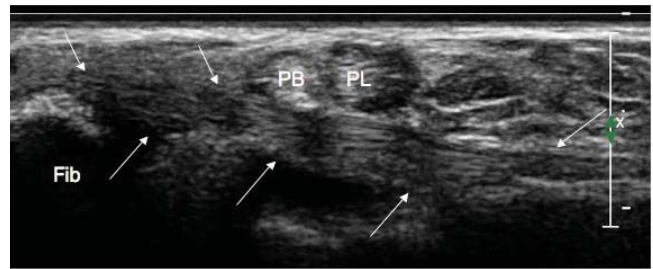


Fig. 10a: Normal calcaneofibular ligament between the arrows.

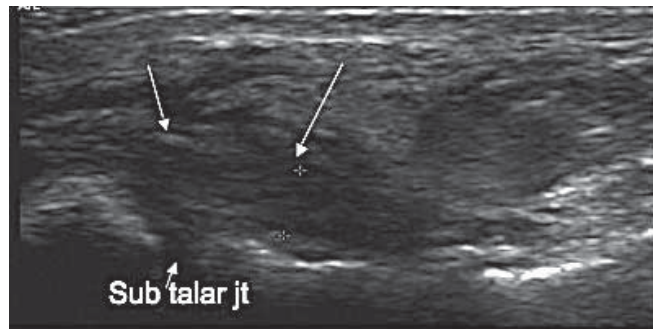


Fig. 10b: Thickening and hypoechoogenicity of the fibular end of the ligament seen here passing over the subtalar joint which contains a small of fluid.

around the lateral side of the foot. There is often an os peronei at this point. The presence of hypoechoogenicity within the tendon surrounding this ossicle, associated hyperaemia and point tenderness would indicate the diagnosis of tendinopathy⁸.

Dislocating peroneals

If the superior and inferior peritoneal retinaculum are disrupted, the peroneal tendons can sublux or dislocate anterior to the lateral malleolus with a palpable click. This is a clinical diagnosis that ultrasound can confirm.

The lateral ligaments

The lateral ligament complex connects the fibula to the talus and calcaneus. It consists of the anterior talo-fibular (ATAF), the calcaneo-fibular ligament (CF) and the posterior talo-fibular ligament (PTF). US is about 90% accurate for diagnosing injury to ATAF and the CF). The (PTF) is not routinely evaluated^{9,10}.

The ATAF blends with the ankle capsule and runs from the inferior margin of the fibula to the lateral margin of the talus close to the junction of the talar body and neck. It becomes progressively tighter as the ankle is brought into plantar flexion and inversion and this is the best position to scan it in (Fig. 9a). In acute injuries it may be thickened, partially or completely ruptured (Figs. 9b, 9c). In a recent rupture, the torn ends of the ligament can be identified. Once torn, the ligament rarely heals and may not be identified at all on US. Dynamic evaluation is not valuable in the acute phase but in the chronic case it can be useful.

The CF ligament originates from the inferior margin of the fibula distal to the ATAF and runs posteriorly and inferiorly deep to the peroneal tendons and over the top of the subtalar joint to insert into the lateral tubercle of the calcaneum. It is a much more defined band of tissue than the ATAF (Fig. 10a).

Inversion of the ankle will tauten the ligament, increasing visibility and reducing anisotropy at the fibular end. The main trick is to line up along the longitudinal plane of the ligament

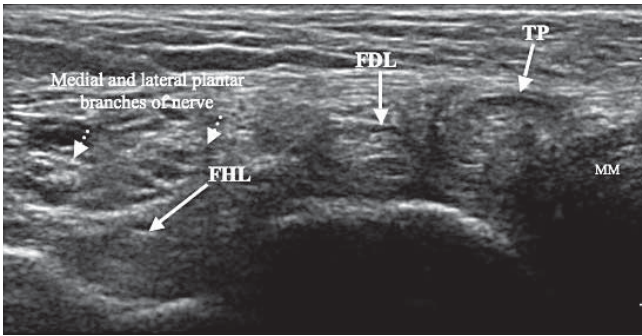


Fig. 11: Transverse section through a normal medial ankle just below the level of the medial malleolus demonstrating the three tendons and also the posterior tibial nerve which has divided it into its medial and lateral plantar branches.

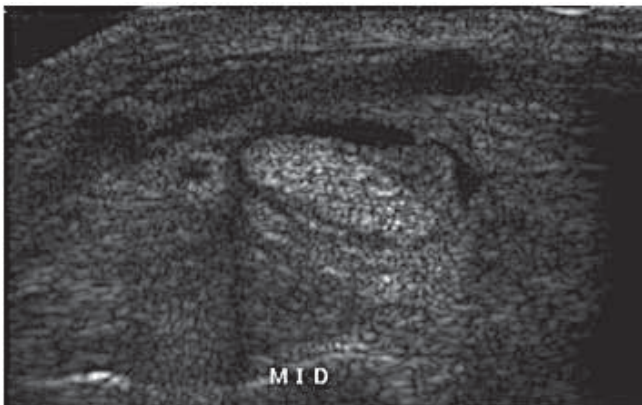


Fig. 12a: Mild thickening of the tendon sheath of tibialis posterior with a small amount of fluid surrounding the tendon.

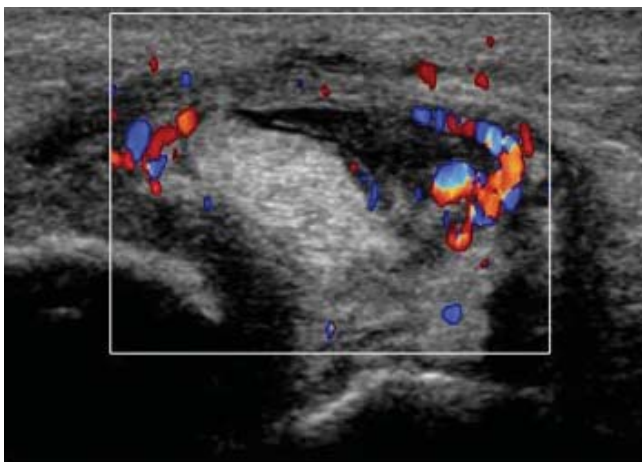


Fig. 12b: Transverse section through a moderately thickened tibialis posterior tendon with marked thickening and hyperaemia of its sheath.

and check for thickening, continuity and laxity (Fig. 10b). When the ligament is intact and functional inverting the dorsiflexed ankle will cause the CF ligament to lift away from the bone and compress the peroneal tendons against the overlying superior retinaculum, hence they look flat not round.

Fluid may be seen in the subtalar joint and more fluid may be squeezed out with inversion stress.

The medial ankle

The mnemonic for order of the medial ankle is “Tom, Dick And Very Naughty Harry”, standing for tibialis posterior (TP), flexor digitorum longus (FDL), flexor hallucis (FHL) and the neurovascular bundle (Fig. 11). All tendons have

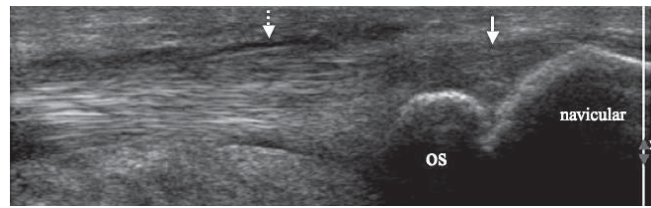


Fig. 13: Longitudinal section through tibialis posterior distal to the medial malleolus down to the insertion into the navicula via an os naviculare. There is a small amount of fluid in the sheath (broken arrow) secondary to more proximal tendinopathy but the distal insertion is normal even though it can appear a little hypoechoic and grainy (solid arrow).

individual sheaths. The three muscles arise from the deep posterior aspect of the calf. The tendons of TP and FDL hook around the medial malleolus with TP inserting predominantly into the navicula and FDL tendon passing under FHL to the plantar aspect of the foot to insert into the distal phalanges of the second to fifth toes. Scanning from the muscle to the tendon is the best way to avoid mistaking the FDL for the TP and therefore not overlooking TP pathology. FHL arises from the fibula. The thick tendon crosses the ankle joint posteriorly and inferior to the other two tendons. It runs in a groove along the calcaneus, passing distally and at the level of the Knot of Henry crosses FDL to course obliquely to the plantar aspect of the foot, inserting into the distal phalanx of the great toe.

Tibialis posterior

Pathology usually starts at the level of the medial malleolus and extends down towards the navicular but it can also be seen proximal to the malleolus in severe cases. Tendon sheath thickening and fluid precede tendon change. Initially, the tendon may be subtly thickened, best appreciated by comparative transverse images of the contralateral tendon. Later the thickening is more obvious and insubstance splits develop. These are often peripherally situated at or just below the level of the medial malleolus (Figs. 12a, 12b)¹¹. Long standing rupture of the TP can be disconcerting, it gives a lovely view of the deltoid. But acute rupture can be tricky as the sheath fills with haemorrhage and debris, which can be mistaken for severe tendinopathy. Try everting the ankle and look for discordant movement.

Insertional pathology

The second point of stress on the TP is where it inserts into the navicular bone. As the normal tendon splays and can look a bit grainy at the insertion (Fig. 13). The presence of hyperaemia and tendon sheath thickening/fluid allows a more confident diagnosis of insertional tendinopathy¹². Similar symptoms occur in patients with an accessory navicular bone who develop a stress reaction between the ossicle and the navicular bone proper. Sonopalpation will elicit focal pain and there may be hyperaemia seen flicking between the navicula and the accessory ossicle.

Flexor digitorum longus

Very little goes wrong with FDL. Occasionally, tendinopathy is identified.

Flexor hallucis longus

The sheath of this tendon is often in continuity with the ankle joint proper and therefore ankle effusions may result

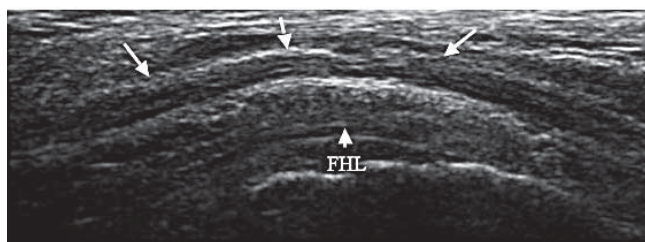


Fig. 14: Normal posterior tibial nerve seen in its long axis as it runs through the tarsal tunnel superficial to flexor hallucis longus.

in fluid in the FHL tendon sheath. It is characteristically dancers who have problems with their FHL and this is usually seen as fluid within the sheath and slight thickening of the sheath but there may be focal enlargement of the tendon or small incomplete tears of the medial edge of the musculotendinous junction. These are difficult diagnoses to make and comparison with the other side is often useful. Lack of tension proximally in FHL may indicate tendon rupture in the mid foot.

Posterior tibial nerve

This is best identified as it passes over the top of flexor hallucis at the level of the ankle joint. It can then be traced proximally in a transverse plane to the level of the muscle belly of tibialis posterior and distally as it passes through the tarsal tunnel and divides into its medial and lateral plantar branch (Fig. 14). Neuritis occurs secondary to compression e.g. by a ganglion in the tarsal tunnel.

The deltoid ligament

The anterior deltoid is a wide, strong ligament comprising the tibionavicular fibres, tibioliamentous complex to the spring ligament and the more posterior tibiocalcaneal segment. Scan in a radial fashion from the anterior tip of the medial malleolus in a coronal plane. By moving the transducer to the posterior border of the malleolus and in a slightly posterior oblique plane, the shorter tibiotalar segment may also be seen.

The posterior deltoid appears more hypoechoic with the deeper tibiotalar fibres less well defined than the more superficial anterior ligament components¹³ (Fig. 15a).

Posteromedial impingement (POMI) is a sequela of an inversion injury as a result of the deep posterior fibres of the deltoid ligament being crushed between the medial wall of the talus and the medial malleolus. Initial symptoms relate to the lateral ankle component of the injury but subsequent medial pain and swelling can arise secondary to synovitis and formation of bulky scar tissue involving the deltoid ligament with resultant impingement between the talus and posterior margin of the medial malleolus (Figs. 15b, 15c).

The anterior ankle

The three tendons in the anterior aspect of the ankle from medial to lateral are tibialis anterior, extensor hallucis longus (EHL) and extensor digitorum longus (EDL). These all have to pass beneath retinaculae and have sheaths to protect them as they do this.

Tibialis anterior

The tendon of tibialis anterior forms in the shin and passes

beneath the superior and inferior extensor retinacula. These are points of potential friction where tendinopathy may be identified. It inserts into the lateral and undersurface of the medial cuneiform and base of first metatarsal. Distal insertional tendinopathy, often in the more medial fibres, is the commonest pathology seen, appearing as the usual triad of a thickened, hypoechoic and mildly hypervascular tendon (Figs. 16a, 16b). Enthesopathy is a frequent accompaniment to this¹⁴. Tibialis anterior can also be accidentally severed.

Extensor hallucis longus

EHL is situated lateral to tibialis anterior; it also has to pass beneath the two retinacula and then passes over the tarsus before inserting into the distal phalanx of the big toe. Overuse or frictional tendinopathy is unusual. The commonest pathol-

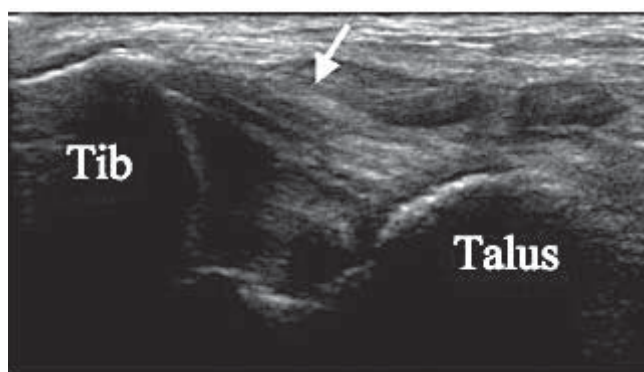
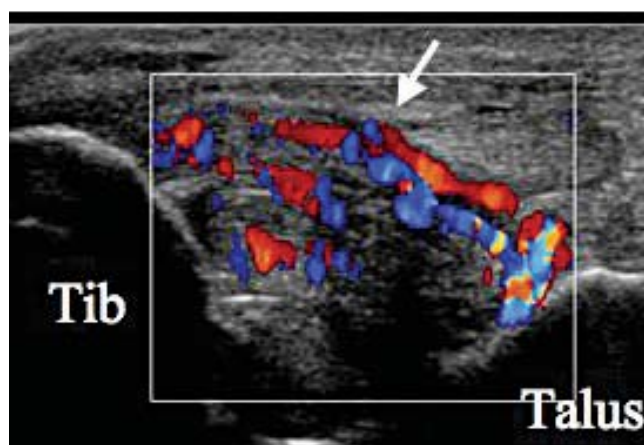
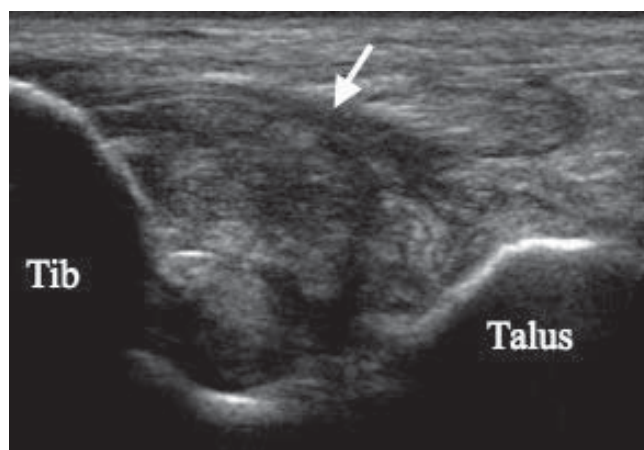
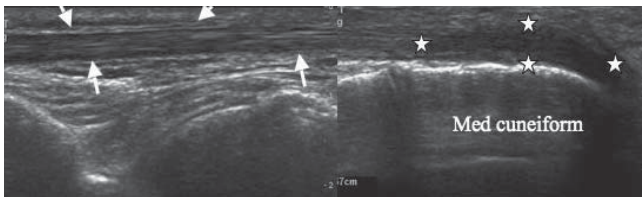


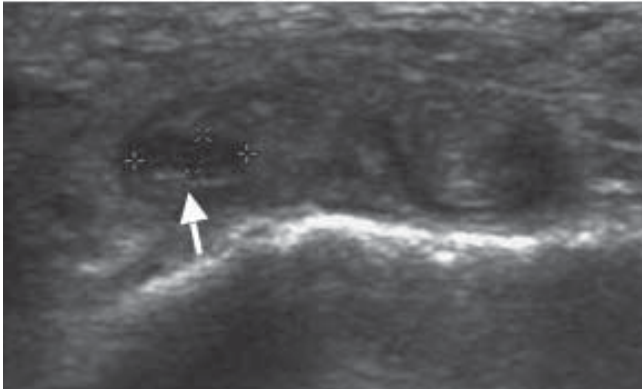
Fig. 15a: Normal deltoid ligament running between the tibia and talus with the more superficial fibres appearing more echogenic and the deeper fibres hypoechoic.



Figs. 15b and 15c: Thickened heterogeneous abnormal deltoid demonstrating hyperaemia.



Figs. 16a: Longitudinal and transverse sections through the insertion of tibialis anterior demonstrating thickening and hypoechogenicity of the distal fibres.



16b: Transverse section of the insertion of tibialis demonstrating tendonopathy with medial defect.

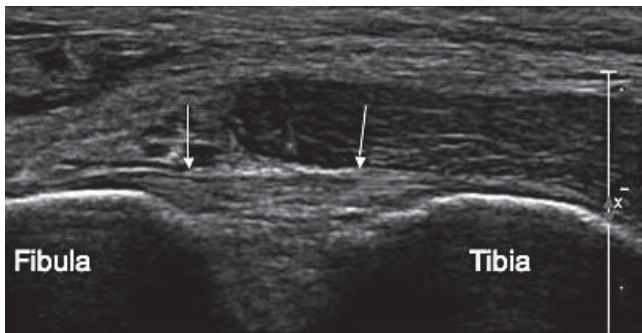


Fig. 17a: Normal anterior tibiofibular ligament stretched between the distal tibia and fibula seen as a well defined fibrillar structure.

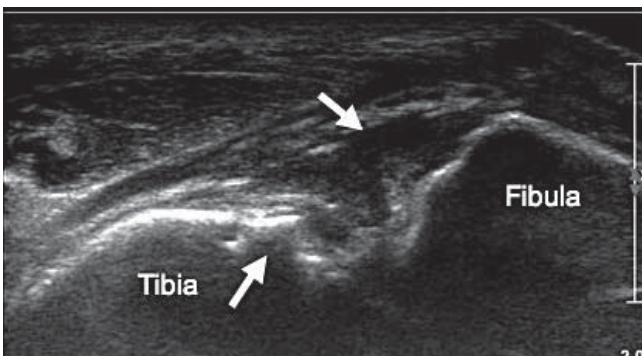


Fig. 17b: Complete disruption to the ligament with bony irregularity of particularly the tibial margin and fluid in the gap.

ogy is traumatic transection e.g. by a cook dropping a knife.

Extensor digitorum longus

The extensor digitorum longus forms at the level of the ankle joint and only has to pass beneath the inferior extensor retinaculum. Tendinopathy can occur deep to the edge of the retinaculum, as the tendon passes over and rubs on bone spurs from osteoarthritic tarsal joints or from trauma e.g. inversion of the ankle.

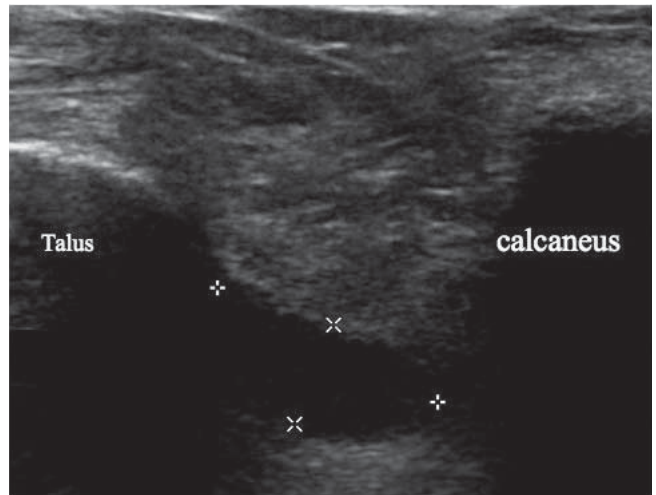


Fig. 18: Anechoic ganglion situated in the sinus tarsi fat between the talus and calcaneus.

The syndesmotic ligaments

The syndesmotic ligaments join the tibia and fibula¹⁵. Ultrasound visualises the anterior tibio-fibular ligament (ATIF) as a horizontal structure between the lower tibia and fibula. It is torn in more serious injuries and may result in an unstable ankle. Look for thickening, hypoechogenicity, disruption and bony irregularity (Figs. 17a, 17b). Check that the deltoid ligament is intact as this will influence the treatment plan.

Ganglia

Ganglia can occur just about anywhere around the ankle joint and sinus tarsi (Fig. 18). They usually present as painless lumps and are asymptomatic unless they cause pressure on either the footwear or adjacent tendons. Identifying their neck and hence which joint they are arising from can be tricky but needs to be done¹⁶.

The plantar side

Plantar fascia

The plantar fascia arises from the medial and lateral tubercles of the calcaneus and extends distally as a thick sheet of fibrous tissue over the sole of the foot. It is the first structure encountered after the subcutaneous fat. The commonest position of fasciitis is where the fibres arise from the medial side of the calcaneus either in the heel strike area or in association with a traction spur on the deeper aspect of the calcaneus. The middle fibres of the origin can also be involved but it is less common for the lateral fibres to be involved. Increased thickness and reduced echogenicity of the fascia are the key features but loss of the echogenic margins, increased convexity of the surface and heterogeneity may also be identified (Figs. 19a, 19b). Measurement alone can be misleading but a thickness of > 5 mm or a difference of > 2 mm between the symptomatic and asymptomatic sides can be used as a guide^{17,18}.

The plantar fascia may be completely torn, characteristically seen as avulsion from the calcaneus (Fig. 20).

Fibromata occur in the distal arch and distal fascia particularly medially. They are represented by focal thickening, which may be painful, and they may be hypervascular.

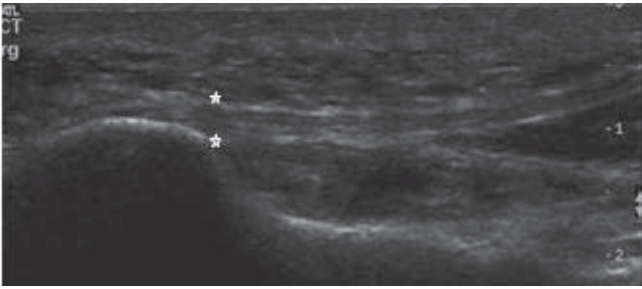


Fig. 19a: Longitudinal section through a normal plantar fascia.

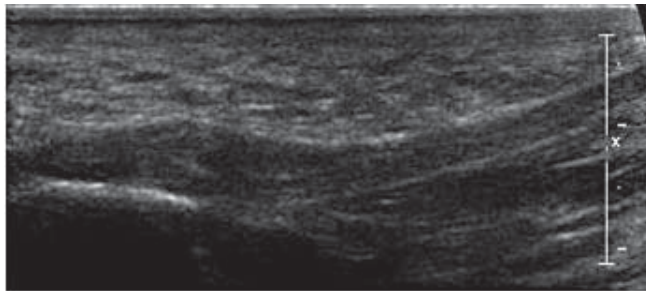


Fig. 19b: Thickened hypoechoic origin of the plantar fascia which has a convex superior margin.

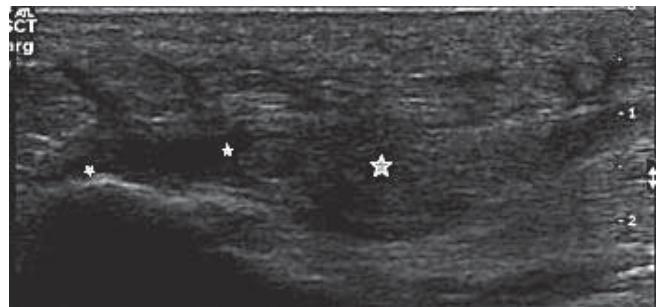


Fig. 20: Complete avulsion of the plantar fascia from the calcaneal tubercle.

And finally

Look for the uniform mildly echogenic fibrillar pattern and well defined margins that denote a normal tendon, ligament or fascia. Hypoechoogenicity, loss of fibrillar definition, hyperaemia and increased size are the cardinal signs of disease. When found, document it, measure it, try to identify what is causing it and look for associated pathology. The inescapable fact is that knowledge of normal anatomy is the keystone to ultrasound diagnosis.

References

- De Maeseneer M, Marcelis S, Jager T, Shahabpour M, Van Roy P, Weaver J, Jacobson JA. Sonography of the normal ankle: a target approach using skeletal reference points. *Am J Roentgenol* 2009; 192 (2): 487–95.
- Kong A, Cassumbhoy R, Subramaniam RM. Magnetic resonance imaging of ankle tendons and ligaments: Part I. *Australas Radiol* 2007; 51 (4): 315–23.
- Briggs L. Understanding ankle ultrasound. *Sound Effects* 1 2007; 20–5.
- Leung JL, Griffith JF. Sonography of chronic Achilles tendinopathy: a case-control study. *J Clin Ultrasound* 2008; 36 (1): 27–32.
- Harris CA, Peduto AJ. Achilles tendon imaging. *Australas Radiol* 2006; 50 (6): 513–25.
- Benjamin M, Toumi H, Ralphs JR, Bydder G, Best TM, Milz S. *J Anat*. Where tendons and ligaments meet bone: attachment sites (“enthuses”) in relation to exercise and/or mechanical load. *J Anat* 2006; 208 (4): 471–90.
- Dombek MF, Lamm BM, Saltrick K, Mendicino RW, Catanzariti AR. Peroneal tendon tears: a retrospective review. *J Foot Ankle Surg* 2003; 42 (5): 250–8.
- Brigido MK, Fessell DP, Jacobson JA, Widman DS, Craig JG, Jamadar DA, van Holsbeeck MT. Radiography and US of os peroneum fractures and associated peroneal tendon injuries: initial experience. *Radiology* 2005; 237 (1): 235–41.
- Milz P, Milz S, Putz R, Reiser M. 13MHz high-frequency sonography of the lateral ankle joint ligaments and the tibiofibular syndesmosis in anatomic specimens. *J Ultrasound Med* 1996; 15 (4): 277–84.
- Chan KM, Karlsson J. ISKOS World consensus conference on ankle instability Jan 2005.
- Prekumar A, Perry MB, Dwyer AJ, Gerber LH, Johnson D, Venzon D, Shawker TH. Sonography and MR imaging of posterior tibial tendinopathy. *Am J Roentgenol* 2002; 178 (1): 223–32.
- Mengiardi B, Pfirrmann C, Zanetti MR. Imaging of tendons and ligaments of the midfoot. *Semin Musculoskelet Radiol* 2005; 9 (3): 243–59.
- Hinterdman B, Knupp M, Magenstert GI. Deltoid ligament injuries: diagnosis and management. *Foot Ankle Clin* 2006; 11 (3): 625–37.
- Mengiardi B, Pfirrmann CW, Vienne P, Kundert HP, Rippstein PF, Zollinger H, Hodler J, Zanetti M. Anterior tibial tendon abnormalities: MR imaging findings. *Radiology* 2005; 235 (3): 977–84.
- Mei-Dan O, Kots E, Barchilon V, Massarwe S, Nyska M, Mann G. A dynamic ultrasound examination for the diagnosis of ankle syndesmotomic injury in professional athletes: a preliminary study. *Am J Sports Med* 2009; 37 (5): 1009.
- Ortega R, Fessell DR, Jacobson JA, Lin J, Van Holsbeeck MT, Hayes CW. Sonography of ankle ganglia with pathologic correlation in 10 pediatric and adult patients. *Am J Roentgenol* 2002; 178 (6): 1445–9.
- Akfirat M, Sen C, Günes T. Ultrasonographic evaluation in plantar fasciitis. *J Foot Ankle Surg* 2007; 46 (6): 442–6.
- Wearing SC, Smeathers JE, Sullivan PM, Yates B, Urry SR, Dubois P. Plantar fasciitis: are pain and fascial thickness associated with arch shape and loading? *Phys Ther* 2007; 87 (8): 1002–8.