

Received: 2011.12.12
Accepted: 2012.01.19

Multiple fusiform cerebral aneurysms – case report

Katarzyna Jaworska, Joanna Dołowy, Małgorzata Kuśmierska, Tomasz Kuniej,
Przemysław Jaźwiec

Department of Medical Radiology and Diagnostic Imaging, 4th Military Clinical Hospital with the Polyclinic in Wrocław,
Wrocław, Poland

Author's address: Katarzyna Jaworska, Department of Medical Radiology and Diagnostic Imaging, 4th Military Clinical
Hospital with the Polyclinic in Wrocław, R. Weigla 5 St., Wrocław, Poland, e-mail: katarzyna.m.jaworska@gmail.com

Summary

Background:

A true aneurysm is a dilation of arterial lumen as a consequence of congenital or acquired abnormalities leading to a reduction of mechanical resistance of vascular wall, most commonly caused by its defected structure in the form of absence or weakening of the muscular and/or elastic layer. From the pathophysiological point of view, cerebral aneurysms can be classified as 'saccular' – most commonly occurring, and 'other types', including fusiform/dolichoectatic, dissecting, serpentine, posttraumatic, mycotic and giant aneurysms with or without intra-aneurysmal thrombosis.

Case Report:

We present a rare case of a patient with multiple fusiform dilations of cerebral vessels and giant fusiform aneurysm in supraclinoid segment of the internal carotid artery. The patient presented to hospital because of sudden, severe vertigo with nausea, impaired balance and disturbed vision. Vascular anomalies were detected on CT scanning without contrast. The diagnostic work-up was complemented by CT angiography, MRI and cerebral angiography.

Conclusions:

Aneurysm located within the intracranial arteries is one of the most common vascular defects of the brain. The number, size and location of aneurysms are highly variable. Aneurysms can have either supra- or infratentorial location, affecting a single or multiple arteries within one or both brain hemispheres. There is often a correlation between the location of the aneurysm and its etiology, as in case of so-called mirror-image aneurysms. Symmetrically located aneurysms may indicate a defect in vascular structure. Asymmetric location, as in the patient described above, is more likely due to acquired causes, mainly atherosclerosis, but also septic emboli or blood disorders.

Key words:

fusiform aneurysm • dolichoectasia • cerebral giant aneurysm • angio-CT • angiography • endovascular treatment

PDF file:

<http://www.polradiol.com/fulltxt.php?ICID=882581>

Background

A true aneurysm is a dilation of arterial lumen as a consequence of congenital or acquired abnormalities leading to a reduction of mechanical resistance of vascular wall, most commonly caused by its defected structure in the form of absence or weakening of the muscular and/or elastic layer [1]. From the pathophysiological point of view cerebral aneurysms can be classified as 'saccular' – most commonly occurring, and 'other types', including fusiform/dolichoectatic, dissecting, serpentine, posttraumatic, mycotic and giant aneurysms with or without intra-aneurysmal

thrombosis [2]. Terms 'fusiform' and 'dolichoectatic' are often used interchangeably, but according to the definition, dolichoectasia also includes elongation of an artery apart from its segmental widening.

The prevalence of intracranial aneurysms in the human population is estimated to be 2-8% [3], with multiple aneurysms in about 1/5 of all cases [4]. They coexist with many other diseases, including polycystic kidney, connective tissue diseases, generalized scleroderma, Conn's syndrome, Recklinghausen disease type I. Atherosclerosis, hypertension and smoking are important risk factors of multiple

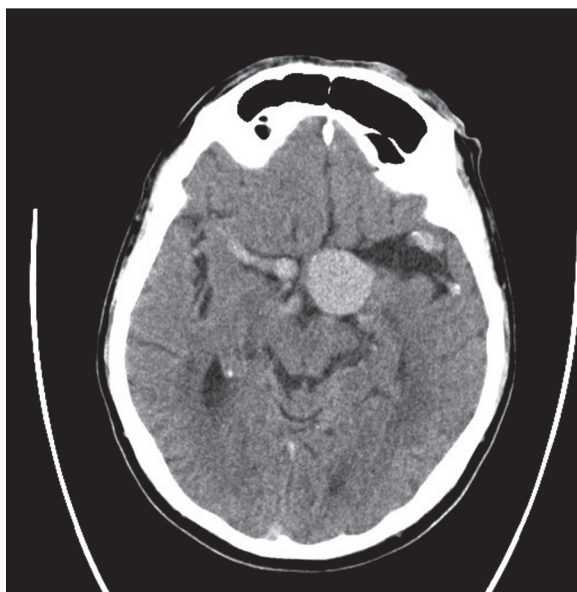


Figure 1. Non-enhanced CT scan (axial view) shows giant aneurysm of left internal carotid artery, aneurysm of right internal carotid artery, dilatation of middle cerebral arteries.

aneurysms [1]. Approximately 90% of all aneurysms are manifested by spontaneous intracranial hemorrhage. Other cases manifest with symptoms related to aneurysmal expansion or remain asymptomatic and can be detected incidentally during routine diagnostics or searching for a different intracranial aneurysm [3].

Case Report

A 55-year-old man with chronic heart failure, chronic kidney disease and moderate arterial hypertension was admitted to the Department of Neurology in the 4th Military Clinical Hospital in Wrocław as an emergency due to sudden, severe vertigo accompanied by impaired balance and disturbed vision, gait difficulties and nausea. The neurological examination revealed: horizontal nystagmus, left-sided facial hypoesthesia, abnormal finger-nose and heel-knee tests and a positive Babinski sign on the left side. The patient was referred to an urgent non-contrast brain CT that showed aneurysmal dilations of multiple cerebral arteries (Figure 1) Angio-CT of cerebral, carotid and vertebral arteries, as well as magnetic resonance imaging examination of the head using a paramagnetic contrast agent (Figure 2) were performed additionally. Diagnostic procedures were complemented by a conventional cerebral angiography. Multiple dilated and tortuous vessels of the circle of Willis were found, as well as a giant aneurysm (measuring 34×24 mm) in the left internal carotid artery, including its division into anterior and middle cerebral artery and proximal segments of these arteries. The aneurysm was causing mass effect on the frontal horn of the left lateral ventricle and compressing the third ventricle and thalamus on the left.

The left middle cerebral artery was enlarged to 6 mm. A widening of the right internal carotid artery to 6–7 mm in the supraclinoid segment and a dilation of the proximal right middle cerebral artery to 6.5 mm were visualized.

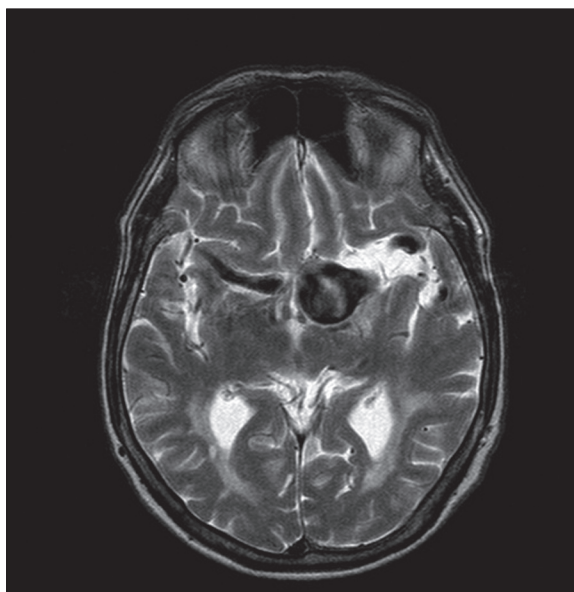


Figure 2. Axial contrast-enhanced T1-weighted MR image; fusiform giant aneurysm of left internal carotid artery.

Internal carotid arteries were dilated in the proximal parts of the extracranial segments. Within the basal artery, a saccular aneurysm sized 11×12 mm, with the presence of a mural thrombus was found, as well as a fusiform dilation characteristic for dolichoectasia, in the distal part of this vessel, covering also the initial portion of the right posterior cerebral artery. Pathologically malformed basilar artery compressed the left anterolateral part of pons. Vertebral arteries were enlarged to 4 mm on the right side and to 5.5 mm on the left.

In addition, computed tomography revealed a vascular malformation with bleeding in supraventricular layers of left parietal area, as well as minor vasogenic lesions, leukoariosis, cortico-subcortical atrophy and advanced cerebral atherosclerosis.

Neurosurgeons recommended a consultation regarding endovascular treatment, but the patient was disqualified from this type of therapy by neuroradiologist. The patient was transferred to the Department of Interventional Radiology (the Independent Public Clinical Hospital in Lublin) for potential specialist neurosurgical treatment.

Discussion

Aneurysm located within the intracranial artery is one of the most common vascular defects of the brain. The number, size and location of aneurysms are highly variable. Aneurysms can have either supra- or infratentorial location, affecting a single or multiple arteries within one or both brain hemispheres. There is often a correlation between the location of the aneurysm and its etiology, as in case of so-called mirror-image aneurysms. Symmetrically located aneurysms may indicate a defect in vascular structure. Asymmetric location, as in the patient described above, is more likely due to acquired causes, mainly atherosclerosis, but also septic emboli or blood disorders [4].

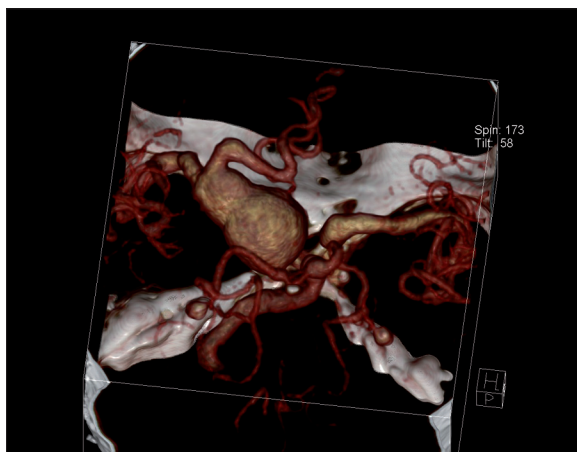


Figure 3. Angio-CT examination, VRT reconstruction; fusiform giant aneurysm of left internal carotid artery occupying its bifurcation.

Morphological classification distinguishes saccular aneurysms that are commonly found and fusiform aneurysms, which represent 3–13% of all cases according to various literature data. Recent reports indicate a gradually increasing prevalence of the latter [5]. In patients over 40 years of age, the atherosclerosis and arterial hypertension are the important risk factors of aneurysms. Fusiform aneurysms are common in males, and the average age of aneurysm detection is 45 years [5]. Connective tissue diseases play an important role in the pathogenesis of fusiform aneurysms. Other causes predisposing to vessel wall impairment leading to aneurysmal malformation include disturbed cerebral circulation, inflammation, smoking, alcohol and a positive family history. The symptoms of fusiform aneurysm are non-specific: headache, cranial nerve compression, ataxia, varying degrees of paresis, sometimes stroke. They may cause a mass effect. Bleeding from fusiform aneurysms occurs much less frequently as compared to intracranial hemorrhage caused by saccular aneurysm. [5]

Fusiform aneurysms are usually located within the basilar artery and vertebral arteries, with dolichoectasia vertebralis being their specific form. They also occur within the middle cerebral arteries and internal carotid arteries. [5]

Fusiform aneurysms may constitute a minor widening of the vessel lumen, including a single or multiple arteries, or large, tortuous dolichoectasias. They may also have giant serpentine forms [6]. Intracranial aneurysms with a diameter exceeding 25 mm are referred to as giant aneurysms (Figure 3) and represent approximately 3–5% of all aneurysms, whereas the incidence of giant fusiform aneurysms is estimated to be less than 1% of all intracranial aneurysms. The presence of mural thrombus (Figure 4), episodes of intracranial hemorrhage and symptoms of expansion are

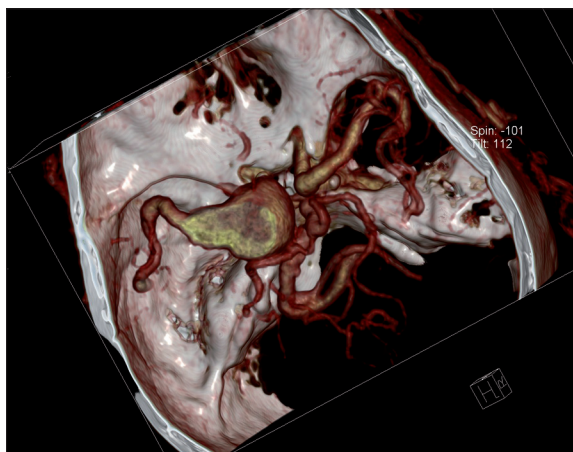


Figure 4. Angio-CT examination, VRT reconstruction; fusiform giant aneurysm of left internal carotid artery with parietal thrombus.

the characteristic features of a giant aneurysm manifestation [7,8].

The imaging methods of intracranial aneurysms include non-invasive and invasive procedures. The non-invasive methods comprise computed tomography angiography (angio-CT) and magnetic resonance angiography (angio-MR). A “golden standard” and, until recently, the only method allowing to determine the source of bleeding has been the invasive cerebral angiography. However, this method carries a risk of complications and re-bleeding from the aneurysm. Currently, the role of noninvasive tests is significantly increasing, mainly due to the advantages of spiral CT such as: high-speed data acquisition and high-quality secondary reconstructions. The assessment of vessels during maximum contrast enhancement within a short period of study using reconstruction software allows for obtaining images of value comparable to conventional angiography [3].

The treatment choice depends on the location, size, morphology and surgical accessibility of the aneurysm, as well as clinical status and patient’s age. For a long time, the only method of aneurysm management was the neurosurgical procedure. Nowadays, endovascular treatment (EVT) has become an alternative for aneurysm clipping, creating an opportunity for patients with inoperable aneurysms. Patients are qualified for endovascular treatment by neurosurgeons and radiologists. Currently, the treatment of fusiform aneurysms includes various methods, such as: wrapping, trapping, vascular stents and by-passes. The therapeutic procedure in patients with unruptured intracranial aneurysms is controversial. Endovascular treatment can prevent rupture of the aneurysm; however, it bears the risk of complications. The safety and efficacy of treatment of unruptured intracranial aneurysms have not been determined yet [1].

References:

1. Knap D, Partyka R, Zbrozarczyk M et al: Tętniaki mózgu – współczesne metody leczenia wewnątrzczaszkowego. *Pol Prz Neurol*, 2010; 6(1): 22–26 [in Polish]
2. Meyers PM, Schumacher HC, Higashida RT et al: Reporting standards for endovascular repair of saccular intracranial cerebral aneurysms. *J Neurointerv Surg*, 2010; 2(4): 312–23
3. Kowalewski K, Sasiadek M: Angiografia TK w diagnostyce tętniaków wewnątrzczaszkowych. *Adv Clin Exp Med*, 2004; 13(2): 349–58 [in Polish]

4. Żukiel R, Blok T, Majewski T et al: Tętniaki mnogie mózgu. Analiza kliniczna 31 przypadków. *Neuroskop*, 1999; 1(1): 13–19 [in Polish]
5. Park SH, Yim MB, Lee CY et al: Intracranial Fusiform Aneurysms: It's Pathogenesis, Clinical Characteristics and Managements. *J Korean Neurosurg Soc*, 2008; 44(3): 116–23
6. Yasumi T, Komiyama M, Iwai Y et al: Evolution of incidentally-discovered fusiform aneurysms of the vertebrobasilar arteria system: neuroimaging features suggesting progressive aneurysm growth. *Neurol Med Chir (Tokyo)*, 2002; 41(11): 523–27
7. Sarica FB, Cekinmez M, Tufan K et al: A non-bleeding complex intracerebral giant aneurysm case: case report. *Turk Neurosurg*, 2008; 18(3): 236–40
8. Jaźwiec P, Chwiszczuk L, Sasiadek M et al: Olbrzymi tętniak tętnicy łączącej tylnej w obrazie panarteriografii naczyń mózgowych i angiografii metodą tomografii komputerowej angio-TK. *Przegląd Lekarski*, 2007; 64(12) :601–3 [in Polish]