



Original article

Total hip arthroplasty using a posterior minimally invasive approach – results after six years[☆]



José Ricardo Negreiros Vicente*, Helder Souza Miyahara, Carlos Malheiros Luzo, Henrique Melo Gurgel, Alberto Tesconi Croci

Instituto de Ortopedia e Traumatologia, Hospital das Clínicas, Faculdade de Medicina, Universidade de São Paulo, São Paulo, SP, Brazil

ARTICLE INFO

Article history:

Received 16 October 2013

Accepted 20 February 2014

Available online 31 December 2014

Keywords:

Hip osteoarthritis

Hip arthroplasty

Minimally invasive surgical procedures

ABSTRACT

Objective: To evaluate the medium-term clinical–functional results (minimum follow-up of six years) from total uncemented hip arthroplasty performed by means of a posterior minimally invasive access, in comparison with the traditional right lateral access.

Methods: In a comparative prospective study, 224 adult patients underwent elective total hip arthroplasty due to a diagnosis of primary or secondary osteoarthritis. A group of 103 patients with posterior minimally invasive access was compared with a group of 121 patients with the traditional right lateral access. The mean length of follow-up among the patients of this sample was 7.2 years. We evaluated the clinical–functional and radiographic results and occurrences of loosening, along with any complications that occurred, with a minimum follow-up of six years.

Results: The clinical–functional analyses before the surgical procedure and six years afterwards were similar in the two groups ($p=0.88$ and $p=0.55$). One patient in the minimally invasive group underwent revision of the acetabular component and two patients in the control group underwent the same procedure ($p=0.46$). The Trendelenburg clinical test, which showed weakness of the hip abductor musculature, was present in five patients operated using the traditional lateral route and absent in all those who underwent the minimally invasive procedure ($p=0.06$). There was no difference regarding the radiographic parameters obtained, either in acetabular or in femoral positioning ($p=0.32$ and $p=0.58$).

Conclusions: The medium-term clinical and radiographic results and the complication rates were similar between the patients who underwent total hip arthroplasty by means of the posterior minimally invasive access and those with the traditional lateral access.

© 2014 Sociedade Brasileira de Ortopedia e Traumatologia. Published by Elsevier Editora Ltda. All rights reserved.

[☆] Work developed by the Hip Group of the Institute of Orthopedics and Traumatology, University of São Paulo Medical School, São Paulo, SP, Brazil.

* Corresponding author.

E-mail: rmnegreiros@gmail.com (J.R.N. Vicente).

<http://dx.doi.org/10.1016/j.rboe.2014.12.005>

2255-4971/© 2014 Sociedade Brasileira de Ortopedia e Traumatologia. Published by Elsevier Editora Ltda. All rights reserved.

Artroplastia total do quadril feita por via posterior minimamente invasiva – Resultados após seis anos

R E S U M O

Palavras-chave:

Osteoartrite do quadril
Artroplastia de quadril
Procedimentos cirúrgicos
minimamente invasivos

Objetivo: Avaliar o resultado clínico-funcional em médio prazo (seguimento mínimo de seis anos) da artroplastia total do quadril não cimentada feita por acesso minimamente invasivo (MIS) posterior comparado ao acesso lateral direto (LD) tradicional.

Métodos: Em um estudo comparativo prospectivo, 224 pacientes adultos foram submetidos à artroplastia total do quadril em caráter eletivo, por diagnóstico de osteoartrose primária ou secundária, e se comparou o grupo MIS posterior (103 pacientes) com o grupo acesso LD tradicional (121). A média de tempo de seguimento dos pacientes da amostra foi 7,2 anos. Avaliamos os resultados clínico-funcionais e radiográficos e a ocorrência de solturas, assim como complicações ocorridas com um seguimento mínimo de seis anos.

Resultados: A análise clínico-funcional antes e seis anos após o procedimento cirúrgico foi semelhante nos dois grupos ($p=0,88$ e $p=0,55$). Um paciente do grupo MIS foi submetido à revisão do componente acetabular e dois do grupo controle foram submetidos ao mesmo procedimento, $p=0,46$. O teste clínico de Trendelenburg, que evidenciou uma fraqueza da musculatura abdução do quadril, estava presente em cinco pacientes operados pela via lateral tradicional e ausente em todos os submetidos ao MIS ($p=0,06$). Não houve diferença quanto aos parâmetros radiográficos obtidos tanto do posicionamento acetabular quanto do femoral ($p=0,32$, $p=0,58$).

Conclusões: Os resultados em médio prazo, clínicos e radiográficos, e a taxa de complicações foram semelhantes entre os pacientes submetidos à artroplastia total do quadril pelo acesso posterior minimamente invasivo e pela via lateral tradicional.

© 2014 Sociedade Brasileira de Ortopedia e Traumatologia. Publicado por Elsevier Editora Ltda. Todos os direitos reservados.

Introduction

Total hip arthroplasty performed by means of a minimally invasive access emerged because of the trend observed in other fields of surgery. It had the aims of ensuring better results, fewer complications, less perioperative morbidity and a lower cost burden for public and private healthcare service providers.^{1,2}

Several studies have shown that a minimally invasive access can lead to better recovery in the immediate postoperative period, with less pain, less bleeding during the hospital stay, less muscle injury and, consequently, shorter hospital stay.³⁻⁵

However, in comparing traditional and minimally invasive surgical accesses, other authors have shown similar short-term results, without any real benefit.^{6,7} Some authors have even warned of higher complication rates and risks with some minimally invasive accesses, such as a single anterior access, and have reported unusual complications and prolonged duration of surgery, along with long learning curves.^{8,9}

Our objective here was to assess the clinical and functional results over the medium term (minimum follow-up of six years) and the complications from uncemented total hip arthroplasty performed by means of a posterior minimally invasive access, in comparison with a traditional right lateral access.

Material and methods

After obtaining approval from our institution's research ethics committee, a prospective comparative study was conducted in which 224 adult patients underwent elective total hip arthroplasty due to a diagnosis of primary or secondary osteoarthrosis. The patients were selected from the waiting list of our hospital's Hip Group.

The samples are described in [Table 1](#).

Randomization was performed by means of a sequence of random numbers, with division into two groups at the time of making the surgical appointments. This was done by a surgeon who was not directly involved in this study, without the knowledge of the surgeon who was the first author. In the first group, the posterior access first described by Moore was used, with small-sized incisions and minimal dissection of soft tissues. In the patients of the control group, the traditional right

Table 1 – Sample parameter.

	Minimally invasive group	Control group	p value
Mean age	56.1 years	55.8 years	0.85
Sex (male/female)	55/48	69/52	0.59
Side (right/left)	52/51	62/59	1
Body mass index (BMI)	27.7	27.1	0.4

lateral access route first described by Hardinger was used, but with the patient in lateral decubitus. There were 103 patients in the minimally invasive access group and 121 in the right lateral access group.

The mean length of follow-up for the whole sample was 7.2 years, with a range from 6.1 to 9 years.

The criteria for non-inclusion comprised presentation of any type of coagulopathy, systemic arterial hypertension that was not under pharmacological control, previous hip surgery or sequelae from congenital hip dysplasia of Crowe types 2, 3 or 4 that required structural grafting in the acetabular roof.

The exclusion criterion was loss of follow-up occurring before the time of the outpatient assessment in the sixth year after the operation.

All the patients followed the same protocol for postoperative analgesia, which consisted of 100 mg of tramadol (Pfizer®) intravenously every eight hours and 100 mg of ketoprofen (Eurofarma®) in a single intravenous dose daily until the day of hospital discharge. Thromboembolic prophylaxis was administered to all the patients, consisting of 40 mg of enoxaparin applied subcutaneously (Sanofi-Aventis®), starting on the first day after the operation and continuing until the 30th day.

All the patients were discharged on the fifth day after the operation and were given guidance regarding physiotherapy and anticoagulant and analgesic medications (500 mg of paracetamol orally every six hours, if necessary).

In this study, we used two models of uncemented prosthesis (Meridian femoral nail with Vitalock-Stryker® acetabulum and Bicontact femoral nail with Aesculap® Plasmacup® acetabulum). The choice between these two implants was based merely on their availability on the day on which the patient was operated. Both of these manufacturers were suppliers to our hip surgery service at the time of this study.

All the patients in the minimally invasive access group were operated by the first author of this study and the patients in the right lateral access group were operated by three surgeons, among whom was the first author.

Some points relating to the posterior minimally invasive access need to be highlighted. This is an access route that implies a gentle learning curve, even for surgeons who are accustomed to the traditional posterior access. The principle of the moving window may be of great value with regard to acetabular and femoral access: the position of the spacers should be changed according to the region to be prepared, with soft-tissue displacement distally for preparation of the acetabulum and proximally for preparation of the femur, so as to avoid great tensioning of the surface tissues and minimize the risk of scar complications at the surgical incision.

The physiotherapy protocol used consisted of assisted active flexion of the ankles and knees using an abduction pad, starting on the first postoperative day; and gait training with partial weight-bearing starting on the second day, with full load applied six weeks after the operation. Each patient's evolution was followed up by means of return visits scheduled to take place one, three, six, 12 and 24 weeks after the operation. The return visits became annual after the first postoperative year.

A clinical-functional assessment was made and the radiographic criteria were also analyzed in both groups. For the clinical-functional assessment, the Harris Hip Score

questionnaire was used before the operation (during the week preceding the surgery), six months and one year afterwards and, finally, six years after the surgery. Six years of follow-up was considered to be the minimum length of time for this criterion in the present study.

Possible late complications and aseptic loosening of the prosthetic components among the patients of this study were evaluated after six years of follow-up.

A radiographic assessment was made at the return visit six months after the operation. The acetabular positioning was considered to be good if the abduction angle of the acetabulum was between 35° and 50°. The femoral positioning was considered to be good if the femoral components presented between 0° and 5° of valgus.

Presence or absence of the Trendelenburg clinical sign was measured at the return visit six years after the operation.

The linear radiographic wear presented by the polyethylene was measured using a compass and ruler marked in millimeters at the sixth-year follow-up. The variation in thickness of the polyethylene between the upper and lower portions was evaluated based on the sphericity of the prosthetic head. We considered that the wear was unacceptable if it was ≥ 1 mm, which would represent more than 0.1 mm of linear wear per year, given the length of follow-up of the patients in our study.¹⁰

Quantitative variables with Gaussian distribution were compared using the non-paired Student t test. Data that did not present normal distribution were evaluated by means of nonparametric tests. Comparisons between the two groups were made using the Mann-Whitney test. Qualitative (non-numerical) data were analyzed using the chi-square test, or the Fisher test when necessary. The level of statistical significance was set at $p = 0.05$.

Results

Regarding the prosthesis models used, the Meridian/Vitalock (Stryker®) implant was more prevalent in both groups than the Bicontact/Plasmacup (Aesculap®), but without any significant difference (60.2% versus 53.7%; $p = 0.34$).

A diagnosis of primary hip osteoarthritis was made in 61 patients of the right lateral group (50.4%) and 57 of the minimally invasive group (55.3%), with $p = 0.5$. All the other patients were diagnosed with osteoarthritis secondary to other pathological conditions, which included osteonecrosis, seronegative arthritis, sequelae from Pèrthes disease, sequelae from a slipped epiphysis, rheumatoid arthritis and post-traumatic hip arthritis.

The linear radiographic wear of the polyethylene was measured using a compass and ruler marked in millimeters at the sixth-year follow-up. A greater degree of wear than expected (>1 mm) was observed in 30% of the patients in the minimally invasive group, versus 33.8% of the controls, with $p = 0.56$.

In the minimally invasive group, no acetabular or femoral osteolysis was identified in any of the patients from the sixth year onwards. However, osteolysis was diagnosed in three patients of the control group, all in relation to the acetabulum ($p = 0.25$).

In relation to the acetabular and femoral positioning among the patients with a minimally invasive access, unsatisfactory results were noted in 5.8% of the acetabular components and in 4.8% of the femoral nails. In comparison, in the control group, there were unsatisfactory results in 9.9% of the acetabular components and 7.4% of the femoral components, with *p* values of 0.32 and 0.58, respectively.

The Trendelenburg clinical test, which shows weakness of the abductor musculature of the hip, was positive in five patients who were operated by means of the traditional lateral approach but was absent from all the patients who underwent surgery by means of the posterior minimally invasive access, although there was no statistically significant difference (*p* = 0.06).

The clinical-functional assessments in the two groups before the surgery were similar (mean of 47.5 in the minimally invasive group and 48 in the control group) (*p* = 0.88).

The Harris Hip Score after the operation showed that there had been an improvement in both groups, with similar mean scores (86 in the right lateral group versus 87.6 in the minimally invasive group; *p* = 0.55).

Aseptic acetabular loosening occurred in one patient, who had been operated by means of the minimally invasive posterior access. This case underwent revision 12 months after the initial surgery. Revision of the prosthesis was necessary in two of the patients in the control group: the polyethylene in one patient was exchanged after 6.5 years of follow-up and acetabular revision was performed in another patient of this group after seven years (*p* = 0.46).

The only statistically significant result was the size of the incision (*p* < 0.001), with a mean of 95.1 mm for the minimally invasive access and 169.8 mm for the traditional lateral access (Fig. 1).

Regarding complications, there were two cases in the minimally invasive group: one of medial acetabular fracturing without displacement, which was treated conservatively; and one of heterotopic ossification, which required surgical resection. In the control group, there were two cases of femoral fractures, which were treated by means of cerclage during the same surgical procedure; one case of dislocation, which was treated by means of closed reduction, without recurrence; one case of superficial infection, which was treated by means of oral antibiotic therapy; and one case of neuropraxia of the ulnar nerve caused by the positioning on the surgical table, which regressed after eight weeks. No significant difference was observed between the groups (*p* = 0.45).

Discussion

In our study, we noted that the mean age of our patients was lower than seen in studies in the literature, which mostly showed mean ages greater than 60 years.^{2,11} This can perhaps be explained by the considerable numbers of cases of osteoarthritis secondary to systemic and rheumatological diseases that were observed in our setting (almost half of our patients). Another possible cause for this finding was perhaps the typical pyramidal age distribution of the Brazilian population, which differs from that of European or North American countries. This lower mean age may represent a source of

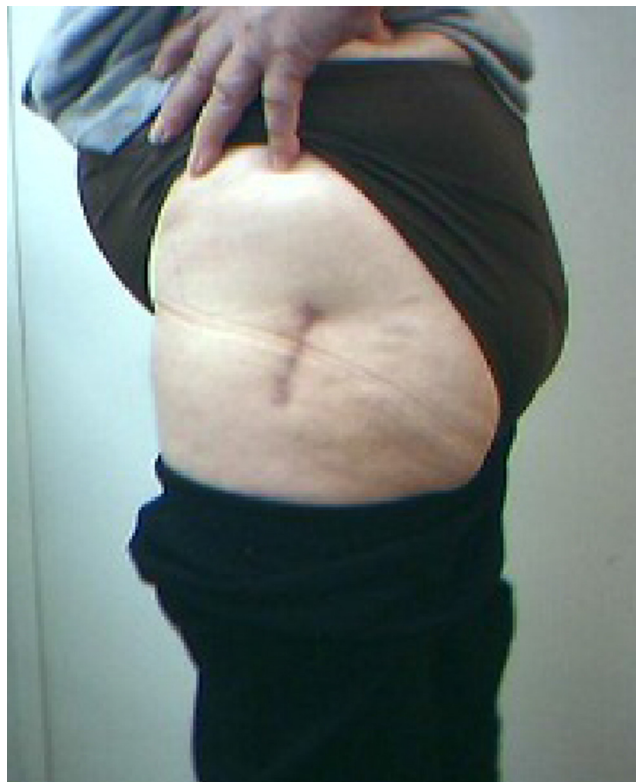

Fig. 1 – Scar of 5.5 cm six months after the operation.

bias, both toward better recovery from the acute postoperative phase and toward the complications inherent to wear and loosening of the arthroplasty, given that these patients theoretically have a higher degree of physical and work activity.

Other possible sources of bias in the results obtained in the present study include the fact that two prosthesis models were used in both groups, although both models were uncemented. However, most of the studies with large samples have tended to present this same bias. Regarding the control group, the fact that the procedures were performed by different surgeons might also be considered to be a source of bias, although diversity of surgeons has also been reported by a good proportion of previous authors.

The use of prostheses with a tribological pair consisting of a conventional polyethylene insert and a metal head, together with the patients' lower age and consequently higher level of activity, may have been responsible for the linear wear greater than expected that was found in one-third of the cases, and for the early acetabular osteolysis that was found in three patients of the control group. However, we emphasize that the methodology used for measuring the wear of the polyethylene presents a margin of error of around 15%. Methods of greater precision such as computerized three-dimensional models are used today, but these were not taken into consideration in the present study because they did not form the authors' main objective.

Regarding the positioning of the prosthesis components, although this was not the main objective of our study, we did not observe any statistically significant difference between the groups. However, in our previous experience, larger acetabula

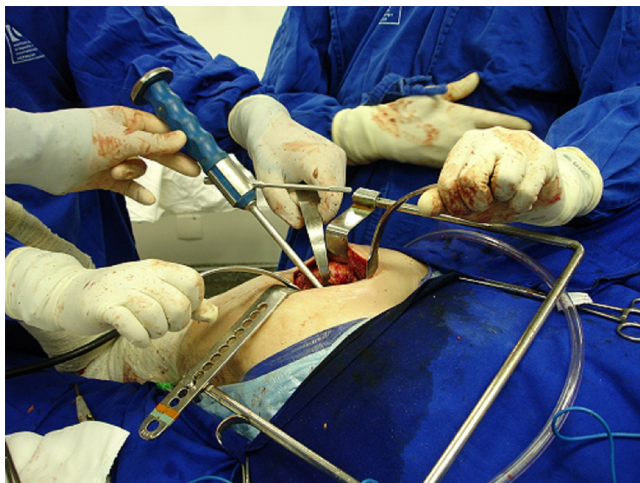


Fig. 2 – Straight acetabular impactor, which might make it difficult to position the component.

(>52) tend to present greater technical difficulty for surgeons, with a higher risk of lateralization and greater abduction angle for the acetabular component. This results from the angle of attack of the acetabular reamer, which is harmful particularly when reamers and impactors that are adapted for smaller accesses are not used (Fig. 2).¹²

Weakness of the abductor musculature, as represented by a positive Trendelenburg test, was only found in patients in the group operated by means of a lateral access. This result was not significant ($p=0.06$). Kinematic gait studies have proven that better results are obtained when the access used does not interfere directly with the integrity of this musculature.¹³

Most studies have shown that the acute postoperative recovery is better when a minimally invasive access is used, with less bleeding, lower muscle damage and shorter hospital stay. The question of bleeding during the hospital stay is another polemical point because although most authors have reported mean volumes of bleeding of 500 mL,^{2,3,14,15} the incidence of transfusions among the patients is close to 50%. This denotes a contradiction and a likely underestimate, which has been confirmed by other studies in which the central scope was blood volume loss and the methodology was more detailed for such estimates.^{5,16,17}

Our study, with a follow-up of more than six years, presented results similar to data in the literature on this topic, as demonstrated in a recent meta-analysis, which showed similar evolution in the two groups, both in relation to the radiographic parameters and in relation to the clinical-functional score of the Harris Hip Score, at all the times evaluated. However, the medium and long-term follow-up seems to be uncertain and inconclusive, given the scarcity of comparative studies with longer follow-ups, and there is no evidence so far regarding the superiority of these accesses in relation to the traditional routes.¹⁸

Overall, in the whole sample, we only observed one case of dislocation. We believe that this low incidence was due to the intensive work conducted by the physiotherapy team of our service, in which postural educational measures were implemented to diminish the risk of this complication. Moreover, in

our study, we were only dealing with patients with a diagnosis of osteoarthritis. It is well known that these patients present lower risk than do patients with a diagnosis of fracturing of the femoral neck who undergo total hip arthroplasty.

We chose to evaluate overall occurrences of complications per group, in a comparative manner, because the sample size would be insufficient for us to evaluate each comparison in detail according to each type of complication that occurred.

The only variable evaluated in this study that showed a significant difference for the minimally invasive access, i.e. the smaller-sized incision, theoretically would indicate that the esthetic result would be better. However, in 2005, Mow et al.¹⁹ demonstrated worse scarring results from small incisions. In our sample, there were no esthetic complaints, but it needs to be borne in mind that this should be last criterion for indicating a less invasive access.

Conclusion

The medium-term clinical and radiographic results and the complication rate are similar for patients undergoing total hip arthroplasty by means of a posterior minimally invasive access and by means of the traditional right lateral route. However, the right lateral access more frequently causes insufficiency of the abductor musculature, in relation to the posterior minimally invasive access.

Conflicts of interest

The authors declare no conflicts of interest.

REFERENCES

1. Wenz JF, Gurkan I, Jibodh SR. Mini-incision total hip arthroplasty: a comparative assessment of perioperative outcomes. *Orthopedics*. 2002;25(10):1031-43.
2. Goldstein WM, Branson JJ, Berland KA, Gordon AC. Minimal-incision total hip arthroplasty. *J Bone Joint Surg Am*. 2003;85 Suppl. 4:33-8.
3. Matta JM, Shahrardar C, Ferguson T. Single-incision anterior approach for total hip arthroplasty on an orthopaedic table. *Clin Orthop Relat Res*. 2005;441:115-24.
4. Berger RA. Total hip arthroplasty using the minimally invasive two-incision approach. *Clin Orthop Relat Res*. 2003;(417):232-41.
5. Vicente JR, Croci AT, Camargo OP. Blood loss in the minimally invasive posterior approach to total hip arthroplasty: a comparative study. *Clinics*. 2008;63(3):351-6 [Sao Paulo].
6. De Beer J, Petruccioli D, Zalzal P, Winemaker MJ. Single-incision, minimally invasive total hip arthroplasty: length doesn't matter. *J Arthroplasty*. 2004;19(8):945-50.
7. Ogonda L, Wilson R, Archbold P, Lawlor M, Humphreys P, O'Brien S, et al. Minimal-incision technique in total hip arthroplasty does not improve early postoperative outcomes. A prospective, randomized, controlled trial. *J Bone Joint Surg Am*. 2005;87(4):701-10.
8. Archibeck MJ, White RE Jr. Learning curve for the two-incision total hip replacement. *Clin Orthop Relat Res*. 2004;(429):232-8.

9. Bal BS, Haltom D, Aleto T, Barret M. Early complications of primary total hip replacement performed with a two-incision minimally invasive technique. *J Bone Joint Surg Am*. 2005;87(11):2432-8.
10. Griffith MJ, Seidenstein MK, Williams D, Charnley J. Socket wear in low friction arthroplasty of the hip. *Clin Orthop Relat Res*. 1978;(137):37-47.
11. Swanson TV. Early results of 1000 consecutive, posterior, single-incision minimally invasive surgery total hip arthroplasties. *J Arthroplasty*. 2005;20(Suppl 3):26-32.
12. Vicente JR, Croci AT, Camargo OP. Restauração do centro de rotação na artroplastia total do quadril minimamente invasiva. *Acta Ortop Bras*. 2009;17(2):14-7.
13. Ritter MA, Harty LD, Keating ME, Faris PM, Meding JB. A clinical comparison of the anterolateral and posterolateral approaches to the hip. *Clin Orthop Relat Res*. 2001;(385):95-9.
14. Chimento GF, Pavone V, Sharrock N, Kahn B, Cahill J, Sculco TP. Minimally invasive total hip arthroplasty. A prospective randomized study. *J Arthroplasty*. 2005;20(2):139-44.
15. Wright JM, Crockett HC, Delgado S, Lyman S, Madsen M, Sculco TP. Mini-incision for total hip arthroplasty. A prospective, controlled investigation with 5-year follow-up evaluation. *J Arthroplasty*. 2004;19(5):538-45.
16. Rosencher N, Kerckamp HEM, Macheras G, Munuera LM, Menichella G, Barton DM, et al. Orthopedic surgery transfusion hemoglobin European overview (OSTHEO) study: blood management in elective knee and hip arthroplasty in Europe. *Transfusion*. 2003;43(4):459-69 [Paris].
17. Pierson JL, Hannon TJ, Earles DR. A blood-conservation algorithm to reduce blood transfusion after total hip and knee arthroplasty. *J Bone Joint Surg Am*. 2004;86(7):1512-8.
18. Moskal JT, Capps SG. Is limited incision better than standard total hip arthroplasty? A meta-analysis. *Clin Orthop Relat Res*. 2013;471(4):1283-94.
19. Mow CS, Woolson ST, Ngarmukos S, Park EH, Lorenz PH. Comparison of scars from total hip replacements done with a standard or a mini-incision. *Clin Orthop Relat Res*. 2005;(441):80-5.