

Featured Article

Focused transcranial ultrasound for treatment of neurodegenerative dementia

Natalie Eleanor Nicodemus^{a,*}, Sergio Becerra^a, Taylor P. Kuhn^b, Hannah R. Packham^a, John Duncan^a, Kennedy Mahdavi^a, Jessica Iovine^a, Santosh Kesari^{c,d}, Scott Pereles^e, Mike Whitney^e, Michael Mamoun^{f,g}, Daniel Franc^h, Alexander Bystritskyⁱ, Sheldon Jordan^{a,j}

^aNeurological Associates – The Interventional Group, USA, Los Angeles, CA

^bDepartment of Psychiatry and Biobehavioral Sciences, University of California, Los Angeles, Los Angeles, CA

^cJohn Wayne Cancer Institute, Santa Monica, CA

^dPacific Neuroscience Institute, Santa Monica, CA

^eRAD Alliance, Los Angeles, CA

^fDepartments of Research and Psychiatry, VA Greater Los Angeles Healthcare System, Los Angeles, Los Angeles, CA

^gCNS Health, Santa Monica, CA

^hLos Angeles Brain Science Project, Santa Monica, CA

ⁱSemel Institute for Neuroscience and Human Behavior, University of California, Los Angeles, Los Angeles, CA

^jDepartment of Neurology, University of California, Los Angeles, Los Angeles, CA

Abstract

Introduction: Preclinical studies support investigation of focused ultrasound for breakdown of cerebral pathologies in neurodegenerative conditions including Alzheimer's disease (AD) and Parkinson's disease (PD).

Methods: A focused transcranial Doppler device with probes (2 MHz, 520 mW/cm²) affixed bilaterally was used to target the hippocampus (AD) or substantia nigra (PD) with functional magnetic resonance imaging navigation for enhanced plaque removal. A total of 22 patients (n = 11 AD, n = 11 PD) underwent 8 consecutive, weekly, 1-hour treatments wherein sleep was encouraged naturally or pharmacologically. Cognitive and motor functioning assessment was carried out using standardized evaluations at baseline and conclusion.

Results: Of all, 62.5% of patients had one or more improved cognitive scores without data incongruence, 87% had stable or improved fine motor scores, and 87.5% had stable or improved gross motor scores. No adverse events were reported.

Discussion: The safety of focused transcranial Doppler and possible enhancement in patient functioning were suggested by outcome data.

© 2019 The Authors. Published by Elsevier Inc. on behalf of the Alzheimer's Association. This is an open access article under the CC BY-NC-ND license (<http://creativecommons.org/licenses/by-nc-nd/4.0/>).

Keywords:

Alzheimer's; ASL; Cognition; Dementia; Parkinson's; Sleep; Ultrasound

1. Introduction

Although the primary originating features of Alzheimer's disease (AD) and Parkinson's disease (PD) are yet to be well defined, these neurodegenerative conditions are characterized

by extracellular deposits of macromolecular material (e.g., plaque) which are apparently toxic and may further accelerate deposit accretion by obstructing the flushing effects of interstitial flow [1–4]. In healthy conditions, a significant amount of extracellular waste from brain activity appears to be removed by convection through extracellular spaces, along perivascular spaces, into the cerebrospinal fluid space, and then outwards along lymphatic channels [1]. The observation of plaque accumulation in AD stands as one of the primary interventional research platforms in the

Primary Research Facility: Neurological Associates – The Interventional Group 2811 Wilshire Blvd., Suite 790, Santa Monica, CA, USA, 90403.

*Corresponding author. Tel.: +760-473-5940; Fax: +310-453-3685.

E-mail address: natalie@naowla.com

<https://doi.org/10.1016/j.trci.2019.06.007>

2352-8737/© 2019 The Authors. Published by Elsevier Inc. on behalf of the Alzheimer's Association. This is an open access article under the CC BY-NC-ND license (<http://creativecommons.org/licenses/by-nc-nd/4.0/>).

neurodegenerative domain, and the pathologies of a number of other neurodegenerative dementias have also been associated with an accumulation of toxic plaques. Abnormalities in alpha-synuclein, for example, appear to be implicated in PD in a manner similar to that of Amyloid- β in AD [2,3]. Numerous AD treatment trials of agents designed for either blocking the production of Amyloid- β plaque with enzymatic inhibitors or accelerating its destruction with antibodies have been a focus of research to date. Despite the robust evidence of problematic plaque accumulation, current efforts have demonstrated moderate slowing of cognitive decline at best and have been largely unfruitful in reversing cognitive impairment [5,6]. This generalized failure may be partly attributed to the potential inability of systemic treatments to break up problematic deposits with sufficient safety and precision. Nevertheless, systemic approaches remain paramount given the intricate neuroanatomical landscape of these disorders, which seems to thoroughly complicate a targeted approach. The development of a targeted approach, if possible, however, could radically change the trajectory of dementia research.

The role of slow-wave sleep for disposal of toxic neurological byproducts may be particularly relevant to this pursuit, especially given evidence for impaired slow-wave sleep in AD [7–10]. Neurophysiology suggests that slow-wave sleep impairment is potentially related to the locus coeruleus and lateral hypothalamus. A cascade of events related to these regions, which appear to degenerate in AD and PD pathologies, have been linked to astrocyte morphing for the convective removal of byproducts through interstitial spaces [11–17]. Given this conceptual framework, it may be beneficial to foster slow-wave sleep—or related physiological processes—to sufficiently reopen pathways for interstitial fluid convection to enhance disposal of activity-induced accretion. The present study sought to incorporate deep sleep facilitation by minimizing interference and using pharmacologic intervention only when necessary for healthier sleep architecture. A sedated state characterized by slow waves and inhibition of norepinephrine may be created with some short acting agents such as dexmedetomidine [18]. Conceptually, dexmedetomidine may be preferred to other agents because it is a short acting norepinephrine blocker, which could mimic slow-wave sleep architecture, opening interstitial spaces and facilitating plaque removal. Dexmedetomidine may also be preferred given its safety profile among the elderly and acutely ill compared with other anesthetic agents [19–22].

Thus far, techniques including immune therapy aimed at plaque for solubilizing, mobilizing, and facilitating convective forces have been minimally effective. The minimal benefit observed [5,6], however, may still inform a refined approach for enhancing glymphatic processes. Recently, focused ultrasound modalities have been developed with implications for a variety of neurological conditions. This modality has been used for many applications in health care, such as fragmentation and mobilization of kidney stones. The technology has demonstrated capacity to alter

targeted tissues through heating, mechanical distortion, and chemical changes induced by acoustic energy absorption processes—all of which have potential implications for the dissolution of problematic plaque accretion. Noninvasive cerebral applications include clot lysis in patients with middle cerebral artery thromboembolism, and higher intensity heating has been used for targeted ablation in treating tremor and metastatic disease [23,24]. Safety and efficacy have been demonstrated in these prior clinical applications. Future applications are already in development for low-intensity ultrasound targeted drug delivery, given its demonstrated ability to penetrate the skull to reach and exert an effect on deep neural tissue with high spatial (millimeter) resolution [25,26] resulting in successful changes in regional neuronal activity in both animals [27] and humans [28–33]. Indeed, early histology and animal studies of low intensity focused ultrasound pulsation demonstrated its ability to produce reversible physiologic effects on neuron clusters, including increased activity in targeted areas [34]. Notably, a preclinical study of low-intensity focused ultrasound has successfully treated amyloid plaque in a mouse model of AD, showing both that ultrasound can effectively target subcortical regions of interest (e.g., hippocampus) and that can successfully aid in the clearance of amyloid [35–37]. Other studies suggest that hippocampal neurogenesis may also be induced by transcranial ultrasound, indicating that this modality could have regenerative value for neurodegenerative conditions [38].

Considering the foregoing, the present study was developed to increase plaque removal in neurodegenerative cerebral pathology using a modality similar to sonolysis, which has already demonstrated safety and potential efficacy in human subjects. The project was outlined as an open-label, clinical study of patients with mild cognitive impairment (MCI) or dementia to evaluate feasibility, tolerability, and efficacy of focused transcranial ultrasound. Aspects of brain physiology and brain fluid dynamic pathophysiology were leveraged for optimal application. Particularly, facilitation of slow-wave sleep by means of sleep deprivation was incorporated through minimized stimulant medication, and in some cases, sublingual administration of dexmedetomidine. The transcranial ultrasound equipment that has been used for human clot lysis was adopted to target the hippocampus in patients with AD. Patients with PD were also included in this study with the substantia nigra as a target for treatment. Building upon a robust framework, we sought to investigate the ability of focused ultrasound and slow-wave sleep modulation to improve cognitive performance in patients, presumably through increased removal of extracellular debris.

2. Methods

2.1. Subjects

This study was approved by an institutional review board, and all patients provided written informed consent. A total of 22 patients (Alzheimer's, $n = 11$; men: $n = 8$, women:

n = 3) (Parkinson's, n = 11; men: n = 8, women = 3) aged 40 to 95 were enrolled in this open-label, clinical study. Patients who demonstrated cognitive decline were identified within the study clinic and were given the opportunity to pursue inclusion. Further recruitment was not necessary, and patients were not compensated for participation. A Clinical Dementia Rating (CDR) between 0.5 (MCI) and 2 (moderate dementia) was required, which was determined by administration of the Quick Dementia Rating System (QDRS). The QDRS and remaining protocol evaluations were administered before entry. Patients were required to have an advanced magnetic resonance imaging (MRI) of the brain including volume measurement of the hippocampus, arterial spin labeling (ASL) perfusion scans, and magnetic resonance spectroscopy of prefrontal cortex, precuneus, and hippocampus. These imaging modalities have been demonstrated as meaningful clinical indicators for discriminating among neurodegenerative subgroups and show sensitivity to change as patients progress from MCI to dementia. Participants were required to demonstrate at least one imaging biomarker of AD or PD for inclusion in the study. Other pathological findings that could be related to the patient's condition (e.g., neoplasm, cortical dysplasia, stroke) were exclusionary. Lumbar puncture for β amyloid-42 and tau proteins, which has demonstrated sensitivity and specificity for identifying MCI and AD [39], was also required for screening. Patients who were unable or unwilling to undergo any of these screening procedures were excluded. Inability to give informed consent was also a basis for exclusion, and progressed cognitive decline to a degree that would inhibit maintained informed consent could result in removal from the study unless a legal representative gave written consent. Patients with cognitive decline due to acute illness or vascular dementia were excluded. Advanced terminal illness, advanced kidney, pulmonary, cardiac, or liver failure, and major depressive disorder were all exclusionary criteria. The Beck Depression Inventory-II, which has been demonstrated as a statistically valid and reliable measure of major depressive disorder, was administered as a depression screening method [40]. Exclusionary criteria also included the presence of a scalp rash, open wounds on the scalp, definite or probable pregnancy, breastfeeding, and an inability to lay down without excessive movement to achieve deep sleep. Concurrent interventions and therapies were not a basis for exclusion unless the study doctor deemed them likely to threaten patient safety when used in conjunction with the study protocol.

2.2. Neurocognitive and behavioral performance

All participants underwent a battery of baseline and conclusion cognitive assessments. The QDRS, an expedited evaluation similar to the CDR assessment, was selected as the primary staging tool for this study [41]. This evaluative tool consists of 10 (5 cognitive, 5 functional) categories with 5 corresponding descriptions depicting clinical progression

per category. These depictions range in severity according to the following scale: 0 (normal), 0.5, 1, 2, and 3 (severe). Trained administrators conducted an interview with next of kin to patients to assign ratings in each of these 10 domains, which resulted in cognitive and behavioral subtotals. Total QDRS scores were translated to CDR scores according to the conversion table outlined in Galvin's QDRS research [41].

The Repeatable Battery for Assessment of Neuropsychological Status (RBANS) (versions A, B, C, and D) and the Montreal Cognitive Assessment (MoCA) (versions 1, 2, and 3) also served as discrete cognitive performance measures. The RBANS, a statistically reliable and sensitive standardized adult (20-89) repeatable measure for detection of MCI and dementia [42], was used to assess cognitive functioning in terms of immediate memory, visuospatial/constructional, language, attention, and delayed memory performance. Domain-specific index scores were evaluated individually alongside total index scores. The MoCA, a 30-question and approximately 10-minute test shown to be highly sensitive and reliable for assessment of MCI and dementia, was included to evaluate data convergence [43]. This test probes multiple domains including visuospatial/executive, naming, memory, attention, language, abstraction, delayed recall, and orientation abilities. Possible scores range from 0 to 30 with a score of 26 or greater considered to be normal [43]. Motor functioning, which is particularly relevant in PD, was also evaluated using the Timed 25-Foot Walk Test (T25-FW) for gross motor functioning and the Rolyan® Nine-Hole Pegboard Test (9-HPT) for assessment of fine motor dexterity. Both movement assessments have shown statistical validity and reliability [44,45].

2.3. Advanced MRI

Advanced MRI was performed at screening and upon completion of the study. These scans were performed at one of three imaging centers in the Los Angeles/Santa Monica area: Resolution Advanced Imaging Center, Westwood Open-MRI, and Tower Saint John's Imaging. Patients were required to undergo follow-up imaging at the same center as baseline. All acquisition parameters were approved by the Food and Drug Administration. Routine neuroradiological interpretations were rendered by collaborating neurologists and neuroradiologists as part of a dementia consensus conference. The findings of these neuroimaging studies were used to help determine patient disease classification.

Two patients consented to have additional ASL MRI sequences for observation of regional cerebrovascular perfusion for investigation of direct physiological effects. These sequences were performed immediately before and after their final sessions of treatment. Postprocessing was performed using FMRIB Software Library [46] with identical parameters. ASL data were superimposed over the acquired T1-weighted brain image demonstrating a map of cerebral perfusion. Voxel-based comparisons showing perfusion values relative to the acquired data range were used for quantification.

2.4. Procedure

Screened participants underwent eight consecutive, weekly, 1-hour focused ultrasound sessions using the DWL Doppler Box X [47]. Ultrasound was delivered using a 2 MHz transducer at a power of 520 mW/cm, which is under the Food and Drug Administration-allowed threshold of 750 mW/cm. Parameters were adapted for this novel context because of the safety demonstrated in prior studies of sonothrombolysis for treatment of stroke [48]. While patient-specific accumulated plaque cannot be directly targeted, regions implicated in the pathology of various neurodegenerative syndromes were targeted. The mesial temporal lobe was targeted in AD and the substantia nigra was targeted in PD cases.

Targeting was done with a combined approach of MRI and Doppler guidance. First, the posterior cerebral artery was identified on the patient's T1 MRI sequence in 3 dimensions. Potential deformation of acoustic waves by the skull was minimized by using the "temporal window," a thin region of the skull that usually allows for successful insonation. Using the OsiriX imaging viewing software, measurements to surface fiducials were made for location identification when projected tangentially to the skull's surface at the thinnest region of the temporal window [49]. These measurements were used to mark the patient's scalp at the target site bilaterally. Monitoring probes attached to a DWL Elastic Headband were then placed on the drawn targets. To further refine transducer placement, Doppler waveforms were used to identify the posterior cerebral artery, which runs from medial to the mesial temporal lobe. The monitoring probe was manipulated until the posterior cerebral artery was detected with blood flow moving away from the probe to target the hippocampal region and with flow moving toward the probe to target the substantia nigra region. After the transducers were affixed bilaterally, power was increased to the investigational therapeutic level, 520 mW/cm.

The procedure took place in a quiet room monitored by medical staff. Patients were instructed to try to sleep for the duration of the hour-long procedure. Standard clinical techniques were used to promote sleep in the office, including mild sleep deprivation and discontinuation of stimulating medications. If patients otherwise indicated an inability to fall asleep, dexmedetomidine was given at a dose congruent with patient height, weight, and medical history. This medication was administered sublingually using a Teleflex Intranasal Mucosal Atomization Device, which allowed the medication to be administered in the form of a spray [50]. Patients were instructed to keep the medication in their mouth for about 2 minutes, or until fully absorbed. Pulse oximetry and blood pressure were monitored throughout the duration of treatment when dexmedetomidine was given, which was only given when necessary for sleep. The ultrasound procedure and any methods utilized to achieve deep sleep were replicated each week. Patients were discharged at the end of treatment when fully awake

and, if given medication or if otherwise necessary, in the care of a responsible adult.

3. Results

3.1. Tolerability and feasibility

All patients were able to tolerate treatment without notable side effects. Posterior cerebral arteries were successfully insonated in all patients, demonstrating the feasibility of targeting methods. Sleep was achieved by all patients during treatment. Dexmedetomidine, which was administered regularly in 14 patients, had no accompanying adverse events. This medication, then, appeared to be a safe sleep agent for use in an older adult population.

3.2. Cognitive faculties

Twenty-one of 22 patients (95.5%) had stable CDR scores after treatment. Six of 22 patients (27.3%) demonstrated clinically meaningful improvement in RBANS total index scores while 15 of 22 (68.2%) had clinically stable scores. Three patients (13.6%) demonstrated a clinically meaningful decline on the RBANS. Clinically significant improvement on the MoCA was seen in 7 patients (31.8%) while 8 patient scores (36.4%) showed no clinically significant change. Seven patients (31.8%) demonstrated a clinically significant decline in MoCA performance.

Assessment of data convergence revealed 1 patient (4.5%) with clinically significant improvement on all 3 cognitive measures secondary to ultrasound treatment. Data incongruence, which was defined as clinically significant improvement in one or more measure with an opposing decline in another, was seen in 3 patients (13.6%). Two of 22 patients (9.1%) improved on at least 2 cognitive measures without any incongruence; Two patients (9.1%) had clinically significant decline on at least 2 of the 3 cognitive measures without incongruence. Fourteen patients (63.6%) had a combination of at least one improved score without incongruence at conclusion. Seven patients (31.8%) had a combination of at least one declined score without incongruence at conclusion.

3.3. Motor functioning

Assessment of fine motor dexterity using the 9-HPT revealed 1 (4.5%) clinically significant improvement of the dominant hand after ultrasound, 3 (14.3%) clinically significant declines after ultrasound, and 19 (90.5%) stable measures (1 patient did not complete the follow-up 9-HPT, and results were therefore thrown out). Gross motor functioning on the T25-FW revealed 2 (9.1%) clinically significant improvements, 3 (13.6%) clinically significant declines, and 17 (77.3%) stable outcomes. Convergence of data showed no incongruence among individual patient motor functioning scores. No patients had clinically significant improvement or decline on both measures after ultrasound.

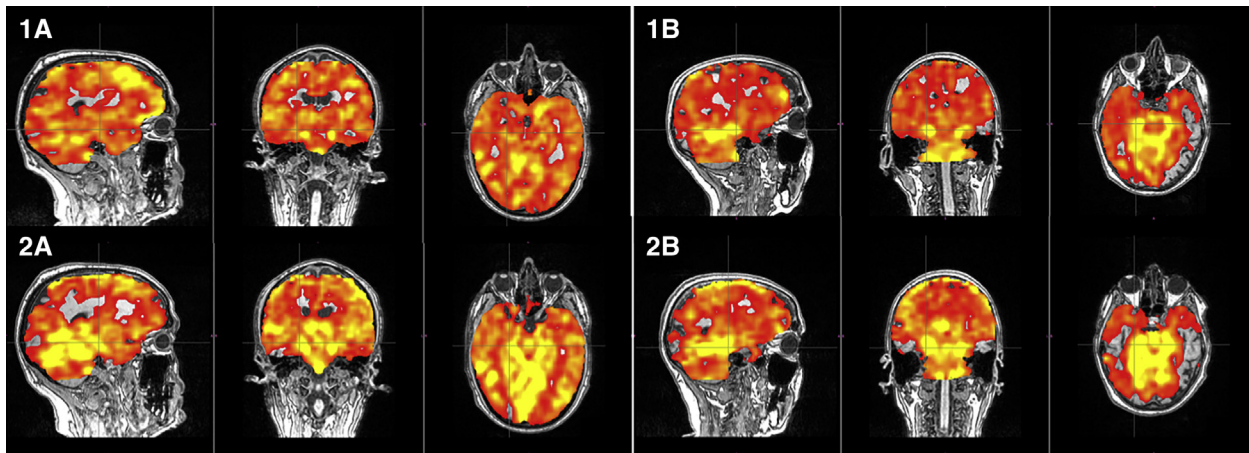


Fig. 1. Pre- and post-ultrasound arterial spin labeling (ASL) sequences demonstrating a color map of relative blood flow perfusion with red (lower) to yellow (higher) perfusion values, which was registered and superimposed over a T1-weighted MRI of the brain. Four three-panel images demonstrate the results of 2 patients (A and B) (1) immediately before and (2) immediately after one-hour of ultrasound treatment.

3.4. Imaging assessment

ASL imaging sequences performed immediately before and after one 1-hour session of ultrasound for a subsample of two patients showed markedly increased perfusion at the targeted hippocampal region after ultrasound (Fig. 1). Quantification of relative cerebral perfusion in various regions demonstrated a greater than 150% increase in relative blood perfusion at the bilateral hippocampi in patient 1. A greater than 50% increase in relative perfusion was seen at the right hippocampus of patient 2, but the left hippocampus had only a 7% increase in relative perfusion.

4. Discussion

Feasibility was demonstrated through successful target insonation and the ability of all study patients to treatment without adverse events. Outcome data was generally stable across cognitive and motor domains among patients, which further supports safety in the given population. Co-occurring interventions make it difficult to identify direct relationships between outcome and the various aspects of the study protocol or incidental variables. Less than 30% of patients, however, demonstrated clinically significant decline in cognitive or motor domains, which supports overall safety. Of all, 62.5% of patients demonstrated clinically significant improvement on at least one cognitive measure, suggesting some positive interventional effect. Incongruent changes to cognitive status observed (decline on one measure, improvement on another) in 3 patients could indicate differences in regionally specific sensitivities among the outcome measures. Co-occurring interventions, specifically tyrosine kinase inhibitor (TKI) intake, modified the investigational premise over the course of this study. To detect data trends that might differentiate ultrasound and TKI effects, additional data were observed for comparison of change before and after inclusion of this focused ultrasound study in individual patient care (see [Supplementary Results](#)). The addi-

tional data from 14 patients demonstrated a trend toward overall positive outcome after the inclusion of ultrasound with ongoing TKI treatment. Because of the nature of these degenerative conditions, any positive change may be considered noteworthy because decline is more common in these conditions than improvement without an intervention of therapeutic value. Counterintuitively, comparison of results before and after ultrasound demonstrated equally prevalent improvement and decline in patient cognitive status.

Given the limited timeframe and lack of later follow-up, detection of longer-term benefit is currently unavailable. It is unlikely that the breakdown and removal of plaque alone (through either the ultrasound, TKI, or a combined approach) would be sufficient to overcome deficits given the neuronal loss engendered by their presence. Toward this end, future studies may benefit from inclusion of blood and/or cerebrospinal fluid-based monitoring of histological markers (e.g., amyloid peptides, alpha-synuclein, activated macrophages) to help further elucidate the cellular mechanism of action underlying the results reported herein. More regenerative methods, possibly in the form of stem cells or exosomes, may provide further benefit to cognitive status. The observation of cognitive performance improvement occurring more frequently than motor performance improvement could fall in line with this concept. The substantia nigra may receive less therapeutic benefit from the treatments investigated herein for one or a combination of several reasons. These include that the substantia nigra is typically at least 70% degenerated before the onset of motor symptoms [51] and therefore the removal of plaque occurs too late in the degenerative process or that chemical alterations secondary to the degeneration, which would not likely have been modified by breakdown of plaque with the TKI or ultrasound directly, are responsible for ongoing progression of motor decline.

Ultrasound for targeted delivery of regenerative therapies or neurochemical interventions may be the next step for improved patient outcome. Efficacy of the combined MRI

and Doppler navigational methods was demonstrated in 2 case studies using ASL imaging before and after 1 hour of ultrasound. These imaging sequences revealed relatively selective hyperperfusion of the targeted ultrasound region such that the efficacy of ultrasound for targeted drug delivery seems particularly plausible. It is also possible that the mechanism of action in this study was that of targeted drug delivery given the concurrent use of the TKI medication. Because of the nonlimiting inclusion criteria, this study design does not allow for delineation of therapeutic mechanism. Observation of ASL response to focused ultrasound could be beneficial for better understanding of blood flow modulation and enhanced perfusion in a larger dataset. With further study, the changes to relative cerebral perfusion observed in this study could further support a mechanism for therapeutic benefit with a broad range of applications. Hemodynamic changes on ASL imaging could, however, also support the original goal of breaking down pathologically relevant protein accumulations for facilitated removal. For future development, refined targeting and greater selectivity could be available with systems that combine multiple ultrasound sources in a spherical array or hybrid system at the temporal window, acoustic wave correction for skull distortion, and thermal imaging with MRI, so called high-intensity focused ultrasound [48].

Similarly, inclusion of blood and/or cerebrospinal fluid-based histopathological markers of amyloid, synuclein, and macrophage activity could provide additional insight into the mechanism of therapeutic action. Although outside the scope of this study, animal modeling could also provide meaningful insight into the mechanism of action of ultrasound on amyloid disposal as well as provide additional information about the specific ultrasound parameters (e.g., pulse repetition frequency) which yield the greatest therapeutic benefit. Because mechanical and heating effects may be helpful for direct dissolution and mobilization of amyloid plaque, the established ability of transcranial ultrasound to stimulate neuronal discharge may facilitate convective forces by the release of glutamate and the subsequent activation of astrocyte filopodia similar to the activation seen in slow-wave sleep [30,52]. Enhancement, then, may be made through one Hertz pulse rates to cohere with natural burst rates of neurons in slow-wave sleep. Alternatively or perhaps additionally, it is possible that ultrasound is inducing, recruiting, or enhancing gamma oscillations within the hippocampus that have recently been shown to increase amyloid removal via enhanced microglial colocalization with amyloid [52]. While gamma oscillations are certainly a possible mechanism, this process is unlikely to be the only driving factor behind our findings, as gamma oscillations have not been reliably demonstrated to occur in other targeted regions, such as the substantia nigra. Finally, it will be important for such studies to use a technique to quantitatively assess plaque density before and after treatment to further elucidate the mechanism of therapeutic action.

Overall, the present study provides data to support ongoing investigation in targeted ultrasound therapeutics, suggesting a slowing of neurodegeneration and indicating potential for regenerative developments through directed delivery of therapeutic substances. Advanced imaging gives more insight into mechanism of action, specifically regarding targeted modification of blood perfusion using hour-long ultrasound delivery. Further research should include larger sample sizes and extended follow-up to better understand the efficacy of this intervention, but this study demonstrates an early framework of advanced technological clinical research in a dominantly pharmacologic interventional setting.

Acknowledgments

This research did not receive any specific grant from funding agencies in the public, commercial, or not-for-profit sectors. All contributing authors have reviewed this submission and indicate no conflicts of interest.

Supplementary Data

Supplementary data related to this article can be found at <https://doi.org/10.1016/j.trci.2019.06.007>.

RESEARCH IN CONTEXT

1. Systematic review: The authors reviewed literature using traditional (e.g., PubMed) sources and meeting abstracts and presentations. Sleep and insufficient disposal of problematic accumulations appear to be relevant for neurodegenerative pathology in Parkinson's and Alzheimer's diseases. Focused ultrasound may have the ability to facilitate disposal of toxic aggregations, and sleep management may also be important in this process.
2. Interpretation: Our findings led to the hypothesis that focused ultrasound delivered in a targeted manner with imaging and Doppler guidance may be able to inhibit decline and promote improved cognition.
3. Future directions: This study demonstrates an early framework of advanced technological clinical research in a dominantly pharmacologic interventional setting. Further research should include larger sample sizes and extended follow-up to better understand the efficacy of this intervention and the new possibilities enabled by its mechanism, namely inclusion of potentially regenerative substances, such as stem cells or exosomes.

References

- [1] Jagust W. Is amyloid- β harmful to the brain? Insights from human imaging studies. *Brain* 2016;139:23–30.
- [2] Iliff JJ, Goldman SA, Nedergaard M. Implications of the discovery of brain lymphatic pathways. *Lancet Neurol* 2015;14:977–9.
- [3] Leshchyn'ska I, Liew HT, Shepherd C, Halliday GM, Stevens CH, Ke YD, et al. A β -dependent reduction of NCAM2-mediated synaptic adhesion contributes to synapse loss in Alzheimer's disease. *Nat Commun* 2015;6:8836.
- [4] Thal DR, Walter J, Saito TC, Fändrich M. Neuropathology and biochemistry of A β and its aggregates in Alzheimer's disease. *Acta Neuropathol* 2015;129:167–82.
- [5] Plog BA, Nedergaard M. The glymphatic system in central nervous system health and disease: past, present, and future. *Annu Rev Pathol Mech Dis* 2018;13:379–94.
- [6] Stefanis L. Synuclein in Parkinson's disease. *Cold Spring Harb Perspect Med* 2012;2:a009399.
- [7] Rocha EM, De Miranda B, Sanders LH. Alpha-synuclein: pathology, mitochondrial dysfunction and neuroinflammation in Parkinson's disease. *Neurobiol Dis* 2018;109:249–57.
- [8] Lavialle M, Aumann G, Anlauf E, Pröls F, Arpin M, Derouiche A. Structural plasticity of perisynaptic astrocyte processes involves ezrin and metabotropic glutamate receptors. *Proc Natl Acad Sci U S A* 2011;108:12915–9.
- [9] Fucke T, Suchanek D, Nawrot MP, Seamari Y, Heck DH, Aertsen A, et al. Stereotypical spatiotemporal activity patterns during slow-wave activity in the neocortex. *J Neurophysiol* 2011;106:3035–44.
- [10] Nir Y, Staba RJ, Andrillon T, Vyazovskiy VV, Cirelli C, Fried I, et al. Regional slow waves and spindles in human sleep. *Neuron* 2011;70:153–69.
- [11] de Andrés I, Garzón M, Reinoso-Suárez F. Functional anatomy of non-REM sleep. *Front Neurol* 2011;2:70.
- [12] Xie L, Kang H, Xu Q, Chen MJ, Liao Y, Thiyagarajan M, et al. Sleep drives metabolite clearance from the adult brain. *Science* 2013;342:373–7.
- [13] Kress BT, Iliff JJ, Xia M, Wang M, Wei HS, Zeppenfeld D, et al. Impairment of paravascular clearance pathways in the aging brain. *Ann Neurol* 2014;76:845–61.
- [14] Mander BA, Marks SM, Vogel JW, Rao V, Lu B, Saletin JM, et al. β -amyloid disrupts human NREM slow waves and related hippocampus-dependent memory consolidation. *Nat Neurosci* 2015;18:1051–7.
- [15] Lim ASP, Ellison BA, Wang JL, Yu L, Schneider JA, Buchman AS, et al. Sleep is related to neuron numbers in the ventrolateral pre-optic/intermediate nucleus in older adults with and without Alzheimer's disease. *Brain* 2014;137:2847–61.
- [16] Fitzgerald PJ. Is elevated norepinephrine an etiological factor in some cases of Alzheimer's disease? *Curr Alzheimer Res* 2010;7:506–16.
- [17] O'Donnell J, Ding F, Nedergaard M. Distinct functional states of astrocytes during sleep and wakefulness: is norepinephrine the master regulator? *Curr Sleep Med Rep* 2015;1:1–8.
- [18] Shteamer JW, Dedhia RC. Sedative choice in drug-induced sleep endoscopy: a neuropharmacology-based review. *Laryngoscope* 2017;127:273–9.
- [19] Chen K, Lu Z, Xin YC, Cai Y, Chen Y, Pan SM. Alpha-2 agonists for long-term sedation during mechanical ventilation in critically ill patients. *Cochrane Database Syst Rev* 2015;1:CD010269.
- [20] Su X, Meng Z-T, Wu X-H, Cui F, Li H-L, Wang D-X, et al. Dexmedetomidine for prevention of delirium in elderly patients after non-cardiac surgery: a randomised, double-blind, placebo-controlled trial. *Lancet* 2016;388:1893–902.
- [21] Seitz DP, Reimer CL, Siddiqui N. A review of epidemiological evidence for general anesthesia as a risk factor for Alzheimer's disease. *Prog Neuro-psychopharmacology Biol Psychiatry* 2013;47:122–7.
- [22] Whittington RA, Bretteville A, Dickler MF, Planel E. Anesthesia and tau pathology. *Prog Neuro-Psychopharmacology Biol Psychiatry* 2013;47:147–55.
- [23] Schlesinger D, Benedict S, Diederich C, Gedroyc W, Klibanov A, Larner J. MR-guided focused ultrasound surgery, present and future. *Med Phys* 2013;40:080901.
- [24] Ricci S, Dini L, Del Sette M, Anzola P, Mazzoli T, Cenciarelli S, et al. Sonothrombolysis for acute ischaemic stroke. Ricci S, editor. *Cochrane Database Syst Rev*. Chichester, UK: John Wiley & Sons, Ltd; 2012:CD008348.
- [25] Naor O, Krupa S, Shoham S. Ultrasonic neuromodulation. *J Neural Eng* 2016;13:031003.
- [26] Tufail Y, Yoshihiro A, Pati S, Li MM, Tyler WJ. Ultrasonic neuromodulation by brain stimulation with transcranial ultrasound. *Nat Protoc* 2011;6:1453.
- [27] Yoo SS, Lee JH, Zhang Y, Lee W, Fischer K, Golby A, et al. FUS-Mediated Reversible Modulation of Region-Specific Brain Function. Washington DC: Proceedings of MRgFUS; 2008. p.10.
- [28] Legon W, Sato TF, Opitz A, Mueller J, Barbour A, Williams A, et al. Transcranial focused ultrasound modulates the activity of primary somatosensory cortex in humans. *Nat Neurosci* 2014;17:322.
- [29] Lee W, Kim H, Lee S, Yoo SS, Chung YA. Creation of various skin sensations using pulsed focused ultrasound: evidence for functional neuromodulation. *Int J Imaging Syst Technology* 2014;24:167–74.
- [30] Lee W, Kim H, Jung Y, Song IU, Chung YA, Yoo SS. Image-guided transcranial focused ultrasound stimulates human primary somatosensory cortex. *Scientific Rep* 2015;5:8743.
- [31] Ai L, Mueller JK, Grant A, Eryaman Y, Legon W. Transcranial focused ultrasound for BOLD fMRI signal modulation in humans. In: Engineering in Medicine and Biology Society (EMBC), 2016 IEEE 38th Annual International Conference. IEEE; 2016. p.1758–61.
- [32] Lee W, Kim HC, Jung Y, Chung YA, Song IU, Lee JH, et al. Transcranial focused ultrasound stimulation of human primary visual cortex. *Scientific Rep* 2016;6:34026.
- [33] Lee W, Chung YA, Jung Y, Song IU, Yoo SS. Simultaneous acoustic stimulation of human primary and secondary somatosensory cortices using transcranial focused ultrasound. *BMC Neurosci* 2016;17:68.
- [34] Mazoue H, Chauchard P, Busnel RG. Nervous excitation with high frequency ultrasonics. *J de physiologie* 1953;45:179.
- [35] Leinenga G, Götz J. Scanning ultrasound removes amyloid- β and restores memory in an Alzheimer's disease mouse model. *Sci Transl Med* 2015;7:278ra33.
- [36] Jordão JF, Thévenot E, Markham-Coultes K, Scarcelli T, Weng Y-Q, Xhima K, et al. Amyloid- β plaque reduction, endogenous antibody delivery and glial activation by brain-targeted, transcranial focused ultrasound. *Exp Neurol* 2013;248:16–29.
- [37] Burgess A, Dubey S, Yeung S, Hough O, Eterman N, Aubert I, et al. Alzheimer disease in a mouse model: MR imaging-guided focused ultrasound targeted to the Hippocampus opens the blood-brain barrier and improves pathologic abnormalities and behavior. *Radiology* 2014;273:736–45.
- [38] Scarcelli T, Jordão JF, O'Reilly MA, Ellens N, Hynynen K, Aubert I. Stimulation of hippocampal neurogenesis by transcranial focused ultrasound and microbubbles in adult mice. *Brain Stimul* 2014;7:304–7.
- [39] Forlenza OV, Radanovic M, Talib LL, Aprahamian I, Diniz BS, Zetterberg H, et al. Cerebrospinal fluid biomarkers in Alzheimer's disease: diagnostic accuracy and prediction of dementia. *Alzheimer's Dement Diagnosis, Assess Dis Monit* 2015;1:455–63.
- [40] Beck AT, Steer RA, Carbin MG. Psychometric properties of the Beck depression inventory: twenty-five years of evaluation. *Clin Psychol Rev* 1988;8:77–100.
- [41] Galvin JE. The Quick Dementia Rating System (QDRS): a rapid dementia staging tool. *Alzheimer's Dement (Amst)* 2015;1:249–59.
- [42] Randolph C. Repeatable Battery for the Assessment of Neuropsychological Status Update. Bloomington, MN: NCS Pearson, PsychCorp; 2012.

- [43] Nasreddine ZS, Phillips NA, Bäckström V, Charbonneau S, Whitehead V, Collin I, et al. The Montreal Cognitive Assessment, MoCA: a brief screening tool for mild cognitive impairment. *J Am Geriatr Soc* 2005;53:695–9.
- [44] Wang Y-C, Magasi SR, Bohannon RW, Reuben DB, McCreath HE, Bubela DJ, et al. Assessing dexterity function: a comparison of two alternatives for the NIH Toolbox. *J Hand Ther* 2011;24:313–20. quiz 321.
- [45] Motl RW, Cohen JA, Benedict R, Phillips G, LaRocca N, Hudson LD, et al. Validity of the timed 25-foot walk as an ambulatory performance outcome measure for multiple sclerosis. *Mult Scler* 2017;23:704–10.
- [46] Jenkinson M, Beckmann CF, Behrens TEJ, Woolrich MW, Smith SM. FSL. *Neuroimage* 2012;62:782–90.
- [47] Compumedics Germany GmbH - DWL Doppler-Box X; 2018.
- [48] Mikulik R, Alexandrov AV. Acute stroke: therapeutic transcranial Doppler sonography. *Front Neurol Neurosci* 2006;21:150–61.
- [49] Rosset A, Spadola L, Ratib O. OsiriX: an open-source software for navigating in multidimensional DICOM images. *J Digit Imaging* 2004;17:205–16.
- [50] Teleflex: LMA MAD Nasal™ Intranasal Mucosal Atomization Device Morrisville, NC: Teleflex; 2018. <https://www.teleflex.com/usa/product-areas/ems/intranasal-drug-delivery/mad-nasal-atomization-device/index>. Accessed November 29, 2018.
- [51] Fearnley JM, Lees AJ. Ageing and Parkinson's disease: substantia nigra regional selectivity. *Brain* 1991;114:2283–301.
- [52] Kim H, Chiu A, Lee SD, Fischer K, Yoo S-S. Focused ultrasound-mediated non-invasive brain stimulation: examination of sonication parameters. *Brain Stimul* 2014;7:748–56.