



CASE REPORT

Open Access

Primary chondrosarcoma of the breast: a case presentation and review of the literature

Sanaa Errorhay^{1*}, Mohamed Fetohi², Samia Mahmoud¹, Hanane Saadi¹, Chahrazed Bouchikhi¹ and Abdelaziz Banani¹

Abstract

Mammary sarcomas are uncommon tumors. When tumors like malignant cystosarcomaphyllodes and metaplastic carcinoma, where malignant cartilaginous areas may be present, are excluded, only nine cases have been reported to date. We report another case of primary chondrosarcoma of the breast here. A 24-year-old Mediterranean woman presented with a painful mass in the right breast and a physical examination revealed a palpable mass. An incisional biopsy was performed and primary chondrosarcoma was diagnosed based on histological examination. Our patient underwent a mastectomy. A preoperative clinical and cytological diagnosis of chondrosarcoma, even though possible in a few cases, is usually not attained due to its similar clinical behavior with other breast tumors.

Keywords: Chondrosarcoma, Breast, Sarcoma

Background

Pure sarcomas are very uncommon tumors of the breast, representing about 0.5% of all mammary tumors. These are rare tumors that must be considered in the differential diagnosis of breast tumors when chondrosarcomatous areas are involved. It is important that they are recognized as a separate entity from the more common breast carcinomas and the difference in behavior of these two tumors is taken into account when planning therapy.

Case presentation

A 24-year-old Mediterranean woman presented with a painful mass in the right breast that had increased in size over a period of five months. The woman had no medical history, and no family history, of breast cancer. A physical examination revealed a palpable mass in her right breast measuring 10 mm to 15 mm in size, not fixed to underlying tissues and not involving the overlying skin. Her contralateral breast and axilla were normal on clinical examination. On mammography, the mass was well demarcated (Figure 1). Her liver ultrasound scan, chest X-ray and bone scintigraphy were normal. An incisional biopsy was performed and the histological examination showed abundant cartilaginous proliferation

varying from mature cartilage to poorly differentiated areas (Figure 2). An immunohistochemical study was performed and immunoreactivity was detected for vimentin but not for AE1/AE3, CK7, and estrogen and progesterone receptors. There was also no overexpression of the HER-2/neu oncoprotein. A final diagnosis of chondrosarcoma of the breast was made with the absence of phyllodes tumor or carcinoma in the whole tumor. Our patient underwent a mastectomy.

Discussion

Primary breast sarcomas are a highly heterogeneous group of tumors. A majority of these tumors are malignant fibrous histiocytoma, fibrosarcoma, liposarcoma and less commonly angiosarcoma, rhabdomyosarcoma, dermatofibrosarcoma, desmoids tumors and so on. A primary chondrosarcoma of the breast is an extremely rare entity. It contains chondrosarcomatoid sectors which arise from mammary tissue. Only nine cases of pure chondrosarcoma have been reported: Kennedy and Biggart reported the first case in 1967, Beltaos and Banerjee reported two cases in 1978, and Thilagavathi brought the fourth case in 1992 [1-3]. The fifth case was reported by Guymer *et al.* in 2001 and the 10th case is reported here [4]. The prognosis of chondrosarcomatous breast tumors is not fully known, because many of the reported cases are difficult to analyze owing to the lack of detailed clinical or morphological information. These

* Correspondence: suine_err@yahoo.fr

¹Department of Obstetrics and Gynecology, University Hospital Hassan II, Sidi Harazem Road, Fez 30000, Morocco

Full list of author information is available at the end of the article

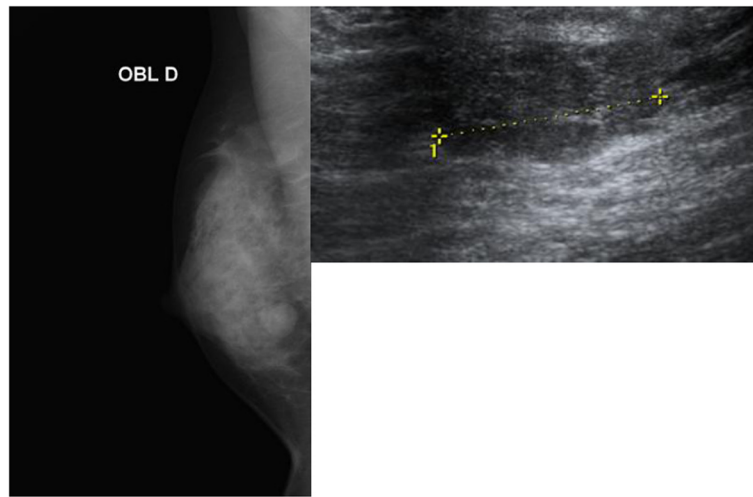


Figure 1 Mammography showing a round,well delineated opaque image in the lower outer quadrant of the right breast. Ultrasound showing a well delineated bilobed tissue lesion measuring 15 mm.

tumors are usually large-sized and occur in women over 40 years old. These tumors usually do not invade the overlying skin [1]. Axillary adenopathy are found in 14 to 29% of the cases, most of which are reactive hyperplasia. The present case substantiates the clinical findings of previously reported cases [1]. To diagnose a primary chondrosarcoma of the breast, a non-mammary primary site has to be excluded clinically and histologically. Differentiation from metaplastic carcinoma is possible by the absence of direct transition between the carcinomatous and the mesenchymal component in the former metaplastic carcinoma. Further, although the sarcoma-like elements in metaplastic carcinoma acquire vimentin positivity, they still retain epithelial markers [5].

Differentiation from malignant cystosarcomaphyllodes with predominant chondrosarcomatoid components can be extremely difficult. Most mammary tumors with areas of chondroid metaplasia have a benign histological appearance. Cystosarcomaphyllodes displaying a chondrosarcomatous element are very rare.

The majority of information that guides treatment management consists of retrospective chart reviews, anecdotal experience, and case reports. Surgery remains the choice of treatment for most sarcomatoid tumors [6]. Multimodality treatment may decrease local and systemic recurrence rates of somatic sarcomas, but results are inconclusive in patients with breast sarcomas [7,8]. The role of chemotherapy and radiotherapy is not yet established because of the limited number of cases reported so far. The tumor was negative for any of the hormonal receptors. This supports the theory that adjuvant therapy with estrogen antagonists and other hormone manipulations have no role in the treatment of mammary sarcomas.

The adjuvant treatment can decrease the rates of local and systematic recurrences, but the results are not significant because of the rarity of this pathological entity and the small number of cases reported, which makes the evaluation of the role of chemotherapy and radiotherapy in primary breast chondrosarcoma more difficult [7,9,10]. In Emad *et al.*'s study of malignant matrix-

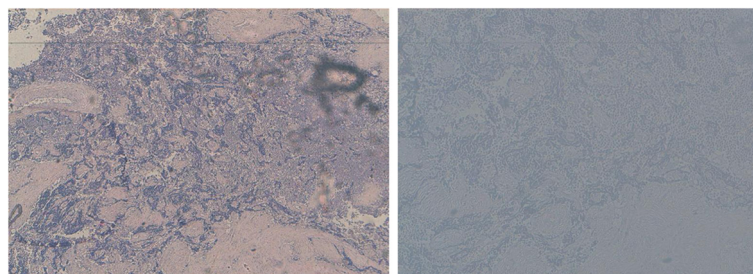


Figure 2 Round or oval tumor cell proliferation containing various differentiated cartilaginous tissues.

producing breast tumors (MP-MBC), they concluded that most MP-MBCs are variants of metaplastic breast carcinoma (MBC) with predominant mesenchymal components behaving similarly to ductal carcinomas. Nevertheless, these tumors cannot be managed differently from other forms of triple-negative breast cancer as there exist limited data on their response to systemic therapy [11].

Conclusions

Primary sarcomas of the breast are rare tumors and it is important that these tumors are recognized as a separate entity from the more common breast carcinomas and the difference in behavior of these two tumors is kept in mind when planning therapy.

Consent

Written informed consent was obtained from the patient for publication of this manuscript and any accompanying images. A copy of the written consent is available for review by the Editor-in-Chief of this journal.

Competing interests

The authors declare that they have no competing interests.

Authors' contributions

ES designed and wrote the paper. FM carried out the medical treatment. SM and SH performed the surgery. BC provided the pathological diagnosis. BA designed the paper. All authors read and approved the final manuscript.

Author details

¹Department of Obstetrics and Gynecology, University Hospital Hassan II, Sidi Harazem Road, Fez 30000, Morocco. ²Department of Oncology, Moulay Ismail Hospital, Ville Nouvelle, Meknes 50020, Morocco.

Received: 12 March 2013 Accepted: 7 August 2013

Published: 21 August 2013

References

1. Kennedy T, Biggart JD: **Sarcoma of the breast.** *Br J Cancer* 1967, **21**:635–644.
2. Beltaos E, Banerjee TK: **Chondrosarcoma of the breast: a case report of two cases.** *Am J Clin Pathol* 1979, **71**:345–349.
3. Thilagavath G, Subramanian S, Samuel AV, Rani U, Somasundaram C: **Primary chondrosarcoma of the breast.** *J Indian Med Assoc* 1992, **90**:16–17.
4. Guymar S, Ferlicot S, Genestie C, Genestie C, Gelberg JJ, Blondon J, Le Charpentier Y: **Breast chondrosarcoma: a case report and review.** *Ann Pathol* 2001, **21**:168–171.
5. Vandenhoute B, Validire P, Veilleux C, Voelh P, Zafrani B: **Breast carcinoma with chondroid metaplasia.** *Ann Pathol* 1995, **15**:53–58.
6. Callery CD, Rosen P, Kinne DW: **Sarcome du sein. Une étude de 32 patients présentant la réestimation de la classification et de la thérapie.** *Ann Surg* 1985, **201**:527–532.
7. Rosen PP: **Sarcoma.** In *Rosen's Breast Pathology*. Edited by Rosen PP. Philadelphia: Lippincott Williams and Wilkins; 2001:813.
8. Van Deurzen CH, Lee AH, Gill MS, Menke-Pluijmers MB, Jager A, Ellis IO: **Metaplastic breast carcinoma: tumour histogenesis or dedifferentiation?** *J Pathol* 2011, **224**:434–437.
9. Tseng WH, Martinez SR: **Metaplastic breast cancer: to radiate or not to radiate?** *Ann Surg Oncol* 2011, **18**:94–103.
10. Gurleyik E, Yildirim U, Gunal O, Pehlivan M: **Malignant mesenchymal tumor of the breast: primary chondrosarcoma.** *Breast Care* 2009, **4**:101–103.

11. Rakha E, Tan PH, Shaaban A, Tse GM, Esteller FC, Van Deurzen CH, Purnell D, Stotter A, Chan T, Yamaguchi R, Dodwell D, Jager A, Soler MT, Juneinah E, Plaza ML, Hodi Z, McCulloch T, Lee AH, Ellis IO: **Do primary mammary osteosarcoma and chondrosarcoma exist? a review of a large multi-institutional series of malignant matrix-producing breast tumors.** *Breast* 2013, **22**:13–18.

doi:10.1186/1477-7819-11-208

Cite this article as: Errarhay et al.: Primary chondrosarcoma of the breast: a case presentation and review of the literature. *World Journal of Surgical Oncology* 2013 **11**:208.

Submit your next manuscript to BioMed Central and take full advantage of:

- Convenient online submission
- Thorough peer review
- No space constraints or color figure charges
- Immediate publication on acceptance
- Inclusion in PubMed, CAS, Scopus and Google Scholar
- Research which is freely available for redistribution

Submit your manuscript at
www.biomedcentral.com/submit

