



Contents lists available at ScienceDirect

Gynecology and Minimally Invasive Therapy

journal homepage: www.e-gmit.com

Case report

A case of bilateral tubal pregnancy



Ayano Funamizu^a, Atsushi Fukui^{a, b, *}, Rie Fukuhara^a, Asami Kobayashi^a, Hitomi Chiba^a, Yukiko Matsumura^a, Asami Ito^a, Hideki Mizunuma^{a, c}

^a Department of Obstetrics and Gynecology, Hirosaki University Graduate School of Medicine, Japan

^b Department of Obstetrics and Gynecology, Hyogo College of Medicine, Japan

^c Department of Obstetrics and Gynecology, Fukushima Medical University, Japan

ARTICLE INFO

Article history:

Received 25 December 2015

Received in revised form

10 April 2017

Accepted 12 May 2017

Available online 6 July 2017

Keywords:

bilateral tubal pregnancy

ectopic pregnancy

human menopausal gonadotropin

laparoscopy

ABSTRACT

Bilateral tubal pregnancy is very rare and occurs in only 1 out of every 200,000 spontaneous pregnancies. In this case, a 29-year-old woman with a history of primary infertility underwent treatment with human menopausal gonadotropin (hMG)-human chorionic gonadotropin (hCG), and became pregnant. A gestational sac (GS) was not detected in the uterus and transvaginal ultrasonography (USG) revealed GS with fetal heartbeat in the left adnexa at 7 weeks and 6 days of gestation. The patient underwent laparoscopic surgery and ultimately, bilateral tubal pregnancy was diagnosed. Consequently, bilateral fallopian tube resection was performed. Afterwards, she conceived by assisted reproductive technology (ART) and delivered vaginally. This case suggests that even if a GS is found in one fallopian tube by USG, it is important to evaluate the other fallopian tube carefully.

Copyright © 2017, The Asia-Pacific Association for Gynecologic Endoscopy and Minimally Invasive Therapy. Published by Elsevier Taiwan LLC. This is an open access article under the CC BY-NC-ND license (<http://creativecommons.org/licenses/by-nc-nd/4.0/>).

Dear Editor,

The incidence of bilateral tubal pregnancy has been reported to be 1 out of every 200,000 intrauterine pregnancies¹ and range from 1 out of every 725 to 1580 ectopic pregnancies.² We experienced a case of bilateral tubal pregnancy.

A 29-year-old woman with a history of primary infertility underwent human menopausal gonadotropin (hMG)-human chorionic gonadotropin (hCG) treatment at a local clinic. She was injected with a total dose of 675 IU of hMG. Three mature follicles (1 follicle in the right ovary and 2 follicles in the left ovary) were detected by transvaginal ultrasonography (TV-USG) and she was then injected with 5000 IU of hCG to induce ovulation. She conceived naturally, but experienced sustained genital tract bleeding. No gestational sac (GS) was detected in the uterus and

serum hCG level was 33,000 mIU/ml at 7 weeks and 2 days of gestation. TV-USG revealed GS with fetal heartbeat in the left adnexa at 7 weeks and 6 days of gestation. Ectopic pregnancy was suspected and she was transported to our hospital by ambulance.

On admission, she presented with genital tract bleeding, blood pressure of 116/73 mmHg, and heart rate of 86 beats per minute, although she denied abdominal pain. Serum hCG level was 44,557 mIU/ml. TV-USG revealed a 4.5 cm left adnexal mass suggestive of an ectopic pregnancy and a small amount of free fluid. No intrauterine pregnancy was visualized. She immediately underwent laparoscopic surgery. There was a 5 cm, unruptured, left ampulla tubal pregnancy and, unexpectedly, a 4 cm, unruptured, right ampulla tubal pregnancy as well (Fig. 1A). We repeated TV-USG during surgery to inspect her uterus and adnexa and detected GS without fetal heartbeat in the right fallopian tube. Therefore, we decided to resect the fallopian tubes bilaterally. Serum hCG level was 16,398 mIU/ml the day after bilateral salpingectomy and she was discharged without incident three days later. The resected specimen revealed villi in bilateral tubes and the diagnosis of bilateral tubal pregnancy was established. She subsequently conceived by in vitro fertilization embryo transfer (IVF-ET) and delivered vaginally successfully.

According to the guidelines of the National Institute for Health and Care Excellence (NICE), women who have an ectopic

Abbreviations: TV-USG, transvaginal ultrasound; hCG, human chorionic gonadotropin; DD, dichorionic-diamniotic.

Conflicts of interest: The authors have no conflicts of interest relevant to this article.

* Corresponding author. Department of Obstetrics and Gynecology, Hyogo College of Medicine, 1-1 Mukogawa-cho, Nishinomiya, Hyogo 663-8501, Japan. Fax: +81 798 46 4163.

E-mail address: a.fukuipon@mac.com (A. Fukui).

<http://dx.doi.org/10.1016/j.gmit.2017.05.003>

2213-3070/Copyright © 2017, The Asia-Pacific Association for Gynecologic Endoscopy and Minimally Invasive Therapy. Published by Elsevier Taiwan LLC. This is an open access article under the CC BY-NC-ND license (<http://creativecommons.org/licenses/by-nc-nd/4.0/>).

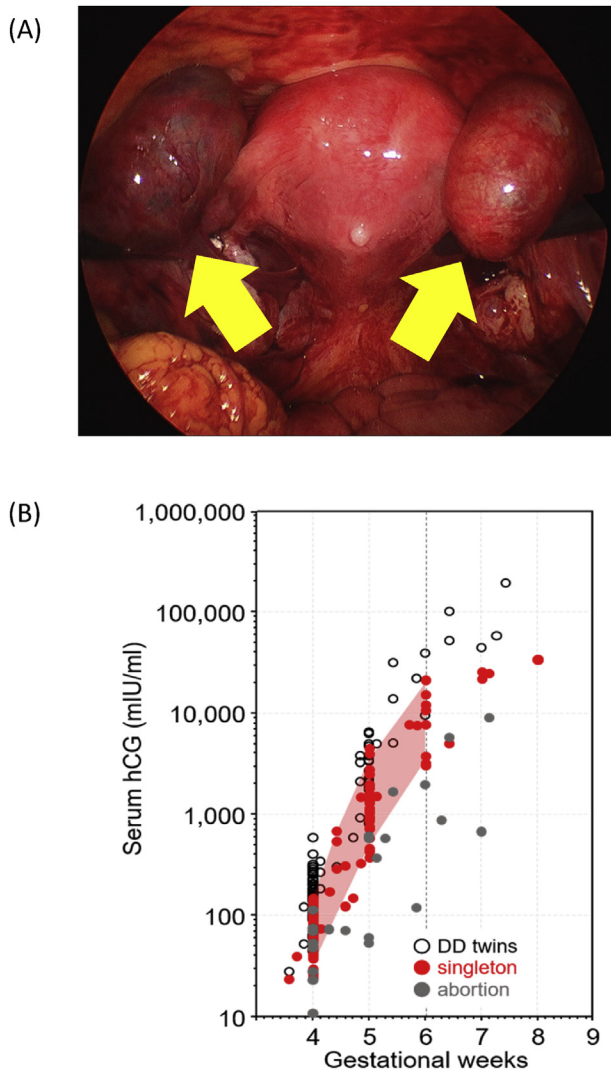


Figure 1. (A) Bilateral tubal pregnancy during surgery. Image of bilateral tubal pregnancy diagnosed at time of surgery. The yellow arrows indicate the swollen fallopian tubes. Left tubal pregnancy diagnosed by TV-USG prior to surgery, but right tubal pregnancy was previously undiagnosed; (B) Transition of serum hCG level in early stages of pregnancy for singleton, twins, and abortion in our hospital data. Serum hCG level in this case within the range expected for singleton pregnancy. The vertical axis shows the serum hCG level and the horizontal axis shows gestational weeks. White circles represent hCG levels for DD twins. Red circles indicate hCG levels for singleton pregnancy. Gray circles indicate hCG level in cases of abortion.

pregnancy with any of the following symptoms are recommended for surgery: significant pain, adnexal mass of 35 mm or larger, positive fetal heartbeat, or serum hCG level in excess of 5000 mIU/ml.³ In this case, we chose to perform a salpingectomy because the serum hCG level was more than 5000 mIU/ml and positive fetal heartbeat was detected in the left tube. However, the applicability criteria for conservative surgical intervention for tubal pregnancy in Japan, written according to the guidelines of the Japan Society of Gynecologic and Obstetric Endoscopy and Minimally Invasive Therapy are as follows: child hope, mass diameter less than 5 cm, serum hCG level lower than 10,000 mIU/ml, first episode of tubal pregnancy, negative fetal heartbeat, and unruptured tubal pregnancy. By this criteria, we would have conserved the right fallopian tube.

Risk factors of tubal pregnancy are damage to the endosalpinx produced by sexually transmitted infections, distortion of pelvic anatomy caused by diseases like endometriosis or by adhesions after previous interventions, etc.¹ In addition to these, the occurrence of multiple ovulations by ovulation induction could cause bilateral tubal pregnancy. It is difficult to diagnose earlier and there have been many unrecognized cases of bilateral tubal pregnancy that were only diagnosed at the time of surgery.^{1,4} In this case, right tubal pregnancy could not be diagnosed by TV-USG prior to surgery. The serum hCG level should not be used as the sole parameter for diagnosis of ectopic pregnancy because the rise in hCG level is generally slower in ectopic pregnancy.^{1,3,5} In this case, Serum hCG level was 44,557 mIU/ml at 7 weeks and 6 days of gestation and was within the range expected for a singleton (Fig. 1B).

In conclusion, even if a GS is found in one fallopian tube by USG, the other fallopian tube needs to be examined carefully as well. It is likewise important to check bilateral fallopian tubes during surgery to inspect for ectopic pregnancy.

References

1. De Los Rios JF, Castaneda JD, Miryam A. Bilateral ectopic pregnancy. *J Minim Invasive Gynecol.* 2007;14(4):419–427.
2. Abrams RA, Kanter AE. Bilateral simultaneous extrauterine pregnancy. *Am J Obstet Gynecol.* 1948;56(6):1198–1200.
3. London. *Ectopic Pregnancy and Miscarriage: Diagnosis and Initial Management in Early Pregnancy of Ectopic Pregnancy and Miscarriage.* 2012.
4. Amine BH, Haythem S. Extra-uterine twin pregnancy: case report of spontaneous bilateral tubal ectopic pregnancy. *Pan Afr Med J.* 2015;20:435.
5. Morse CB, Sammel MD, Shaunik A, et al. Performance of human chorionic gonadotropin curves in women at risk for ectopic pregnancy: exceptions to the rules. *Fertil Steril.* 2012;97(1), 101–106 e102.