


# Use of two parallel oxygenators during veno-venous extracorporeal membrane oxygenation in a patient with severe obesity and COVID-19 pneumonia

Perfusion  
2022, Vol. 0(0) 1–4  
© The Author(s) 2022  
Article reuse guidelines:  
[sagepub.com/journals-permissions](https://sagepub.com/journals-permissions)  
DOI: 10.1177/02676591221115264  
[journals.sagepub.com/home/prf](https://journals.sagepub.com/home/prf)  


Atsushi Miyazato, Yutaka Kondo,  Kentaro Seki, Yasuaki Kumakawa, Tadashi Ishihara, Koichiro Sueyoshi, Ken Okamoto and Hiroshi Tanaka

## Abstract

**Background:** Veno-Venous Extracorporeal Membrane Oxygenation (VV-ECMO) is one effective treatment for COVID-19 pneumonia, but controversy regarding VV-ECMO management in obese patients still exists. In this report, we described a case in which two oxygenators were used in parallel in a severely obese patient (Body mass index: 60 kg/m<sup>2</sup>, body surface area: 2.8 m<sup>2</sup>).

**Case:** The case was of a 27-year-old man diagnosed with COVID-19 pneumonia and admitted to our hospital. VV-ECMO was required on the fifth day after admission due to gradually worsening respiratory conditions and partial pressure of arterial oxygen (PaO<sub>2</sub>)/FiO<sub>2</sub> ratio of 77. Immediately after the initiation of VV-ECMO, post-oxygenator in circuit, PaO<sub>2</sub> was low at 134 mmHg. Even though the VV-ECMO circuit was replaced on the same day, the PaO<sub>2</sub> still was low at 261 mmHg. Thus, we decided to use two oxygenators in parallel, after which the PaO<sub>2</sub> stabilized at 400–500 mmHg.

**Conclusions:** In this case, VV-ECMO oxygenation could be stabilized by utilizing two oxygenators in parallel. Using two membrane oxygenators may be a treatment option in severely obese patients with respiratory failure.

## Keywords

Obesity, extracorporeal membrane oxygenation, critical care, COVID-19, SARS-CoV-2

## Introduction

Veno-venous extracorporeal membrane oxygenation (VV-ECMO) is considered to be effective for patients with coronavirus disease 2019 (COVID-19) pneumonia. Among COVID-19 associated VV-ECMO patients, 49% were obese with a mean body mass index (BMI) of 32 kg/m<sup>2</sup>, signifying that obese patients are commonly seen.<sup>1</sup> However, VV-ECMO use in obese patients is associated with many issues, including cannulation difficulties, higher circuit flow requirements, increased bleeding and thrombosis, and complications due to pre-existing comorbidities.<sup>2</sup> Thus, obesity has historically been considered a relative contraindication for VV-ECMO support.<sup>3</sup> In particular, severely obese patients are difficult to treat with VV-ECMO.

We herein report a case of a severely obese patient (BMI: 60 kg/m<sup>2</sup>) with COVID-19 pneumonia who

initially underwent VV-ECMO with one oxygenator, followed by the application of two oxygenators in parallel.

## Case description

A 27-year-old male presented with a chief complaint of dyspnea and reported having a cough and fever for 5 days prior to the hospital visit. The patient was initially diagnosed with upper respiratory tract inflammation at

---

Department of Emergency and Critical Care Medicine, Juntendo University Urayasu Hospital, Urayasu, Japan

### Corresponding author:

Yutaka Kondo, Department of Emergency and Critical Care Medicine, Juntendo University Urayasu Hospital, 2-1-1, Tomioka, Urayasu 2790021, Japan.

Email: [kondokondou2000@yahoo.co.jp](mailto:kondokondou2000@yahoo.co.jp)

a nearby clinic. The patient revisited the clinic, and COVID-19 antigen testing confirmed a positive infection. The patient was then urgently transported to our hospital, as he had also developed dyspnea.

The patient was severely obese, with a BMI of 60 kg/m<sup>2</sup> (height: 175 cm, body weight: 184 kg, body surface area: 2.8 m<sup>2</sup>). He had a medical history of depression. He had the following vital signs upon hospital admission: blood pressure: 123/55 mmHg, heart rate: 90 beats/min, respiratory rate: 20 breaths/min, oxygen saturation (SpO<sub>2</sub>): 93% (room air), body temperature: 36.9°C, and Glasgow Coma Scale score: E4V5M6. A chest radiograph revealed reduced transparency and ground-glass opacity predominantly in the periphery of both lungs. SARS-CoV-2 nucleic acid detected using the fluorescence quantitative reverse transcription-polymerase chain reaction method was positive.

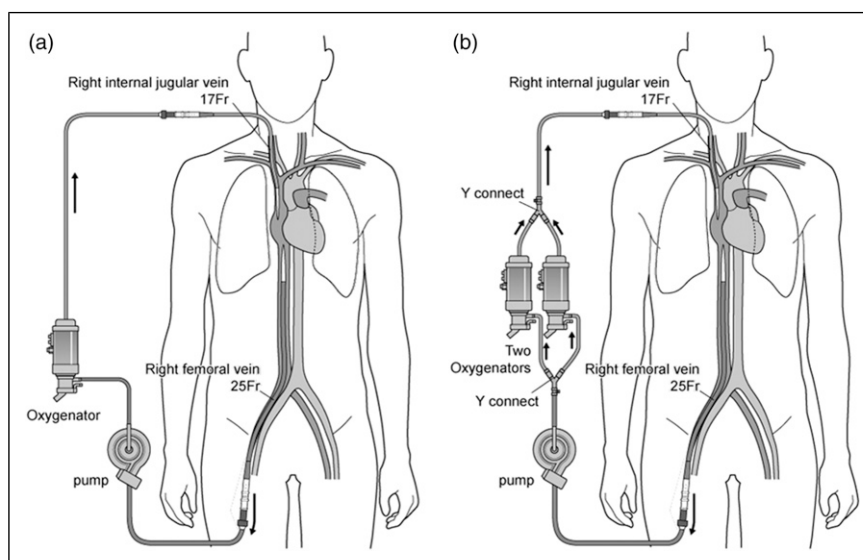
The patient was admitted to the general hospital ward on day 1. Due to a decline in respiratory condition, he was moved to the intensive care unit (ICU) and intubated on day 2. The patient had difficulty assuming a prone position due to severe obesity; therefore, VV-ECMO (Custom Pack EBS Heart Lung Kit Type LX with Heat Exchanger [Capiiox<sup>®</sup>; Terumo, Tokyo, Japan]; Maximum flow, 7 L/min) was initiated on day 5 after admission. A 17 Fr cannula was placed by puncture in the right internal jugular vein as a cannula for return, and a 25 Fr cannula was placed in the right femoral vein as a drainage cannula by surgical cutdown. After VV-ECMO initiation, the ventilator was set to the lung rest setting. VV-ECMO was started with a flow of 6 L/min and a rotation speed of 2523 rpm. However, the post-oxygenator in circuit PaO<sub>2</sub>

was low (134.4 mmHg). The PaO<sub>2</sub> remained between 81 and 261 mmHg although the oxygenator was replaced with a new one on the same day.

On day 6, we decided to add another oxygenator which was placed in parallel to stabilize SpO<sub>2</sub> (Figure 1). This strategy improved the PaO<sub>2</sub> levels to 479 mmHg, and no subsequent decrease was observed. We set a ECMO flow of 6.5 L/min and flow sensors revealed that each oxygenator received a blood flow of 3.2 L/min and 3.3 L/min, respectively. To verify the efficacy of two oxygenators, we calculated the oxygen delivery (DO<sub>2</sub>) and oxygen consumption (VO<sub>2</sub>) ratios. In the case of one oxygenator, the DO<sub>2</sub>/VO<sub>2</sub> was 3.50, which was slightly lower than normal. After using two oxygenators, the DO<sub>2</sub>/VO<sub>2</sub> showed a clear improvement to 4.97 (Table 1). On day 17, the patient was successfully withdrawn from VV-ECMO, although bleeding was seen from the cannula site for return. The bleeding complication was not related to the replacement of the two oxygenators, although it was associated with the ECMO equipment.

## Discussion

In this case, a patient with severe obesity and COVID-19 pneumonia showed a low post-oxygenator in circuit PaO<sub>2</sub> level during VV-ECMO. Thus, we decided to use two oxygenators in parallel to manage VV-ECMO safely. As shown in Table 1, the use of two oxygenators in parallel stabilized the PaO<sub>2</sub> and arterial blood oxygen saturation (SaO<sub>2</sub>) to 400–500 mmHg and ≥95%, respectively, which reflected improved SpO<sub>2</sub>.



**Figure 1.** (a) Extracorporeal membrane oxygenation circuit with an oxygenator on pump (b) Two oxygenators in parallel after hybrid configuration.

**Table 1.** Changes in oxygenation before and after induction of two oxygenators.

	An oxygenator (ECMO pump on)	Two oxygenators	Wean off ECMO
Pump flow (L/min)	6.02	6.5	5.74
Hgb (g/dL)	15	13.7	12.4
PaO <sub>2</sub> after oxygenator (mmHg)	134.4	478.9	423.9
DO <sub>2</sub> /VO <sub>2</sub>	3.50	4.97	—
Arterial blood gases			
pH	7.423	7.52	7.493
PaCO <sub>2</sub> (mmHg)	42	36.6	36.2
PaO <sub>2</sub> (mmHg)	56.1	88.6	88.5
SaO <sub>2</sub> (%)	89.6	97.2	96.1
HCO <sub>3</sub> <sup>-</sup> (mEq/L)	26.8	29.3	27.3
Lactate (mg/dL)	13.5	19.9	14.6

ECMO: extracorporeal membrane oxygenation; DO<sub>2</sub>: Oxygen delivery (ml/min), VO<sub>2</sub>: Oxygen consumption (ml/min).

In general, a post-oxygenator in circuit PaO<sub>2</sub> greater than 300 mmHg indicates that the membrane oxygenator is functioning well.<sup>3</sup> In this case, the PaO<sub>2</sub> remained low even after initial oxygenator placement and subsequent replacement. It was unlikely that there was a problem with the oxygenator itself, as checks performed after oxygenator replacement did not reveal any thrombi or mechanical issues.

The standards for the levels of O<sub>2</sub> consumption and CO<sub>2</sub> emission in patients with obesity, severe acute respiratory distress syndrome, infection, or head trauma that are managed with VV-ECMO are currently unclear.<sup>4</sup> ELSO guidelines recommend a SaO<sub>2</sub> of 80–85% or even 75–80% for critically ill VV-ECMO patients.<sup>3</sup> In our case, SaO<sub>2</sub> in the body showed ≥80% during VV-ECMO (Table 1).

Obese patients experience specific physiological changes. Some advocate that obese patients have a higher cardiac output than non-obese patients to maintain the O<sub>2</sub> supply in a larger body.<sup>5</sup> As obese patients have a higher cardiac output, the blood flow to the lungs also increases. Occasionally, this change creates a systemic shunt of the blood flow via the native lungs. Furthermore, a shunt can be induced in a VV-ECMO circuit if the VV-ECMO flow rate is high.<sup>6,7</sup> The present case demonstrated that this situation could be solved by using two oxygenators. Using two oxygenators separates blood flow to each oxygenator and enables efficient oxygenation. We used two oxygenators in parallel and set a VV-ECMO flow of 6.5 L/min. Flow sensor revealed that each oxygenator received half of the entire blood flow. We assumed that a low shunt proportion and a high oxygenation proportion improved the situation. This meant that a shunt in the VV-ECMO circuit was suspected when using one oxygenator. Furthermore, we set two oxygenators in parallel because two sequential

oxygenators would not promote good oxygenation efficiency as the second oxygenator would oxygenate the blood, which has already been oxygenated by the first.

Different kinds of oxygenators could avoid using two oxygenators. The oxygenator which we used had 2.5 m<sup>2</sup> membrane area. Oxygenator for high-flow extracorporeal gas exchange (larger membrane area, etc.) could be a solution in this situation.

We could not find any obvious thrombi or mechanical problems visually. However, some issues might have occurred in the oxygenator which could not have been detected by visual inspection. Non-visualized clots might cause oxygenator failure because severely obese patients have increased blood viscosity, making thrombus formation easier. Lipid droplets can also cause emboli and lipid is more difficult to see visually.

We would have replaced the entire circuit in the event of occurrence of oxygenator failure. This is because we are used to replacing the entire circuit although some hospitals may change only the oxygenator in trouble. The strategy may vary depending on the clinician's experience, hospital preference, and even situation.

DO<sub>2</sub>/VO<sub>2</sub> ranges of 4–5 are normal, and a DO<sub>2</sub>/VO<sub>2</sub> < 2 can cause anaerobic metabolism. In this case, two oxygenators were able to maintain the normal range of DO<sub>2</sub>/VO<sub>2</sub> value, although the DO<sub>2</sub>/VO<sub>2</sub> showed below normal values during one oxygenator. Aerobic metabolism was safely ensured by two oxygenators. The increase of DO<sub>2</sub>/VO<sub>2</sub> may be an advantage for VV-ECMO oxygenation in obese patients.

As global trends of obesity increase, the use of VV-ECMO in obese patients is also increasing. The two-oxygenator strategy may be a useful treatment option for obese patients requiring VV-ECMO.

## Conclusion

We demonstrated O<sub>2</sub> supply stabilization in a patient with severe obesity (BMI of 60 kg/m<sup>2</sup>) by using two parallel oxygenators. The use of two parallel oxygenators may be useful in patients with severe obesity requiring VV-ECMO.

## Declaration of conflicting interests

The author(s) declared no potential conflicts of interest with respect to the research, authorship, and/or publication of this article.

## Funding

The author(s) received no financial support for the research, authorship, and/or publication of this article.

## ORCID iD

Yutaka Kondo  <https://orcid.org/0000-0003-1072-7089>

## References

1. Extracorporeal Life Support Organization. *Full COVID registry dashboard*, <https://www.else.org/COVID19.aspx> (2021, accessed 15 December 2021).
2. Azouz V, Hill S, Firstenberg M, et al. Extracorporeal membrane oxygenation in extreme obesity: a case report and review of the literature. *Heart Surg Forum* 2018; 21(6): E485–E488.
3. Extracorporeal Life Support Organization. *General guidelines for all ECLS cases*, [https://www.else.org/Portals/0/ELSO-Guidelines-General-All-ECLS-Version-1\\_4.pdf](https://www.else.org/Portals/0/ELSO-Guidelines-General-All-ECLS-Version-1_4.pdf) (2017, accessed 15 December 2021).
4. Leloup G, Rozé H, Calderon J, et al. Use of two oxygenators during extracorporeal membrane oxygenator for a patient with acute respiratory distress syndrome, high-pressure ventilation, hypercapnia, and traumatic brain injury. *Br J Anaesth* 2011; 107(6): 1014–1015.
5. Vasan RS. Cardiac function and obesity. *Heart* 2003; 89(10): 1127–1129.
6. Umei N, Ichiba S. Venovenous extracorporeal membrane oxygenation as a treatment for obesity hypoventilation syndrome. *Case Rep Crit Care* 2017; 2017: 9437452.
7. Gaglani B, Westphal ND, Bryant C, et al. An 18-year-old survivor with a body mass index of 73.9 kg/m<sup>2</sup> on venovenous extracorporeal membrane oxygenation for coronavirus disease 2019: a collaborative multidisciplinary effort. *Crit Care Explorations* 2021; 3(1): e0331.