

# Evaluation of Postoperative Sensory and Motor Deficit Following Craniomaxillofacial Reconstruction Using Bicoronal Flap: An Evaluative Study

B. C. Sikkerimath, Aditya Anshu, Anu Jose, Saurabh Jain

Department of Oral and Maxillofacial Surgery, PMNM Dental College and Hospital, Bagalkot, Karnataka, India

## Abstract

**Introduction:** The ideal surgical approach to treat craniomaxillofacial skeleton should provide maximum exposure of the facial skeleton, ensure less potential for injury to facial structures and allow for good cosmetic result. Several designs have been described such as hemicoronal, preauricular, lateral eyebrow, and bicoronal approach. Although the bicoronal flap gives superior long-term cosmetic results, it has a few disadvantages. We conducted this study to assess neurosensory disturbances and motor deficit following craniomaxillofacial reconstruction using bicoronal flap. **Materials and Methods:** A prospective study was carried out in the Department of Oral and Maxillofacial Surgery, North Karnataka, India. Forty patients with craniomaxillofacial trauma requiring fixation of fracture or reconstruction were included in the study. Postoperative neurosensory evaluation is carried out at intervals of 1 week, 1 month, 3 months, and 6 months clinically using mechanoreceptive and nociceptive testing. **Results:** Among 40 cases, 11 (27.5%) had postoperative paraesthesia affecting the supraorbital region; 9 (22.5%) of them had return of normal sensation within 6 months and 2 (5%) patients became normal after one year. Four patients had unilateral frontalis weakness on the right side for a period of 6 months. **Discussion:** The bicoronal flap is a preferred approach for access to the craniofacial skeleton and orbit with minimal sensory and motor complications. However, before choosing the same, the advantage of raising such a wide flap should be weighted comparing the benefits and complications.

**Keywords:** Flap, maxillofacial, orbit, paraesthesia, trauma

## INTRODUCTION

For many years facial fractures have been treated through a variety of small incisions placed strategically about the face, and these small wounds create multiple scars.<sup>[1]</sup> The scarring is aggravated when these peepholes are stretched by retractors and rubbed by mechanical tools such as drills and burs. Reducing the fractures and wiring them into position is often difficult when the surgeon is working through such small openings.

The ideal surgical approach to treat the craniomaxillofacial skeleton should provide maximum exposure of the facial skeleton, ensure less potential of injury to facial structure and allow for good cosmetic result.<sup>[2,3]</sup> Several designs have been described such as hemicoronal, preauricular, infraorbital, lateral eyebrow, and bicoronal approach.

Of the various approaches used in the treatment of facial lesions and injuries, the coronal approach, popularized by Tessier, is one of the most versatile of all.<sup>[4]</sup> He has shown that it is advantageous to create a coronal, subperiosteal flap to expose the skull and facial bones. His work with congenital and posttraumatic reconstructions has adequately demonstrated the safety of this procedure.<sup>[5]</sup>

**Address for correspondence:** Dr. Aditya Anshu,  
Department of Oral and Maxillofacial Surgery, PMNM Dental College and  
Hospital, Bagalkot, Karnataka, India.  
E-mail: aditya\_anshu93@yahoo.co.in

Received: 14-12-2020

Last Revised: 08-04-2021

Accepted: 17-04-2021

Published: 24-07-2021

This is an open access journal, and articles are distributed under the terms of the Creative Commons Attribution-NonCommercial-ShareAlike 4.0 License, which allows others to remix, tweak, and build upon the work non-commercially, as long as appropriate credit is given and the new creations are licensed under the identical terms.

For reprints contact: WKHLRPMedknow\_reprints@wolterskluwer.com

**How to cite this article:** Sikkerimath BC, Anshu A, Jose A, Jain S. Evaluation of postoperative sensory and motor deficit following craniomaxillofacial reconstruction using bicoronal flap: An evaluative study. *Ann Maxillofac Surg* 2021;11:21-6.

### Access this article online

#### Quick Response Code:



Website:  
www.amsjournal.com

DOI:  
10.4103/ams.ams\_426\_20

The bicoronal flap is a popular approach that provides excellent exposure to the upper and middle third of the face and also provides an esthetic and low morbidity repair.<sup>[6,7]</sup>

It has the advantages of providing maximum exposure of the upper one-third of the facial skeleton and frontoparietal region of the cranium for the management of extensive craniofacial trauma and correction of craniofacial deformities, good cosmetic results, avoids injury to facial structures, and allows harvest and placement of cranial bone grafts.<sup>[8,9]</sup>

However, it may cause potential damage to the temporal branch of the facial nerve resulting in weakness of frontalis muscle, sensory disturbance, anaesthesia, or paraesthesia affecting supratrochlear nerve, supraorbital nerve, and preauricular region.<sup>[9-11]</sup>

The aims and objectives of the present study are to evaluate the postoperative sensory and motor deficit following craniomaxillofacial reconstruction using bicoronal flap, the persistence of neurosensory and motor deficit, and thus supporting or disputing its use as a versatile flap in maxillofacial reconstruction.

## SUBJECTS AND METHODS

An evaluative study was carried out in the Department of Oral and Maxillofacial Surgery for a period of 5 years from June 2015 to June 2020. Ethical clearance for the study was obtained from the Institutional Review Board of the institution where the study was performed (Clearance No. 1274). Forty patients with craniomaxillofacial trauma who were willing to participate in the study were included in the study. The procedure to be performed was explained, followed by informed written consent.

### Inclusion criteria:

Patients who are willing to participate in the study, patients who have not undergone any prior surgery in the craniomaxillofacial

region, patients >18 years of age, and patients who are medically fit to be taken under general anaesthesia were included in the study.

### Exclusion criteria

Patients with infected craniomaxillofacial fractures with large hematoma, medically compromised patients, and patients not willing to participate in the study were excluded from the study.

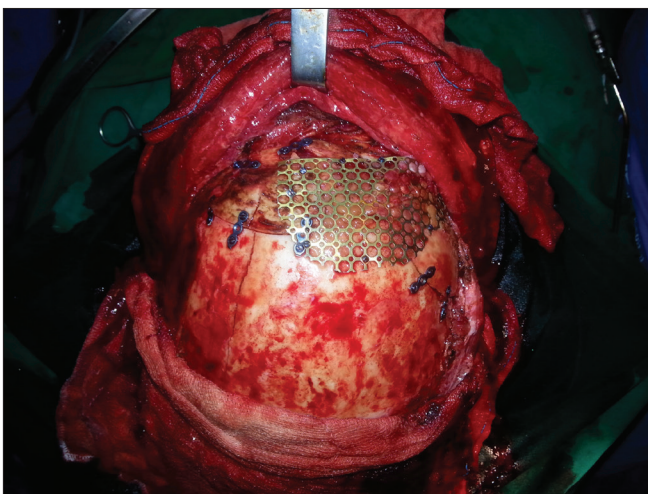
On admission, all patients underwent imaging examination which included computed tomography (CT) scan of the brain and face (axial and coronal section) with 3-D reconstruction if needed.

All patients were operated by the bicoronal surgical incision [Figure 1] for access to the craniofacial fracture site and in few cases, additional incisions such as the infraorbital and the intraoral degloving incisions were used for complete exposure of the midface.

All cases were treated under general anaesthesia with nasotracheal or submental intubation (in case of nasal bone fracture). The coronal incision began at the upper attachment of the helix and extended transversely over the vault of the skull to the midline and then to the contralateral helix. The incision can be slightly curved forward at the vertex of the skull following the hairline, but posterior to it. The flap was raised in the subgaleal plane leaving the periosteum intact. Continuous locking sutures at the flap margin or haemostats or Raney clips were used as an aid to haemostasis. The periosteum was incised about 3 cm above the supraorbital ridges and the dissection was then completed subperiosteally. If required the supraorbital neurovascular bundle was released from the notch/foramen.

The lateral dissection followed the outer surface of the temporalis fascia to approximately 2 cm above the zygomatic arch. At that point where the temporalis fascia splits into two layers, an incision running anterosuperiorly at 45° was made through the superficial layer of the temporalis fascia to spare the frontal branches of the facial nerve. This incision was connected anteriorly with the lateral or the posterior limb of the supraorbital periosteal incision. Once the plane of dissection was established deep to the superficial layer of the temporal fascia the dissection was continued inferiorly until the periosteum of the zygomatic arch was reached. The periosteum was then incised and reflected laterally over the arch, the body of the zygoma, and the lateral orbital rim. Reflection of the periosteum provided exposure of the frontal bone, the upper part of the nose and the nasoethmoidal region, the roof, medial and lateral walls of the orbit, the zygomatic bone, and the entire zygomatic arch. Other incisions such as the intraoral vestibular and the infraorbital were added for further exposure when necessary.

In case of anterior cranial fossa base fracture associated with facial fractures, dural repair and obliteration of frontal sinus



**Figure 1:** Intraoperative photograph

using tensor fascia lata graft was done by the neurosurgical team. This was followed by the fixation of fracture segments using titanium mesh and implants by the maxillofacial surgery team.

After reduction and fixation of the fragments using titanium mini plates and mesh or correction of craniomaxillofacial defect using bone cement (surgical simplex P -mixture of polymethyl methacrylate, methyl methacrylate-styrene-copolymer, and barium sulfate Ph.Eur.), the periosteum and the temporal fascia were sutured with 3-0 vicryl (Polyglactin), galea and skin were closed in layers with 2-0 Vicryl (Polyglactin) and 2-0 Ethilon (Monofilament polyamide) respectively. Suction drains were used in all patients and pressure dressing applied for 48 h.

All cases have been followed up for a minimum of 6 months in intervals of 1 week, 1 month, 3 months, and 6 months.

All cases have been evaluated clinically for the following parameters postoperatively.

### Neurosensory disturbances/paraesthesia<sup>[12]</sup>

Clinical neurosensory testing is generally divided into two basic categories, mechanoreceptive and nociceptive, based upon the specific receptors stimulated through cutaneous contact. Mechanoreceptive testing was done using two-point discrimination, static light touch, and brush directional stroke tests. Nociceptive testing was done using pin-prick and thermal discrimination tests.

Neurosensory testing was done in a quiet room with the patient and examiner relaxed and comfortable. Neurosensory dysfunctions were assessed using the following simple tests [Figure 2].

#### *Two-point discrimination*

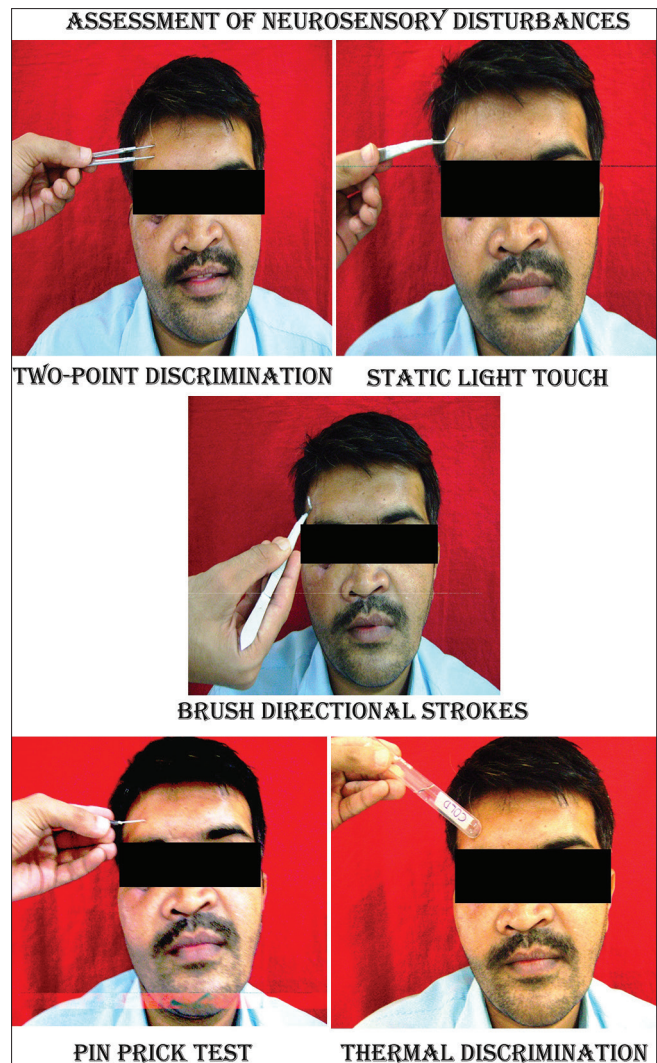
This is a test of tactile gnosis that assesses the quantity and density of functional sensory receptors and afferent fibers. It was measured with any instrument which allows the distance between two points to be altered such as caliper or graduated 2-points discrimination disc.

If sharp points are used, the small myelinated A- $\alpha$  and unmyelinated C afferent fiber of 0.5 to 0.7  $\mu$ m in diameter are assessed. However, if blunt points are used the larger myelinated A- $\alpha$  afferent fiber of 5 to 15  $\mu$ m in diameter is assessed.

After injury, two-point discrimination is slowest to recover. It must wait not only for myelination and maturation of the nerve fibers but also for the Meissner's corpuscles to become connected.

#### *Static light touch*

The instrument used for testing static light touch was fine 3-0 polypropylene suture. This monofilament suture was applied perpendicular to the skin surface until it just begins to deform or bend.



**Figure 2:** Neurosensory deficit evaluation during postoperative follow-ups

The examiner then chooses to either apply the monofilament or not apply the monofilament and immediately asks the patient for an appropriate response subsequent to his actions. The patient should respond to two of three correct as an appropriate response. If the patient responds correctly to only one of three, the process was repeated with increasingly stiffer monofilaments.

#### *Brush directional strokes*

Brushstroke direction was examined using fine 3-0 polypropylene suture. The technique was simple with the patient's eye closed, a brush made of 25 mm 3-0 prolene was first detected by the static light touch test and was gently stroked over 1 cm length of skin at a constant rate. The direction of the stroke was varied and the patient describes it on either forward to backward or backward to forward. Correct recognition was recorded as positive (present) in proforma.

This is a test of proprioception and assesses the integrity of the larger A- $\alpha$  and A- $\alpha$  myelinated axons which innervate the

lanceolate endings, Pacinian, and Meissner corpuscles. The putative sensory modalities for these receptors are vibrations, touch, and flutter. These are rapidly adapting receptors with myelinated afferent axons of 15 to 20 µm diameter.

#### Pin prick test<sup>[12,13]</sup>

This test assesses the free nerve endings and the small A-α and C fiber that innervate the free nerve endings responsible for nociception. The nociceptive discrimination test evaluates free nerve endings associated with small diameter axons which are the most resistant to injury.

For this test, sharp needle was held between the thumb and index finger and was applied firmly in a quick fashion with sufficient intensity of application to draw a small drop of blood at puncture site. The appropriate response should have been a feeling of sharp pain and was recorded as positive.

#### Thermal discrimination

In this test, a glass test tube containing water at 4°C was applied to the above test areas. Then the patient was asked to indicate whether he/she felt cold sensation and was noted as per his/her perception. Temperature discrimination test is utilized to detect small, myelinated, and unmyelinated A-α and sensory fiber injury. Correct recognition is recorded as positive in performa.

#### Temporal branch of facial nerve weakness

Assessed clinically by examination of frontal wrinkling and ability to close eyes tightly. Patient was asked to frown and wrinkle his or her forehead.

## RESULTS

The statistical software IBM SPSS statistics 20.0 (IBM SPSS Statistics 20.0, Karnataka, India) was used for the analysis of the data and Microsoft word and excel were used to generate graphs, tables, etc. Level of significance was fixed at  $P = 0.05$  and any value  $\leq 0.05$  was considered to be statistically significant.

All patients were followed up for 6 months [Tables 1 and 2] for analyzing neurosensory disturbances and motor deficit. Out of 40 cases of bicoronal flap, 11 cases had post-operative paraesthesia affecting the supraorbital region. Nine of these had return of normal sensation within 6 months and two patients became normal after 1 year.

None of the patients had supratrochlear, zygomaticotemporal, or auriculotemporal nerve anaesthesia or paraesthesia.

Only four patients had unilateral frontalis weakness on the right side. These patients were unable to produce wrinkles on the right forehead region. It got resolved spontaneously within a period of 6 months.

## DISCUSSION

The bicoronal flap is frequently used for surgical access in the treatment of midface fractures above the level of Le Fort I.<sup>[13]</sup> It

provides the best access to the upper and middle facial thirds while resulting in an acceptable and concealed scar.<sup>[14]</sup>

Of the various approaches used in the treatment of facial lesions and injuries, the coronal approach, popularized by Tessier, is one of the most versatile of all.<sup>[4]</sup> His work with congenital and posttraumatic reconstructions has adequately demonstrated the safety of this procedure.<sup>[5]</sup>

In our study, the most common complication was damage to the supraorbital nerve. Two cases of supraorbital nerve paraesthesia had return of normal sensation within 6 months and one patient became normal after one year. This correlates with the study by Zhuang *et al.*<sup>[15]</sup> in zygomaticomaxillary complex fracture reduction using bicoronal approach. Two of his patients experienced paraesthesia/anaesthesia in the supraorbital region, two had temporal/parietal region paraesthesia, six patients experienced facial nerve weakness.

A meticulous approach, to release the supraorbital nerve from the bony canal (supraorbital notch) may prevent supraorbital nerve paraesthesia. Damage to the supratrochlear nerve can be avoided by keeping the dissection in the subperiosteal plane on the medial aspect of the orbit. Auriculo-temporal nerve damage can be prevented by limiting the inferior extension of the bicoronal incision till the level of the helix. Damage to the zygomaticotemporal and zygomaticofacial nerve may be unavoidable if wide exposure of the malar bone is required.<sup>[8]</sup>

In our study, only one patient had frontalis muscle weakness that got resolved in 6 months. Injury to the temporal branch of the facial nerve can be minimized by modified preauricular approach given by Al-kayat and Bramley. They divided the more superficial of the two layers of temporalis fascia about 1 cm above the zygomatic arch and reflected it forwards with the nerve lying in between it and the bulk of the flap.<sup>[16]</sup>

Severe craniofacial trauma patients frequently have altered consciousness levels that impair sensitivity testing.

**Table 1: Postoperative follow-up schedule**

Postoperative parameters	Follow-up period			
	1 week	1 month	3 months	6 months
Neurosensory disturbances	11 patients	11 patients	11 patients	2 patient
Motor deficit	4 patients	4 patients	4 patients	Nil

**Table 2: Postoperative complications in patients who underwent bicoronal flap procedure**

Complications	Number of patients (%)
Neurosensory disturbances	11 (27.5)
Motor deficit	4 (10)

Furthermore, sensitivity may be altered secondary to trauma, pain, edema, fractures, and comminution of the frontal area. All these features make it difficult to determine if dysaesthesias are related to the trauma or the surgical procedure to raise the flap. The pinprick test used gives a gross estimate of sensitivity alterations as related to pressure and pain, but it is practical and commonly employed in this kind of evaluation.<sup>[13]</sup>

Dunaway and Trott<sup>[4]</sup> have reported 25 cases of a method of exposure of condylar fractures using an extended bicoronal approach combined with myotomy of the masseter muscle. Acceptable reduction and fixation were achieved in all cases with an early return to function. The incidence of complications was low, with three mild temporary facial palsies. The excellent surgical exposure and protection of the facial nerve, combined with cosmetically acceptable scars are the advantages of this technique.<sup>[17]</sup>

Maxillofacial surgeons have used the bicoronal flap for nearly three decades to gain access to the craniofacial skeleton. Krawala, Grime, Stassen, and Perry have done a retrospective analysis of 68 bicoronal flaps done over a 5-year period and have shown that their incidence of permanent morbidity was low. Although 24 patients (35%) experienced some form of sensory abnormality immediately after the operation, this persisted for longer than two years in only one. Complete motor recovery occurred by one year in all 15 patients (22%) who developed postoperative frontalis weakness.<sup>[10]</sup>

In the study by Rajmohan *et al.*, four patients had sensory nerve deficits along the distribution of supraorbital nerve, which completely resolved at the end of six months. In four patients, motor nerve weakness was observed in the immediate postoperative period which gradually improved. However, it persisted even after six months in a patient with the pathology of the temporo-orbital region.<sup>[18]</sup> Mahipathy *et al.*<sup>[19]</sup> in his study on bicoronal flap reported that two patients had sensory deficits which recovered within 2 week postoperatively and two had motor nerve deficits, for one patient it persisted even after 4 months.

Kumar *et al.*<sup>[1]</sup> reported a modified technique of dual plane dissection in one case to avoid temporal branch of the facial nerve. The incision is made in a standard way and is deepened to the level of loose areolar layer between the temporal lines. Furthermore, the incision is deepened to the bone lateral to the temporal lines, and between the temporal lines, the flap is raised in subgaleal plane. Lateral to the temporal lines, the plane of dissection is changed to a subpericranial plane by incising the pericranium in an anteroposterior direction along the temporal lines. Then, the incision is carried anteriorly toward the lateral orbital rim and this results in a dual plane coronal flap. In his study on ten cases, three cases had transient deficit of temporal branch of the facial nerve, two of which recovered within 2<sup>nd</sup> postoperative week and one case of facial nerve palsy which

recovered at the end of the 12<sup>th</sup> postoperative week. These results were comparable with that of our study.

Singh and Dhungel also reported a similar conclusion in their study, with neurosensory disturbances in 28.6% and no permanent neurosensory disturbances after 6 months.<sup>[10]</sup>

To avoid injury to the frontal branch of the facial nerve, care needs to be taken while dissecting along the deep temporal fascia and while elevating the superficial temporal fascia, the dissection is performed in posterior to anterior fashion to dissect along galeotemporal plane and release this galeotemporal fusion point to avoid injury to the frontal branch of the facial nerve.<sup>[20]</sup> However, postoperatively, the frontal branch may have some weakness usually due to traction injury and it will recover over time mostly.

Thus, we concluded that bicoronal flap can be safely used for craniomaxillofacial reconstruction with minimal complications.

## CONCLUSION

We conclude that the bicoronal flap is a good surgical technique to expose the craniomaxillofacial skeleton. This method of exposure has become particularly useful with increased indications for rigid internal fixation and primary bone grafting in the management of complex facial fractures. However, surgical expertise is needed to prevent injury to the nerve and development of postoperative neurosensory and motor deficits.

## Financial support and sponsorship

Nil.

## Conflicts of interest

There are no conflicts of interest.

## REFERENCES

1. Kumar VS, Rao NK, Mohan KR, Krishna L, Prasad BS, Ranganadh N, *et al.* Minimizing complications associated with coronal approach by application of various modifications in surgical technique for treating facial trauma: A prospective study. *Natl J Maxillofac Surg* 2016;7:21-8.
2. Mishra M, Singh G, Singh H, Tewari A. Bicoronal approach in correction of post-traumatic frontal bone deformity: Report of two cases. *Traumaxilla* 2019;1:38-41.
3. Kadakia S, Badhey A, Ashai S, Lee TS, Ducic Y. Alopecia following bicoronal incisions. *JAMA Facial Plast Surg* 2017;19:220-4.
4. Leena L. Versatility of bicoronal flap approach in head and neck surgeries. *Univ J Surg Surg Spec* 2017;3:4.
5. Tessier P. Experiences in the treatment of orbital hypertelorism. *Plast Reconstr Surg* 1974;53:1-8.
6. Nakamura N, Sasaguri M, Okawachi T, Nishihara K, Nozoe E. Secondary correction of bilateral cleft lip nose deformity - Clinical and three-dimensional observations on pre- and postoperative outcome. *J Craniomaxillofac Surg* 2011;39:305-12.
7. Karimi A, Shoohanizad E. The Management of Zygomatic Complex Fractures: A Review. *Journal of Pharmaceutical Research International*. 2019;1-6.
8. Durairaj AR, Jaikrishnan S, Maity P, Natarajan PG, Mahipathy SR, Sundaramurthy N. Hemicoronal with supratemporalis approach for unilateral zygomatic arch fracture: A study of 20 cases. *Int J Sci Res* 2019;8(11):1-3.

9. Leena B, Balasubramanian T. Versatility of bicoronal flap approach in head and neck surgeries. *Online J Otolaryngol* 2011;1:1-11.
10. Singh AK, Dhungel S. Indications and Complications Associated with Coronal Approach to Upper Midface Fracture. *Journal of College of Medical Sciences-Nepal* 2019;15:239-43.
11. Vujcich N, Gebauer D. Current and evolving trends in the management of facial fractures. *Aust Dent J* 2018;63 Suppl 1:S35-47.
12. Shepherd DE, Ward-Booth RP, Moos KF. The morbidity of bicoronal flaps in maxillofacial surgery. *Br J Oral Maxillofac Surg* 1985;23:1-8.
13. Munro IR, Fearon JA. The coronal incision revisited. *Plast Reconstr Surg* 1994;93:185-7.
14. Markowitz BL, Manson PN. Panfacial fractures: Organization of treatment. *Clin Plast Surg* 1989;16:105-14.
15. Zhuang QW, Zhang XP, Wang X, Zhang J, Li ZP, Si YM, *et al.* Coronal approach to zygomaticomaxillary complex fractures. *Eur Rev Med Pharmacol Sci* 2015;19:703-11.
16. Iizuka T, Lindqvist C. Sensory disturbances associated with rigid internal fixation of mandibular fractures. *J Oral Maxillofac Surg* 1991;49:1264-8.
17. Leach P, Rutherford S, Likhith A, Leggate J. Zig-zag bicoronal scalp incision for cranio-facial cases in paediatric neurosurgery. *Childs Nerv Syst* 2004;20:483-4.
18. Rajmohan S, Tauro D, Bagulkar B, Vyas A. Coronal/hemicoronal approach - A gateway to craniomaxillofacial region. *J Clin Diagn Res* 2015;9:PC01-5.
19. Mahipathy SR, Durairaj AR, Sundaramurthy N, Nandy S. Coronal incision: An approach to facial fractures. *Ann Appl Biosci* 2017;4:A89-93.
20. Ali K, Lettieri SC. Management of panfacial fracture. *Semin Plast Surg* 2017;31:108-17.