

DOI: 10.5455/msm.2021.33.78-81

Received: FEB 18 2021; Accepted: MAR 20, 2021

© 2021 Meliha Halilbasic, Amra Nadarevic Vodencarevic, Almira Cosickic, Amir Halilbasic, Arnes Cabric

This is an Open Access article distributed under the terms of the Creative Commons Attribution Non-Commercial License (<http://creativecommons.org/licenses/by-nc/4.0/>) which permits unrestricted non-commercial use, distribution, and reproduction in any medium, provided the original work is properly cited.

CASE REPORT

Mater Sociomed. 2021 Mar; 33(1): 78-81

Adalimumab in Treatment of Uveitis in Pediatric Behcet's Disease—a Case Report

Meliha Halilbasic¹, Amra Nadarevic Vodencarevic¹, Almira Cosickic², Amir Halilbasic², Arnes Cabric³

¹Eye Clinic, University Clinical Center Tuzla, Bosnia and Herzegovina

²Clinic for Children's Diseases, University Clinical Center Tuzla, Bosnia and Herzegovina

³Public Institution, Polyclinic with a day care hospital Doboj-Jug, Bosnia and Herzegovina

Corresponding author: Meliha Halilbasic, Ass. Prof. MD, PhD. Eye Clinic University Clinical Center Tuzla, Prof. I. Pasica b.b, Tuzla, Bosnia and Herzegovina, E mail: meliha.halilbasic@gmail.com. ORCID ID: <https://www.orcid.org/000-0002-4702-817X>.

ABSTRACT

Introduction: Behcet's Disease (BD) is an inflammatory disease characterized by multisystemic involvement and featured by a chronic, relapsing disease course. Recurrent ocular inflammation and macular involvement may lead to severe loss of visual acuity. Prolonged use of local and systemic corticosteroids lead to numerous side effects and complications. Very often other immunosuppressive therapies are needed. Biologic agents are promising for the treatment of Behcet's disease-associated uveitis. **Aim:** To report successful treatment of paediatric uveitis due to incomplete Behcet's disease with administration of adalimumab, after failing to react to all other modalities of treatment. **Case report:** We present the case of a 15-year-old girl who was treated for recurrent uveitis in both eyes with developed complications on anterior and posterior ocular segment. She was earlier treated with topical and systemic steroids for uveitis, laser photocoagulation and methotrexate, however, relapses occurred inspite all treatment modalities. Patient was diagnosed with incomplete Behcet's disease, and adalimumab therapy was initiated. Inflammation was well-controlled by adalimumab administration without need for local or systemic corticosteroids. **Conclusion:** Adalimumab is effective for treating children with Behcet's disease-associated uveitis. Control of ocular inflammation in our case was achieved without need for continuing local or systemic corticosteroids, thus preventing further complications and possible significant vision loss. **Keywords:** Behcet's disease, ophthalmology, adalimumab, pediatric uveitis.

1. INTRODUCTION

Behcet's Disease (BD) is an inflammatory disease of unknown etiology characterized by multisystemic involvement and featured by a chronic, relapsing disease course. Pathohistological it is vasculitis affecting small and large vessels and veins are predominantly affected (1, 2). The most common clinical manifestations of BD are recurrent oral ulcerations (ROU), genital ulcerations (GU) and ocular inflammation, but also neurological, gastrointestinal and articular involvement are reported with considerable frequency (3). The term pediatric BD (PEDBD) is used for cases diagnosed during childhood, whereas the term juvenile BD is used for those cases who have manifestations of the disease before the age of 16 years, but the diagnosis is made during adulthood (4). The epidemiological BD has a high prevalence among countries identifying the old "Silk Road", a wide area between the Mediterranean countries and the eastern Asia (5). The etiology of BD is still unknown; however, it appears to be a complex disease relying on an interaction between the genetic background and the environment. The most important genetic predisposition factor associated with BD is human leukocyte antigen (HLA) B5 and its sub-allele HLA-B51 (6, 7). Behcet's disease is rarely observed in children or patients above the age of 50. The disease starts in childhood in 4–26% of cases with the mean age of onset between 10 and 12 years (8, 9). Since it is quite rare in pediatric population and clinical picture is frequently incomplete, latency between the disease onset and the setting up right diagnosis and therefore right treatment of BD in children and adolescents is

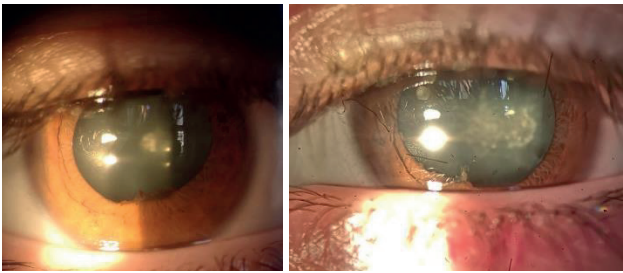


Figure 1. Slit lamp image of right and left eye, with posterior synechiae and posterior cortical cataracts

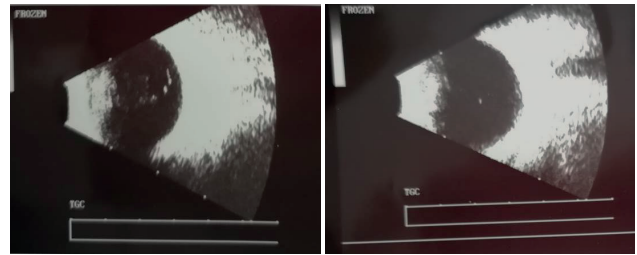


Figure 2. Ultrasound of right and left eye with vitreous inflammatory reaction

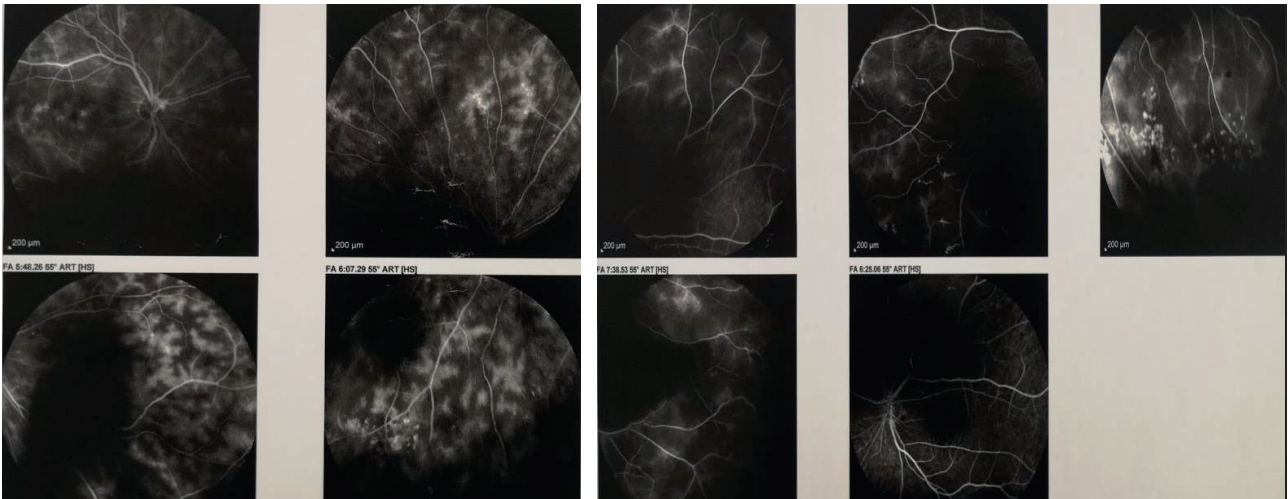


Figure 3. Fluorescein angiography of right and left eye

a difficult clinical challenge (10). Usually ocular involvement occurs 2–4 years after disease onset, but in 10–20% of patients it represents the initial manifestation (9, 11). Severe vision loss due to ocular involvement is seen in 25% of cases (12). Repeated episodes of posterior-segment inflammation can result in end-stage ocular BD characterized by blindness with a clinical picture of optic atrophy, vascular attenuation, and diffuse retinal atrophy (13, 14). Thanks to new therapeutic strategies the prognosis of eye involvement has improved in recent years (15). Recently recommendations for the treatment of pediatric BD have been updated and allowed a considerable improvement of the therapeutic strategies. In particular, the use of anti-TNF α drugs as a second-line option for refractory BD, and as a first-line treatment in severe ocular and neurological involvement, has demonstrated to be effective in improving the outcome of BD patients (10).

2. AIM

We report successful treatment of pediatric uveitis due to incomplete Behçet's disease with administration of adalimumab, after failing to react to all other modalities of treatment.

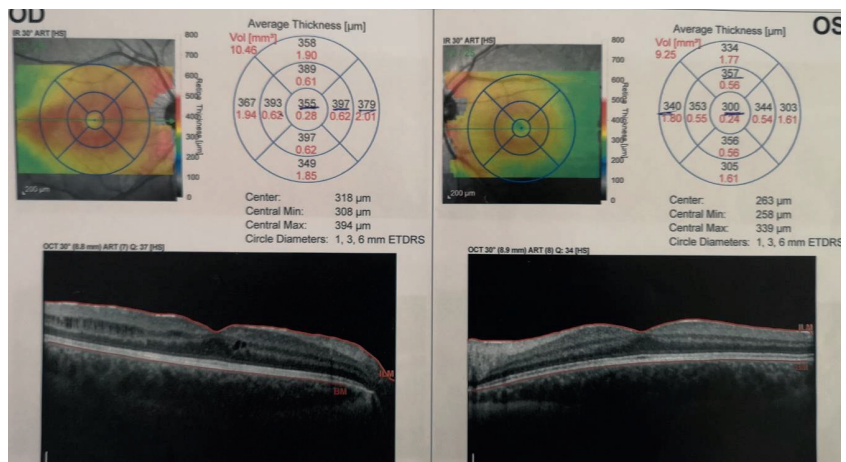


Figure 4. SD OCT showing intraretinal cysts, more on right eye

3. CASE REPORT

A 15-year-old female patient was referred to us for evaluation of uveitis treated in other clinics before. Child reported first symptoms 5 years ago, which consisted of blurry vision in right eye first then left eye and redness of eyes. She had oral aphtae and oral ulcers as well, that improved over time with treatment. She was treated earlier for right sided knee inflammation. She has been diagnosed with uveitis and for 5 years treated with on and off topical, peribulbar and systemic corticosteroids with periods of improvement and periods of worsening of symptoms. She developed cataract in both eyes and was planned for surgery two years ago, but parents refused surgical intervention. Two years prior to referral to our clinic she had

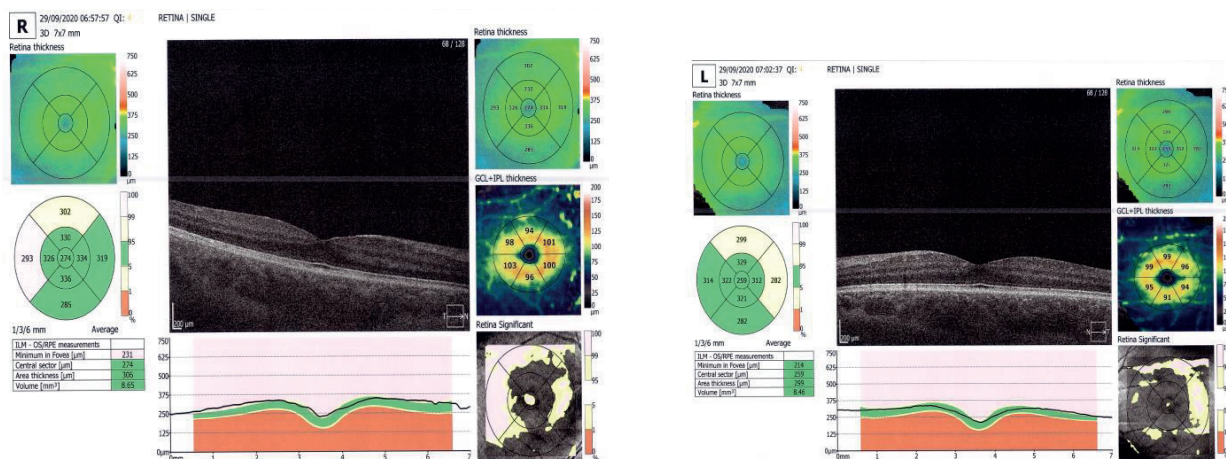


Figure 5. SD OCT after 12 months with adalimumab

laser photocoagulation in both eyes due to retinal vasculitis and was started on Methotrexat 15 mg weekly. Despite the administration of local and systemic corticosteroids and MTX, inflammation persisted; therefore, the patient was referred to our clinic for second opinion.

The best corrected visual acuity (BCVA) was 0.9 in RE and 0.6 in LE, and the IOPs of the right and left eye were 17 and 18 mmHg, respectively. Anterior chamber cell grade of 0.5+ in the both eyes. She had posterior synechiae in both eyes and posterior cortical cataract in both eyes (Figure 1). The vitreous cell grade was 3+ in the right eye and 2+ in the left eye. On ultrasound she had inflammatory reaction in vitreous, more prominent in right eye (Figure 2). Posterior segment was hazy due to vitreal changes and cataract, but laser burns could be seen as well as signs of vasculitis and macular changes. We performed fluorescein angiography and SD OCT on patient to reveal intraretinal cysts on both eyes and perifoveolar oedema right eye (Figure 3 and 4).

Non-ocular manifestations oral ulcers were improved with previous treatment. Skin or genital lesions were not observed. She was referred to pediatric rheumatologist for complete evaluation. All laboratory workup was within normal limits. Chest X ray and abdominal ultrasound were normal. Interferon-gamma release assay and Quanti Feron Tb gold test for tuberculosis infection and Treponema pallidum antibody hemagglutination test for syphilis were negative; Hepatitis HBs and anti HBc were negative as well as HCV Ag; angiotensin-converting enzyme, antinuclear antibody, and anti-citrullinated protein antibody levels were within the normal range. MRI of brain and cervical spine were normal, as well as EEG. Neurological examination was normal. She tested positive for HLA-B51. There was no family history of autoimmune diseases. Following treatment, initiated in the previous clinic, was continued: 0.1% dexamethasone eye drops (four times/day), tropicamide/phenylephrine eye drops (once/day), Methotrexat (MTX) 15 mg once a week followed by folic acid. The patient was diagnosed with the incomplete type of Behçet's disease on the basis of the presence of a typical ocular symptoms and recurrent oral ulcers, retinal vasculitis recurred in both eyes in spite of treatment with MTX, therefore, initiation of adalimumab was proposed. Subcutaneous adalimumab injection was then introduced. The patient was 15-year-

old and weighed 57 kg when adalimumab was initiated, thus we administered 40 mg every 2 weeks. After 2 months BCVA improved in both eyes, to 1.0 RE and 0.7 LE. The anterior chamber in both eyes improved to 0, within 2 months after beginning adalimumab administration. Posterior synechiae and cataract did not change. Oral ulcers and problems with knee did not repeat after adalimumab therapy. The inflammation subsided. After three months she was taken off local medication. On the first follow up SD OCT showed significant improvement (Figure 5) as well as after 18 months.

After 12 months with adalimumab we decided to lower MTX dosage to 10 mg once per week and she remained symptoms free with this lower dose. The follow-up period after introduction of adalimumab was 18 months (at the time this report was written) and the patient did not experience any side effects. Her ocular and oral symptoms of BD were well controlled.

4. DISCUSSION

Behçet's disease is a rare entity in pediatric population and diagnosis is challenging due to the long time interval between disease onset and the development of a clinical picture compatible with the BD diagnostic criteria (10). In our case child had symptoms of ocular involvement as well as oral aphthae and arthralgia for five years before diagnosis of incomplete BD was established. Very often not all symptoms are present at once and that makes clinical diagnosis even harder, particularly because the spectrum of the differential diagnosis is extremely wide (10). Hopefully, introduction and adoption of diagnostic criteria for BD in pediatric age will help to improve the diagnostic sensibility and delay in diagnostics, as in our case (17).

Although corticosteroids, local and systemic, represent first line of treatment, they are not recommended for prolonged use in children due to side effects. The recommendation for the treatment of pediatric BD has been recently updated. In particular, the use of anti-TNF α drugs as a second-line option for refractory BD, and as a first-line treatment in severe ocular and neurological involvement, has demonstrated to be effective in improving the outcome of BD patients (10, 18). In our case child developed cataracts due to long use of corticosteroids. Introduction of

MTX helped control inflammation and prevent development of severe posterior segment complications, although did not completely stop inflammatory process. It was important that adalimumab, although late, was introduced before repeated inflammation caused irreversible structural and functional changes. Increased risks of serious infections, lymphoma, or other cancers as side effects of TNF- α antagonist have been described. This child did not have any side effects but we will continue to follow her.

5. CONCLUSION

Adalimumab is effective for treating children with Behçet's disease-associated uveitis, even when all other modalities failed to control inflammation. The use of anti TNF α treatment has to become a standard for severe ocular, neurological and digestive involvement. We should not wait for severe ocular complications before introduction of biological agents for children with ocular manifestation of BD.

List of abbreviations: BD-Behçet's Disease, ROU-Recurrent oral ulcerations, GU- genital ulcerations, PEDBD-pediatric BD, HLA-human leukocyte antigen, BCVA-best corrected visual acuity, RE-right eye, LE-left eye, IOP-intraocular pressure, SD OCT-spectral domain ocular coherent tomography, MTX-Methotrexat.

- **Patient Consent Form:** Consent of patient's parents was obtained for publication of data, although there are no images in this case studies to reveal patient information.
- **Author's contributions:** MH and AC analyzed and interpreted the patient data regarding laboratory results, ordered and obtained necessary diagnostic examinations, followed and examined patient. MH, ANV, AC, AH and AC are major contributors in writing the manuscript. All authors read and approved the final manuscript.
- **Conflict of interest:** There are no conflicts of interest.
- **Financial support and sponsorship:** Nil.

REFERENCES

1. Yıldız M, Köker O, Adrovic A, Şahin S, Barut K, Kasapçopur Ö. Pediatric Behçet's disease—clinical aspects and current concepts. *Eur J Rheumatol*. 2019; 7(Suppl 1): 1-10. doi:10.5152/eurjrheum.2019.19121.
2. Tong B, Liu X, Xiao J, Su G. Immunopathogenesis of Behçet's disease. *Front Immunol*. 2019; 10:665. doi:10.3389/fimmu.2019.00665.
3. Greco A, De Virgilio A, Ralli M, et al. Behçet's disease: new insights into pathophysiology, clinical features and treatment options. *Autoimmun Rev*. 2018; 17(6): 567-575. doi:10.1016/j.autrev.2017.12.006.
4. Kone-Paut I, Yurdakul S, Bahabri SA, Shafae N, Ozen S, Ozdogan H, et al. Clinical features of Behçet's disease in children: An international collaborative study of 86 cases. *J Pediatr*. 1998; 132: 721–725. doi: 10.1016/S0022-3476(98)70368-3.
5. Verity DH, Marr JE, Ohno S, Wallace GR, Stanford MR. Behçet's disease, the Silk Road and HLA-B51: Historical and geographical perspectives. *Tissue Antigens*. 1999; 54 doi: 10.1034/j.1399-0039.1999.540301.x.
6. De Menthon M, LaValley MP, Maldini C, Guillevin L, Mahr A. HLA-B51/B5 and the risk of Behçet's disease: A systematic review and meta-analysis of case-control genetic association studies. *Arthritis Care Res*. 2009; 61: 1287–1296. doi: 10.1002/art.24642.
7. Yazici H, Seyahi E, Hatemi G, Yazici Y. Behçet syndrome: A contemporary view. *Nat Rev Rheumatol*. 2018; 14: 107–119. doi: 10.1038/nrrheum.2018.3.
8. Davatchi F, Shahram F, Chams-Davatchi C, Shams H, Nadji A, Akhlaghi M, et al. Behçet's disease in Iran: analysis of 6500 cases. *Int J Rheum Dis*. 2010; 13: 367-373. doi: 10.1111/j.1756-185X.2010.01549.x.
9. Atmaca L, Boyvat A, Yalçındağ FN, Atmaca-Sonmez P, Gurler A. Behçet disease in children. *Ocul Immunol Inflamm*. 2011; 19(2): 103-107. doi: 10.3109/09273948.2011.555592.
10. Costagliola G, Cappelli S, Consolini R. Behçet's Disease in Children: Diagnostic and Management Challenges. *Ther Clin Risk Manag*. 2020; 16: 495-507. Published 2020 Jun 11. doi:10.2147/TCRM.S232660
11. Kone-Paut I, Shahram F, Darce-Bello M, et al. Consensus classification criteria for pediatric Behçet's disease from a prospective observational cohort: PEDBD. *Ann Rheum Dis*. 2016; 75(6): 958–964. doi:10.1136/annrheumdis-2015-208491.
12. Hazleman BL. Rheumatic disorders of the eye and the various structures involved. *Br J Rheumatol*. 1996; 35(3): 258-268. doi:10.1093/rheumatology/35.3.258.
13. Kone-Paut I. Behçet's disease in children, an overview. *Pediatr Rheumatol Online J*. 2016; 14(1): 10. doi:10.1186/s12969-016-0070-z.
14. Reiff A, Kadayifcilar S, Ozen S. Rheumatic inflammatory eye diseases of childhood. *Rheum Dis Clin North Am*. 2013; 39(4): 801-832. doi:10.1016/j.rdc.2013.05.005.
15. Accorinti M, Pesci FR, Pirraglia MP, Abicca I, Pivetti-Pezzi P. Ocular Behçet's disease: changing patterns over time, complications and long-term visual prognosis. *Ocul Immunol Inflamm*. 2017; 25(1): 29-36. doi:10.3109/09273948.2015.1094095.
16. Poddighe D, Mukusheva Z, Dauyey K, Assylbekova M. Adalimumab in the treatment of pediatric Behçet's disease: case-based review. *Rheumatol Int*. 2019 Jun; 39(6): 1107-1112. doi: 10.1007/s00296-019-04300-0.
17. Kone-Paut I, Shahram F, Darce-Bello M, et al. Consensus classification criteria for pediatric Behçet's disease from a prospective observational cohort: PEDBD. *Ann Rheum Dis*. 2016; 75(6): 958–964. doi:10.1136/annrheumdis-2015-208491.
18. Hiyama, T., Harada, Y., Doi, T. et al. Early administration of adalimumab for pediatric uveitis due to Behçet's disease. *Pediatr Rheumatol*. 2019; 17: 29. <https://doi.org/10.1186/s12969-019-0333-6>.