



Novel Management of Rhinophyma by Patterned Ablative 2940nm Erbium:YAG Laser

This article was published in the following Dove Press journal:
Clinical, Cosmetic and Investigational Dermatology

Ashraf Badawi ^{1,2}
Mai Osman¹
Ahmed Kassab ¹

¹Department of Medical Laser Applications, National Institute of Laser Enhanced Sciences, Cairo University, Giza, Egypt; ²Department of Dermatology and Allergology, Faculty of Medicine, University of Szeged, Szeged, Hungary

Introduction: Rhinophyma is a cosmetic disorder that causes emotional distress if the symptoms are extensive or obvious enough. Treatment options range from topical antibiotics or isotretinoin, surgical resection, cryosurgery, electrocautery, dermabrasion and more recently laser therapy. With the limitations of surgical techniques, lasers gained popularity for treating rhinophyma. However, laser ablation is invasive and can lead to side effects and prolonged downtime. Fractional photothermolysis (FP) was introduced to overcome the limitations posed by conventional ablative lasers. To the best of our knowledge, there are no previous studies to evaluate the use of Er:YAG in an ablative mode with a fractional handpiece for the treatment of rhinophyma.

Aim of the Work: The goal of this study was to evaluate the efficacy and safety of fractional ablative 2940 nm Er:YAG laser for the treatment of mild to moderate rhinophyma.

Patients and Methods: Sixteen patients having mild to moderate rhinophyma were treated with fractional ablative 2940 nm Er:YAG laser. All patients received 4 laser treatments and were followed up over the following 3 months. An additional follow-up appointment 6 months after the last session was arranged to detect any signs of recurrence.

Outcome Measures: Patient questionnaire was used to evaluate patient subjective satisfaction. Objective evaluation was performed by a blind assessment of clinical photographs that were taken before and 3 months after the final treatment by two independent blinded evaluators.

Results: Patient questionnaire taken 3 months after last treatment revealed that 8 patients (50%) were “very satisfied”, 4 patients (25%) were satisfied, and 4 patients (25%) were somewhat satisfied. None of the patients assessed their results as not satisfying.

Conclusion: In conclusion, the use of patterned ablative Er:YAG laser with a PS01 handpiece and parameters used in this study comprise an effective tool for treatment of mild to moderate rhinophyma with rapid postoperative recovery compared with conventional surgical procedures and other ablative lasers.

Keywords: rhinophyma, fractional lasers, ablative lasers, Er:YAG laser

Introduction

Rhinophyma was first recognized in ancient Greece and Arabia. In 1845, Von Hebra coined the word Rhinophyma.¹ He derived this word from the Greek word “rhis” meaning nose and “phyma” meaning growth.¹ Rhinophyma is a slowly progressive, benign, disfiguring disorder of the nose which presents the end stage of acne rosacea. The clinical presentation includes an enlargement and hypervascularization of the lower two-thirds of the nose; in addition, a reddish purple discoloration develops, and the nose takes on a lobular, nodular appearance.^{2,3} The most severe cases can affect breathing, vision and even food intake. Factors implicated in the

Correspondence: Ashraf Badawi
2147 Mayflower Boulevard, Oakville,
Ontario L6H4E6, Canada
Email ashrafbadawi@hotmail.com

worsening of rosacea and ultimately in the formation of rhinophyma have included *Demodex folliculorum*, alcohol, caffeine, spicy foods, and other vasodilatory agents.⁴⁻⁷ Histopathologically, there is a chronic inflammatory process with hypertrophy of the subcutaneous and sebaceous tissues; the dilated ducts become occluded with inspissated debris, bacteria, and sebum.⁸ Because rhinophyma is a cosmetic disorder, it is expected to cause emotional distress if the symptoms are extensive or obvious enough. Patients seek medical aid to improve the shape of their disfigured noses.⁹ Treatment options range from topical antibiotics or isotretinoin (reserved for mild disease), surgical resection with or without subsequent skin graft, cryosurgery, electrocautery, dermabrasion and more recently laser therapy.¹⁰ With the limitations of surgical techniques, lasers gained popularity for treating rhinophyma. However, laser ablation using conventional carbon dioxide (CO₂) and erbium yttrium aluminum garnet (Er:YAG) lasers are invasive and can lead to serious side effects and prolonged downtime.^{11,12} Fractional photothermolysis (FP) was introduced in an attempt to overcome the limitations posed by conventional ablative lasers. The fractionated lasers heat the tissue in columns called microscopic treatment zones (MTZs). These surrounding areas of unaffected tissue act as reservoirs for healing, enabling the MTZs to resolve quickly with minimal discomfort by providing a reservoir for keratinocyte migration.¹³

To the best of our knowledge, there are no previous studies to evaluate the use of Er:YAG in an ablative mode with a fractional handpiece for the treatment of rhinophyma.

Aim of the Work

The goal of this study was to evaluate the efficacy and safety of fractional ablative 2940 nm Er:YAG laser for the treatment of mild to moderate rhinophyma.

Patients and Methods

The study was conducted from April 2016 to April 2018. Sixteen patients (10 males and 6 females), aged 45–71 years (mean 57.75 years) with Fitzpatrick skin phototypes III to IV having mild to moderate rhinophyma were treated with fractional ablative 2940-nm Er:YAG laser. The diagnosis of rhinophyma was made clinically and the severity of the nasal deformity was assessed using the grading system advised by El-Azhary and colleagues.¹⁰ The duration of rhinophyma ranged from 2 to 15 years (mean 6.5 years).

All patients had been receiving medical treatment for acne rosacea for several years before the procedure, and the rosacea was inactive at the time of laser therapy. This study was conducted in the outpatient clinic at the National Institute of Laser Enhanced Sciences, Cairo University. Before and after photos were taken for the patients. Informed consent was obtained from all the patients before the procedure, and they gave written and signed permission to use all data and photographs for scientific aims. Exclusion criteria included any form of treatment for the rhinophyma within the previous year, patients of photosensitivity inducing medications, patients on blood thinners, patients who have any suspicious lesions on the face or with a history of skin malignancy, patients on chemotherapy or isotretinoin. Pregnant female patients were excluded as well. This clinical study was conducted in accordance with the Helsinki Declaration of 1975 and was approved by the ethical committee of the national laser institute board, registration number Cu – NILES/37/20.

Technique

The treatment area on the nose was cleansed/sterilized with Betadine and moist towels were draped over the entire nose while the area to be treated was marked. Patients were anaesthetized topically with 5% lidocaine cream which was applied under occlusion for 60 minutes to reduce pain or discomfort during the procedure. All appropriate laser precautions were taken prior to starting treatment. Protective eyewear was worn by the patient and all present in the room throughout the treatment.

Patients were advised to avoid tanning, heavy sun exposure and deep facial peel procedures for 4 weeks prior to treatment. In our study we used an Er:YAG laser (Fotona XS Dynamis, Slovenia) with a 7 mm spot size PS01 handpiece which is a pixilated handpiece that produces a pattern of multiple 1 to 1.5 mm ablation holes in the tissues. The parameters applied yielded around 0.7 J/cm² and they were as follows: energy 250 to 300 mJ, with 5 µm ablation depth, MTZ density level of 2 to 3, short pulse (SP) duration mode, and frequency 6 to 8 Hz. The Er:YAG laser which allows tissue vaporization, was used with a back-and-forth motion on the diseased tissue. The fractional resurfacing was continued in the prominent sebaceous areas with multiple passes that were stopped on the appearance of pinpoint bleeding while the less sebaceous areas of the nose were treated with fewer passes. A smoke evacuator was used throughout the procedure. No forced air cooling was used.

At the end of the treatment, an occlusive dressing with antibiotic and Vaseline ointment was placed on the treated area. Patients were given wound care instructions, including daily application of an antibiotic cream (fusidic acid) for the first week after treatment and a broad-spectrum sunscreen until re-epithelization was complete. The patients did not require additional medications for pain management. All patients received 4 laser treatments with 4-week intervals between the sessions and were followed up over the next 3 months. An additional follow-up appointment at 3 months (6 months after the last session) was arranged to detect any signs of recurrence.

Outcome Measures

Improvement of the patients was assessed both subjectively and objectively. Patient questionnaire was used to evaluate patient subjective satisfaction. We used a 4-point scale (0-not satisfied, 1-somewhat satisfied, 2-satisfied, 3-very satisfied). Objective evaluation was performed by a blind assessment of clinical photographs that were taken before and 3 months after the final treatment by two independent blinded evaluators where the photos of the patients were given in random order. The evaluators had to first assign correct order (before/after) and secondly rate the improvement on a 5-point Global Aesthetic Improvement Scale (GAIS: 0-worse, 1-no change, 2-improved, 3-much improved, 4-very much improved).

Also, the duration of the downtime was recorded in all cases and any side effects observed were recorded at each treatment session and during the follow-up period (3 months after the last session).

Statistical Analysis

Quantitative data were expressed as means and standard deviations, while Qualitative data were expressed as frequencies and percentages.

Results

A total of 16 patients with a mean age of 57.8 years (range: 45–71 years) were included in this study. Based on the clinical classification by el-Azhary et al¹⁰ 8 patients had mild and 8 had moderate rhinophyma (Table 1).

Patient questionnaire taken 3 months after last treatment revealed that 8 patients (50%) achieved a “very satisfied” result, 4 patients (25%) were satisfied and 4 patients (25%) were somewhat satisfied. None of the patients assessed their results as not satisfying (Table 2).

Table 1 Patient Characteristics

Age; mean, (range) [years]	57.8 (45–71)
Sex, n (%)	
Female	6 (37.5%)
Male	10 (62.5%)
Fitzpatrick skin phototype, n (%)	
III	12 (75%)
IV	4 (25%)
Rhinophyma severity, n (%)	
Mild	8 (50%)
Moderate	8 (50%)
Duration of rhinophyma; mean (range) [years]	6.5 (2–15)

All the 2 blinded evaluators were able to identify the before and after photographs of all the patients correctly.

The first blinded evaluator rated the changes on the patients' photos as follows: 4 patients (25%) very much improved, 8 patients (50%) much improved, 4 patients (25%) improved and none of the patients showed no change or worsening.

Table 2 Data Summary of Treatment Outcome; Objective Evaluation by Blinded Physicians, Subjective Evaluation (Patient Satisfaction) and Duration of Reepithelization (N=16)

Objective Evaluation (GAIS)	
(Cosmetic result) (n, %) Evaluator 1	
Very much improved	4 (25%)
Much improved	8 (50%)
Improved	4 (25%)
No change	0
Worse	0
(Cosmetic result) (n, %) Evaluator 2	
Very much improved	4 (25%)
Much improved	9 (56.25%)
Improved	3 (18.75%)
No change	0
Worse	0
Subjective Evaluation	
(Patient satisfaction) (n, %)	
Very satisfied	8 (50%)
Satisfied	4 (25%)
Somewhat satisfied	4 (25%)
Not satisfied	0
Re-epithelialization (downtime)	
Mean (range) [days]	3.7 (2–5)
Recurrence (n, %)	1 (6.25%)

The second blinded evaluator rated the changes on the patients' photos as follows: 4 patients (25%) very much improved, 9 patients (56.25%) much improved, 3 patients (18.75%) improved and none of the patients showed no change or worsening (Table 2).

Figure 1 shows one of the patients before the treatment and 3 months after the last laser session with high patient satisfaction and significant improvement.

Re-epithelization (downtime) took an average of 3.7 days (2–5 days). Figure 2 shows a female patient with mild rhinophyma immediately after the laser session where there is minimal skin charring. All patients tolerated the treatment well under topical anaesthesia alone. In all patients, side effects were mild to moderate and consisted of erythema, crusting, and swelling that lasted for a few days. No persistent side effects such as hyper- or hypopigmentation or scarring were observed in any of the treated patients at follow-up (Figure 1).

Only one patient experienced a recurrence of the condition in the 6-month follow-up period (Table 2).

Discussion

Rhinophyma can be a social stigma that prompts patients to seek treatment for this cosmetic problem. It also causes functional problems including nasal obstruction. Rhinophyma remains a troublesome condition for which no single effective treatment exists.¹⁴

The CO₂ laser was first reported in 1980 for the treatment of rhinophyma.¹² In recent years, Er:YAG lasers have been increasingly reported in the literature.^{15–17} The Er:YAG laser is a solid-state laser that emits a wavelength of 2940 nm in the mid-infrared region. It has the highest absorption in water which makes the Er:YAG an effective soft tissue ablative surgical device. It offers an excellent solution for careful

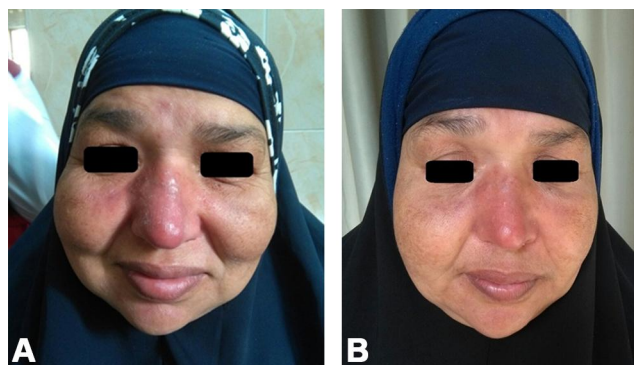

Figure 1 Female patient (A) before the treatment and (B) 3 months after the last laser treatment.

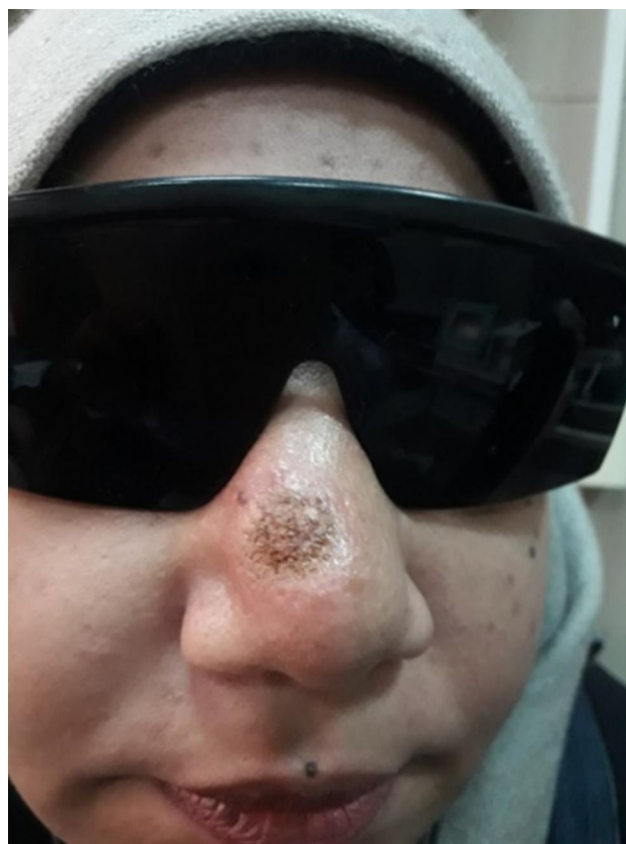

Figure 2 Female patient with mild rhinophyma showing the impact of the laser on the skin lesion and how the skin looks immediately after the session.

ablative removal of superficial layers with minimal damage to the adjacent tissues. Er:YAG laser absorption in water is tenfold higher than that of the CO₂ laser. Thus, the heat produced by the absorption of the Er:YAG is efficiently used for tissue ablation, with very little heat conduction to surrounding tissue. The CO₂ laser, with its higher heat conduction, will cause deep thermal damage to the surrounding tissue resulting in longer healing time and higher incidence of complications compared to Er:YAG laser.^{18,19}

Hantash et al²⁰ first published results with an ablative fractional CO₂ laser resurfacing device in 2007. The delivery of energy in columns with surrounding zones of uninjured tissue promotes rapid wound healing and collagen induction resulting in contraction and tightening of the tissue.^{13,21} There is a decreased risk of scarring and shorter downtime than seen with traditional ablative treatments, as the uninjured skin allows for faster re-epithelialization. This might interpret the absence of post-operative complications in the present study.

This study provides further evidence of the effectiveness of the fractional ablative resurfacing for treatment of

rhinophyma and is the first study, to our knowledge, to demonstrate the efficacy of ablative Er:YAG laser in the treatment of rhinophyma while using a pixilated “PS01” handpiece. Here we present sixteen cases of mild to moderate rhinophyma that were successfully treated with fractional Er:YAG 2940 nm laser.

Smaller proportion of female patients with rhinophyma in our study (6 women and 10 men) is consistent with the results published by several authors.^{22,23} Compared to men, women had less severe disease and presented earlier for treatment. Also, the age distribution of this study is comparable to those reported in previous studies.^{24–26}

Overall, the outcome with this technique was excellent to very good in 75% of the treated cases at a 3-month follow-up. Most of the patients stated that they were very satisfied or satisfied with the cosmetic result. These findings are consistent with those of Serwoka et al,²⁷ who treated 5 patients with longstanding history of mild to moderate rhinophyma with a series of fractional ablative CO₂ laser treatments. They noted significant improvement and reduction in the rhinophyma without the typical scarring noted with most other treatments.

Similarly, Meesters et al²⁸ conducted a study on three patients with mild rhinophyma who were treated with a fractionated carbon dioxide (CO₂) laser. Two patients experienced significant improvement, whereas one patient showed little response.

We observed in our current study that the blinded evaluators gave a different score for the before and after patients than the data obtained by the patient satisfaction scale. Whereas the 2 blinded evaluators evaluated only 4 patients (25%) as showing very good improvement, the patient satisfaction score showed that 8 patients (50%) are very satisfied. This could be explained by the fact that with a chronic long-lasting disease like the rhinophyma which is causing so much distress to the patient, even mild improvement of the appearance of the skin lesion might be satisfactory for them, especially if the treatment is associated with short downtime, minimal discomfort and no complications.

Orenstein et al²⁹ reported marked cosmetic improvement in 6 patients with moderate to severe rhinophyma after a single ablative Er:YAG laser treatment with no complications. However, the post-operative healing time was seven to fourteen days, significantly longer than that in our study. Ablative lasers work by creating homogenous thermal damage at a specified depth within the skin.¹² These lasers have generally fallen out of favour due to

their unfavourable side effect profile, which limits its usefulness due to prolonged healing time which is often inconvenient for patients, especially those with only mild disease.¹³

Using the novel patterned fractionated Er:Yag handpiece in our study is believed to be responsible for the shorter downtime associated with the full field ablation reported in previous studies.

It should be noted that the variation in the parameters used and in the number of passes applied for different aspects of the nose in the current study with this novel patterned handpiece, created a more natural result as it can be feathered at the edges of the treatment resulting in a blended natural appearance.

Optimal cosmetic results can be achieved by careful removal of hyperplastic sebaceous tissue with preservation of the deepest portion of adnexal structures to guarantee scar-free re-epithelialization. For this reason, recurrence of rhinophyma is a well-known phenomenon, particularly when hyperplastic tissue is not removed completely.³⁰

In the present study, one case of recurrence was observed after 6 months of the last laser session and this is considered an excellent recurrence rate compared to all the studies published keeping into consideration the significant less downtime and incidence of complications associated with our novel method and parameters.

In 2019, Mathis and Ibrahim³¹ treated 11 male patients with the full ablative Er:Yag laser and followed up the patients for 30 days only, so there was no report about the recurrence. A major differentiation point between our current study and that of Mathis and Ibrahim³¹ is the downtime as in our study, the Re-epithelization (downtime) took an average of 3.7 days (2–5 days) compared with the reported 13 days to achieve full re-epithelization with the full ablation method utilized in their study. This significant reduction in the downtime is highly appreciated by both patients and physicians and is attributed to the novel delivery method utilized in our study.

Limitations in this study might include the lack of histopathological examination to rule out the presence of a coexistent pathology and to demonstrate the histopathological improvement of the treated tissue. It would have been also helpful to have a longer follow-up period to evaluate the recurrence rate after a year of the last laser session.

Finally, it is worth mentioning that the beneficial effects of Erbium:YAG laser treatment with this novel

patterned fractional handpiece were not limited to the cosmetic outcome only as most patients reported improved confidence and well-being and attended the return consultation with apparently higher self-esteem.

Conclusion

In conclusion, the use of patterned ablative Er:YAG laser with a PS01 handpiece and parameters used in this study comprise an effective tool for treatment of mild to moderate rhinophyma with a pain-free rapid postoperative recovery and an excellent safety profile compared with conventional surgical procedures and other ablative lasers. However, it may not be the ideal resurfacing tool for severe rhinophyma or patients with bulky lesions. Further research is needed in order to confirm these preliminary findings and to optimize laser settings and number of treatment sessions. Besides, as public demand grows for less invasive modalities to treat common cosmetic skin concerns, dermatologic surgeons must continue to explore new treatment options.

Ethics and Consent

All procedures performed in studies involving human participants were in accordance with the ethical standards of the institutional and/or national research committee and with the 1964 Helsinki declaration and its later amendments or comparable ethical standards.

Informed consent was obtained from all individual participants included in the study.

Funding

The authors declare that there was no funding from any party or anyone or funding agencies.

Disclosure

The authors declare that they have no conflicts of interest.

References

- Roberts JO, Ward CM. Rhinophyma. *J R Soc Med.* 1985;78(8):678–681. doi:10.1177/014107688507800819
- Nelson B, Fuciarelli K. Surgical management of rhinophyma. *Cutis.* 1998;61(6):313–316.
- Hoasjoe DK, Stucker FJ. Rhinophyma: review of pathophysiology and treatment. *J Otolaryngol.* 1995;24(1):51–56.
- Wiemer DR. Rhinophyma. *Clin Plast Surg.* 1987;14(2):357–365. doi:10.1016/S0094-1298(20)30606-4
- Dotz W, Berliner N. Rhinophyma. A master's depiction, a patron's affliction. *Am J Dermatopathol.* 1984;6(3):231–235. doi:10.1097/0000372-198406030-00006
- Rohrich RJ, Griffin JR, Adams WP Jr. Rhinophyma: review and update. *Plast Reconstr Surg.* 2002;110(3):860–869; quiz 870. doi:10.1097/01.PRS.0000019919.70133.BF
- Ayers S Jr and Mihan R. Demodex folliculorum in rosacea. *Arch Dermatol.* 1970;101(6):706–707. doi:10.1001/archderm.101.6.706
- Arikan OK, Muluk NB, Cirpar O. Treatment of rhinophyma with radiofrequency: a case report. *B-ENT.* 2010;6(3):209–213.
- Simo R, Sharma VL. Treatment of rhinophyma with carbon dioxide laser. *J Laryngol Otol.* 1996;110:841–846. doi:10.1017/S0022215100135121
- El-Azhary RA, Roenigk RK, Wang TD. Spectrum of results after treatment of rhinophyma with the carbon dioxide laser. *Mayo Clin Proc.* 1991;66:899–905. doi:10.1016/S0025-6196(12)61576-6
- Sadick H, Goepel B, Bersch C, Goessler U, Hoermann K, Rhinophyma: RF. Diagnosis and treatment options for a disfiguring tumor of the nose. *Ann Plast Surg.* 2008;61:114–120.
- Shapshay SM, Strong MS, Anastasi GW, Vaughan CW. Removal of rhinophyma with the carbon dioxide laser: a preliminary report. *Arch Otolaryngol.* 1980;106(5):257–259. doi:10.1001/archotol.1980.00790290009004
- Manstein D, Herron GS, Sink RK, et al. Fractional photothermolysis: a new concept for cutaneous remodeling using microscopic patterns of thermal injury. *Lasers Surg Med.* 2004;34(5):426–438. doi:10.1002/lsm.20048
- Vojinović M, Bilić M, Kovač L, Peršić-Vojinović S, Basta-Juzbašić A. Treatment of massive rhinophyma by combined electrosurgery and CO2 laser. *Acta Dermatovenerol Croat.* 2009;17(1):20–24.
- Fincher EF, Gladstone HB. Use of a dual-mode erbium: YAG laser for the surgical correction of rhinophyma. *Arch Facial Plast Surg.* 2004;6:267–271. doi:10.1001/archfaci.6.4.267
- Goon PK, Dalal M, Peart FC. The gold standard for decortifications of rhinophyma: combined erbium-YAG/CO2 laser. *Aesthetic Plast Surg.* 2004;28:456–460. doi:10.1007/s00266-004-0012-x
- Trelles MA. Laser resurfacing today and the 'cook book' approach: a recipe for disaster? *J Cosmet Dermatol.* 2004;3:237–241. doi:10.1111/j.1473-2130.2004.00090.x
- Rizoiu IM, Eversole LR, Kimmel AI. Effect of an erbium, chromium: yttrium, scandium, gallium, garnet laser on mucocutaneous soft tissues. *Oral Surg Oral Med Oral Radio Endod.* 1996;82:386–395. doi:10.1016/S1079-2104(96)80302-7
- Kaufmann R, Hartmann A, Hibst R. Cutting and skin ablative properties of pulsed mid-infrared laser surgery. *J Dermatol Surg Oncol.* 1994;20:112–118. doi:10.1111/j.1524-4725.1994.tb00123.x
- Hantash BM, Bedi, VP, Kapadia B, et al. In vivo histological evaluation of a novel ablative fractional resurfacing device. *Lasers Surg Med.* 2007;39(2):96–107. doi:10.1002/lsm.20468
- Laubach HJ, Tannous Z, Anderson RR, Manstein D. Skin responses to fractional photothermolysis. *Lasers Surg Med.* 2006;38(2):142–149. doi:10.1002/lsm.20254
- Wollina U. Rosacea and rhinophyma in the elderly. *Clin Dermatol.* 2011;29(1):61–68. doi:10.1016/j.clindermatol.2010.07.009
- Little SC, Stucker FJ, Compton A, Park SS. Nuances in the management of rhino-phyma. *Facial Plast Surg.* 2012;28(2):231–237. doi:10.1055/s-0032-1309304
- Wetzig T, Averbek M, Simon JC, Kendler M. New rhinophyma severity index and mid-term results following shave excision of rhinophyma. *Dermatology.* 2013;227:31–36. doi:10.1159/000351556
- Lazzeri D, Larcher L, Huemer GM, et al. Surgical correction of rhinophyma: comparison of two methods in a 15-year-long experience. *J Craniomaxillofac Surg.* 2013;41:429–436.
- Bieniek A, Matusiak Ł, Chlebicka I, Szepietowski JC. Secondary intention healing in skin surgery: our own experience and expanded indications in hidradenitis suppurativa, rhinophyma and non-melanoma skin cancers. *J Eur Acad Dermatol Venereol.* 2013;27:1015–1021. doi:10.1111/j.1468-3083.2012.04646.x

27. Serowka KL, Saedi N, Dover JS, Zachary CB. Fractionated ablative carbon dioxide laser for the treatment of rhinophyma. *Lasers Surg Med.* 2014;46:8–12. doi:10.1002/lsm.22184
28. Meesters AA, Linden MM, De Rie MA, Wolkerstorfer A. Fractionated carbon dioxide laser therapy as treatment of mild rhinophyma: report of three cases. *Dermatol Ther.* 2015;28:147–150. doi:10.1111/dth.12205
29. Orenstein A, Haik J, Tamir J, et al. Treatment of rhinophyma with ER:YAG laser. *Lasers Surg Med.* 2001;29:230–235. doi:10.1002/lsm.1112
30. Schweinzer K, Kofler L, Spott C, et al. Surgical treatment of rhinophyma: experience from a German cohort of 70 patients. *Eur J Dermatol.* 2017;27(3):281–285.
31. Mathis J, Ibrahim SF. Erbium-doped yttrium aluminium garnet (Er:YAG) laser resurfacing restores normal function and cosmesis in patients with severe rhinophyma. *J Clin Aesthet Dermatol.* 2019;12(7):28–33. PMID: 31531160; PMCID: PMC6715331.

Clinical, Cosmetic and Investigational Dermatology

Dovepress

Publish your work in this journal

Clinical, Cosmetic and Investigational Dermatology is an international, peer-reviewed, open access, online journal that focuses on the latest clinical and experimental research in all aspects of skin disease and cosmetic interventions. This journal is indexed on CAS.

The manuscript management system is completely online and includes a very quick and fair peer-review system, which is all easy to use. Visit <http://www.dovepress.com/testimonials.php> to read real quotes from published authors.

Submit your manuscript here: <https://www.dovepress.com/clinical-cosmetic-and-investigational-dermatology-journal>