

Contents lists available at [ScienceDirect](http://www.sciencedirect.com)

International Journal of Surgery Case Reports

journal homepage: www.casereports.com

The successful use of dronabinol for failure to thrive secondary to intestinal dysmotility



Grace H. Taylor*, Steven D. Schweitzberg

Harvard Medical School, 25 Shattuck Street, Boston, MA 02115, United States

ARTICLE INFO

Article history:

Received 10 March 2015
 Received in revised form 28 April 2015
 Accepted 30 April 2015
 Available online 5 May 2015

Keywords:

Gastroparesis
 Intestinal dysmotility
 Failure to thrive
 Cannabinoids

ABSTRACT

INTRODUCTION: Symptoms of severe intestinal dysmotility decrease patients' quality of life and may prevent them from sustaining adequate oral intake. Dronabinol is a synthetic cannabinoid that is labeled for use in AIDS-related anorexia and chemotherapy-associated nausea and vomiting that has additional efficacy in patients with other etiologies of nausea, vomiting, and anorexia.

PRESENTATION OF CASE: We present a 58-year-old female with a history of nausea, vomiting, abdominal pain, and inability to maintain oral intake after multiple laparotomies for ectopic pregnancy, recurrent caecal volvulus, and cholecystitis. After eight years of unsuccessful trials of medicines, dietary modifications, and a partial colectomy, she began a trial of dronabinol, which caused almost complete remission of her symptoms. When this medication was discontinued by her payer, she was unable to maintain oral intake and therefore, was admitted to the hospital for fluid resuscitation and resumption of dronabinol.

DISCUSSION: The use of dronabinol in this patient with severe intestinal dysmotility allowed her to maintain her nutritional status orally and obviated the need for enteral or parenteral feeding. Unfortunately, it was not covered by her insurance company for this indication.

CONCLUSION: Dronabinol has the potential to improve quality of life for patients beyond those undergoing chemotherapy or suffering from AIDS. Lack of access to this medicine for patients with intestinal dysmotility after all other modalities have been tried can lead to morbid and expensive complications, such as inpatient admission and surgery for enteral access.

© 2015 The Authors. Published by Elsevier Ltd. on behalf of Surgical Associates Ltd. This is an open access article under the CC BY-NC-ND license (<http://creativecommons.org/licenses/by-nc-nd/4.0/>).

1. Introduction

Appropriate motility of the gastrointestinal tract requires functioning of the musculature as well as the enteric, autonomic, and somatic nervous systems. These systems can be perturbed by various local or systemic insults, including but not limited to metabolic derangements, degenerative neurological disease, spinal cord injury, infiltrative disease, post-viral syndromes, and paraneoplastic syndromes [1,2]. There are a number of disorders characterized by symptoms of dysmotility—anorexia, nausea, vomiting, abdominal pain, distention, constipation, and/or diarrhea—that do not have clear etiologies, such as irritable bowel syndrome and functional abdominal pain [3,4]. There is a wide range of medical treatments for patients with these symptoms, including pro- and anti-kinetic agents, anti-emetics, antidepressants, antibiotics, laxatives, and other medicines.

Dronabinol is a synthetic cannabinoid that is thought to act through endogenous cannabinoid receptors on multiple organ systems including the central and enteric nervous systems [5,6]. It

has been established as an effective treatment for AIDS-associated anorexia and chemotherapy-induced nausea [7–12]. It is frequently used off-label for anorexia and nausea of other etiologies, but there is a dearth of literature supporting its efficacy in those settings. Its anti-emetic mechanism of action is not completely understood, although, it is thought to act both centrally and peripherally [13,14]. Data suggest that it may slow gastric emptying and increase colonic compliance in humans [15,16].

We present a case of a 58-year-old woman with debilitating nausea, vomiting, and abdominal pain secondary to intestinal dysmotility whose symptoms were refractory to medical treatment with the exception of dronabinol.

2. Presentation of case

The patient is a 58 year-old woman who presented to multiple health care providers over several years with symptoms of nausea, vomiting, abdominal pain, and weight loss in the context of reduced oral intake (Fig. 1). Her symptoms began in 2003, after she presented to the emergency department of an outside hospital with a caecal volvulus and underwent an exploratory laparotomy with reduction of volvulus, lysis of adhesions, appendectomy, and Meckel's diverticulectomy. Her surgical history prior to this was

* Corresponding author.

E-mail address: grace.taylor@hms.harvard.edu (G.H. Taylor).

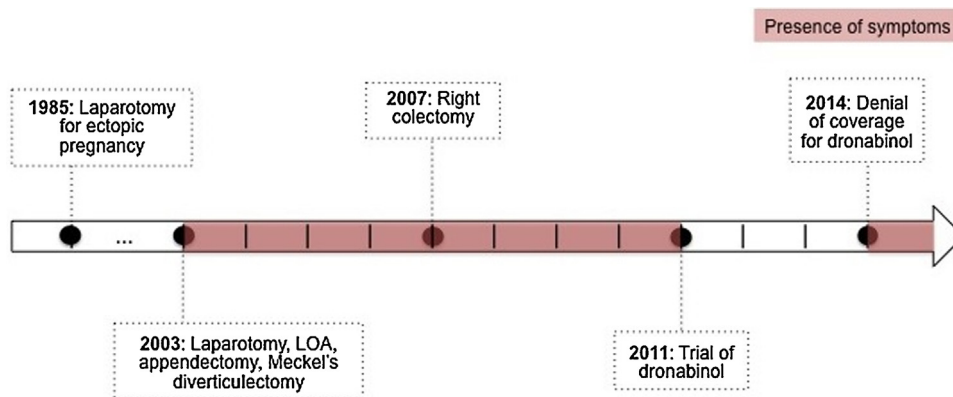


Fig. 1. Timeline of patient's pertinent medical and surgical history. Shaded areas represent presence of symptoms of abdominal pain, nausea, vomiting, and anorexia.

significant for a laparotomy for ectopic pregnancy in 1985. After the caecal volvulus surgery, the patient continued to experience episodes every few months of intense, right-sided abdominal pain, nausea, and vomiting. These symptoms progressed over the course of a year into constant moderate nausea, more frequent episodes of pain, and difficulty maintaining an appetite and oral intake. Due to her symptoms, she was unable to continue her work in the food service industry and applied for social security disability insurance. In 2005, she underwent another laparotomy for cholecystectomy during which extensive adhesions were found and lysed. For approximately one year after this surgery, she was symptom-free, but her intermittent "blockage" and near-constant nausea returned.

Multiple etiologies for her symptoms were considered and then, ruled out by additional work-up, including but not limited to diabetes mellitus, celiac disease, inflammatory bowel disease, and connective tissue disease. In 2007, a two-hour gastric emptying study showed markedly delayed gastric emptying. In addition, a capsule study demonstrated luminal stenosis in the small bowel at a site consistent with the location of her Meckel's diverticulectomy in 2003. In May 2008, she underwent a limited right colectomy to treat her presumed recurrent small bowel obstructions at the site of the stenosis. Following this operation, her symptoms diminished considerably until December 2008, when she again felt a recurrence in her nausea, vomiting, and abdominal pain.

Trials of metoclopramide, prochlorperazine, ondansetron, erythromycin, tramadol, megestrol, multiple laxatives, omeprazole, tegaserod, and donnatal among other medicines were either unsuccessful in abating the patient's symptoms or had intolerable side effects. Empiric treatment for possible bacterial overgrowth in the small bowel was attempted with levofloxacin and probiotics, without effect. Various dietary modifications were explored, with a low-fat, high-carbohydrate diet proving to be the most effective. Regardless, the patient struggled to maintain a weight over 50 kg (BMI 18.4 kg/m²).

In 2011, a trial of 2.5 mg of dronabinol twice a day was initiated. Within a few months, the patient began to experience decreased nausea and increased appetite. She denied any adverse effects, and was able to consistently keep her weight above 50 kg.

After the initiation of dronabinol, her course was largely uneventful for several years. Her dose was titrated up to 5 mg four times a day, which sufficiently controlled her symptoms. In May 2014, after a change in her insurance, she received a letter from Medicare stating that her request for coverage of dronabinol was denied, as its use in her case was not supported by the FDA or Medicare-approved references. She presented to the outpatient surgery clinic having been off dronabinol for several days, complaining again of nausea, vomiting, abdominal pain, and inability

to tolerate oral intake "like from before." At that time, she weighed 48 kg (BMI of 17.6) with physical exam findings consistent with dehydration. She was admitted directly to the hospital for failure to thrive. While in the hospital, she was able to receive dronabinol and experienced a marked remission in her symptoms. Since, she has obtained dronabinol from the hospital's free care pharmacy and has maintained her weight nearly 50 kg.

Since their original denial, Medicare has denied three subsequent appeals to have dronabinol covered. The patient's surgeon was required to testify in front of an administrative judge, who ruled in favor of the patient finding that the use of the drug in this instance was based on treating the same symptoms as the approved indications. This was subsequently overturned by an administrative oversight panel. The patient does not want symptoms typically associated with marijuana and has rejected the notion of pursuing this option now available in several states. Currently, the patient is working with lawyers at the Medicare Advocacy Project in an attempt to regain stable access to this medication.

3. Discussion

This patient presented with intestinal dysmotility of unclear etiology. Gastric emptying studies indicate delayed gastric emptying, but there is also an obstructive element that has been temporarily alleviated by lysis of adhesions and resection of the stenosed bowel. Since, as we have been unable to identify the pathophysiologic basis of her disease, our strategy has been to treat her symptoms. She was unresponsive to many different medical therapies but responded excellently to dronabinol, both subjectively in terms of her quality of life and objectively in terms of her weight. Despite this dramatic and consistent response, Medicare has rejected her requests and appeals for coverage of this medicine. When she was admitted to the hospital in 2014 for dehydration and failure to thrive, prompt treatment with dronabinol prevented her from needed parenteral or enteral nutrition.

Research identifying the possible uses of dronabinol is ongoing, and as a result insurance policy is appropriately dynamic. For example, recent evidence supporting the use of dronabinol for Tourette syndrome has been cited in the Federal Register, resulting in approval for coverage for Tourette syndrome by some payers [17]. Further research in the utility of dronabinol to treat symptoms of intestinal dysmotility is warranted, and may allow for both better patient care and more appropriate insurance coverage.

4. Conclusion

Our experience with this demonstrates that dronabinol can be an effective and well-tolerated treatment option for nausea,

vomiting, and abdominal pain secondary to intestinal dysmotility where other modalities have failed. The mechanism of action is unclear, but is likely in the same family of etiologies of other established indications. Lack of insurance coverage for dronabinol can be a significant barrier to care and necessitates continued research to make the basis for policy in the future.

Conflicts of interest

The authors have no financial or personal conflicts of interest to disclose.

Funding

The authors have no funding sources to declare.

Consent

Written informed consent was obtained from the patient for publication of this case report. A copy of this consent is available for review by the Editor-in-Chief of this journal on request.

Ethical approval

No ethical approval was required or obtained.

Authors contributions

Grace Taylor – primary author and resource researcher. Steven Schwaitzberg – secondary author, editorial review.

Guarantor

Grace Taylor and Steven Schwaitzberg.

Acknowledgment

We would like to thank the patient, who took the time to share her insights on the impact of her disease.

References

- [1] A. Ouyang, G.R. Locke, Overview of neurogastroenterology–gastrointestinal motility and functional GI disorders: classification, prevalence, and epidemiology, *Gastroenterol. Clin. N. Am.* 36 (3) (2007) 485–498.
- [2] N. Venkatasubramani, M.R. Sood, Motility disorders of the gastrointestinal tract, *Indian J. Pediatr.* 73 (10) (2006) 927–930.
- [3] E.A. Mayer, Irritable bowel syndrome, *N. Engl. J. Med.* 358 (16) (2008) 1692–1699.
- [4] W.G. Thompson, G.F. Longstreth, D.A. Drossman, K.W. Heaton, E.J. Irvine, S.A. Müller-Lissner, Functional bowel disorders and functional abdominal pain, *Gut* 45 (Suppl. 2) (1999) II43–II47.
- [5] N.A. Darmani, Δ 9-Tetrahydrocannabinol and synthetic cannabinoids prevent emesis produced by the cannabinoid CB1 receptor antagonist/inverse agonist SR 141716A, *Neuropsychopharmacology* 24 (2) (2001) 198–203.
- [6] B.R. Martin, J.L. Wiley, Mechanism of action of cannabinoids: how it may lead to treatment of cachexia, emesis, and pain, *J. Support. Oncol.* 2 (4) (2004) 305–314.
- [7] P.O. Anderson, G.G. McGuire, Delta-9-tetrahydrocannabinol as an antiemetic, *Am. J. Health-Syst. Pharm.* 38 (5) (1981) 639–646.
- [8] T.F. Plasse, R.W. Gorter, S.H. Krasnow, M. Lane, K.V. Shepard, R.G. Wadleigh, Recent clinical experience with dronabinol, *Pharmacol. Biochem. Behav.* 40 (3) (1991) 695–700.
- [9] N.E. Slatkin, Cannabinoids in the treatment of chemotherapy-induced nausea and vomiting: beyond prevention of acute emesis, *J. Support. Oncol.* 5 (Suppl. 3–5) (2007) 1–9.
- [10] M. Struwe, S.H. Kaempfer, C.J. Geiger, A.T. Pavia, T.F. Plasse, K.V. Shepard, T.G. Evans, Effect of dronabinol on nutritional status in HIV infection, *Ann. Pharmacother.* 27 (7–8) (1993) 827–831.
- [11] M.R. Tramèr, D. Carroll, F.A. Campbell, D.J.M. Reynolds, R.A. Moore, H.J. McQuay, Cannabinoids for control of chemotherapy induced nausea and vomiting: quantitative systematic review, *BMJ* 323 (7303) (2001) 16.
- [12] E.A. Voth, R.H. Schwartz, Medicinal applications of delta-9-tetrahydrocannabinol and marijuana, *Ann. Intern. Med.* 126 (10) (1997) 791–798.
- [13] N.A. Darmani, Mechanisms of broad-spectrum antiemetic efficacy of cannabinoids against chemotherapy-induced acute and delayed vomiting, *Pharmaceuticals* 3 (9) (2010) 2930–2955.
- [14] B.R. Martin, J.L. Wiley, Mechanism of action of cannabinoids: how it may lead to treatment of cachexia emesis and pain, *J. Support. Oncol.* 2 (4) (2004) 305–314.
- [15] T. Esfandyari, et al., Effect of a cannabinoid agonist on gastrointestinal transit and postprandial satiation in healthy human subjects: a randomized placebo-controlled study, *Neurogastroenterol. Motil.* 18 (9) (2006) 831–838.
- [16] T. Esfandyari, et al., Effects of a cannabinoid receptor agonist on colonic motor and sensory functions in humans: a randomized, placebo-controlled study, *Am. J. Physiol.-Gastrointest. Liver Physiol.* 293 (1) (2007) G137–G145.
- [17] "Denial of Petition To Initiate Proceedings To Reschedule Marijuana," vol. 76, No. 131, Federal Register, p. 40578 (07.08.11).

Open Access

This article is published Open Access at sciedirect.com. It is distributed under the [IJSCR Supplemental terms and conditions](#), which permits unrestricted non commercial use, distribution, and reproduction in any medium, provided the original authors and source are credited.