

RESEARCH ARTICLE

Effect of Silodosin, an Alpha1A-Adrenoceptor Antagonist, on Ventral Prostatic Hyperplasia in the Spontaneously Hypertensive Rat

Shogo Shimizu¹, Takahiro Shimizu¹, Panagiota Tsounapi², Youichirou Higashi¹, Darryl T. Martin³, Kumiko Nakamura¹, Masashi Honda², Keiji Inoue⁴, Motoaki Saito^{1*}

1 Department of Pharmacology, Kochi Medical School, Kochi University, Nankoku, Japan, **2** Department of Surgery, Division of Urology, Tottori University School of Medicine, Yonago, Japan, **3** Department of Urology, Yale University School of Medicine, New Haven, CT, United States of America, **4** Department of Urology, Kochi Medical School, Kochi University, Nankoku, Japan

* saitomo@kochi-u.ac.jp



Abstract

Background

A decreased prostatic blood flow could be one of the risk factors for benign prostatic hyperplasia/benign prostatic enlargement. The spontaneously hypertensive rat (SHR) shows a chronic prostatic ischemia and hyperplastic morphological abnormalities in the ventral prostate. The effect of silodosin, a selective alpha_{1A}-adrenoceptor antagonist, was investigated in the SHR prostate as a prostatic hyperplasia model focusing on prostatic blood flow.

Methods

Twelve-week-old male SHRs were administered perorally with silodosin (100 µg/kg/day) or vehicle once daily for 6 weeks. Wistar Kyoto (WKY) rats were used as normotensive controls and were treated with the vehicle. The effect of silodosin on blood pressure and prostatic blood flow were estimated and then the prostates were removed and weighed. The tissue levels of malondialdehyde (MDA), interleukin-6 (IL-6), chemokine (C-X-C motif) ligand 1/cytokine-induced neutrophil chemoattractant 1 (CXCL1/CINC1), tumor necrosis factor-alpha (TNF-α), transforming growth factor beta 1 (TGF-β1), basic fibroblast growth factor (bFGF) and alpha-smooth muscle actin (α-SMA) were measured. The histological evaluation was also performed by hematoxylin and eosin staining.

Results

There was a significant increase in blood pressure, prostate weight, prostate body weight ratio (PBR), tissue levels of MDA, IL-6, CXCL1/CINC1, TNF-α, TGF-β1, bFGF and α-SMA in the SHR compared to the WKY rat. The ventral prostate in the SHR showed the morphological abnormalities compared to the WKY rat. Prostatic blood flow was decreased in the SHR. However, treatment with silodosin significantly restored the decreased prostatic blood flow in the SHR. Moreover, silodosin normalized tissue levels of MDA, IL-6, CXCL1/CINC1, TNF-α,

OPEN ACCESS

Citation: Shimizu S, Shimizu T, Tsounapi P, Higashi Y, Martin DT, Nakamura K, et al. (2015) Effect of Silodosin, an Alpha1A-Adrenoceptor Antagonist, on Ventral Prostatic Hyperplasia in the Spontaneously Hypertensive Rat. PLoS ONE 10(8): e0133798. doi:10.1371/journal.pone.0133798

Editor: Aamir Ahmed, King's College London, UNITED KINGDOM

Received: April 14, 2015

Accepted: July 1, 2015

Published: August 26, 2015

Copyright: © 2015 Shimizu et al. This is an open access article distributed under the terms of the [Creative Commons Attribution License](https://creativecommons.org/licenses/by/4.0/), which permits unrestricted use, distribution, and reproduction in any medium, provided the original author and source are credited.

Data Availability Statement: All relevant data are within the paper.

Funding: This study was supported by JSPS KAKENHI (to MS; grant no. 24592431 and 20591880).

Competing Interests: The authors have declared that no competing interests exist.

TGF- β 1, bFGF and α -SMA, and it ameliorated ventral prostatic hyperplasia in the SHR excluding blood pressure. Silodosin decreased PBR but not prostate weight in the SHR.

Conclusions

Silodosin can inhibit the progression of prostatic hyperplasia through a recovery of prostatic blood flow.

Introduction

Benign prostatic hyperplasia (BPH) is one of the most common diseases among elderly men. Epidemiological data show that approximately 50% of patients develop lower urinary tract symptoms (LUTS) due to BPH/benign prostatic enlargement (BPE) [1]. BPH/BPE consist of overgrowth of epithelial and stromal cells within the transitional zone and periurethral area [2]. Although aging and androgens are two established risk factors for the development of BPH/BPE, serum androgen levels are generally decreased in elderly males and are not correlated with prostate volume [2]. There is some evidence that vascular risk factors may be associated with progression of BPH/BPE [3,4]. Clinical data showed that BPH and hypertension occur with increasing prevalence with older age, and are more likely to be pathophysiologically relevant [5,6]. De Nuzio et al. suggested that BPH related LUTS are caused by multiple factors including pelvic atherosclerosis followed by chronic ischemia of prostate, and chronic inflammation in the prostate [7]. Inflammation with cytokines and macrophage infiltration might induce proliferation of prostatic tissue [3,8]. Recent basic and clinical research suggest that prostatic inflammation could be one of the central mechanisms in the development of BPH/BPE [9,10]. In addition, chronic histological inflammation was found in more than 90% of specimens obtained from transurethral resection of the prostate [11].

The spontaneously hypertensive rat (SHR) is commonly used as a genetically hypertensive rat model of BPH/BPE [12]. The SHR exhibits decreased prostatic blood flow and develops hyperplastic morphological abnormalities in the ventral prostate as early as 15 weeks [13,14]. However, our previous data showed that there was no statistical difference in dihydrotestosterone (androgen hormone) levels in the prostate between the SHR and the WKY rat, which is used as a normotensive control model [15]. These reports indicate that the ventral prostate of the SHR can be a good model for human BPH/BPE. Our previous report showed chronic treatment with nicorandil, a vasodilator, significantly increased prostatic blood flow and inhibited the progression of ventral prostatic hyperplasia in the SHR [15]. A recent study showed that chronic pelvic ischemia induced distinct functional and morphological changes in the rat ventral prostate. Pretreatment with tadalafil, a phosphodiesterase type 5 inhibitor, has been shown to decrease collagen deposition in the ventral prostate caused by arterial endothelial injury [16]. Thus, blood flow in the prostate plays an important role in prostatic hyperplasia development.

Alpha (α)₁-adrenoceptor antagonists are the most frequently used drugs for treatment of BPH related LUTS. It is widely known that α ₁-adrenoceptor antagonists relax prostate smooth muscle and decrease urethral resistance, thereby alleviating LUTS [17]. Pinggera et al. demonstrated that α ₁-adrenoceptor antagonists ameliorated chronic ischemia of the lower urinary tract in patients with LUTS [18]. Doxazosin, an α ₁-adrenoceptor antagonist, restored prostatic blood flow in the SHR [14]. Additionally, chronic treatment with terazosin, an α ₁-adrenoceptor antagonist, inhibited hyperplastic changes in the SHR prostate [19]. Thus, we investigated

whether silodosin, a selective α_{1A} -adrenoceptor antagonist, could ameliorate blood flow, inflammation and hyperplasia in the SHR ventral prostate.

Material and Methods

Animal preparation

The layout of the experiments were approved by the Institutional Animal Care and Use committee of Kochi University (Permit Number: H-113), which were in accordance with the guidelines for proper conduct of animal experiments from the Science Council of Japan. The protocol was approved by the committee on Ethics of Animal Experiments of the Kochi University (Permit Number: H-113). All studies involving animals were reported in accordance with ARRIVE guidelines [20]. In this study, we used 12 weeks old male SHRs and WKY rats. The animals were purchased from SLC Japan (Hamamatsu, Japan). All animals were kept under identical conditions of temperature and humidity, and had access to food and drinking water *ad libitum*. When the animals ($n = 24$) reached 12 weeks of age, they were randomly divided into three groups ($n = 8/\text{group}$): an age-matched WKY rat group treated with vehicle (0.5% methylcellulose in distilled water) perorally (p.o.) (WKY), SHRs treated with vehicle p.o. (SHR), and SHRs treated with silodosin at a daily dose of 100 $\mu\text{g}/\text{kg}$, p.o. (SHR+Sil100). Taking into consideration that the US Food and Drug Administration suggested an oral dose of silodosin to be taken at 8 mg once daily, we adopted the dosage of 100 $\mu\text{g}/\text{kg}$, which was administered (p.o.) once daily for 6 weeks in accordance with our previous experiments [21]. Also, our preliminary data showed no significant differences in prostatic blood flow or basic fibroblast growth factor (bFGF) in the prostate between the SHRs treated with two different doses of silodosin (i.e. 100 or 300 $\mu\text{g}/\text{kg}$ p.o.) once daily for six weeks. Thus, in subsequent experiments we decided to use only a dose of 100 $\mu\text{g}/\text{kg}$ p.o.. After 6 weeks of treatment, when the animals reached 18 weeks of age, blood pressure and heart rate were measured with the tail cuff method, which included warming the whole animal body in the absence of anesthesia (BP-98A-L, Softron, Tokyo, Japan) [15]. Subsequently, prostatic blood flow was measured under intraperitoneally (i.p.) administered sodium pentobarbital anesthesia (50 mg/kg) as described below; afterwards, the rats were sacrificed with an overdose of sodium pentobarbital (60 mg/kg i.p.). The isolated prostates were frozen at -80°C until measurements of tissue were performed. The remaining parts of ventral and dorsolateral prostate were placed in 10% neutral buffered formalin for histopathological evaluation [15].

Measurement of prostatic blood flow

Prostatic blood flow was measured using the hydrogen clearance method [15]. The hydrogen electrode (80 μm diameter, UHE-201C; Unique Medical Co., Tokyo, Japan) was inserted into the ventral prostate. A rod-type Ag/AgCl reference electrode (UHE-001; Unique Medical Co.) was inserted between the skin and musculature region in the abdomen.

Measurement of oxidative stress in the prostate

The levels of malondialdehyde (MDA), a widely used marker of lipid peroxidation, in prostatic tissue homogenates were identified using a commercially available kit (NWLSSSTM Malondialdehyde Assay; Northwest Life Science Specialties LLC., Vancouver, WA). The MDA concentrations were normalized by the protein content.

Measurements of inflammatory cytokines in the prostate

Commercially available kits were used to identify homogenates levels of interleukin-6 (IL-6) (Quantikine ELISA Rat IL-6 Immunoassay, R6000B; R&D Systems Inc, MN), chemokine (C-X-C motif) ligand 1/cytokine-induced neutrophil chemoattractant 1 (CXCL1/CINC1) (Rat CXCL1/CINC1 Quantikine ELISA; R&D Systems Inc.) and tumor necrosis factor- α (TNF- α) (Rat TNF- α ELISA kit; RayBiotech, Inc, GA). Obtained markers were normalized by the protein content. CXCL1/CINC1 is the rat homologue to human IL-8.

Transforming growth factor beta 1 (TGF- β 1) and bFGF measurements in the prostate

For the measurement of TGF- β 1 and bFGF, we used commercially available kits (Quantikine ELISA mouse/rat/porcine/canine TGF- β 1 immunoassay MB100B; R&D Systems Inc.) (Quantikine ELISA mouse/rat FGF basic immunoassay MFB00; R&D Systems Inc). The concentrations of TGF- β 1 and bFGF were normalized by the protein content.

Protein assay in the prostatic homogenates

Protein concentration was determined using a commercially available kit (Protein Assay Rapid Kit; Wako Pure Chemical, Osaka, Japan). Bovine serum albumin was used as the standard.

Western blot analysis of alpha-smooth muscle actin (α -SMA)

Western blot analysis was performed according to previous methods [15]. Protein samples (50 μ g) were subjected to SDS-polyacrylamide gel electrophoresis on 12% gradient gels, and the separated proteins were transferred to polyvinylidene difluoride membranes. The membrane was blocked with 5% nonfat milk in Tris-Buffered Saline containing 0.1% Tween 20 (TBS-T), and then incubated overnight on a shaker at 4°C with antibodies for α -SMA (1:400), and anti- β -actin (1:1,000) in 5% nonfat milk in TBS-T. After washing with TBS-T (10 min \times 3 times), the membrane was incubated for 1 hour at room temperature on a shaker with a 1:3,000 dilution of horseradish peroxidase-conjugated rabbit antibody in 5% nonfat milk in TBS-T. After washing with TBS-T (10 min \times 3 times), the detection was performed using an enhanced chemiluminescence reagent (Millipore Corporation, Billerica, MA). The intensity of target bands was quantified by densitometry using Malti Gauge software (FUJIFILM, Tokyo, Japan). A rabbit polyclonal anti- α -SMA (ab5694, Abcam, Tokyo, Japan) and a rabbit polyclonal anti- β -actin (54590, AnaSpec, Inc., San Jose, CA) were used as primary antibodies. β -Actin was used as a control for normalization of α -SMA.

Histological examinations

After fixation, the tissues were embedded in paraffin, and five-micron-thick tissue sections were cut from the paraffin blocks. All of the prostate specimens were stained using hematoxylin and eosin (HE). Each section was viewed under a light microscope at a magnification of \times 40–400 and morphological changes were evaluated by two blinded investigators (S.S. and H.Y.). ImageJ 1.48 software (NIH, Bethesda, MD) was used to calculate the HE stained gland area in the rat ventral prostate. The stained area in the gland indicated the degree of proliferation of epithelial components. Under blind conditions, we randomly counted 10 glands in each section and then quantified the glandular epithelial area as stained area per glandular area under 100-fold magnification. The mean percent area density was also evaluated for each group.

Data analysis

Quantitative data are presented as means \pm SEM and were compared among multiple experimental groups using analysis of variance and Fisher's multiple comparison tests. *P*-values less than 0.05 were considered statistically significant.

Drugs and chemicals

Silodosin was supplied by the Daiichi-Sankyo Pharmaceutical Co. Ltd (Tokyo, Japan). All other chemicals were commercially available and of reagent grade quality.

Results

General features of the animals

After six weeks of silodosin or vehicle treatment, body weights in the SHR and SHR+Sil100 groups were significantly lower compared to the WKY group (Table 1). The prostate weight and the prostate body weight ratio (PBR) in the SHR and SHR+Sil100 groups were significantly higher than those in the WKY group. Treatment with silodosin significantly decreased PBR, but not prostate weight in the SHR. Heart rate was significantly lower in the SHR group compared to the WKY group. Heart rate in the SHR+Sil100 group was not significantly different from either the WKY group or the SHR group. The SHR+Sil100 group demonstrated significantly higher mean blood pressure compared to the WKY group, while there were no significant differences when compared to the SHR group (Table 1).

Prostatic blood flow

Prostatic blood flow in the SHR group was significantly lower compared to the WKY group. Treatment with silodosin significantly increased prostatic blood flow compared to the SHR group (Fig 1).

MDA concentrations in the ventral prostate

Oxidative stress levels were significantly increased in the SHR ventral prostates compared to the WKY group, as evaluated by MDA concentrations in the prostate tissues. Treatment with silodosin significantly decreased MDA concentrations compared to the SHR group. There were no statistically significant differences in MDA concentrations between the WKY and SHR+Sil100 groups (Fig 2).

IL-6, CXCL1/CINC1 and TNF- α levels in the ventral prostate

Our results revealed a significant increase in IL-6, CXCL1/CINC1 and TNF- α levels in the ventral prostate of the SHR group compared to the WKY group. Treatment with silodosin significantly decreased levels of IL-6, CXCL1/CINC1 and TNF- α in the SHR ventral prostate compared to the vehicle control SHR ventral prostate. There were no statistically significant differences between the WKY group and the SHR+Sil100 group with respect to IL-6, CXCL1/CINC1 and TNF- α levels (Fig 3).

TGF- β 1, bFGF and α -SMA levels in the ventral prostate

There was a significant increase in TGF- β 1, bFGF and α -SMA levels in the SHR group compared to the WKY group. Treatment with silodosin significantly decreased TGF- β 1 and bFGF levels, and α -SMA protein expression compared to the SHR group. Also, there were no

Table 1. The General Features.

Factors	Groups		
	WKY	SHR	SHR+Sil100
Body Weight (g)	402 ± 5	326 ± 16†	336 ± 12†
Prostate Weight (mg)	630 ± 35	926 ± 31†	863 ± 54†
PBR (×10 ⁻³)	1.57 ± 0.09	2.86 ± 0.07†	2.56 ± 0.11†#
Heart Rate (bpm)	338.0 ± 9.6	302.4 ± 3.9†	324.0 ± 9.8
Mean Blood Pressure (mmHg)	106.5 ± 1.1	166.0 ± 5.9†	154.7 ± 4.5†

PBR: Prostate body weight ratio (prostate weight/body weight); WKY: 18-week-old WKY rats treated with vehicle, p.o.; SHR: 18-week-old SHRs treated with the vehicle, p.o.; SHR+Sil100: 18-week-old SHRs treated with silodosin at a daily dose of 100 µg/kg, p.o.

Data are shown as mean ± SEM of eight separate determinations in each group.

†: Significantly different from the WKY group (*P* < 0.05);

#: Significantly different from the SHR group (*P* < 0.05).

doi:10.1371/journal.pone.0133798.t001

statistically significant differences between the WKY group and the SHR+Sil100 group with respect to TGF-β1, bFGF and α-SMA levels (Fig 4).

Histological evaluation of the prostatic tissues

In contrast to histological sections in the WKY group, ventral prostate in the SHR group showed morphological abnormalities, characterized by increased branching of epithelial cells. Treatment with silodosin decreased these morphological alterations observed in the SHR

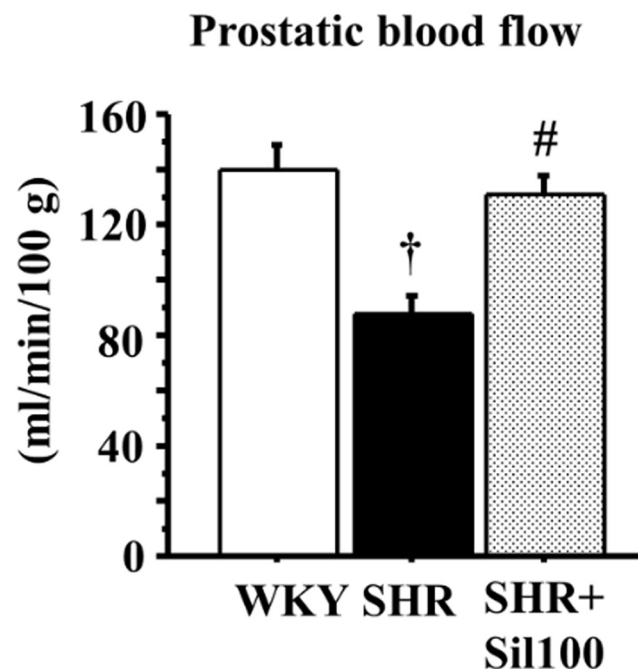


Fig 1. Blood flow in the ventral prostate. The effect of silodosin on blood flow in the ventral prostate of the 18-week-old Wistar-Kyoto rat group (WKY), the 18-week-old SHR group (SHR) and the 18-week-old SHRs treated with silodosin at a daily dose of 100 µg/kg, p.o. (SHR+Sil100). Data are shown as mean ± SEM of eight separate determinations in each group. †: Significantly different with the WKY group; #: Significantly different with the SHR group (*P* < 0.05 is a level of significance).

doi:10.1371/journal.pone.0133798.g001

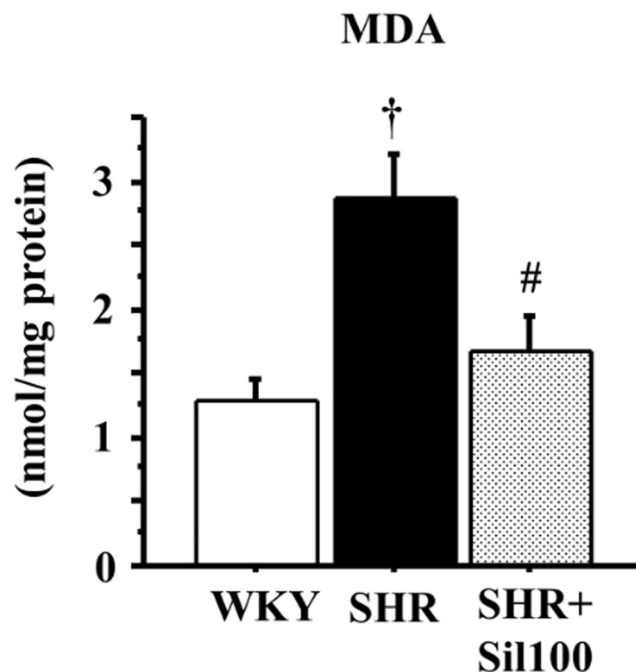


Fig 2. MDA levels in the ventral prostate. The effect of silodosin on MDA levels in the ventral prostate of the 18-week-old Wistar-Kyoto rat group (WKY), the 18-week-old SHR group (SHR) and the 18-week-old SHRs treated with silodosin at a daily dose of 100 $\mu\text{g}/\text{kg}$, p.o. (SHR+Sil100). Data are shown as mean \pm SEM of eight separate determinations in each group. †: Significantly different with the WKY group; #: Significantly different with the SHR group ($P < 0.05$ is a level of significance).

doi:10.1371/journal.pone.0133798.g002

group (Fig 5). For calculations using ImageJ, glandular epithelial area (stained area/glandular area) in the SHR group and the SHR+Sil100 group were significantly higher compared to the WKY group, indicating hyperplasia of the prostate. As well, the glandular epithelial area in the SHR+Sil100 group was significantly lower compared to the SHR group (Fig 5).

Discussion

The present study showed that chronic treatment with silodosin significantly ameliorated decreased prostatic blood flow, and increased oxidative stress, inflammatory cytokines, growth factors and morphological abnormalities in the SHR ventral prostate. On the other hand, silodosin failed to decrease blood pressure in the SHR. The management of prostatic blood flow recovery is a very important factor to ameliorate prostatic hyperplasia [15,16,22]. Pinggera et al. demonstrated that chronic ischemia of the prostate and bladder could be associated with LUTS [18]. Silodosin has a very higher selectivity for the α_{1A} subtype than for α_{1B} and α_{1D} -adrenoceptor subtypes compared to other α_1 -adrenoceptor antagonists, while minimizing the undesirable effects on blood pressure [23]. Some reports demonstrated that chronic treatment with a selective α_{1A} -adrenoceptor antagonist silodosin increased bladder blood flow in the SHR and in a rat model of chronic bladder ischemia induced by atherosclerosis. Also, the treatment subsequently improved bladder dysfunction [21,24]. α_{1A} -Adrenoceptors are abundant in smooth muscle of the prostate [23]. Molecular analysis in human has shown 70% of the α_1 -adrenoceptor mRNA in the prostate was comprised of the α_{1A} subtype [25]. The mechanism for improvement of blood flow to the prostate with silodosin could be due to the blockade of α_{1A} subtype in the smooth muscle or microvessels (vascular smooth muscle) supplying blood flow to the prostate.

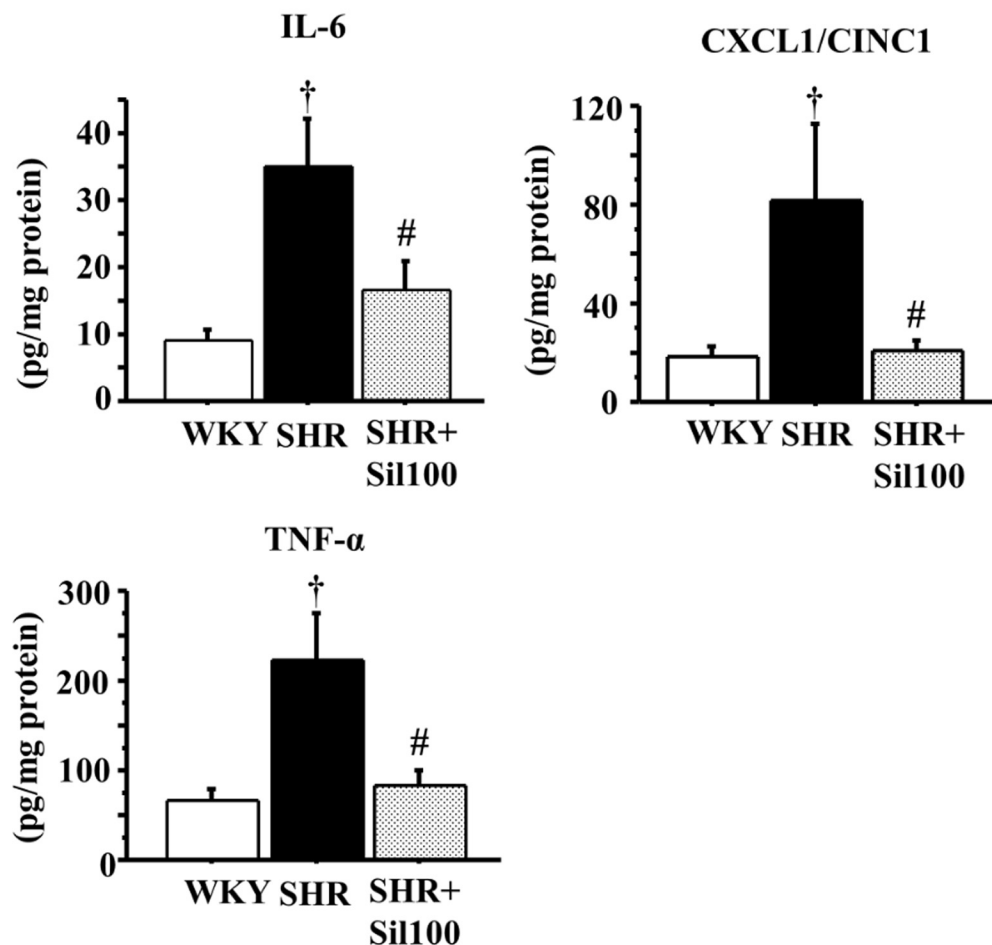


Fig 3. IL-6, CXCL1/CINC1 and TNF- α levels in the ventral prostate. Tissue levels of IL-6 (left upper panel), CXCL1/CINC1 (right upper panel), and TNF- α (left lower panel) in the ventral prostate are shown. WKY: 18-week-old Wistar-Kyoto rat group; SHR: 18-week-old SHR group; SHR+Sil100: 18-week-old SHRs treated with silodosin at a daily dose of 100 μ g/kg, p.o.. Data are shown as mean \pm SEM of eight separate determinations in each group. †: Significantly different with the WKY group; #: Significantly different with the SHR group ($P < 0.05$ is a level of significance).

doi:10.1371/journal.pone.0133798.g003

In the SHR, it is possible that ischemia or local hypoxia induces morphological structural alteration contributing to pathogenesis of BPH. The SHR prostate exhibited a high density of hypoxic cells that were localized in the epithelium when compared to the WKY rat [26]. Local hypoxia induces mild levels of reactive oxygen species (ROS), which can promote neovascularization and fibroblast-to-myofibroblast transdifferentiation and growth factors release (IL-8, TGF- β , FGF-7 and FGF-2) [3]. Under hypoxic conditions, growth factors stimulate not only inflammatory cells, but also epithelial and stromal cells, leading to prostatic enlargement [3]. Moreover, ROS produced by inflammatory cells create a positive feedback loop, which can amplify inflammation in human cells from BPH tissue [27]. Prostatic ischemia leads to generation of ROS and subsequent oxidative stress [15]. Oxidative stress has been considered to play a role in the development of BPH [15]. The current study shows that SHR has a significant increase in the concentration of MDA, an oxidative stress marker, in the prostate as compared to the WKY rat prostate. Prostatic hyperplasia in the SHR could be related to oxidative stress

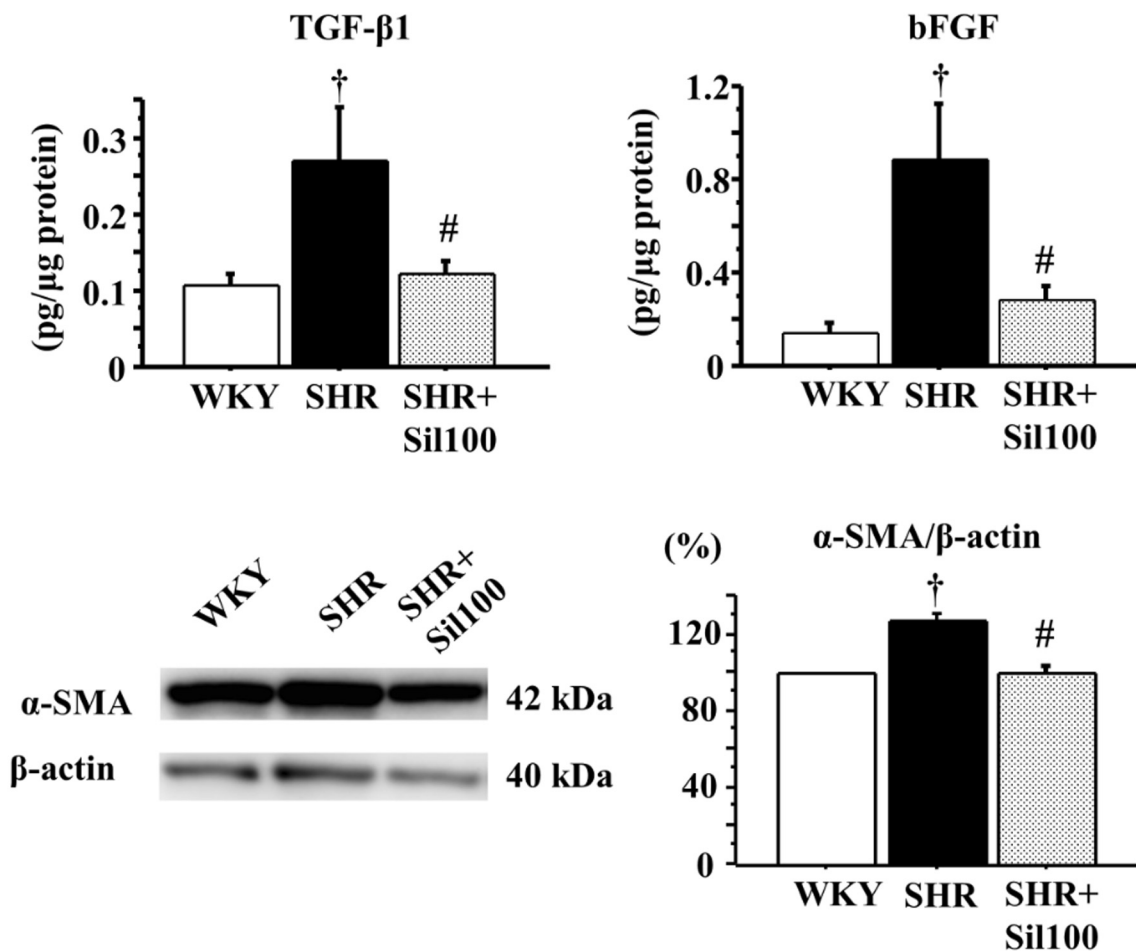


Fig 4. TGF-β1, bFGF and α-SMA levels in the ventral prostate. Tissue levels of TGF-β1 (left upper panel), bFGF (right upper panel), α-SMA (right lower panel), and a representative blot of α-SMA in the ventral prostate (left lower panel) are shown. WKY: 18-week-old Wistar-Kyoto rat group; SHR: 18-week-old SHR group; SHR+Sil100: 18-week-old SHRs treated with silodosin at a daily dose of 100 μg/kg, p.o.. Data are shown as mean ± SEM of eight separate determinations in each group. †: Significantly different with the WKY group; #: Significantly different with the SHR group ($P < 0.05$ is a level of significance).

doi:10.1371/journal.pone.0133798.g004

caused by lower prostatic blood flow. Treatment with silodosin significantly ameliorates increased MDA concentrations in the SHR ventral prostate. A previous study showed that silodosin could improve bladder blood flow, and ameliorated detrusor overactivity by reducing ROS produced by ischemia/reperfusion in atherosclerosis induced chronic bladder model [24]. Those data suggested that silodosin reduced oxidative stress via the recovery of prostatic blood flow in the SHR.

Inflammation of BPH is largely characterized by infiltration of activated lymphocytes and macrophages in the prostate. Inflammatory cytokines secreted from inflammatory cells may induce proliferation of both epithelial and stromal compartments, which results in prostate volume enlargement and BPH [28]. IL-6 and IL-8 are recognized as potent growth factors for prostatic epithelial and stromal cells [3]. TNF-α is a multifunctional cytokine that is thought to induce inflammation [3]. The current study demonstrates that the SHR significantly increased

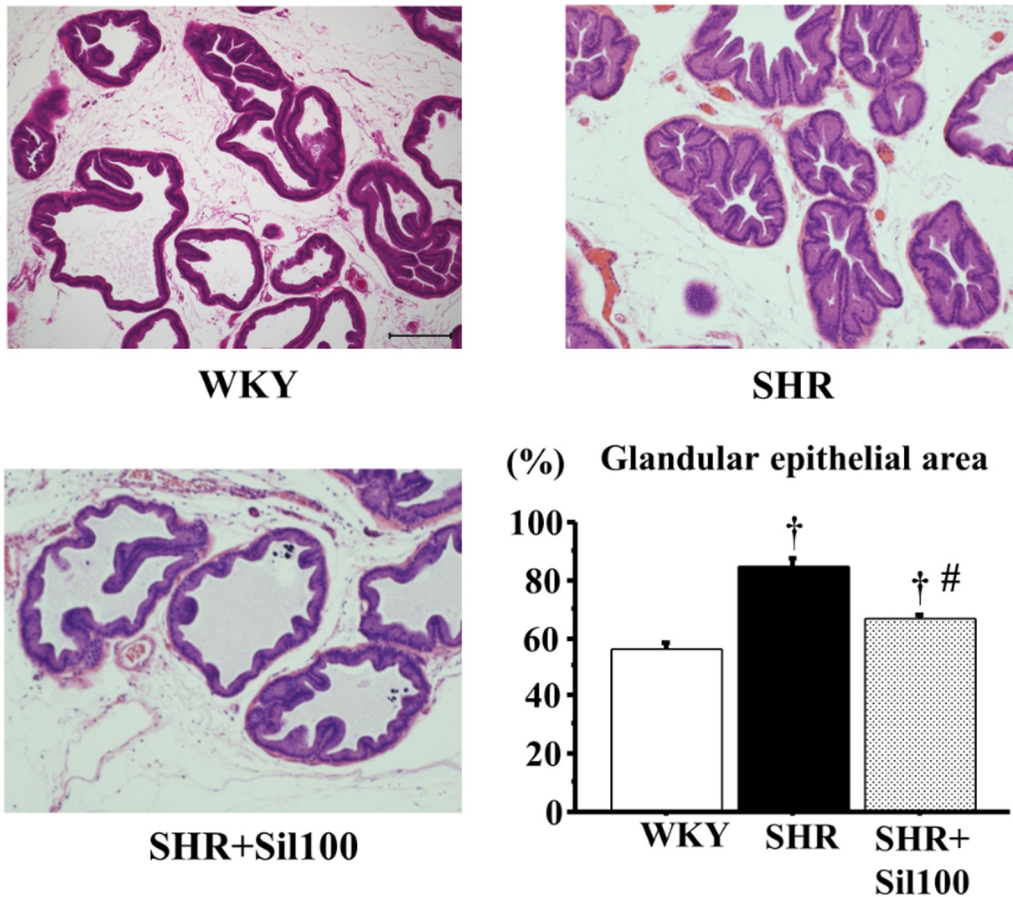


Fig 5. Histological changes in the ventral prostate of the SHR animals. The ventral prostate in the WKY group (left upper panel), the SHR group (right upper panel), and the SHR+Sil100 group (left lower panel) are shown. Glandular epithelial area (%) (HE stained area/ventral prostate glandular area \times 100) are depicted in the right lower panel. WKY: 18-week-old Wistar-Kyoto rat group; SHR: 18-week-old SHR group; SHR+Sil100; 18-week-old SHRs treated with silodosin at a daily dose of 100 μ g/kg, p.o.. Original magnification: \times 100. The scale bar is 200 μ m. †: Significantly different with the WKY group; #: Significantly different with the SHR group ($P < 0.05$ is a level of significance).

doi:10.1371/journal.pone.0133798.g005

levels of IL-6, CXCL1/CINC1 and TNF- α in the prostate. Epidemiological studies also showed an elevation of IL-6, IL-8 and TNF- α in men with BPH as compared to normal prostate without BPH [9]. To our knowledge, this is the first study to report an increase in inflammatory cytokines in the SHR prostate. Moreover, chronic treatment with silodosin decreased these inflammatory cytokines in the SHR prostate. From our international literature searches, there were no pharmacological or biochemical evidence that silodosin had an anti-oxidative or an anti-inflammatory effect. A possible mechanism as to why silodosin ameliorated oxidative stress and inflammation in the prostate of SHR may be due to the improvement in the prostatic blood flow.

A variety of hormonal and paracrine factors (i.e. growth factors) stimulate prostatic growth and development. TGF- β 1 and bFGF play critical roles in the regulation of prostatic growth and proliferation of stromal cells [29,30]. In the human prostate, TGF- β 1 and bFGF are produced by stromal smooth muscle cells and are also secreted by epithelial cells of glands [30]. In the current study, silodosin significantly decreased levels of TGF- β 1 and bFGF in the SHR ventral prostate compared to the vehicle control SHR ventral prostate. The α -SMA is recognized as a marker for prostatic fibroblast within prostatic stroma [16,31]. Previous reports demonstrated that α -SMA

was abundant in stromal smooth muscle in BPH human prostate [32]. The current study showed that chronic treatment with silodosin decreased protein levels of α -SMA in the SHR ventral prostate compared to the vehicle control SHR ventral prostate. These data suggest that silodosin could inhibit the extent of hyperplasia in stromal tissue in the SHR.

Involvement of α_1 -adrenoceptors in prostatic growth and hyperplasia has been repeatedly suggested [32–34], even though the molecular mechanism is not well understood. Silodosin could inhibit growth factors via an increase in prostatic blood flow, and decrease in oxidative stress and inflammatory cytokines in the SHR ventral prostate. This study showed that epithelial cells of the SHR ventral prostate were taller in shape compared to the WKY. We evaluated the HE stained area in each ventral prostate gland to quantify the degree of proliferation of epithelial components. Treatment with silodosin decreased glandular epithelial area in the SHR compared to the vehicle control, suggesting that silodosin could inhibit the progression of prostatic hyperplasia. Also, silodosin decreased PBR, but not prostate weight, in the SHR. One limitation of this study is that the histological changes in the ventral prostate of 18-week-old SHRs are characterized as mainly epithelial (glandular) hyperplasia, which is considerably different from those of human BPH (fibromyo-glandular hyperplasia). While both epithelial and stromal cells contribute to human BPH/BPE, stromal cells play a bigger role. The previous experimental studies showed that treatment with other α_1 -adrenoceptor antagonists (i.e. terazosin and doxazosin) caused stromal regression and reduced growth in patients with BPH [32–34]. Thus, chronic treatment with silodosin could inhibit prostatic stromal growth in animal models as well as human BPH. However, in clinical studies, treatment with some α_1 -adrenoceptor antagonists (i.e. tamsulosin, alfuzosin and doxazosin) failed to reduce prostate volume, although chronic treatment with terazosin, α_1 -adrenoceptor antagonist was reported to reduce prostate volume [35–38]. Further evidence is needed to explain the discrepancy between the experimental and clinical data.

Conclusions

Chronic treatment with silodosin has the potential to ameliorate prostatic blood flow, oxidative stress, inflammatory responses and growth factors in the SHR ventral prostate. Silodosin can inhibit the progression of prostatic hyperplasia through a recovery of prostatic blood flow.

Acknowledgments

This study was supported by JSPS KAKENHI (MS; Grant no. 24592431 and 20591880).

Author Contributions

Conceived and designed the experiments: SS MS. Performed the experiments: SS TS PT YH KN MS. Analyzed the data: SS TS PT YH MS. Contributed reagents/materials/analysis tools: MH KI. Wrote the paper: SS TS PT DTM MS.

References

1. Sarma AV, Wei JT. Clinical practice. Benign prostatic hyperplasia and lower urinary tract symptoms. *N Engl J Med*. 2012; 367(3):248–57. doi: [10.1056/NEJMcp1106637](https://doi.org/10.1056/NEJMcp1106637) PMID: [22808960](https://pubmed.ncbi.nlm.nih.gov/22808960/)
2. Barnard RJ, Aronson WJ. Benign prostatic hyperplasia: does lifestyle play a role? *Phys Sportsmed*. 2009; 37(4):141–6. doi: [10.3810/psm.2009.12.1752](https://doi.org/10.3810/psm.2009.12.1752) PMID: [20048551](https://pubmed.ncbi.nlm.nih.gov/20048551/)
3. De Nunzio C, Kramer G, Marberger M, Montironi R, Nelson W, Schroder F, et al. The controversial relationship between benign prostatic hyperplasia and prostate cancer: the role of inflammation. *Eur Urol*. 2011; 60(1):106–17. doi: [10.1016/j.eururo.2011.03.055](https://doi.org/10.1016/j.eururo.2011.03.055) PMID: [21497433](https://pubmed.ncbi.nlm.nih.gov/21497433/)

4. Gacci M, Corona G, Vignozzi L, Salvi M, Serni S, De Nunzio C, et al. Metabolic syndrome and benign prostatic enlargement: a systematic review and meta-analysis. *BJU Int.* 2015; 115(1):24–31. doi: [10.1111/bju.12728](https://doi.org/10.1111/bju.12728) PMID: [24602293](https://pubmed.ncbi.nlm.nih.gov/24602293/)
5. Lewandowski J, Sinski M, Symonides B, Korecki J, Rogowski K, Judycki J, et al. Beneficial influence of carvedilol on urologic indices in patients with hypertension and benign prostatic hyperplasia: results of a randomized, crossover study. *Urology.* 2013; 82(3):660–5. doi: [10.1016/j.urology.2013.03.087](https://doi.org/10.1016/j.urology.2013.03.087) PMID: [23987161](https://pubmed.ncbi.nlm.nih.gov/23987161/)
6. Wolak T, Toledano R, Novack V, Sharon A, Shalev A, Wolak A. Doxazosin to treat hypertension: it's time to take it personally—a retrospective analysis of 19,495 patients. *J Hypertens.* 2014; 32(5):1132–7. doi: [10.1097/HJH.000000000000119](https://doi.org/10.1097/HJH.000000000000119) PMID: [24509125](https://pubmed.ncbi.nlm.nih.gov/24509125/)
7. De Nunzio C, Aronson W, Freedland SJ, Giovannucci E, Parsons JK. The correlation between metabolic syndrome and prostatic diseases. *Eur Urol.* 2012; 61(3):560–70. doi: [10.1016/j.eururo.2011.11.013](https://doi.org/10.1016/j.eururo.2011.11.013) PMID: [22119157](https://pubmed.ncbi.nlm.nih.gov/22119157/)
8. Gandaglia G, Briganti A, Gontero P, Mondaini N, Novara G, Salonia A, et al. The role of chronic prostatic inflammation in the pathogenesis and progression of benign prostatic hyperplasia (BPH). *BJU Int.* 2013; 112(4):432–41. doi: [10.1111/bju.12118](https://doi.org/10.1111/bju.12118) PMID: [23650937](https://pubmed.ncbi.nlm.nih.gov/23650937/)
9. Yang X, Yuan L, Xiong C, Yin C, Ruan J. Abacopteris penangiana exerts testosterone-induced benign prostatic hyperplasia protective effect through regulating inflammatory responses, reducing oxidative stress and anti-proliferative. *J Ethnopharmacol.* 2014; 157:105–13. doi: [10.1016/j.jep.2014.09.025](https://doi.org/10.1016/j.jep.2014.09.025) PMID: [25260581](https://pubmed.ncbi.nlm.nih.gov/25260581/)
10. Sauver JL, St. Jacobson DJ, McGree ME, Gorman CJ, Lieber MM, Jacobsen SJ. Longitudinal association between prostatitis and development of benign prostatic hyperplasia. *Urology.* 2008; 71(3):475–9. doi: [10.1016/j.urology.2007.11.155](https://doi.org/10.1016/j.urology.2007.11.155) PMID: [18342190](https://pubmed.ncbi.nlm.nih.gov/18342190/)
11. Nickel JC, Downey J, Young I, Boag S. Asymptomatic inflammation and/or infection in benign prostatic hyperplasia. *BJU Int.* 1999; 84(9):976–81. PMID: [10571623](https://pubmed.ncbi.nlm.nih.gov/10571623/)
12. Golomb E, Rosenzweig N, Eilam R, Abramovici A. Spontaneous hyperplasia of the ventral lobe of the prostate in aging genetically hypertensive rats. *J Androl.* 2000; 21(1):58–64. PMID: [10670520](https://pubmed.ncbi.nlm.nih.gov/10670520/)
13. Yamashita M, Zhang X, Shiraishi T, Uetsuki H, Takechi Y. Determination of percent area density of epithelial and stromal components in development of prostatic hyperplasia in spontaneously hypertensive rats. *Urology.* 2003; 61(2):484–9. PMID: [12597986](https://pubmed.ncbi.nlm.nih.gov/12597986/)
14. Yono M, Yamamoto Y, Yoshida M, Ueda S, Latifpour J. Effects of doxazosin on blood flow and mRNA expression of nitric oxide synthase in the spontaneously hypertensive rat genitourinary tract. *Life Sci.* 2007; 81(3):218–22. PMID: [17574276](https://pubmed.ncbi.nlm.nih.gov/17574276/)
15. Saito M, Tsounapi P, Oikawa R, Shimizu S, Honda M, Sejima T, et al. Prostatic ischemia induces ventral prostatic hyperplasia in the SHR; possible mechanism of development of BPH. *Sci Rep.* 2014; 4:3822. doi: [10.1038/srep03822](https://doi.org/10.1038/srep03822) PMID: [24448152](https://pubmed.ncbi.nlm.nih.gov/24448152/)
16. Zarifpour M, Nomiya M, Sawada N, Andersson KE. Protective effect of tadalafil on the functional and structural changes of the rat ventral prostate caused by chronic pelvic ischemia. *Prostate.* 2015; 75(3):233–41. doi: [10.1002/pros.22909](https://doi.org/10.1002/pros.22909) PMID: [25327615](https://pubmed.ncbi.nlm.nih.gov/25327615/)
17. Kawabe K, Yoshida M, Homma Y. Silodosin, a new alpha1A-adrenoceptor-selective antagonist for treating benign prostatic hyperplasia: results of a phase III randomized, placebo-controlled, double-blind study in Japanese men. *BJU Int.* 2006; 98(5):1019–24. PMID: [16945121](https://pubmed.ncbi.nlm.nih.gov/16945121/)
18. Pinggera GM, Mitterberger M, Pallwein L, Schuster A, Herwig R, Frauscher F, et al. alpha-Blockers improve chronic ischaemia of the lower urinary tract in patients with lower urinary tract symptoms. *BJU Int.* 2008; 101(3):319–24. PMID: [18005199](https://pubmed.ncbi.nlm.nih.gov/18005199/)
19. Nakamura H, Itakura C. Influence of terazosin on the epithelium of prostate gland of spontaneously hypertensive rats. *J Toxicol Pathol.* 1992; 5(1):101–4.
20. McGrath JC, Drummond GB, McLachlan EM, Kilkenny C, Wainwright CL. Guidelines for reporting experiments involving animals: the ARRIVE guidelines. *Br J Pharmacol.* 2010; 160(7):1573–6. doi: [10.1111/j.1476-5381.2010.00873.x](https://doi.org/10.1111/j.1476-5381.2010.00873.x) PMID: [20649560](https://pubmed.ncbi.nlm.nih.gov/20649560/)
21. Inoue S, Saito M, Tsounapi P, Dimitriadis F, Ohmasa F, Kinoshita Y, et al. Effect of silodosin on detrusor overactivity in the male spontaneously hypertensive rat. *BJU Int.* 2012; 110(2 Pt 2):E118–24. doi: [10.1111/j.1464-410X.2011.10814.x](https://doi.org/10.1111/j.1464-410X.2011.10814.x) PMID: [22146017](https://pubmed.ncbi.nlm.nih.gov/22146017/)
22. Shimizu S, Tsounapi P, Shimizu T, Honda M, Inoue K, Dimitriadis F, et al. Lower urinary tract symptoms, benign prostatic hyperplasia/benign prostatic enlargement and erectile dysfunction: are these conditions related to vascular dysfunction? *Int J Urol.* 2014; 21(9):856–64. doi: [10.1111/iju.12501](https://doi.org/10.1111/iju.12501) PMID: [24930630](https://pubmed.ncbi.nlm.nih.gov/24930630/)

23. Schilit S, Benzeroual KE. Silodosin: a selective alpha1A-adrenergic receptor antagonist for the treatment of benign prostatic hyperplasia. *Clin Ther.* 2009; 31(11):2489–502. doi: [10.1016/j.clinthera.2009.11.024](https://doi.org/10.1016/j.clinthera.2009.11.024) PMID: [20109995](https://pubmed.ncbi.nlm.nih.gov/20109995/)
24. Goi Y, Tomiyama Y, Nomiya M, Sagawa K, Aikawa K, Yamaguchi O. Effects of silodosin, a selective alpha1A-adrenoceptor antagonist, on bladder blood flow and bladder function in a rat model of atherosclerosis induced chronic bladder ischemia without bladder outlet obstruction. *J Urol.* 2013; 190(3):1116–22. doi: [10.1016/j.juro.2013.03.110](https://doi.org/10.1016/j.juro.2013.03.110) PMID: [23545103](https://pubmed.ncbi.nlm.nih.gov/23545103/)
25. Andersson KE, Lepor H, Wyllie MG. Prostatic alpha 1-adrenoceptors and uroselectivity. *Prostate.* 1997; 30(3):202–15. PMID: [9122046](https://pubmed.ncbi.nlm.nih.gov/9122046/)
26. Morelli A, Sarchielli E, Comeglio P, Filippi S, Mancina R, Gacci M, et al. Phosphodiesterase type 5 expression in human and rat lower urinary tract tissues and the effect of tadalafil on prostate gland oxygenation in spontaneously hypertensive rats. *J Sex Med.* 2011; 8(10):2746–60. doi: [10.1111/j.1743-6109.2011.02416.x](https://doi.org/10.1111/j.1743-6109.2011.02416.x) PMID: [21812935](https://pubmed.ncbi.nlm.nih.gov/21812935/)
27. Atawia RT, Mosli HH, Tadros MG, Khalifa AE, Mosli HA, Abdel-Naim AB. Modulatory effect of silymarin on inflammatory mediators in experimentally induced benign prostatic hyperplasia: emphasis on PTEN, HIF-1alpha, and NF-kappaB. *Naunyn Schmiedeberg Arch Pharmacol.* 2014; 387(12):1131–40. doi: [10.1007/s00210-014-1040-y](https://doi.org/10.1007/s00210-014-1040-y) PMID: [25164963](https://pubmed.ncbi.nlm.nih.gov/25164963/)
28. Kramer G, Mitteregger D, Marberger M. Is benign prostatic hyperplasia (BPH) an immune inflammatory disease? *Eur Urol.* 2007; 51(5):1202–16. PMID: [17182170](https://pubmed.ncbi.nlm.nih.gov/17182170/)
29. Tuxhorn JA, Ayala GE, Smith MJ, Smith VC, Dang TD, Rowley DR. Reactive stroma in human prostate cancer: induction of myofibroblast phenotype and extracellular matrix remodeling. *Clin Cancer Res.* 2002; 8(9):2912–23. PMID: [12231536](https://pubmed.ncbi.nlm.nih.gov/12231536/)
30. Hennenberg M, Schreiber A, Ciotkowska A, Rutz B, Waidelich R, Strittmatter F, et al. Cooperative effects of EGF, FGF, and TGF-beta1 in prostate stromal cells are different from responses to single growth factors. *Life Sci.* 2015; 123:18–24. doi: [10.1016/j.lfs.2014.12.006](https://doi.org/10.1016/j.lfs.2014.12.006) PMID: [25529149](https://pubmed.ncbi.nlm.nih.gov/25529149/)
31. Quiles MT, Arbos MA, Fraga A, de Torres IM, Reventos J, Morote J. Antiproliferative and apoptotic effects of the herbal agent *Pygeum africanum* on cultured prostate stromal cells from patients with benign prostatic hyperplasia (BPH). *Prostate.* 2010; 70(10):1044–53. doi: [10.1002/pros.21138](https://doi.org/10.1002/pros.21138) PMID: [20503393](https://pubmed.ncbi.nlm.nih.gov/20503393/)
32. Kyprianou N, Litvak JP, Borkowski A, Alexander R, Jacobs SC. Induction of prostate apoptosis by doxazosin in benign prostatic hyperplasia. *J Urol.* 1998; 159(6):1810–5. PMID: [9598465](https://pubmed.ncbi.nlm.nih.gov/9598465/)
33. Glassman DT, Chon JK, Borkowski A, Jacobs SC, Kyprianou N. Combined effect of terazosin and finasteride on apoptosis, cell proliferation, and transforming growth factor-beta expression in benign prostatic hyperplasia. *Prostate.* 2001; 46(1):45–51. PMID: [11170131](https://pubmed.ncbi.nlm.nih.gov/11170131/)
34. Chon JK, Borkowski A, Partin AW, Isaacs JT, Jacobs SC, Kyprianou N. Alpha 1-adrenoceptor antagonists terazosin and doxazosin induce prostate apoptosis without affecting cell proliferation in patients with benign prostatic hyperplasia. *J Urol.* 1999; 161(6):2002–8. PMID: [10332490](https://pubmed.ncbi.nlm.nih.gov/10332490/)
35. Paick JS, Cho MC, Song SH, Kim SW, Ku JH. Impacts of the quinazoline-based alpha1-antagonist, terazosin, and of the sulfonamide derivative, tamsulosin, on serum prostate-specific antigen and prostate volume. *J Korean Med Sci.* 2008; 23(3):509–13. doi: [10.3346/jkms.2008.23.3.509](https://doi.org/10.3346/jkms.2008.23.3.509) PMID: [18583890](https://pubmed.ncbi.nlm.nih.gov/18583890/)
36. Roehrborn CG. Three months' treatment with the alpha1-blocker alfuzosin does not affect total or transition zone volume of the prostate. *Prostate Cancer Prostatic Dis.* 2006; 9(2):121–5. PMID: [16304557](https://pubmed.ncbi.nlm.nih.gov/16304557/)
37. McConnell JD, Roehrborn CG, Bautista OM, Andriole GL Jr., Dixon CM, Kusek JW, et al. The long-term effect of doxazosin, finasteride, and combination therapy on the clinical progression of benign prostatic hyperplasia. *N Engl J Med.* 2003; 349(25):2387–98. PMID: [14681504](https://pubmed.ncbi.nlm.nih.gov/14681504/)
38. Roehrborn CG, Siami P, Barkin J, Damiao R, Major-Walker K, Nandy I, et al. The effects of combination therapy with dutasteride and tamsulosin on clinical outcomes in men with symptomatic benign prostatic hyperplasia: 4-year results from the CombAT study. *Eur Urol.* 2010; 57(1):123–31. doi: [10.1016/j.eururo.2009.09.035](https://doi.org/10.1016/j.eururo.2009.09.035) PMID: [19825505](https://pubmed.ncbi.nlm.nih.gov/19825505/)