

CASE REPORT

Desmoplastic ameloblastoma with osteoplasia: Review of literature with a case report

Vindhya Savithri, Mahija Janardhanan, Rakesh Suresh, RB Vinod Kumar

Department of Oral Pathology and Microbiology, Amrita School of Dentistry, Kochi, India

Address for correspondence:

Dr. Vindhya Savithri,
Department of Oral Pathology and Microbiology,
Amrita School of Dentistry, Kochi - 682 041,
Kerala, India. E-mail: vinna7@gmail.com

ABSTRACT

Desmoplastic ameloblastoma (DA) is a relatively rare histological variant of ameloblastoma with specific clinical, radiological, and histological features. This tumor is more commonly seen in the anterior region of jaws as a mixed radiopaque-radiolucent lesion resembling benign fibro-osseous lesions. Histologically, DA is characterized by small nests and strands of “compressed” odontogenic epithelium supported by pronounced collagenized stroma. Metaplastic bone formation has been reported in few cases. This report describes a lesion in the left anterior maxilla of a young female patient.

Key words: Ameloblastoma, desmoplasia, osteoplasia

INTRODUCTION

Ameloblastoma is the second most common odontogenic tumor. It arises from odontogenic epithelium and is known for its distinct aggressive clinical behavior and characteristic histologic picture. Based on clinical and radiographic characteristics, histopathology, behavioral and prognostic aspects, the subtypes of ameloblastoma are classic solid/multicystic, unicystic, peripheral and desmoplastic types.^[1] The first detailed report in English literature on desmoplastic ameloblastoma (DA) was given by Eversole in 1984, who called it an “ameloblastoma with pronounced desmoplasia.”^[2]

DA is a rare variant of ameloblastoma accounting for approximately 4-13% of ameloblastomas.^[3] It is characterized by an unusual histomorphology, including extensive stromal collagenization or desmoplasia. A characteristic feature is an almost equal distribution in location between the maxilla and mandible. Radiologically, the desmoplastic variant exhibits atypical and varied radiographic features such as: Localized irregular multilocular radiolucency with indistinct borders, or a mixed radiopaque-radiolucent appearance with ill-defined margins similar to fibro-osseous lesion, or a massive expansile osteolytic lesion with honeycomb, mottled or multilocular appearance.^[4] Tooth displacement is a common feature. DA may

be defined as a benign but locally invasive variant consisting of proliferating, irregular, often bizarrely shaped islands and cords of odontogenic epithelium of varying sizes embedded in a desmoplastic connective tissue stroma. Formation of metaplastic bone trabeculae (osteoplasia) rimmed by active osteoblasts has been described in a few cases.^[5] A possible transitional form of DA, showing microscopic features of desmoplastic variant together with areas of classical follicular/plexiform ameloblastoma has been described as a “hybrid lesion.”^[6]

CASE REPORT

A 26-year-old female reported with a swelling in relation to the upper front teeth. The swelling was slow in growth and present since 4 months. She had also noticed a slight downward movement of the affected teeth and had mild pain. On examination, a bony hard swelling was seen in relation to 21, 22 and 23 on the buccal aspect measuring about 2.5 cm × 1.5 cm and extending into the palate. It was non-tender. Grade I mobility of 21 and 22 was also noticed.

Radiographs revealed the presence of irregular radiolucencies with faint radio-opacities in the periapical region of 22 and 23. Lamina dura of the teeth was hazy and teeth were seen to be displaced [Figure 1]. A provisional diagnosis of benign fibro-osseous lesion was made and an incisional biopsy was done.

Both hard-tissue and soft-tissue were received. The specimens showed few irregular epithelial islands in a densely fibrous connective stroma. The islands consisted of peripheral cuboidal cells and central spindle cells. Some of the islands showed cystic degeneration [Figure 2]. Extensive desmoplasia

Access this article online**Quick Response Code:****Website:**

www.jomfp.in

DOI:

10.4103/0973-029X.119784

was seen throughout the stroma compressing the epithelial islands [Figure 3]. Areas of osseous metaplasia with active osteoblasts were also noted [Figure 4]. With the above picture, a diagnosis of DA with osteoplasia was made.

DISCUSSION

Clinically, DA may occur in all age groups with more cases in the 4th to 5th decade. There is no gender predilection and is seen equally in males and females.^[7] In this aspect, it is comparable with the conventional ameloblastoma. DA is reported to occur in the anterior or premolar region of either maxilla or mandible. This is in contrast to the conventional ameloblastoma which is found predominantly in the posterior region of mandible. Usually, the patient's first symptom is a painless swelling. Involved teeth may be displaced with cortical plate expansion. The size of DA is mostly smaller than other types of ameloblastoma.^[7] This could be attributed to the fact that it is detected earlier because of its anterior location. A case of peripheral DA has also been reported recently.^[8] The clinical presentation in our case falls in the same category as generally accepted.

The radiographic features of DA also differ from the conventional ameloblastoma. A wide range of appearance from radiolucency to radiolucency with flecks of opacity to mixed radiolucent/radio-opaque has been reported. Conventional ameloblastoma usually presents as a well-defined unilocular/multilocular radiolucency. Again, the borders of DA are usually poorly defined.^[9] DA usually infiltrates into marrow spaces and surrounding non-neoplastic bone without a fibrous capsule.^[10] Also, osteoplastic bone may be produced by the lesion. The unique radiographic picture seen is thought to be due to its infiltrative nature. The presence of osteoplastic bone can also present similarly. The unconventional clinical site along with the mixed radiolucent/radio-opaque picture, in our patient, led us to the diagnosis of a benign fibro-osseous lesion.

Histological features consisted of proliferating, irregularly shaped islands and cords of odontogenic epithelium of varying sizes embedded in a desmoplastic connective tissue stroma. The tumor islands may show a pointed, stellate or "kite-like" appearance. The epithelial cells at the periphery of the islands are cuboidal and occasionally show hyperchromatic nuclei.

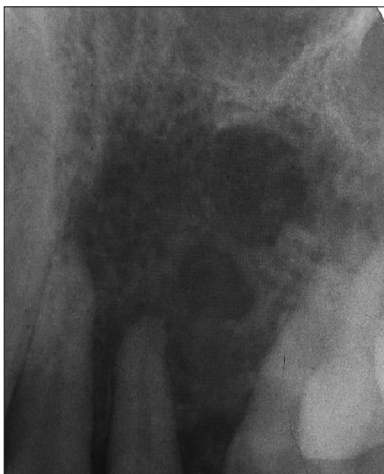

Figure 1: Intra-oral periapical radiograph showing irregular radiolucencies with faint radio-opacities

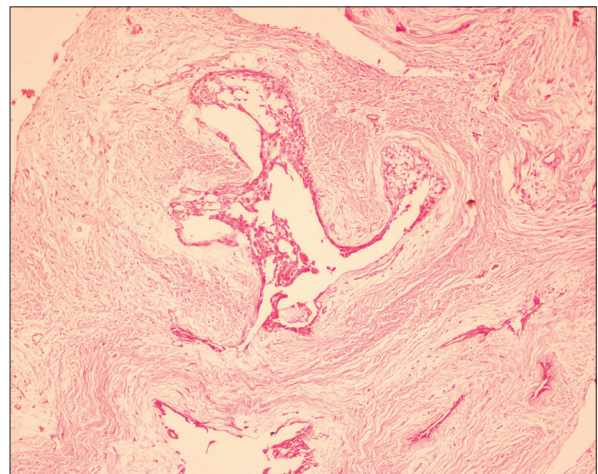


Figure 2: Odontogenic islands with cystic degeneration (H&E stain, x100)

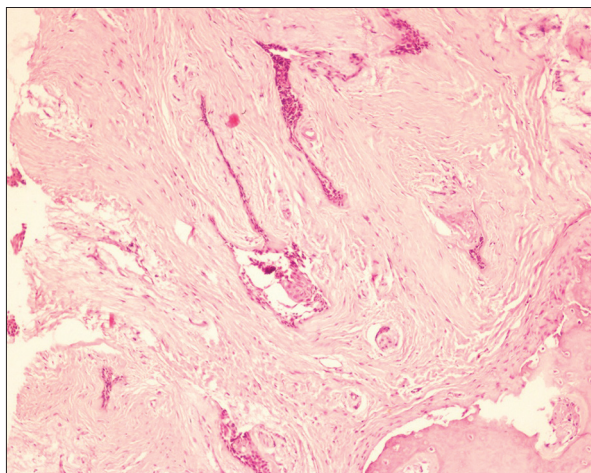


Figure 3: Desmoplasia compressing the tumor islands (H&E stain, x100)

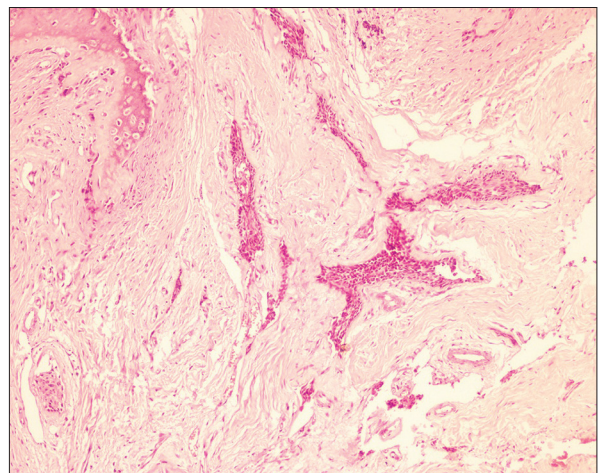


Figure 4: Osseous metaplasia with active osteoblasts (H&E stain, x100)

Columnar cells demonstrating reversed nuclear polarity are rarely conspicuous although some islands may show ameloblast-like cells peripherally.^[3] The center of the islands may contain spindle-shaped or squamoid epithelial cells. DA exhibiting granular cell transformation in some of the tumor cells has been reported.^[11] Furthermore, a case with associated follicular, plexiform, acanthomatous and basaloid changes has been documented.^[12] True glandular differentiation with mucus cells has been reported in the tumor islands.^[10,13] Cystic degeneration within the tumor has also been described.^[14] In our case, few islands with kite-like appearance with spindle cells in the interior of the island and stromal desmoplasia were noted.

Extensive stromal desmoplasia is a striking finding with a tendency to squeeze or compress the odontogenic islands at the periphery. The mechanism of desmoplasia is not understood even after two decades. Various immunohistochemical studies have reported DA tumor cells as showing variable expression of S-100 protein and desmin, high expression of caspase-3 and Fas, decreased expression of cytokeratin 19 and high expression of p63.^[15,16] Intense staining for collagen Type IV adjacent to tumor islands has been noted in DA.^[3] This indicates active synthesis of extracellular matrix proteins and that the stroma is not scar tissue. Marked expression of transforming growth factor- β has been demonstrated and it may play a part in the desmoplasia.^[17] It has also been suggested that it may indicate a maturation process and lesions in the anterior region may mature faster, hence the finding of desmoplasia.^[15] Oxytalan fibers have been identified in the stromal tissue.^[14,18] This finding indicates that this tumor may be periodontal in origin. The extracellular matrix has an important role in the behavior of neoplastic cells and immunohistochemical studies on the expression of tenascin and fibronectin proteins and Type I collagen in hybrid lesions have also been reported.^[19] Both tenascin and fibronectin showed positive staining around the conventional follicles rather than the desmoplastic areas. This indicates the greater aggressive potential of conventional follicular ameloblastoma as compared to DA as tenascin has been observed in unstable environments like neoplasia. Type I collagen showed intense staining in a fibrillar pattern in DA areas reflecting its high grade in the matrix.

Prominent osteoplasia within the tumor tissue seen in our case has been reported only in eight other cases of DA so far.^[20] The metaplastic bony trabeculae varied from woven to mature bone, which contained osteocytes and were lined by plump active osteoblasts. Remnants of non-neoplastic bone often seem to remain in the tumor tissue. Studies have been done to find whether the bone found is new bone or mature bone. Fibrous bone can be recognized using Masson-trichrome staining.^[20] The presence of peripheral un-calcified fibrous bone gave the impression of newly forming bone rather than destroyed trabecular bone. Hence it can be suggested that if the desmoplasia is caused by tumor cell stimulation of stromal fibroblasts, then that stimuli could also affect another cell type, i.e., osteoblasts for formation of new bone (osteoplasia).^[13]

CONCLUSION

The biologic behavior of the lesion is still debatable. Conflicting reports are available regarding the recurrence because of paucity of adequate samples.^[3,7] The radiographic picture suggests an infiltrative process with the propensity to recur and the stromal reaction may be viewed as a defensive response of the host to the aggressive tumor. Furthermore, the lesions in maxilla are close to many vital structures and the thin cortical bone is a weak barrier and the tumor usually infiltrates into marrow spaces.^[21] Thus, a clear-cut border may be difficult to identify. The radiological and histological findings of poor encapsulation and ill-defined borders warrants a long-term follow-up. A radical approach to its treatment is recommended as in a case of conventional ameloblastoma.

REFERENCES

1. Reichert PA, Philipsen HP. Benign Neoplasms and tumor-like lesions arising from the odontogenic apparatus showing odontogenic epithelium with mature fibrous stroma, without ectomesenchyme. In: *Odontogenic Tumors and Allied Lesions*. London: Quintessence Publishing Co., Ltd. 2004. p. 41.
2. Eversole LR, Leider AS, Hansen LS. Ameloblastomas with pronounced desmoplasia. *J Oral Maxillofac Surg* 1984;42:735-40.
3. Philipsen HP, Reichart PA, Takata T. Desmoplastic ameloblastoma (including "hybrid" lesion of ameloblastoma). Biological profile based on 100 cases from the literature and own files. *Oral Oncol* 2001;37:455-60.
4. Laxmana AR, Gogineni SB, Thomas PS, Shetty SR. Desmoplastic ameloblastoma-a report of two clinical cases. *Braz J Oral Sci* 2010;9:137-41.
5. Effiom OA, Odukoya O. Desmoplastic ameloblastoma: Analysis of 17 Nigerian cases. *Oral Surg Oral Med Oral Pathol Oral Radiol Endod* 2011;111:e27-31.
6. Waldron CA, el-Mofty SK. A histopathologic study of 116 ameloblastomas with special reference to the desmoplastic variant. *Oral Surg Oral Med Oral Pathol* 1987;63:441-51.
7. Sun ZJ, Wu YR, Cheng N, Zwahlen RA, Zhao YF. Desmoplastic ameloblastoma-A review. *Oral Oncol* 2009;45:752-9.
8. Curran AE, Byerly PD. Peripheral desmoplastic ameloblastoma: Report of a rare case. *J Oral Maxillofac Surg* 2008;66:820-5.
9. Kaffe I, Buchner A, Taicher S. Radiologic features of desmoplastic variant of ameloblastoma. *Oral Surg Oral Med Oral Pathol* 1993;76:525-9.
10. Takata T, Miyauchi M, Ito H, Ogawa I, Kudo Y, Zhao M, et al. Clinical and histopathological analyses of desmoplastic ameloblastoma. *Pathol Res Pract* 1999;195:669-75.
11. Ashman SG, Corio RL, Eisele DW, Murphy MT. Desmoplastic ameloblastoma. A case report and literature review. *Oral Surg Oral Med Oral Pathol* 1993;75:479-82.
12. Hirota M, Aoki S, Kawabe R, Fujita K. Desmoplastic ameloblastoma featuring basal cell ameloblastoma: A case report. *Oral Surg Oral Med Oral Pathol Oral Radiol Endod* 2005;99:160-4.
13. Angadi PV, Kale A, Hallikerimath S, Kotrashetti V, Mane D, Bhatt P, et al. 'Hybrid' desmoplastic ameloblastoma: An unusual case report with immunohistochemical investigation for TGF- β and review of literature. *Eastern J Med* 2011;16:9-17.

14. Kawai T, Kishino M, Hiranuma H, Sasai T, Ishida T. A unique case of desmoplastic ameloblastoma of the mandible: Report of a case and brief review of the English language literature. *Oral Surg Oral Med Oral Pathol Oral Radiol Endod* 1999;87:258-63.
15. Sivapathasundharam B, Einstein A, Syed RI. Desmoplastic ameloblastoma in Indians: Report of five cases and review of literature. *Indian J Dent Res* 2007;18:218-21.
16. Yazdi I, Seyedmajidi M, Foroughi R. Desmoplastic ameloblastoma (a hybrid variant): Report of a case and review of the literature. *Arch Iran Med* 2009;12:304-8.
17. Takata T, Miyauchi M, Ogawa I, Kudo Y, Takekoshi T, Zhao M, *et al.* Immunoexpression of transforming growth factor beta in desmoplastic ameloblastoma. *Virchows Arch* 2000;436:319-23.
18. Kishino M, Murakami S, Fukuda Y, Ishida T. Pathology of the desmoplastic ameloblastoma. *J Oral Pathol Med* 2001;30:35-40.
19. dos Santos JN, De Souza VF, Azevêdo RA, Sarmiento VA, Souza LB. "Hybrid" lesion of desmoplastic and conventional ameloblastoma: Immunohistochemical aspects. *Braz J Otorhinolaryngol* 2006;72:709-13.
20. Itoh Y, Nakahara H, Itoh R, Ito A, Satou T. Osteoplastic ameloblastoma: A case report and literature review. *Oral Surg Oral Med Oral Pathol Oral Radiol* 2012;113:e23-8.
21. Pillai RS, Ongole R, Ahsan A, Radhakrishnan RA, Pai KM. Recurrent desmoplastic ameloblastoma of the maxilla: A case report. *J Can Dent Assoc* 2004;70:100-4.

How to cite this article: Savithri V, Janardhanan M, Suresh R, Kumar RV. Desmoplastic ameloblastoma with osteoplasia: Review of literature with a case report. *J Oral Maxillofac Pathol* 2013;17:298-301.

Source of Support: Nil. **Conflict of Interest:** None declared.