



Case Report

Clinical presentation and management of hypophysitis: An observational study of case series

Marouan Karrou¹, Salma Benyakhlef¹, Achwak Alla¹, Najoua Messaoudi¹, Asmae Oulad Amar², Siham Rouf¹, Imane Kamaoui², Nouredine Oulali³, Faycal Moufid³, Naima Abda⁴, Hanane Latrech¹

Departments of ¹Endocrinology-Diabetology and Nutrition, ²Radiology, ³Neurosurgery and ⁴Epidemiology, Medical School, Mohammed VI University Hospital Centre, Oujda, Oujda-Angad, Morocco.

E-mail: *Marouan Karrou - marouan.karrou@gmail.com; Salma Benyakhlef - salmabenyakhlef1@gmail.com; Achwak Alla - allaachwak02@gmail.com; Najoua Messaoudi - najouamessaoudi93@gmail.com; Asmae Oulad Amar - asmaeouladamar@gmail.com; Siham Rouf - roufsiham@gmail.com; Imane Kamaoui - ikamaoui@gmail.com; Nouredine Oulali - noureddine_oulali@yahoo.fr; Faycal Moufid - moufidnch@hotmail.fr; Naima Abda - abda.naima@yahoo.com; Hanane Latrech - hlatrech@hotmail.fr



*Corresponding author:

Marouan Karrou,
Department of Endocrinology-
Diabetology and Nutrition,
Medical School, Mohammed
VI University Hospital Centre,
Oujda, Oujda-Angad, Morocco.
marouan.karrou@gmail.com

Received : 08 May 2021

Accepted : 24 May 2021

Published : 28 June 2021

DOI

10.25259/SNI_454_2021

Quick Response Code:



ABSTRACT

Background: Hypophysitis is described as a rare chronic inflammatory affection of the pituitary gland. However, to date, its pathogenesis has not been completely cleared up. Clinical features are polymorphic, including symptoms related to inflammatory compression and/or hypopituitarism. Laboratory tests determine hormone deficiencies orientating replacement therapy's protocol. MRI of the hypothalamic-pituitary region is crucial in exhibiting major radiological signs such as pituitary homogeneous enlargement and gland stalk's thickening. The etiological diagnosis is still challenging without affecting the management strategy. Corticosteroids have widely been used but a close follow-up without any treatment has also been approved.

Case Description: In this report, seven patients with hypophysitis have been collected over a period of 6 years. The average age of our patients was 32.1 years ± 11.8 with a female predominance (71.4%). Panhypopituitarism was objective in 42.9% of cases, a combined deficiency of the hypothalamic-pituitary thyroid, adrenal and gonadal axes in 28.6% of cases. A central diabetes insipidus was noted in 42.9% of the patients. Idiopathic hypophysitis was the most common etiology. The use of long course corticosteroids was required in 28.6% when compressive signs were reported.

Conclusion: Hypophysitis remains a rare disease with nonspecific clinical and radiological patterns. Autoimmune origin seems to be the most frequent etiology. No guidelines have been established for hypophysitis management and the evolution is still unpredictable.

Keywords: Central diabetes insipidus, Corticosteroids, Hormone replacement, Hypophysitis, Hypopituitarism

INTRODUCTION

Hypophysitis is described as a rare chronic inflammatory affection of the pituitary gland, which may then damage the pituitary tissue and be responsible for temporary or permanent endocrine disorders.^[6] However, to date, its pathophysiological mechanism has not been completely cleared up.

Hypophysitis classification is mainly based on histological and etiological patterns. Therefore, four histological types have been described, starting with the granulomatous hypophysitis

This is an open-access article distributed under the terms of the Creative Commons Attribution-Non Commercial-Share Alike 4.0 License, which allows others to remix, tweak, and build upon the work non-commercially, as long as the author is credited and the new creations are licensed under the identical terms.

©2021 Published by Scientific Scholar on behalf of Surgical Neurology International

described in 1917,^[29] then the lymphocytic or autoimmune hypophysitis as the most frequent variant,^[13] along with three other subtypes; depending on the pituitary region involvement. More recently, Folkerth *et al.*^[11] described the xanthomatous hypophysitis followed by the latest new reported type which has been described regarding IgG4-related hypophysitis.^[2,5]

Hypophysitis clinical features are polymorphic usually related to sella and parasella compression illustrated clinically by headache, nausea, vomiting and visual disturbances, pituitary hormone deficiencies, or diabetes insipidus.^[12]

Several radiological signs may be very useful for diagnosis discussion, especially homogeneous pituitary enlargement with intense contrast enhancement and loss of bright spot of the neurohypophysis on T1-weighted images.^[3]

Hypophysitis management revolves around the necessity of precocious hormone replacement therapy, the decision of corticosteroid treatment initiation, and the use of decompression surgery once we have the indication.

In this report, we describe seven cases of hypophysitis diagnosed through clinical symptoms and imaging patterns without pathology examination, with good evolution under replacement therapy and corticosteroids in one case. Regression of hypophysitis clinical and radiological signs was observed in most of our patients even without corticosteroids therapy.

CLINICAL AND PARACLINICAL EVALUATION

All of the patients included in this study [Table 1] were over the age of 18 years old; followed up in our center between July 2014 and January 2021, with the diagnosis of hypophysitis. They all had a complete updated medical record according

to the data exploitation features. Patients who did not match with those criteria were excluded from the study. The mean age of the cases (\pm SD) was 32.1 years \pm 11.8, with 71.4% of women, and the diagnosis of hypophysitis was based on the analysis of all the data from the clinical, biological, and radiological assessment. Symptoms were variable; including headache, visual acuity disorders, nausea, and vomiting. Laboratory tests evaluated cortisol, gonadotropins, prolactin, thyroid hormone levels, and insulin-like growth factor 1. Imaging signs of hypophysitis were assessed by magnetic resonance imaging (MRI) of the hypothalampituitary region using sagittal and coronal T1-T2-weighted sections with gadolinium enhancement. Many radiological findings were suggestive for our diagnosis counting gland enlargement; and increased stalk thickening with the absence of posterior pituitary bright spot traduced clinically by the presence of diabetes insipidus.

RESULTS

Each patient underwent a clinical examination, besides the evaluation of both anterior and posterior pituitary functions. Patients consulted for signs of sella compression in 85.7% of cases (headache: 85.7%, vomiting: 71.4%, and visual disturbance in 57.1%) and a polyuria-polydipsia syndrome (PPS) in 42.9% of the cases.

Endocrine assessment of our patients showed a corticotropic, thyrotropic, and gonadotropic axis deficit. In 71%, the somatotropic axis was deficient in 28% of cases, however, hyperprolactinemia was observed in one patient. A panhypopituitarism in 42.9% of cases. A central diabetes insipidus was observed in 42.9% of the patients.

The most observed radiological features are homogeneous and symmetric pituitary enlargement with intense contrast enhancement in 57.1% [Figure 1], a loss of neurohypophysis bright spot without any involvement of the anterior pituitary in

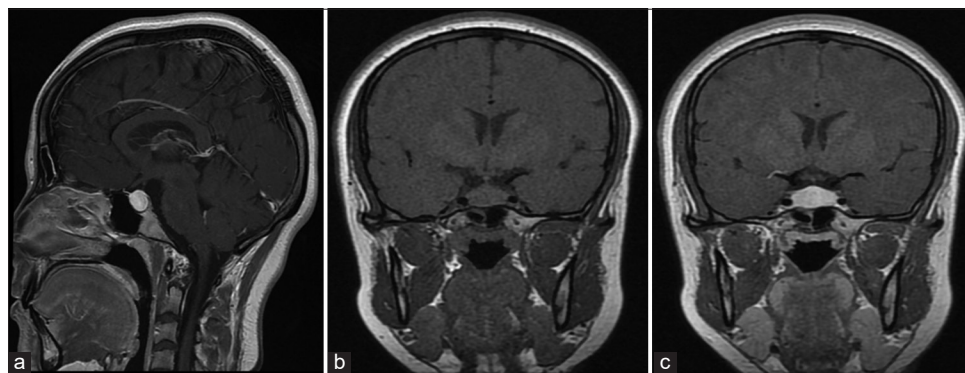


Figure 1: Hypothalamic-pituitary MRI of patient number 1 before corticosteroid treatment, showing a homogeneous hypertrophy of the pituitary gland with high contrast after gadolinium injection. (a) Sagittal section SE T1 after gadolinium injection (swelling of the antehypophyseal gland with homogeneous enhancement after contrast). (b and c) Pituitary dynamic sequence in coronal section SE T1 before (b) and after (c) gadolinium injection.

Table 1: Clinical and endocrinological summary of seven hypophysitis patients.

	Case N°1	Case N°2	Case N°3	Case N°4	Case N°5	Case N°6	Case N°7
Gender	F	M	F	M	F	F	F
Age	21	47	23	21	32	49	32
Medical history	None	Tubercular pericarditis	Hashimoto's thyroiditis	None	Recent childbirth	Lupus	Coeliac disease
Signs and symptoms	Signs of sella compression	Signs of sella compression + PPS + anterior hypopituitarism	Signs of sella compression + PPS	PPS	Signs of sella compression + anterior hypopituitarism	Signs of sella compression + anterior hypopituitarism	Signs of sella compression + anterior hypopituitarism
Adenohypophysis assessment:	8 AM Cortisol: 1.9	8 AM Cortisol: 2.5	8 AM Cortisol: 13.6	8 AM Cortisol: 14.9	8 AM Cortisol: 0.0	8 AM Cortisol: 5.8	8 AM Cortisol: 3.8
8 AM Cortisola:µg/dl	8 AM ACTH: 7.3	8 AM ACTH: 11.5	8 AM ACTH: NA	8 AM ACTH: NA	8 AM ACTH: 8.3	8 AM ACTH: 9.2	8 AM ACTH: 8.1
8 AM ACTHb: pg/ml	TSH: 0.1	TSH: 0.11	TSH: 2.02	TSH: 1.54	TSH: 0.10	TSH: 0.2	TSH: 0.3
TSHc: µUI/l	FT4: 9	FT4: 10	FT4: 16	FT4: 14	FT4: 8	FT4: 6	FT4: 9.34
FT4c: pmol/l	FSH: 0.92	FSH: 0.35	FSH: 4.98	FSH: 1.82	FSH: 0.9	FSH: 0.9	FSH: 1.91
FSHa: mUI/ml	LH: 0.83	LH: 0.01	LH: 7.67	LH: 0.12	LH: 0.03	LH: 0.03	LH: 1.1
LHa: mUI/ml	E2: 25	T: 0.05	E2: 163	E2: 10	E2: 10	E2: 10	E2: 10
E2a: pg/ml	Prolactin: 84	Prolactin: 22	Prolactin: 24	T: 8.89	Prolactin: 2.09	Prolactin: 5.15	Prolactin: 1.8
Ta: ng/ml	IGF-1: 318	IGF-1: 210	IGF-1: 189	Prolactin: 13	IGF-1: 76	IGF-1: 66	IGF-1: 79
Prolactina: ng/ml				IGF-1: NA			
IGF-1d: ng/ml							
Neurohypophysis assessment	Normal	CDI	CDI	CDI	Normal	Normal	Normal
Visual assessment	Normal	Normal	Hyperemia + scotoma	Normal	Normal	Normal	Normal
The probable etiological diagnosis	Lymphocytic	Tubercular	Lymphocytic	Lymphocytic	Lymphocytic	Lymphocytic	Lymphocytic
Treatment	Corticosteroids + PHR	PHR + Desmopressin + antituberculosis drugs	Desmopressin + corticosteroids	Desmopressin	PHR	PHR	PHR
Radiological evolution	Pituitary hypotrophy	Patient died	Loss of hyperintensity of the neurohypophysis on T1-weighted images	Loss of hyperintensity of the neurohypophysis on T1-weighted images	Reduction to normal volume	Reduction to normal volume	Pituitary hypotrophy

ACTH: Adrenocorticotrophic hormone, FSH: Follicle-stimulating hormone, FT4: Free T4 (thyroxine), IGF-1: Insulin-like growth factor 1, LH: Luteinizing hormone, TSH: Thyroid-stimulating hormone, E2: Estradiol, T: Testosterone, PPS: Polyuro-polydipsia syndrome, CDI: Central diabetes insipidus, PHR: Pituitary hormone replacement, NA: Not available. Dosing technique = a: Microparticles immunology by chemiluminescence, b: Chemiluminescence, c: Electrochemiluminescence, d: Chemiluminescence CLIA Diasorin

28.6% of cases. A pituitary atrophy was noticed in one patient. All our patients had normal ophthalmology evaluation (visual acuity, dilated fundus examination, and visual field) excepting one patient who had pupillary hyperemia with a scotoma, his MRI showed a homogeneous and symmetrical increase in pituitary volume with intense intake of gadolinium.

The analysis of patients' medical history disclosed an autoimmune disease in 42.9% of cases, a tuberculous

pericarditis, and recent childbirth in 14.3% of cases. The etiological diagnosis was based on clinical, biological, and radiological criteria. A probable lymphocytic hypophysitis was noted in 85.7% of cases (adenohypophysitis in 50%, infundibulo-neurohypophysitis in 33.4%, and panhypophysitis in 16.7%) and tuberculosis in 14.4% of cases. Therapeutic management relied on the etiological diagnosis. The use of a long course corticosteroid therapy was

required in 28.6% of subjects in case of visual disturbances due to compression, in addition to hormone replacement therapy (HYDROCORTISON and LEVOTHYROXIN in 71%, DYDROGESTERON + ESTRADIOL in 28.6%), and desmopressin in patients with central diabetes insipidus (42.85%).

Outcome and follow-up

MRI was performed every 6 months, especially during the first 2 years, to assess the progression of the disease. Pituitary deficiencies were reassessed to adjust hormone dosing and monitor new endocrine disorders. Clinical improvement was achieved in all our patients with a reduction to normal volume in 2 cases (28.57%). The patients were kept under clinical observation. Pituitary hypotrophy was observed in one patient treated with glucocorticoids [Case 1, Figure 2]. In addition, patients with infundibulo-neurohypophysitis still had diabetes insipidus with the same radiological features (loss of hyperintensity of the neurohypophysis on T1-weighted images). However, the same deficiencies mentioned in the initial assessment were observed. Only one patient died of acute respiratory distress related to an uninvestigated lung condition.

DISCUSSION

The chronic inflammation of the pituitary gland is a rare condition, explaining the low number of reported cases in the literature. We have been able to compile seven cases over a period of 6 years, whereas Fedala *et al.* in Algeria reported a total of 15 cases over 16 years^[10] and Imber *et al.* reported 21 cases over 17 years.^[21]

A clear predominance of women was noted by most authors throughout literature.^[19,20] This was also observed in our study which clearly demonstrates the significant female involvement in this pathology.

Literature data^[1,19,21] demonstrated that hypophysitis had an nonspecific clinical presentation including some usual

symptoms related to inflammatory compression of sella and parasella structures or lymphocytic pleocytosis (headache and visual disturbances).^[18] Anterior hypopituitarism was seen in cases of adenohypophysis involvement by the inflammatory process. PPS is also frequently observed due to neurohypophysis involvement,^[1] All these clinical findings were also observed in our study. Furthermore, Honegger *et al.*^[19] observed a weight gain in 18% of cases, which is explained by the autoimmune involvement of the hypothalamic base^[8] leading to a central leptin insensitivity which plays an important role in satiety leading to hyperphagia and obesity.^[28]

Biological assessment of hypophysitis aimed to determine which axes are deficient and to confirm the etiology of the observed central diabetes insipidus responsible of a PPS. The number of axes involved is variously reported in literature depending on the authors. The adrenal axis seems to be the most involved followed by the thyroid axis and then the gonadal axis.^[7] Buxton and Robertson^[4] analyzed the chronology of the anterior pituitary axis involvement to differentiate between hypophysitis and its main differential diagnosis. In fact, in pituitary adenoma, unlike hypophysitis, gonadal and somatotrophic axes are vulnerable,^[19] thus a conserved somatotropin secretion is more in favor of a primary hypophysitis diagnosis.^[19] A pronounced hypopituitarism contrasting with a small sized lesion raises suspicion about hypophysitis,^[4,24] however, a panhypopituitarism or a combined deficit of adrenal, thyroid, and gonadal axes was frequently observed in our study concurring with data of the literature.

The presence of a diabetes insipidus implies an autoimmune involvement of the infundibulo-neurohypophysis specifically the vasopressin-secreting cells, by anti-hypothalamic antibodies.^[8]

MRI was an efficient imaging tool in the assessment of the hypothalamic-pituitary region. Radiological diagnosis of hypophysitis can sometimes tend to be difficult due to the polymorphic nature of the lesions, however, certain findings are of great orientation value. In particular, a pituitary enlargement [Figure 1] often homogenous and symmetric, intense homogenous enhancement postgadolinium on T1WI and T2WI, thickening of the pituitary stalk, and loss of bright spot of the neurohypophysis [Figure 3] on T1WI and potentially on T1 Fat-Sat sequence in the case of an infundibulo-neurohypophysitis.^[3]

The real challenge for an endocrinologist or a radiologist is to differentiate between a hypophysitis and its main differential, the holosellar pituitary adenoma. For that purpose, we use Gutenberg *et al.* radiological score^[16] which takes into account: patient's age (<30 yo), relation to pregnancy, pituitary volume, signal intensity and homogeneity postgadolinium, mass symmetry, presence or

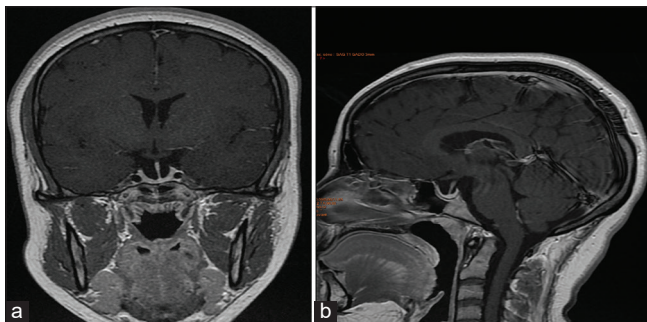


Figure 2: Hypothalamic-pituitary MRI of patient number 1 after corticosteroid therapy showing hypotrophy of the anterior pituitary with arachnocele. (a and b) Dynamic coronal (a) and sagittal (b) section FSE T1 after gadolinium injection.

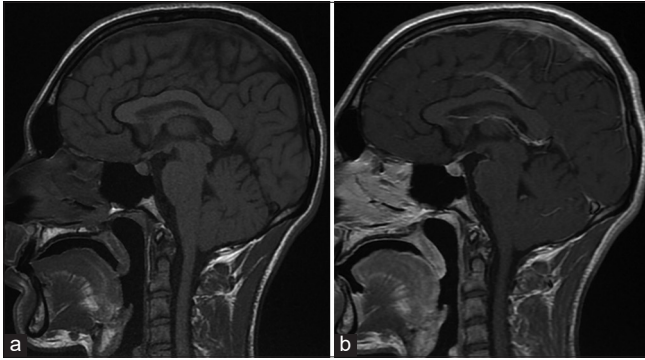


Figure 3: T1 sagittal section of hypothalamic-pituitary MRI before (a) and after (b) gadolinium injection showing the absence of the bright spot of the neurohypophysis (case 4).

loss of posterior pituitary bright spot, and stalk size. These various radiological findings were observed by several authors at different rates, with regard to our study. More specifically, the radiological lesions observed were a pituitary enlargement, intense and homogeneous enhancement postgadolinium injection, pituitary stalk thickening, and loss of bright spot of the neurohypophysis in case of a posterior involvement, whether isolated or associated to an anterior involvement.

Throughout literature, various etiologies were described by different authors. Our study reported a lymphocytic involvement in 80% of cases versus granulomatous involvement in 20% of cases in accordance with data from Guo *et al.* series.^[14]

In the absence of any consensus regarding management, multiple therapeutic protocols were described throughout literature,^[9,17,22] joining clinical, biological, and radiological monitoring to hormone replacement therapy and/or use of desmopressin in case of an associated central diabetes insipidus, or corticosteroids or immunosuppressive therapy and surgery, even radiation therapy in case of refractory hypophysitis. A more conservative approach by Honegger *et al.* was promising (30/76) with MRI regression of the disease in 46% of cases, and a stabilized pituitary size in 27%, with improvement of the adenohypophysis function in 27% of cases and neurohypophysis function in three patients.^[17] In our series of cases, the conservative approach was favored in the absence of compressive signs and to avoid side effects of surgery, especially in young patients and long-term corticosteroid therapy. Multiple corticosteroid therapy protocols were reported throughout literature^[15,17,23-25] with different success and failure rates. Generally speaking, corticosteroid therapy was used in cases of compression signs of neighboring structures. Kristof *et al.*^[24] reported a normalization or an improvement of MRI results in 89% of patients, with a recovery of adenohypophysis function with no or

minimal side effects related to a standardized treatment by glucocorticoids over a 6-week period. In a review of the literature, Lupi *et al.*^[25] found a pituitary mass reduction in 87% of patients utilizing oral glucocorticoids, and 75% of patients receiving IV glucocorticoids. In Honegger *et al.* series,^[17] 32 patients received corticosteroid therapy with a dose varying between 20 and 500 mg/day over a period considerably varied, ranged from 4 days to a year and a follow-up up to 12½ years. A good radiological evolution was noted in in 65.5% of patients. In addition, an endocrine improvement was noticed in 15% of cases. This study^[17] was considered as the first study providing clear evidence of a high recurrence rate in primary hypophysitis after glucocorticoids treatment with a relapse observed in 38% of cases. However, this study showed no correlation between recurrence and the duration of high-dose glucocorticoid therapy. Furthermore, recurrence was not related to the initial dose of glucocorticoids. Corticosteroid therapy was administered to only two patients with visual disturbances at a dose of 1 mg/kg/day for 1 month, followed by gradual dose reduction. Pituitary volume regression was assessed in one patient [Figure 2] while stabilization was observed in the other one. Nonetheless, no endocrine improvement was noticed, which is contradictory of the findings in the previous literature.

In the literature review carried out by Karaca and Kelestimur,^[22] surgical management of hypophysitis was indicated when a mass effect was determined such as visual deterioration, ophthalmoplegia, severe symptoms, an uncertain differential diagnosis, and corticosteroids failure,^[17,21] with a significant clinical and radiological improvement rate between 68% and 100%. The risk of pituitary functions deterioration after surgery had been reported from 11% up to 40% in the literature.^[17,21] The recurrence rate is estimated between 8% and 20% throughout the literature.^[20,21,27] Pituitary surgery like all surgeries, it is not without complications, which in this condition can occur in up to 10% of cases.^[17,21] These complications include postoperative meningitis and rhinorrhea, which require surgical revision. Decompression surgery was not required in our series of patients given the success with corticosteroids along with hormone replacement therapies.

Right after the analysis of this study and the available data in the literature, we found that the evolution of hypophysitis was unpredictable and inconstant. In fact, it could be either favorable (clinical improvement, recovery of pituitary functions, and pituitary volume regression on MRI) under monitoring alone or under treatment, or disadvantageous with the persistence of clinical signs, deterioration of pituitary functions, recurrence, etc. Lupi *et al.* demonstrated in an experimental animal model demonstrating that the evolution

of hypophysitis can lead to an empty sella [Figure 3]. These experimental observations were also observed in humans and more results might be required to assess this scientific hypothesis.^[26]

CONCLUSION

Hypophysitis remains a rare disease with a polymorphic and nonspecific clinical and radiological presentation. Primary damage to the pituitary gland of autoimmune origin seems to be the most frequent etiology and its management should revolve around the need to correct hormonal deficits, and to remove the compression on neighboring structures if present. However, the evolution varies from patient to patient hence the need for multidisciplinary management.

Declaration of patient consent

Patient's consent not required as patients identity is not disclosed or compromised.

Financial support and sponsorship

Nil.

Conflicts of interest

There are no conflicts of interest.

REFERENCES

- Allix I, Rohmer V. Hypophysite: Un spectre étiologique de plus en plus large ? *Ann Endocrinol* 2012;73:S17-25.
- Bando H, Iguchi G, Fukuoka H, Taniguchi M, Yamamoto M, Matsumoto R, *et al.* The prevalence of IgG4-related hypophysitis in 170 consecutive patients with hypopituitarism and/or central diabetes insipidus and review of the literature. *Eur J Endocrinol* 2014;170:161-72.
- Bonneville JF. Imagerie des hypophysites. *Ann Endocrinol* 2012;73:76-7.
- Buxton N, Robertson I. Lymphocytic and granulocytic hypophysitis: A single centre experience. *Br J Neurosurg* 2001;15:242-5.
- Caturegli P, Iwama S. From Japan with love: Another tessera in the hypophysitis mosaic. *J Clin Endocrinol Metab* 2013;98:1865-8.
- Caturegli P, Lupi I, Landek-Salgado M, Kimura H, Rose NR. Pituitary autoimmunity: 30 years later. *Autoimmun Rev* 2008;7:631-7.
- Caturegli P, Newschaffer C, Olivi A, Pomper MG, Burger PC, Rose NR. Autoimmune hypophysitis. *Endocr Rev* 2005;26:599-614.
- De Bellis A, Sinisi AA, Pane E, Dello Iacovo A, Bellastella G, Di Scala G, *et al.* Involvement of hypothalamus autoimmunity in patients with autoimmune hypopituitarism: Role of antibodies to hypothalamic cells. *J Clin Endocrinol Metab* 2012;97:3684-90.
- Faje A. Hypophysitis: Evaluation and management. *Clin Diabetes Endocrinol* 2016;2:1-8.
- Fedala NS, Chentli F, Meskine D, Haddam AE. Les hypophysites: Aspects cliniques et évolutifs. *Ann Endocrinol* 2016;77:338.
- Folkerth RD, Price DL, Schwartz M, Black PM, De Girmami U. Xanthomatous hypophysitis. *Am J Surg Pathol* 1998;22:736-41.
- Fukuoka H. Hypophysitis. *Endocrinol Metab Clin North Am* 2015;44:143-9.
- Goudi RB, Pinkerton PH. Anterior hypophysitis and hashimoto's disease in a young woman. *J Pathol Bacteriol* 1962;83:584-5.
- Guo S, Wang C, Zhang J, Tian Y, Wu Q. Diagnosis and management of tumor-like hypophysitis: A retrospective case series. *Oncol Lett* 2016;11:1315-20.
- Gutenberg A, Hans V, Puchner MJ, Kreutzer J, Brück W, Caturegli P, *et al.* Primary hypophysitis: Clinical-pathological correlations. *Eur J Endocrinol* 2006;155:101-7.
- Gutenberg A, Larsen J, Lupi I, Rohde V, Caturegli P. A radiologic score to distinguish autoimmune hypophysitis from nonsecreting pituitary adenoma preoperatively. *AJNR Am J Neuroradiol* 2009;30:1766-72.
- Honegger J, Buchfelder M, Schlaffer S, Droste M, Werner S, Strasburger C, *et al.* Treatment of primary hypophysitis in Germany. *J Clin Endocrinol Metab* 2015;100:3460-9.
- Honegger J, Fahlbusch R, Bornemann A, Hensen J, Buchfelder M, Müller M, *et al.* Lymphocytic and granulomatous hypophysitis: Experience with nine cases. *Neurosurgery* 1997;40:713-23.
- Honegger J, Schlaffer S, Menzel C, Droste M, Werner S, Elbelt U, *et al.* Diagnosis of primary hypophysitis in Germany. *J Clin Endocrinol Metab* 2015;100:3841-9.
- Hunn BH, Martin WG, Simpson S Jr, Mclean CA. Idiopathic granulomatous hypophysitis: A systematic review of 82 cases in the literature. *Pituitary* 2014;17:357-65.
- Imber BS, Lee HS, Kunwar S, Blevins LS, Aghi MK. Hypophysitis: A single-center case series. *Pituitary* 2015;18:630-41.
- Karaca Z, Kelestimur F. The management of hypophysitis. *Minerva Endocrinol* 2016;41:390-9.
- Khare S, Jagtap VS, Budyal SR, Kasaliwal R, Kakade HR, Bukan A, *et al.* Primary (autoimmune) hypophysitis: A single centre experience. *Pituitary*. 2015;18:16-22.
- Kristof RA, Van Roost D, Klingmüller D, Springer W, Schramm J. Lymphocytic hypophysitis: Non-invasive diagnosis and treatment by high dose methylprednisolone pulse therapy? *J Neurol Neurosurg Psychiatry* 1999;67:398-402.
- Lupi I, Manetti L, Raffaelli V, Lombardi M, Cosottini M, Iannelli A, *et al.* Diagnosis and treatment of autoimmune hypophysitis: A short review. *J Endocrinol Invest* 2011;34:e245-52.
- Lupi I, Zhang J, Gutenberg A, Landek-Salgado M, Tzou SC, Mori S, *et al.* From pituitary expansion to empty sella: Disease progression in a mouse model of autoimmune hypophysitis.

- Endocrinology 2011;152:4190-8.
27. Park SM, Bae JC, Joung JY, Cho YY, Kim TH, Jin SM, *et al.* Clinical characteristics, management, and outcome of 22 cases of primary hypophysitis. *Endocrinol Metab (Seoul)* 2014;29:470-8.
28. Roth C, Wilken B, Hanefeld F, Schröter W, Leonhardt U. Hyperphagia in children with craniopharyngioma is associated with hyperleptinemia and a failure in the downregulation of appetite. *Eur J Endocrinol* 1998;138:89-91.
29. Simmonds M. Über das vorkommen von riesenzellen in der hypophyse. *Virch Arch Pathol Anat.* 1917;223:281-90.

How to cite this article: Karrou M, Benyakhlef S, Alla A, Messaoudi N, Amar AO, Rouf S, *et al.* Clinical presentation and management of hypophysitis: An observational study of case series. *Surg Neurol Int* 2021;12:304.