

# Cardiac effects of the c.1583 C→G *LMNA* mutation in two families with Emery-Dreifuss muscular dystrophy

LI ZHANG<sup>1</sup>, HONGRUI SHEN<sup>2</sup>, ZHE ZHAO<sup>2</sup>, QI BING<sup>2</sup> and JING HU<sup>2</sup>

Departments of <sup>1</sup>Cardiovascular Disorders and <sup>2</sup>Neuromuscular Disorders, The Third Hospital of Hebei Medical University, Shijiazhuang, Hebei 050051, P.R. China

Received August 18, 2014; Accepted June 5, 2015

DOI: 10.3892/mmr.2015.4065

**Abstract.** The present study aimed to examine and analyze cardiac involvement in two Emery-Dreifuss muscular dystrophy (EDMD) pedigrees caused by the c.1583 C→G mutation of the lamin A/C gene (*LMNA*). The clinical and genetic characteristics of members of two families with EDMD were evaluated by performing neurological examinations, skeletal muscle biopsies, cardiac evaluations, including electrocardiography, 24 h Holter, ultrasound cardiography and <sup>99</sup>Tc<sup>M</sup>-MIBI-gated myocardial perfusion imaging, and genomic DNA sequencing. Family history investigations revealed an autosomal dominant transmission pattern of the disease in Family 1 and a sporadic case in Family 2. The three affected patients exhibited typical clinical features of EDMD, including joint contractures, muscle weakness and cardiac involvement. Muscle histopathological investigation revealed dystrophic features. In addition, each affected individual exhibited either cardiac arrhythmia, which was evident as sinus tachycardia, atrial flutter or complete atrioventricular inhibition. Cardiac imaging revealed dilated cardiomyopathy in two of the individuals, one of whom was presented with heart failure. The second patient presented with no significant abnormalities in cardiac structure or function. The three affected individuals exhibited a heterozygous missense mutation in the *LMNA* gene (c.1583 C→G), which caused a T528R amino acid change in the *LMNA* protein. In conclusion, the present study identified three patients with EDMD, exhibiting the same dominant *LMNA* mutation and presenting with a spectrum of severe cardiac abnormalities, including cardiac conduction system defects, cardiomyopathy and heart failure. As *LMNA* mutations have been associated with at least six clinical disorders, including EDMD, the results of the present study provide additional mutational and functional data, which

may assist in further establishing *LMNA* mutational variation and disease pathogenesis.

## Introduction

Emery-Dreifuss muscular dystrophy (EDMD) refers to a group of inherited muscular dystrophies, characterized by slow, progressive muscular weakness and atrophy of the humeral and peroneal distributions, with early contractures, which affect the Achilles tendon, spine and elbows (1). EDMD is also associated with cardiomyopathy and abnormalities of the cardiac conduction system (2,3). Cardiac problems are the leading cause of sudden mortality in patients with EDMD, therefore, it is important that cardiac symptoms are diagnosed and treated early to improve outcomes and prolong life expectancy in patients with EDMD (2,4).

EDMD can arise from mutations in five different genes, *EMD*, *LMNA*, *SYNE1*, *SYNE2* and *FHL1*, and can be inherited as an X-linked, autosomal dominant (AD) or autosomal recessive disorder (5). The autosomal forms of the disease are predominantly caused by gene mutations in the lamin A/C gene (*LMNA*) (6), and patients with EDMD exhibiting *LMNA* mutations typically present with more severe cardiac involvement, compared with patients with other EDMD gene mutations. However, there are currently few case reports detailing the various genetic mutations according to phenotype (7-9). The structural/functional correlations are further complicated by *LMNA* mutations, which have been associated with several distinct clinical disorders, including Hutchinson-Gilford progeria syndrome, Charcot-Marie-Tooth disease, limb girdle muscular dystrophy, familial partial lipodystrophy and dilated cardiomyopathy, in addition to EDMD (7). To further improve knowledge regarding specific *LMNA* mutations and disease phenotypes, the present case study assessed the cardiac phenotypes in two families with EDMD, caused by the same c.1583 C→G (T528R) *LMNA* mutation.

## Materials and methods

**Collection of clinical data.** The present case study investigated two Chinese families, which included three EDMD-affected and 12 unaffected members, ascertained by neurological examination. Clinical data and detailed family surveys were collected. The patients and family members included in the

---

*Correspondence to:* Dr Jing Hu, Department of Neuromuscular Disorders, The Third Hospital of Hebei Medical University, 139 Ziqiang Road, Shijiazhuang, Hebei 050051, P.R. China  
E-mail: jinghu689@163.com

**Key words:** Emery-Dreifuss muscular dystrophy, *LMNA*, lamin A/C, cardiomyopathy

Table I. Primer sequences.

Exon	Sense	Anti-sense
1	5TCGGGACGCAAGAGGCAAAG3	5CGACTCGTTTCACGCACTCCTCA3
2	5CAGTGGGAGGAAGAACCATAAC3	5GTTATGGTTCTTCTCCCACTG3
3	5GGGCGGCGTCGTAGAGTAGG3	5AAGTCCTACTCTACGACGCC3
4	5GAGTTTGTAGTGCGACGAAGG3	5TGACCACCTCTAACTGTTACCCT3
5	5CCCCACCAGTTGCTGTTCC3	5GGAACAGCAACCTGGTGGGG3
6	5AGAGGAGGAGCGGGAGGTTTC3	5TCTGGACCTCTGAGTGACCG3
7	5CCTCCTCATCCACCTCCTCCAC3	5GCCGCAGCAGCTTCTCACAG3
8	5TCAGGGTGAACCTTGGTGGG3	5AATGGAGATGATCCCTTGCTG3
9	5CAGGTGTTCTGTGCCTTCCA3	5 GTGGAAGGCACAGAACACCTG3
10	5 GTGGTGGTGATGGAGCAGGT3	5 TGAGGACGACGAGGATGAGG3
11	5CGTGACACTGGAGGCAGAAGAG3	5GGCAGAAGAGCCAGAGGAGATG3

present study provided written informed consent and the study was approved by the ethics committee of the Third Hospital of Hebei Medical University (Hebei, China).

**Muscle biopsy, histochemistry and immunohistochemical analyses.** Skeletal muscle biopsies were performed for diagnostic purposes on the three affected patients. Briefly, muscle biopsy specimens (0.5 cm diameter, 1.0 cm length) were collected from the biceps brachii, under local lidocaine anesthesia (Xiamen Kang Source Biotechnology Limited, Xiamen, China). The muscle biopsy specimens were frozen in isopentane cooled in liquid nitrogen, and 7  $\mu$ m cryostat sections were made using an EM UC ultrathin section machine (Leica Microsystems, Mannheim, Germany), and were used for the subsequent histochemistry and immunofluorescence staining experiments. Morphological analysis of the muscle was performed using the following routine histological stains: Hematoxylin and eosin, modified Gomori trichrome, NADH-tetrazoliumreductase, succinate dehydrogenase, adenosine monophosphate deaminase and cytochrome *c* oxidase to assess enzymatic activity, adenosine triphosphatase at pH 9.8, 4.3 and 4.6 to assess muscle fiber distribution, acid phosphatase, and oil red O staining to assess fatty deposition (all Shanghai Bioleaf Biotech Co., Ltd., Shanghai, China). Immunohistochemical analysis was performed using antibodies targeting procoagulant and anticoagulant membrane components. The following antibodies were used in 1:50 dilutions overnight at 4°C: Anti-emerin (NCL-EMERIN) and anti-lamin A/C (NCL-LAM-A/C) (Novocastra, Newcastle upon Tyne, UK). Biotinylated anti-mouse immunoglobulin G secondary antibodies (Novocastra) were then used for 1 h at 37°C. The avidin-biotin-peroxidase complex (ABC) method was used for signal detection (ABC kit; Vector Laboratories, Inc., Burlingame, CA, USA). After staining the muscle specimens were visualized, and the images were captured, using a BX51 confocal scanning laser microscope (Olympus Corporation, Tokyo, Japan).

**Investigation of cardiac involvement.** Electrocardiography (ECG) (FX-740; Fukuda Denshi Co., Ltd., Tokyo, Japan), 24 h Holter (FM-800; Fukuda Denshi Co., Ltd.), ultrasound cardiography (UCG) (iE33; Philips, Amsterdam, Netherlands)

and  $^{99}\text{Tc}^{\text{M}}$ -MIBI-gated myocardial perfusion imaging (GPI) (Infinita Hawkeye 4; GE Healthcare Bio-Sciences, Piscataway, NJ, USA) investigations were performed on the three patients with EDMD (patients 1, 2 and 3).

**Gene analysis.** Genomic DNA from nine family members from Family 1, and six family members from Family 2 were extracted from peripheral blood (500  $\mu$ l) using the Genomic DNA Extraction kit 5.0 (Takara Biotechnology Co., Ltd., Dalian, China), according to the manufacturer's instructions. Control genomic DNA samples were obtained from 50 healthy Chinese unrelated individuals. DNA concentration was determined using a Nanodrop ND-1000 spectrophotometer (Thermo Fisher Scientific, Inc., Wilmington, DE, USA). Each reaction required 50 ng genomic DNA, 10 pmol primer sets (sequences in Table I; Sigma-Aldrich, St. Louis, MO, USA), dNTP and Qiagen Multiplex PCR Master Mix (Qiagen, Hilden, Germany). The following conditions were used for multiplex polymerase chain reaction (PCR): 15 min at 95°C; 40 cycles of amplification at 95°C for 30 sec, 60°C for 30 sec and 72°C for 1 min; 35 cycles of denaturation at 95°C for 45 sec 63.5°C for 30 sec and 72°C for 45 sec; 10 min at 72°C. Briefly, 50 ng genomic DNA from the patients was amplified using the hot-start PCR method. The DNA was subjected to PCR using the Qiagen Multiplex PCR Master Mix. Each PCR reaction consisted of 50 ng genomic DNA, 16.8  $\mu$ l SYBR Green PCR Master Mix, and 250 nm specific primer pairs, in a total 25  $\mu$ l volume. Using a pre-sequencing kit (USB Corporation, Cleveland, OH, USA), the PCR products were purified and sequenced by dye terminator chemistry using an ABI Prism 377 DNA Sequencer (Applied Biosystems, Foster City, CA, USA). The resulting sequences were subsequently aligned and mutations were determined using Sequencher version 4.9 sequence alignment software (Gene Codes Corporation, Ann Arbor, MI, USA).

## Results

**Clinical data.** The clinical data of the three patients with EDMD are presented and summarized in Fig. 1 and Table II. The patients from Family 1 exhibited an AD mode of inheritance, whereas the patient from Family 2 was a sporadic

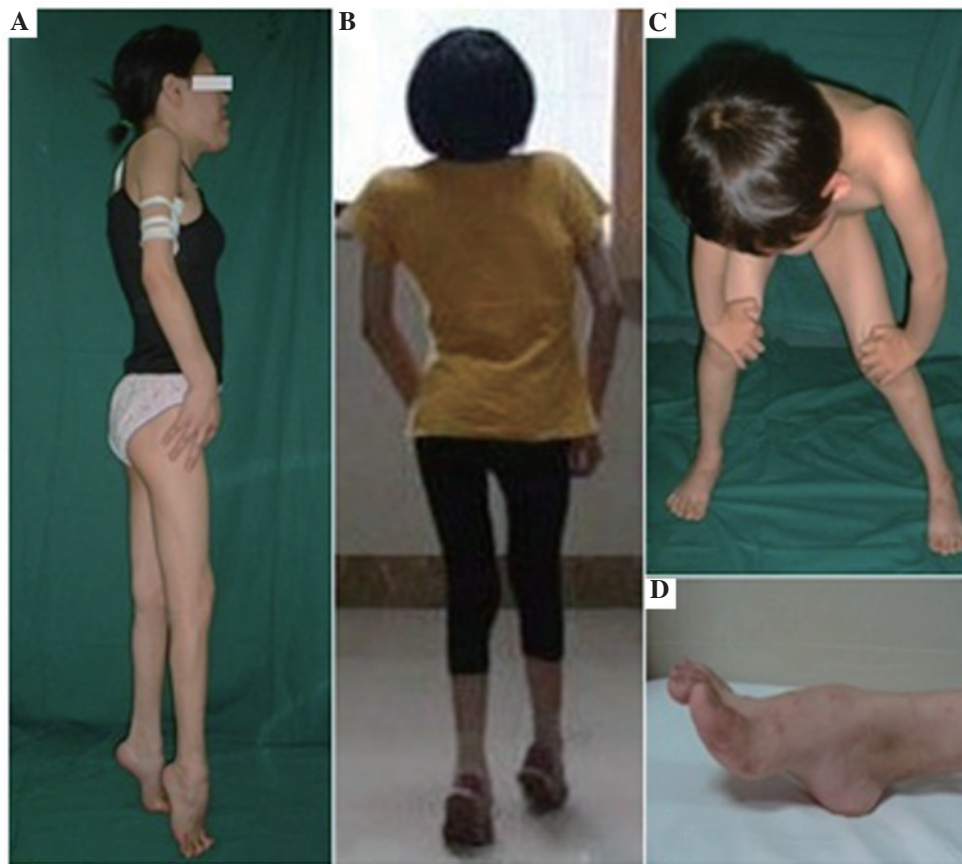

Figure 1. Images of the three patients with Emery-Dreifuss muscular dystrophy in the present study. (A and B) Patients 1 and 3 exhibited shoulder, elbow and ankle contractures, standing on toes, generalized muscle atrophy and limited neck mobility. (C) Patient 2, the daughter of Patient 1, exhibited a positive Gower's sign. (D) Patient 3 also exhibited Achilles tendon contracture.

case (Fig. 2A and B). The levels of serum creatine kinase were marginally increased in Patient 2, and were normal in Patients 1 and 3. The electromyogram revealed myogenic damage in each of the three patients.

**Pathological analysis of muscle biopsies.** Routine histological analysis revealed dystrophic features in the muscle tissues, with degeneration, polyfocal necrosis, fiber splitting and moderate to marked fibrosis. Adipose tissue infiltration was also observed. In addition, atrophic and scattered regenerating fibers were noted. The ATP enzyme staining revealed a predominance of type I fibers. Immunofluorescence staining for emerin and lamin A/C revealed normal labeling along the membrane in all three cases (Fig. 3).

**Cardiac evaluation.** Patient 1 (33 years old) presented with panicky, shortened breathing and dyspnea. The heart border expanded to the left and a heart rate of 42 beats per min (bpm) was recorded. Patient 2 (12 years old), the daughter of Patient 1, presented with no clear cardiac abnormalities upon initial clinical examination. Patient 3 (24 years old) presented with panicky and transient amaurosis with a heart rate of 52 bpm.

Further cardiac assessments revealed a variety of abnormalities in each patient (Figs. 4 and 5). The ECG and Holter of Patient 1 demonstrated complete atrioventricular inhibition and premature ventricular contractions of 26 beats/24 h. The UCG revealed that this individual had generalized cardiac enlarge-

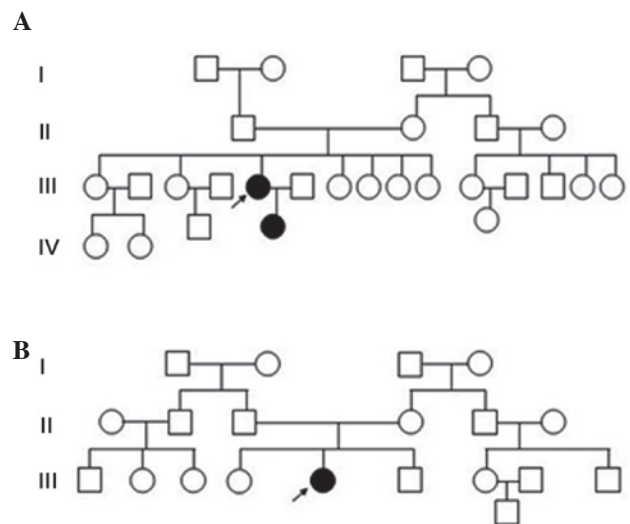


Figure 2. Pedigree of the two families examined in the present study. (A) Family 1 pedigree. The arrow indicates the proband. Individuals diagnosed with EDMD are represented by solid black symbols and healthy individuals are indicated with open symbols. (B) Family 2 pedigree. The arrow indicates the proband. Open symbols represent healthy individuals. Circles indicate females, squares indicate males.

ment, mitral and tricuspid valve regurgitation and decreased function of the left ventricle (Table II). The  $^{99}\text{Tc}^{\text{M}}$ -MIBI GPI assessment indicated left ventricular hypertrophy and varie-



Table II. Clinical data of patients 1, 2 and 3 in the two pedigrees.

Patient	Gender/ age (years)	Weakness			Atrophy					Contracture					UCG		
		Prox	Dist		Limbs	Body	Neck	Shoulder	Elbow	Ankle	Spine	EMG myogenic	EDV/ ESV (ml)	LVEF (%)	CK (U/l)		
1	F/33	+	+		+	+	+	+	+	+	+	163/70	40	140			
2	F/12	+	+		+	-	-	-	+	+	+	80/41	69	255			
3	F/24	+	+		+	+	+	+	+	+	+	135/66	55	127			

Patient 1, proband of family 1; patient 2, daughter of patient 1; Patient 3, proband of family 2; Prox, proximal; Dist, distal; CK, serum creatine kinase; EMG, electromyography; EDV, left ventricular end-diastolic volume; ESV, left ventricular end-systolic volume; LVEF, left ventricular ejection fraction; UCG, ultrasound cardiography.

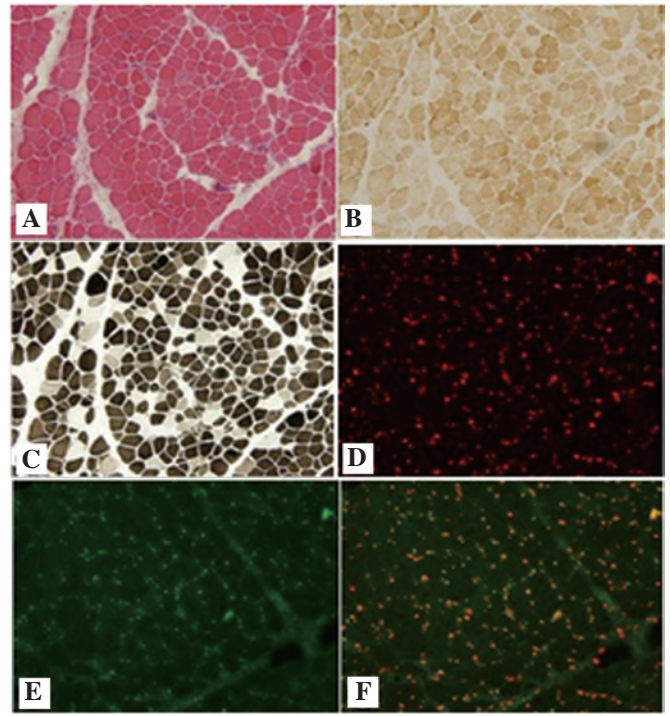


Figure 3. Representative histopathological analysis of muscle biopsies from Patient 1 with Emery-Dreifuss muscular dystrophy. (A) Hematoxylin and eosin staining revealed scattered muscle fiber degeneration, necrosis, regeneration and connective tissue proliferation. (B) Cytochrome *c* staining revealed decreased enzyme activity. (C) Staining of the ATP enzyme revealed type I fiber predominance. (D) Immunofluorescence staining using a monoclonal antibody against emerin demonstrated a normal muscle fiber nuclear membrane. (E) Immunofluorescence staining using a monoclonal antibody against lamin A/C revealed a normal muscle fiber nuclear membrane. (F) Merged immunofluorescence staining using monoclonal antibodies against emerin and lamin A/C demonstrated normal labeling along the muscle fiber nuclear membrane. Magnification, x40.

gated changes in the left ventricular myocardium. Patient 2 suffered from sinus tachycardia, as determined by ECG and Holter. The UCG and <sup>99</sup>Tc<sup>M</sup>-MIBI GPI scan was normal. The ECG and Holter of Patient 3 revealed atrial flutter and the UCG demonstrated mild left ventricular enlargement and decreased diastolic function of the left ventricle (Table II). The <sup>99</sup>Tc<sup>M</sup>-MIBI GPI assessment revealed that myocardial perfusion was moderately decreased in the apex of the left ventricle.

**Genetic analysis.** The genetic analysis in the present study identified one missense mutation, c.1583C→G, in exon 9 of *LMNA*. This change caused a T528R mutation in the LMNA protein. The mutation was heterozygous in the three affected individuals examined in the present study, and none of the 12 unaffected family members (seven from Family 1 and five from Family 2) exhibited this base change on either allele (Fig. 6). In addition, the mutation was not identified in 50 Chinese control chromosomes.

**Discussion**

The *LMNA* gene is located on chromosome 1q21 and encodes the A-type lamins, lamin A and C, and two minor isoforms, C2 and AΔ10, which arise through alternative splicing. The first 566 amino acids are identical in lamins A and C (10).

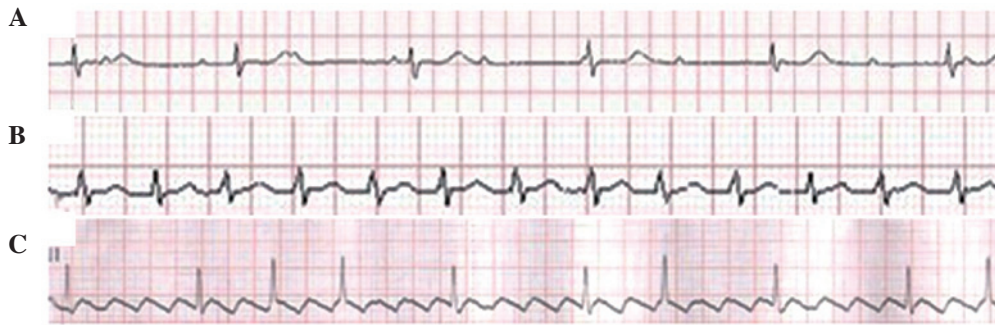

Figure 4. Electrocardiogram traces of patients 1, 2 and 3. (A) Patient 1 exhibited a complete atrioventricular block. (B) Patient 2 exhibited sinus tachycardia. (C) Patient 3 exhibited atrial flutter.

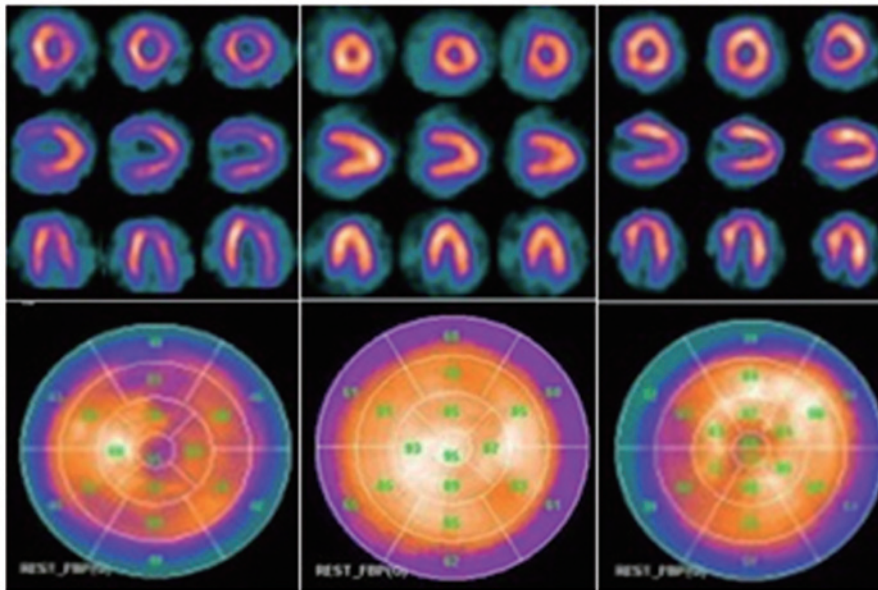


Figure 5.  $^{99}\text{Tc}^{\text{M}}$ -MIBI-gated myocardial perfusion imaging of patients 1, 2 and 3. Patient 1 exhibited variegated changes in the left ventricular myocardium. Myocardial perfusion imaging was normal for Patient 2. Patient 3 exhibited decreased myocardial perfusion in the left ventricular apex.

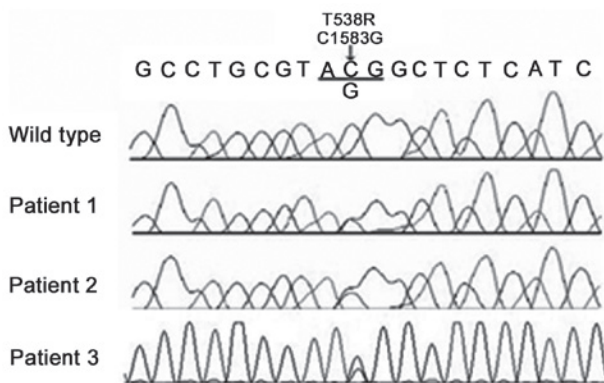


Figure 6. *LMNA* gene sequences of patients 1, 2 and 3. Chromatograms of the heterozygous c.1583 C→G (p.T528R) mutation in exon 9 of *LMNA*.

Structurally, the protein is composed of a central  $\alpha$ -helical dimerization domain flanked by a short amino-terminal head and a larger carboxy-terminal tail (11). Lamins A and C are located in the inner nuclear lamina and are widely expressed in skeletal and cardiac muscle, fat, blood vessels, skin and nerve

tissue (12). Lamins A and C are considered to be important in maintaining the size and shape of the nucleus, and contribute to DNA replication, chromatin formation, RNA splicing, cell differentiation and signal transduction (10,11,13).

The three patients with EDMD identified in the present study were members of two families. The first family presented with an AD inheritance pattern, while the single patient with EDMD in Family 2 was the only known affected member, suggesting a sporadic mutation. Patients 1, 2 and 3 all presented with the typical clinical features of EDMD, including joint contractures, muscle weakness and cardiac involvement. The contractures initially affected the shoulders, elbows or ankles and impacted the posterior cervical muscles, thereby limiting neck flexion and forward spine flexion. Muscle weakness was slowly progressive and typically targeted to the peroneal and humeral distribution. With time, a limb-girdle distribution of muscle weakness developed. Immunostaining for emerin and lamin A/C revealed normal labeling along the nuclear membrane in all three cases. Although routine histological analyses revealed dystrophic features, these phenotypes lacked specificity for EDMD and, therefore, gene analysis was required.



It was revealed that each patient possessed the same heterozygous missense mutation, c.1583C→G, in exon 9 of *LMNA*, which caused a T528R amino acid change in the LMNA protein. A previous study suggested that the majority (76%) of AD-EDMD cases arise from sporadic mutations (14). The mutation identified in the present study was previously described in reports of Italian and German individuals, suggesting that this change exhibits an increased incidence despite ethnic differences (15,16). In the present study, Patient 3 was the only known individual from Family 2 to exhibit the T528R *LMNA* mutation, which supported the suggestion that it was a sporadic mutation.

Cardiac involvement is a frequent and serious complication in EDMD, with a high risk of sudden mortality (4). The degree of cardiac involvement negatively correlates with the severity of skeletal muscle weakness, however, it demonstrates a positive correlation with age and disease course (17). The predominant cardiac manifestations are progressive conduction system defects and/or sinus node dysfunction. The incidence of atrial fibrillation and atrial flutter is the highest, followed by atrioventricular inhibition (18). A number of patients present with ventricular tachycardia, ventricular fibrillation and other malignant arrhythmias, which are the leading causes of sudden mortality in patients with EDMD (15,17). Consistent with previous reports, the present study revealed various ECG findings, which were positively correlated with age and disease course in all three patients. The ECG demonstrated only sinus tachycardia in the youngest patient (Patient 2; 12-years old). By contrast, atrial flutter was observed in Patient 3 (24-years old), supporting sinus node dysfunction and complete atrioventricular inhibition in the oldest patient (Patient 1; 33-years old). This latter finding suggested severe conduction system defects.

It has been previously reported that cardiac involvement in AD-EDMD caused by *LMNA* mutations may be more severe, compared with other forms of EDMD (17,19,20) and are often accompanied by dilated cardiomyopathy (DCM), left ventricular dysfunction and heart failure (15,20). Pathologically, the normal myocardium is progressively replaced by fibro-adipose tissue, resulting in atrial and ventricular enlargement with progression towards clinical heart failure (15,21). The cardiac imaging of the three patients reported in the present study revealed that myocardial damage was progressive with increasing age and course of disease. The oldest patient (Patient 1) presented with left ventricular dysfunction, enlarged heart chambers and severe myocardial perfusion defects, which suggested dilated cardiomyopathy and heart failure. Patient 3 also developed decreased myocardial perfusion in the left ventricular apex. By contrast, the youngest patient (Patient 2) revealed no abnormal findings on cardiac imaging examination, therefore, follow-up observations are required as this patient ages.

Amino acid 528 is located on the highly conserved carboxy terminal tail of lamin A/C, suggesting that the T528R mutation may negatively impact the structure of the carboxy terminal tail and decrease protein stability (22,23). It has been reported that patients with AD-EDMD caused by the R541H *LMNA* mutation develop severe DCM, requiring heart transplant during childhood (9,24). Analysis of protein function has revealed that the lamin A/C p.R541H mutation causes

the highly conserved sequence of the carboxy terminal tail to mis-fold, leading to severe cardiac damage, which is consistent with the observations of the present study (25,26).

In conclusion, the present study identified three patients with EDMD exhibiting the same dominant *LMNA* mutation. These patients presented with a spectrum of severe cardiac abnormalities, including cardiac conduction system defects, cardiomyopathy and heart failure. Since *LMNA* mutations have been associated with at least six clinical disorders, including EDMD, the present case study provides additional mutational and functional data, which may assist in further establishing *LMNA* mutational variation and disease pathogenesis.

## References

- Dreifuss FE and Hogan GR: Survival in x-chromosomal muscular dystrophy. *Neurology* 11: 734-737, 1961.
- Emery AE: Emery-Dreifuss muscular dystrophy—a 40 year retrospective. *Neuromuscul Disord* 10: 228-232, 2000.
- Emery AE and Dreifuss FE: Unusual type of benign x-linked muscular dystrophy. *J Neurol Neurosurg Psychiatry* 29: 338-342, 1966.
- Becane HM, Bonne G, Varnouss, Muchir A, Ortega V, Hammouda EH, Urtizberea JA, Lavergne T, Fardeau M, Eymard B, *et al*: High incidence of sudden death with conduction system and myocardial disease due to lamins A and C gene mutation. *Pacing Clin Electrophysiol* 23: 1661-1666, 2000.
- Emery AE: The muscular dystrophies. *Lancet* 359: 687-695, 2002.
- Bonne G, Di Barletta MR, Varnouss, Bécane HM, Hammouda EH, Merlini L, Muntoni F, Greenberg CR, Gary F, Urtizberea JA, *et al*: Mutations in the gene encoding lamin A/C cause autosomal dominant Emery-Dreifuss muscular dystrophy. *Nat Genet* 21: 285-288, 1999.
- Rankin J and Ellard S: The laminopathies: A clinical review. *Clin Genet* 70: 261-274, 2006.
- Waters DD, Nutter DO, Hopkins LC and Dorney ER: Cardiac features of an unusual X-linked humeroperoneal neuromuscular disease. *N Engl J Med* 293: 1017-1022, 1975.
- Fatkin D, MacRae C, Sasaki T, Wolff MR, Porcu M, Frenneaux M, Atherton J, Vidaillet HJ Jr, Spudich S, De Girolami U, *et al*: Missense mutations in the rod domain of the lamin A/C gene as causes of dilated cardiomyopathy and conduction-system disease. *N Engl J Med* 341: 1715-1724, 1999.
- Fisher DZ, Chaudhary N and Blobel G: cDNA sequencing of nuclear lamins A and C reveals primary and secondary structural homology to intermediate filament proteins. *Proc Natl Acad Sci USA* 83: 6450-6454, 1986.
- Goldman RD, Gruenbaum Y, Moir RD, Shumaker DK and Spann TP: Nuclear lamins: Building blocks of nuclear architecture. *Genes Dev* 16: 533-547, 2002.
- Moir RD, Spann TP and Goldman RD: The dynamic properties and possible functions of nuclear lamins. *Int Rev Cytol* 162B: 141-182, 1995.
- Lin F and Worman HJ: Structural organization of the human gene encoding nuclear lamin A and nuclear lamin C. *J Biol Chem* 268: 16321-16326, 1993.
- Bonne G, Mercuri E, Muchir A, Urtizberea A, Bécane HM, Recan D, Merlini L, Wehnert M, Boor R, Reuner U, *et al*: Clinical and molecular genetic spectrum of autosomal dominant Emery-Dreifuss muscular dystrophy due to mutations of the lamin A/C gene. *Ann Neurol* 48: 170-180, 2000.
- Sanna T, Dello Russo A, Toniolo D, Vytopil M, Pelargonio G, De Martino G, Ricci E, Silvestri G, Giglio V, Messano L, *et al*: Cardiac features of Emery-Dreifuss muscular dystrophy caused by lamin A/C gene mutations. *Eur Heart J* 24: 2227-2236, 2003.
- Vytopil M, Benedettis, Ricci E, Galluzzi G, Dello Russo A, Merlini L, Boriani G, Gallina M, Morandi L, Politano L, *et al*: Mutation analysis of the lamin A/C gene (*LMNA*) among patients with different cardiomyopathy phenotypes. *J Med Genet* 40: e132, 2003.
- Brodsky GL, Muntoni F, Miodic S, Sinagra G, Sewry C and Mestroni L: Lamin A/C gene mutation associated with dilated cardiomyopathy with variable skeletal muscle involvement. *Circulation* 101: 473-476, 2000.

18. Voit T, Krogmann O, Lenard HG, Neuen-Jacob E, Wechsler W, Goebel HH, Rahlf G, Lindinger A and Nienaber C: Emery-Dreifuss muscular dystrophy: Disease spectrum and differential diagnosis. *Neuropediatrics* 19: 62-71, 1988.
19. Funakoshi M, Tsuchiya Y and Arahata K: Emerin and cardiomyopathy in Emery-Dreifuss muscular dystrophy. *Neuromuscul Disord* 9: 108-114, 1999.
20. van Berlo JH, Duboc D and Pinto YM: Often seen but rarely recognised: Cardiac complications of lamin A/C mutations. *Eur Heart J* 25: 812-814, 2004.
21. Wehnert MS and Bonne G: The nuclear muscular dystrophies. *Semin Pediatr Neurol* 9: 100-107, 2002.
22. Garg A, Cogulu O, Ozkinay F, Onay H and Agarwal AK: A novel homozygous Ala529Val LMNA mutation in Turkish patients with mandibuloacral dysplasia. *J Clin Endocrinol Metab* 90: 5259-5264, 2005.
23. Shen JJ, Brown CA, Lupski JR and Potocki L: Mandibuloacral dysplasia caused by homozygosity for the R527H mutation in lamin A/C. *J Med Genet* 40: 854-857, 2003.
24. Sébillon P, Bouchier C, Bidot LD, Bonne G, Ahamed K, Charron P, Drouin-Garraud V, Millaire A, Desrumeaux G, Benaïche A, *et al*: Expanding the phenotype of LMNA mutations in dilated cardiomyopathy and functional consequences of these mutations. *J Med Genet* 40: 560-567, 2003.
25. Cenni V, Sabatelli P, Mattioli E, Marmirolis, Capanni C, Ognibene A, Squarzoni S, Maraldi NM, Bonne G, Columbaro M, *et al*: Lamin A N-terminal phosphorylation is associated with myoblast activation: Impairment in Emery-Dreifuss muscular dystrophy. *J Med Genet* 42: 214-220, 2005.
26. Krimm I, Ostlund C, Gilquin B, Couprie J, Hossenlopp P, Mornon JP, Bonne G, Courvalin JC, Worman HJ and Zinn-Justins: The Ig-like structure of the C-terminal domain of lamin A/C, mutated in muscular dystrophies, cardiomyopathy and partial lipodystrophy. *Structure* 10: 811-823, 2002.