

[PICTURES IN CLINICAL MEDICINE]

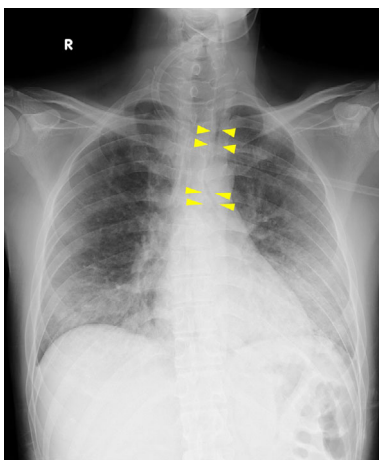
Pneumomediastinum Associated with HIV-positive *Pneumocystis jirovecii* Pneumonia

Tomohiro Hosoda and Mitsuo Sakamoto

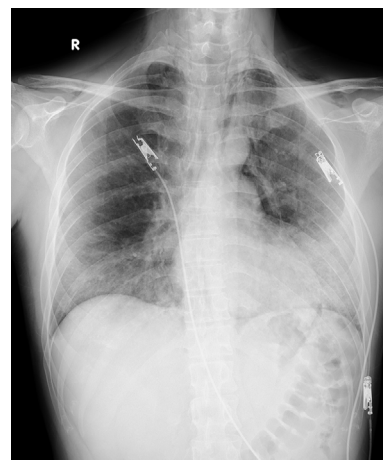
Key words: pneumomediastinum, *Pneumocystis jirovecii* pneumonia, HIV

(Intern Med 58: 3607-3608, 2019)

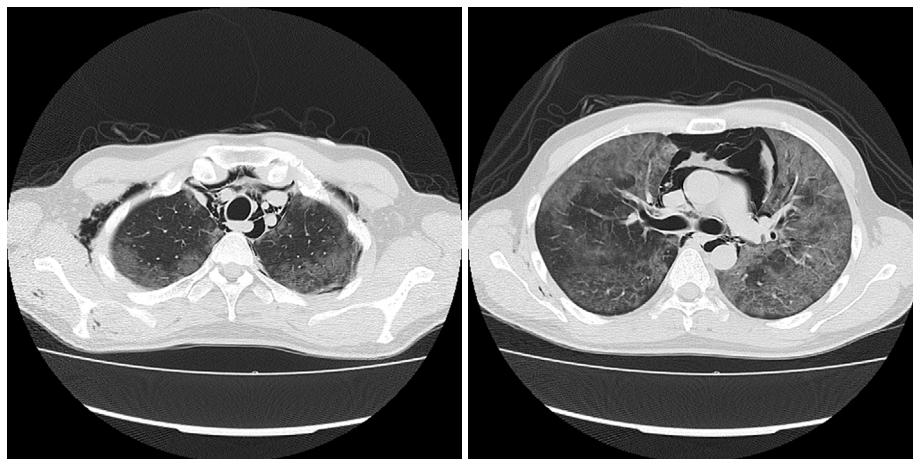
(DOI: 10.2169/internalmedicine.3524-19)



Picture 1.



Picture 2.



Picture 3.

Pneumomediastinum is a rare but severe complication of *Pneumocystis jirovecii* pneumonia with HIV infection (HIV-PCP) (1). Spontaneous pneumomediastinum occurs due to an abrupt increase in the transalveolar pressure gradient, as

Department of Infectious Disease, Kawasaki Municipal Kawasaki Hospital, Japan

Received: June 20, 2019; Accepted: July 3, 2019; Advance Publication by J-STAGE: August 6, 2019

Correspondence to Dr. Tomohiro Hosoda, ottotto723@gmail.com

is seen during violent coughing (2). A 37-year-old Japanese man presented to our hospital with a 2-week history of dyspnea and non-productive cough. Chest computed tomography (CT) on admission revealed diffuse bilateral ground-glass opacities without pulmonary cysts or pneumomediastinum. He was diagnosed with HIV-PCP based on a microscopic examination of a sputum specimen and a Western blot assay of HIV-1. The patient's respiratory failure and cough did not improve by day 3 of hospitalization despite treatment with trimethoprim-sulfamethoxazole (ST) and systemic corticosteroids, and chest X-ray revealed a paratracheal air line, indicating pneumomediastinum (Picture 1, arrowheads). On day 6 of hospitalization, he suddenly complained of precordial pain, and subsequent chest X-ray and CT revealed subcutaneous emphysema and exacerbation of pneumomediastinum without any new cystic lesions (Picture 2, 3). He was administered intravenous pen-

tamidine, and pneumomediastinum regressed conservatively. His respiratory condition gradually improved.

The authors state that they have no Conflict of Interest (COI).

References

1. Cheng WL, Ko WC, Lee NY, et al. Pneumomediastinum in patients with AIDS: a case report and literature review. *Int J Infect Dis* **22**: 31-34, 2014.
2. Saleem N, Parveen S, Odigwe C, et al. Pneumomediastinum, pneumorrhachis, and subcutaneous emphysema in *Pneumocystis jiroveci* pneumonia in AIDS. *Proc (Bayl Univ Med Cent)* **29**: 188-190, 2016.

The Internal Medicine is an Open Access journal distributed under the Creative Commons Attribution-NonCommercial-NoDerivatives 4.0 International License. To view the details of this license, please visit (<https://creativecommons.org/licenses/by-nc-nd/4.0/>).